

# **Role of Multi Slice Computed Tomography in Assessment of Transposition of Great Arteries**

## **Abstract**

**Background:** Transposition of the great arteries (TGA) is a congenital conotruncal malformation. Imaging has an essential role in evaluating TGA, both prior and post-surgery, aiding in defining the anatomy, quantifying hemodynamics, and assessing complications. This research evaluated the multi-slice computed tomography (MSCT) role in TGA assessment in correlation with echocardiogram and correction either by catheterization or surgically.

**Methods:** This prospective trial was carried out on 20 cases with suspected or diagnosed cases of TGA and underwent MSCT heart angiography and great vessels for diagnosis confirmation, had limited or incomplete visualization of transposition of great arteries during echocardiography (echo) examination or underwent TGA operations and post-operative follow up. All patients were subjected to history taking from the parents, echo and MSCT.

**Results:** ECHO can significantly predict TGA (AUC= 0.856, P value <0.001) at cut off  $\leq 6.6$  with 79.95% sensitivity, 84.62% specificity, 88.2% PPV and 73.3% NPV. MSCT can significantly predict TGA (AUC= 0.877, P value <0.001) at cut off  $\leq 0.16$  with 89.47% sensitivity, 76.92% specificity, 85% PPV and 83.3% NPV. By comparing between ECHO and MSCT as predictors at the same time.

**Conclusions:** MSCT and transthoracic echocardiogram combination can provide effective and safe imaging for preoperative evaluation, but for post-operative assessment of surgically operated/ catheterized TGA cases, MSCT angiography is the method of choice.

**Keywords:** Multi Slice Computed Tomography, Transposition, Great Arteries, Echocardiogram.

## **Introduction:**

Transposition of the great arteries (TGA) is a congenital conotruncal malformation with discordant connections between the great arteries and ventricles, with the left ventricle (LV) being the origin of the pulmonary artery (PA) , and the right ventricle (RV) is the origin of aorta <sup>[1]</sup>.

The two predominant types of TGA are total transposition or dextro-transposition of the great arteries (D-TGA), also known as D-loop, and congenitally corrected transposition (CCTGA), also known as L-loop or L-TGA. The ventricular and atrial connections are concordant in D-TGA, while they are discordant in CCTGA, with the right atrium linked to the LV, and the left atrium linked to the RV <sup>[2, 3]</sup>.

During the neonatal period, D-TGA can exist and can be managed via operations such as arterial switch operation (ASO), atrial switch operation (AtrSO), nikaidoh or rastelli operations <sup>[4, 5]</sup>.

Some of the frequent complications occurring from ASO are supraaortic pulmonary or branch PA stenosis, neo aortic dilatation and coronary artery narrowing are, while the frequent complications occurring from AtrSO are systemic ventricular dysfunction, arrhythmia, baffle stenosis and leak <sup>[6]</sup>.

CCTGA may occur at later phase in life, even in adulthood. operations may be performed for lesions associating it such as ventricular septal defect (VSD), subpulmonic stenosis, and tricuspid regurgitation <sup>[7, 8]</sup>.

Anatomic correction for CCTGA involves a double-switch surgery including both atrial and arterial switch operations. Imaging has an essential role in TGA evaluation, both prior and post-surgery, aiding in defining the anatomy, quantifying hemodynamics, and assessing complications <sup>[9, 10]</sup>.

The work aimed to evaluate the multi-slice computed tomography (MSCT) role in assessment of TGA in correlation with echocardiogram and correction either by catheterization or surgically.

### **Materials and Methods:**

This prospective trial was carried out 20 cases aged from 23 days to 18 years, 12 males and 8 females, with suspected or diagnosed cases of TGA and subjected to MSCT angiography of the heart and great vessels for diagnosis confirming, had limited or incomplete visualization of transposition of great arteries during echocardiography (echo) examination or underwent TGA operations and post-operative follow up in Radiodiagnosis Department, Tanta University Educational Hospital between March 2021 and February 2022.

Exclusion criteria were renal dysfunction (serum creatinine > 1.5 mg /dL) and serious allergy to iodinated contrast media.

All cases were subjected to history taking from the parents, echo and MSCT.

**Patient preparation for MSCT:** Intravenous (IV) cannula (20-to 24-gauge) was placed in a lower limb peripheral vein (11 cases), or in right upper limb vein (9 cases). Cases younger than 4 years (n= 14) were sedated by I.V. midazolam (n=2) (0.05-0.1mg/kg) or oral chloral hydrate (n= 12) (50–100 mg/kg; maximum dose, 2000 mg). Cases with older age (n=6) were reassured verbally with satisfactory responses and were able to completely suspend respiration. There was no need for general anesthesia.

Emergency set containing oxygen container with mask and extension tubing, sphygmomanometer and emergency medications such as adrenaline for severe hypotension or anti-histaminic for contrast reaction.

**Data acquisition:** scanning was performed with 320-row MSCT scanner (Aquilion One, Toshiba Medical Systems, Otawara, Japan). The case was laid down on the CT table in supine position and a restrain was applied over the chest to minimize motion artifacts.

Electrocardiogram (ECG) electrodes were placed on chest wall after putting alcohol for skin preparation and ECG trace was observed to ensure that good amplitude of R wave was used for scan trigger. The IV line was connected and tested with saline to be sure that no extravasation could occur. After that, a scanogram (lateral and frontal views) was performed where the scan began from neck root to proximal common carotid and subclavian arteries reaching down to the portal vein level. In 3 and 17 cases respectively, non-diluted, non-ionic contrast material (Ultravist 370, Schering AG, Germany or Omnipaque 350, Nycomed, Amersham) was injected through the IV cannula utilizing dual syringe mechanical power injector (Stellant D, Medrad, Indianola, PA, USA) at a rate of flow of 1-1.5 ml/sec, and in older children, it was increased to 3 ml/sec. The volume of contrast was computed -based on body weight at a maximum dose of 2 ml /kg followed by IV saline chaser injection of 1 ml/kg. to prevent air bubbles formation in connection tube, certain care was taken to avoid dampening of transmitted pressure and air embolism, which cause lower flow.

Manual Bolus tracking was performed 20 seconds post injection of the contrast material (for lower limb venous line) and after 10 to 15 seconds (for upper limb venous line), the scan is performed following both ventricles' opacification. CT parameters were optimized depending on patient's weight and all scans were performed in a craniocaudal direction. The cases were scanned via a single-phase retrospective ECG gated CT angiography volume scan with a rotation time of 0.35 s and a tube voltage of 80 kV elevated to 100 kV in 6 older cases. The current of the tube was automatically adjusted according to the shape and size of each case.

Images' quality was viewed prior the end of examination. For evaluation of the radiation dose post-examination, the dose-length product (DLP) was recorded. 15-30 minutes post-procedure, the case was observed till recovered. Nothing was administrated orally till total recovery. Then, the peripheral venous line was removed. No complications whatsoever

occurred during the MSCT angiography examination including contrast extravasation or reaction.

**Image reconstruction and post processing** was performed in 0.5 mm-thickness slice and post-processing scans was performed by the end of examination on a specific vital Images workstation (Vitreax, vital images, USA). Three-dimensional volume rendering (VR), maximum intensity projections (MIP), curved and multiplanar planer reformations (MPR) were utilized to view heart malformations. Reformation planes are performed by projecting a line on one of the transverse sections so that the resultant MPR images will be parallel to the projected line and perpendicular to the transverse plane. Thin MPR images are utilized for accurate vessels' measurements. Curved planar images were utilized for visualizing curved vascular structures for evaluation of the caliber of the main pulmonary arteries and thoracic aorta. VR was obtained after bone removal. The VR technique was convenient for viewing structures that course oblique or parallel to the transverse plane and provided a road map for the surgery.

**MIP and minimum intensity projection (MinIPs):** Airways and peripheral vessels are usually visualized better as sections' assimilation in a volume slab. Using this method, CT images are obtained at their usual section thickness and then assembled in multiples, or "slabs" to form a thicker image.

**Radiation dose evaluation:** the exact dose length product conversion coefficients for children were different for different age ranges<sup>[11]</sup>.

### **Statistical analysis**

SPSS V.20 was used for all of the statistical analyses. Quantitative and proportional displays of qualitative information were provided. Quantitative information shown as mean and standard deviation (SD). Chi-square analysis was done to show the relationships between categorical variables. The significance threshold used was  $p < 0.05$ .

## Results:

Table 1 shows demographic data of the studied patients.

**Table 1: Demographic data of the studied patients (n = 20)**

Sex	Male	12 (60 %)
	Female	8 (40 %)
Age (years)	Less than 1 year	12 (60 %)
	More than 1 year	8 (40 %)

Data are presented as frequency (%).

Table 2 shows distribution of the studied cases according to clinical symptoms, echo and CT and according to ECHO and CT postoperative.

**Table 2: Distribution of the studied cases according to clinical symptoms, echo and CT (n = 20) and according to ECHO and CT postoperative**

<b>Clinical</b>		<b>Failure to thrive</b>	3 (15 %)
		<b>Cyanosis</b>	13 (65 %)
		<b>Recurrent chest infections</b>	5 (25 %)
		<b>Poor feeding</b>	4 (20 %)
		<b>Dyspnea</b>	17 (85 %)
		<b>Hemoptysis</b>	1 (5 %)
		<b>Tachypnea</b>	5 (25 %)
<b>ECHO</b>	<b>Situs</b>	<b>Solitus with levocardia</b>	16 (80 %)
		<b>Solitus with dextrocardia</b>	2 (10 %)
		<b>Ambiguous with levocardia</b>	1 (5 %)
		<b>Ambiguous with dextrocardia</b>	1 (5 %)
	<b>Atrio-ventricular connection</b>	<b>Concordant</b>	16 (80 %)
		<b>Discordant</b>	4 (20 %)
	<b>Ventriculo-arterial connection</b>	<b>Concordant</b>	0 (0 %)
		<b>Discordant</b>	20 (100)
	<b>RV: size &amp; systolic function</b>	<b>Dilated</b>	15 (75 %)
		<b>Fair (40 - 55%)</b>	5 (25 %)
		<b>Impaired (&lt;40%)</b>	15 (75 %)
	<b>ASD / PFO</b>		8 (40 %)
	<b>VSD</b>		14 (70 %)
	<b>PDA</b>		5 (25 %)
	<b>LV: size &amp; systolic function</b>	<b>Dilated</b>	4 (20 %)
		<b>Hypoplastic</b>	1 (5 %)
		<b>Fair (40 - 55%)</b>	14 (70 %)
<b>Impaired (&lt;40%)</b>		6 (30 %)	
<b>Pulmonary valve</b>	<b>Stenosis</b>	2 (10 %)	
<b>Aortic Coarctation</b>		1 (5 %)	
<b>MPA narrowing</b>		3 (15 %)	

		<b>RPA narrowing</b>	1 (5 %)	
		<b>LPA narrowing</b>	3 (15 %)	
	<b>Mitral valve</b>	<b>Average</b>	19 (95 %)	
		<b>Straddelig</b>	1 (5 %)	
	<b>Aortic arch</b>	<b>Left</b>	18 (90 %)	
		<b>Right</b>	0 (0 %)	
		<b>Couldn't be properly assessed</b>	2 (10 %)	
<b>CT</b>	<b>Situs</b>	<b>Solitus with levocardia</b>	16 (80 %)	
		<b>Solitus with dextrocardia</b>	2 (10 %)	
		<b>ambiguous with levocardia</b>	1 (5 %)	
		<b>ambiguous with dextrocardia</b>	1 (5 %)	
	<b>Atrio-ventricular connection</b>	<b>concordant</b>	16 (80 %)	
		<b>discordant</b>	4 (20 %)	
	<b>Ventriculo-arterial connection</b>	<b>concordant</b>	0 (0 %)	
		<b>discordant</b>	20 (100 %)	
	<b>Right side</b>	<b>Dilated</b>	15 (75 %)	
	<b>Left side</b>	<b>Dilated</b>	4 (20 %)	
		<b>Hypoplastic</b>	1 (5 %)	
		<b>Mitral valve straddeling</b>	1 (5 %)	
		<b>PS</b>	2 (10 %)	
		<b>MPA narrowing</b>	3 (15 %)	
		<b>RPA narrowing</b>	1 (5 %)	
		<b>LPA narrowing</b>	3 (15 %)	
		<b>Coarctation</b>	2 (10 %)	
		<b>ASD</b>	8 (40 %)	
		<b>VSD</b>	14 (70 %)	
		<b>PDA</b>	5 (25 %)	
		<b>Type of TGA</b>	<b>L-TGA</b>	4 (20 %)
			<b>D-TGA</b>	16 (80 %)
		<b>Coronaries (origin)</b>	<b>Reversed origin</b>	12 (60 %)
			<b>Usual origin</b>	4 (20 %)
			<b>Single coronary a. originates from rt posterior facing aortic sinus</b>	1 (5 %)
			<b>Non-interpretable due to cardiac motion artifact</b>	3 (15 %)
		<b>Coronaries (caliber)</b>	<b>Average</b>	19 (95 %)
	<b>Ectatic</b>		1 (5 %)	
	<b>Aortic arch</b>	<b>Left</b>	19 (95 %)	
		<b>Right</b>	1 (5 %)	
<b>ECHO Post (n = 18<sup>#</sup>)</b>	<b>Type of surgery</b>	<b>Arterial switch</b>	13 (72.2 %)	
		<b>Atrial switch</b>	1 (5.5 %)	
		<b>Glenn shunt</b>	4 (22.3 %)	
		<b>RVOT obstruction</b>	1 (5.5 %)	
		<b>LVOT obstruction</b>	2 (11.2 %)	
		<b>Systemic function %</b>	<b>Good systolic (&gt; 60%)</b>	15 (83.3 %)

		<b>Average (55- 60 %)</b>	3 (16.7 %)
	<b>Fractional shortening %</b>	<b>Average (&gt;25%)</b>	15 (83.3 %)
		<b>Abnormal (&lt;25%)</b>	3 (16.7 %)
<b>CT Post (n = 4<sup>#</sup>)</b>	<b>Type of operation</b>	<b>Glenn shunt</b>	4 (100 %)
	<b>Patency of shunt</b>	<b>Patent</b>	3 (75 %)
		<b>Stenotic</b>	1 (25 %)
	<b>Veno-venous connections</b>		1 (25 %)

Data are presented as frequency (%). #: 2 missed cases in ECHO (died), #: Only 4 cases undergone CT post. ASD: Atrial septal defect, VSD: Ventricular septal defects, RV: Right ventricle, LV: Left ventricle, ASD/PFO: Atrial septal defect/ Patent foramen ovale, PS: Pulmonary stenosis, MPA: Main pulmonary artery, RPA: Right pulmonary artery, LPA: Left pulmonary artery, PDA: Patent ductus arteriosus, TGA: Transposition of the great arteries, D-TGA: Dextro-transposition of the great arteries, L-TGA: Congenitally corrected transposition of the great arteries, RVOT: Right ventricle outflow tract, LVOT: left ventricular outflow tract, Echo: Echocardiography, CT: Computed tomography.

SV: Stroke volume, SVI: Stroke volume index, CO: Cardiac output, CI: Cardiac index

Table 3 shows comparison between ECHO and CT according to different parameters

**Table 3: Comparison between ECHO and CT according to different parameters**

		<b>ECHO</b>	<b>CT</b>	<b>MCN p</b>
<b>Situs</b>	<b>Solitus with levocardia</b>	16 (80 %)	16 (80 %)	1.000
	<b>Solitus with dextrocardia</b>	2 (10 %)	2 (10 %)	
	<b>Ambiguous with levocardia</b>	1 (5 %)	1 (5 %)	
	<b>Ambiguous with dextrocardia</b>	1 (5 %)	1 (5 %)	
<b>Atrio-ventricular connection</b>	<b>concordant</b>	16 (80 %)	16 (80 %)	1.000
	<b>discordant</b>	4 (20 %)	4 (20 %)	
<b>Ventriculo-arterial connection</b>	<b>concordant</b>	0 (0 %)	0 (0 %)	1.000
	<b>discordant</b>	20 (100 %)	20 (100 %)	
<b>RV</b>	<b>Average</b>	5 (25 %)	5 (25 %)	1.000
	<b>Dilated</b>	15 (75 %)	15 (75 %)	
<b>LV</b>	<b>Dilated</b>	4 (20 %)	4 (20 %)	1.000
	<b>hypoplastic</b>	1 (5 %)	1 (5 %)	
<b>ASD/PFO</b>		8 (40 %)	8 (40 %)	1.000
<b>VSD</b>		14 (70 %)	14 (70 %)	1.000
<b>PS</b>		2 (10 %)	2 (10 %)	1.000
<b>MPA narrowing</b>		3 (15 %)	3 (15 %)	1.000
<b>RPA narrowing</b>		1 (5 %)	1 (5 %)	1.000
<b>LPA narrowing</b>		3 (15 %)	3 (15 %)	1.000
<b>Coarctation</b>		1 (5 %)	2 (10 %)	1.000
<b>PDA</b>		5 (25 %)	5 (25 %)	1.000
<b>Aortic arch</b>	<b>Left</b>	18 (90 %)	19 (95 %)	1.000
	<b>Right</b>	0 (0 %)	1 (5 %)	

RV: Right ventricle, LV: Left ventricle, ASD/PFO: Atrial septal defect/ Patent foramen ovale, VSD: Ventricular septal defects, PS: pulmonary stenosis, MPA: Main pulmonary artery, RPA: Right pulmonary artery, LPA: Left pulmonary artery, PDA: Patent ductus arteriosus

Table 4 shows findings of TGA cases by MSCT and echo referring to surgical results in 20 cases.

**Table 4: Findings of TGA cases by MSCT and echo referring to surgical results in 20 cases**

		Intervention	ECHO				MSCT			
			True		False		True		False	
			+ve	-ve	+ve	-ve	+ve	-ve	+ve	-ve
<b>Pulmonary stenosis</b>		2	2	18	0	0	2	18	0	0
<b>Mitral valve straddling</b>		1	1	19	0	0	1	19	0	0
<b>Type of TGA</b>	<b>D-TGA</b>	16	16	4	0	0	16	4	0	0
	<b>L-TGA</b>	4	4	16	0	0	4	16	0	0
<b>VSD</b>		14	14	6	0	0	14	6	0	0
<b>ASD</b>		8	8	12	0	0	8	12	0	0
<b>PDA</b>		5	5	15	0	0	5	15	0	0
<b>Aortic coarctation</b>		2	1	18	0	1	2	18	0	0
<b>LV size</b>	<b>Average</b>	15	15	5	0	0	15	5	0	0
	<b>Dilated</b>	4	4	16	0	0	4	16	0	0
	<b>Hypoplastic</b>	1	1	19	0	0	1	19	0	0
<b>RV size</b>	<b>Average</b>	5	5	15	0	0	5	15	0	0
	<b>Dilated</b>	15	15	5	0	0	15	5	0	0
<b>MPA narrowing</b>		2	2	17	1	0	2	17	1	0
<b>RPA narrowing</b>		1	1	19	0	0	1	19	0	0
<b>LPA narrowing</b>		3	3	17	0	0	3	17	0	0
<b>Aortic arch</b>	<b>Left</b>	19	18	1	0	1	19	1	0	0
	<b>Right</b>	1	0	19	0	1	1	19	0	0

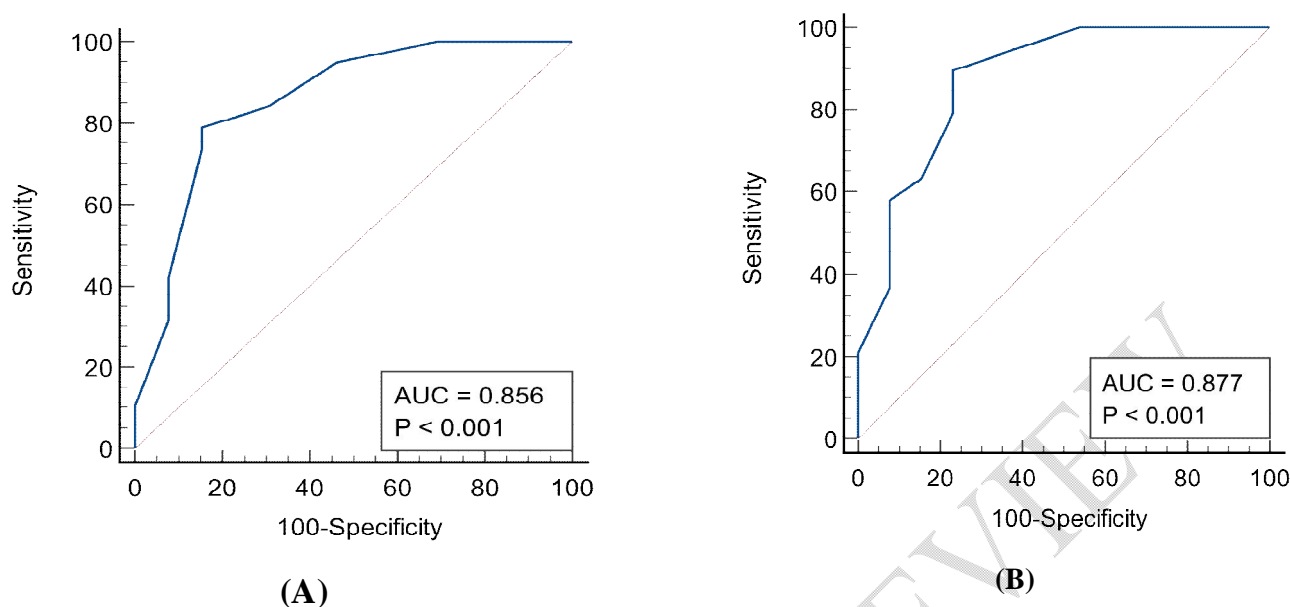
TGA: Transposition of the great arteries, D-TGA: Dextro-transposition of the great arteries, L-TGA: Congenitally corrected transposition of the great arteries, RV: Right ventricle, LV: Left ventricle, ASD: Atrial septal defect, VSD: Ventricular septal defects, PS: pulmonary stenosis, MPA: Main pulmonary artery, RPA: Right pulmonary artery, LPA: Left pulmonary artery, PDA: Patent ductus arteriosus

ECHO can significantly predict TGA (AUC= 0.856, P value <0.001) at cut off  $\leq 6.6$  with 79.95% sensitivity, 84.62% specificity, 88.2% PPV and 73.3% NPV. MSCT can significantly predict TGA (AUC= 0.877, P value <0.001) at cut off  $\leq 0.16$  with 89.47% sensitivity, 76.92% specificity, 85% PPV and 83.3% NPV. By comparing between ECHO and MSCT as predictors at the same time, there was no significant difference between them in early prediction of TGA. Table 5, Figure 1

**Table 5: ROC curve analysis of ECHO and MSCT for early prediction of TGA**

	Cut-off	AUC	Sensitivity	Specificity	PPV	NPV	P value
ECHO	$\leq 6.6$	0.856	78.95	84.62	88.2	73.3	<0.001*
MSCT	$\leq 0.16$	0.877	89.47	76.92	85.0	83.3	<0.001*

\* Significant as p <0.05. Echo: Echocardiography, MSCT: Multi-slice computed tomography.



**Figure 1: (A) ROC curve of ECHO, (B) ROC curve of MSCT for early prediction of TGA**

## Discussion

Multiplanar and three-dimensional (3D) images obtained from MSCT data can illustrate normal and pathologic cardiovascular structures in cases suffering from congenital heart disease <sup>[12]</sup>.

In this study, male patients were more commonly presented with TGA (12, 60%) than female patients (8 females, 40%) with a male to female ratio (3:2), their age ranged from the age of 23 days to 18 years. Similarly, Nievelstein et al. <sup>[13]</sup> reported that their study included 100 patients with males are more common than females (60 males and 40 females) with male to female ratio (3:2) and it the same ratio as in our study.

In this study, the 20 patients who studied for the TGA are divided into 16 cases of D-TGA (80%), and 4 cases of L-TGA (20%).

In the current study, the associated anomalies were subclassified to right & left ventricular anomalies, mitral and pulmonary valve anomalies, pulmonary arteries& aortic anomalies, atrial and VSD and PDA.

In this study, right ventricle was found normal in 5 (25% of cases) patients and dilated in 15 (75% of cases) patients. While Right ventricle was normal in 14 (70%) patients and dilated in 6 (30%) patients. Mitral valve straddling associated with TGA detected by MSCT was in only 1 patient (5%) in the form of straddling of its leaflets. Anomalies of the pulmonary region include pulmonary valve anomaly and pulmonary vascular anomalies; the pulmonary valve anomaly associated with TGA is pulmonary stenosis, while the anomalies of development of MPA, LPA and RPA are mainly narrowing specially at the ostial region causing ostial stenosis.

In this study, MSCT detected pulmonary valve stenosis in only 2 (10% of patients) patients, while MPA stenosis in 3 (15% of patients), RPA stenosis in only one patient (5% of patients), LPA stenosis in 3 (15% of patients), While echo detected same number of abnormal pulmonary cases among all patients. Kappa test revealed a very good agreement between both MSCT and echo in detecting pulmonary region anomalies ( $p=1.000$ ).

Pelberg et al. <sup>[14]</sup>, who studied normally and abnormally related great arteries reported also that the most common main PA anomalies in TGA was the MPA pulmonary stenosis (7 cases, 16%) followed by left PA stenosis, then right PA stenosis.

In this study, MSCT detected ASD in 8 patients (40% of all patients), VSD in 14 patients (70% of all patients). While echo detected same number of patients with septal defects among all patients. Kappa test revealed a very good agreement between both Echo and MSCT in the detection of pulmonary region anomalies ( $p=1.000$ ).

Liu Jet al. <sup>[15]</sup>, who studied the CT angiography image quality using model-based reconstruction in infants suffering from congenital heart disease agreed with our study which revealed exactly the same ratio of cases of TGA associated with VSD reaching 20 cases out of total 25 patients (70%), while approximately same ratio of TGA cases associated with ASD, it stated that 14 cases out of total 25 cases were positive for ASD (50%)<sup>(112)</sup>.

In the present study, MSCT reported PDA in 5 (25%) patients. That came in agreement with ECHO which was able to diagnose those 5 cases.

Similarly, Alam et al.<sup>[16]</sup> study revealed approximately the same ratio of PDA associated with congenital heart diseases like TGA which was 13 cases out of total 60 cases.

In the present study, MSCT reported aortic coarctation in 2 (10%) patients. While Echo detected aortic coarctation in only 1 (5%) patient. Kappa test revealed a good agreement between both echo and MSCT in detecting pulmonary region anomalies.

In the current study, MSCT results correlated with surgery findings or cardiac catheterization, MSCT missed the diagnosis of a case of supravulvular pulmonary stenosis of and it was due to cardiac motion artifact which affected the quality of the examination. Lin et al.<sup>[17]</sup> also missed the diagnosis of a case of pulmonary atresia due to motion artifact.

Tabari et al.<sup>[18]</sup> and Cohen et al.<sup>[19]</sup>, their studies declared that MDCT angiography was particularly useful in assessment of great vessel anomalies.

Bu et al.<sup>[20]</sup> reported that echo missed diagnosis of 2 cases of pulmonary stenosis and they declared that MSCT was better than echo in diagnosis of extracardiac great vessel anomalies.

Also, Liu et al.<sup>[15]</sup> concluded that MDCT also is the most accurate test for diagnosing the great vessel anomalies.

MSCT could diagnose cases of great vessel anomalies with 100% specificity, 100% sensitivity, 100% PPV, 100% NPV and 100% accuracy.

Nie et al.<sup>[21]</sup> and Abd El-Rahman et al.<sup>[22]</sup> mentioned that in all patients the MDCT correctly diagnosed all cases of aorto-pulmonary vascular anomalies (sensitivity 100%, specificity 100%).

Cohen et al.<sup>[19]</sup> that studied guidelines of multimodality imaging for cases with the great arteries' transposition: stated that coronary CT angiography routinely conducted on adolescents and young adults with TGA post-surgical management or catheterization

provides useful and precise information for the postoperative management and selection of high-risk cases.

We traced some of our cases, only four cases could undergo CT postoperatively, all of them had Glenn/ MBT shunt, patency of shunt was patent in 3 (75%) patients and stenotic in 1 (25%) patient. Veno-venous connections were absent in 3 (75%) patients and present in 1 (25%) patient.

In contrast, Hazekamp et al. <sup>[23]</sup> the Society of Thoracic Surgeons congenital heart surgery database: that studied update on quality and outcomes stated that 14 cases (6.5%) out of total 217 cases underwent Glenn shunt, have failed.

Echocardiography could diagnose cases of TGA and associated anomalies with 100% sensitivity, 99.6% specificity, 97.9% PPV, 99.6% NPV and 99.3% accuracy.

MSCT could diagnose cases of TGA and associated anomalies with 96.8% sensitivity, 93.4% specificity, 91.9% PPV, 100% NPV and 99.6% accuracy.

### **Conclusions:**

MSCT can accurately depict the spatial relationship between the great arteries and diagnose the associated anomalies for TGA cases. Combining MSCT and transthoracic echocardiogram can provide an effective and safe alternative imaging modality for preoperative assessment, but for post-operative assessment of surgically operated/ catheterized TGA cases especially those with postoperative complications, MSCT angiography is the method of choice we recommend it.

### **Ethical Approval and Consent:**

The trial was conducted after approval from the Ethical Committee Tanta University Hospitals. Informed written consent was obtained from the relatives of the patients.

**Financial support and sponsorship:** Nil

**Conflict of Interest:** Nil

**References:**

1. Jain S. Congenital heart disease: Saving lives and securing liveliness with early primary care and expert family care. *J Family Med Prim Care*. 2021;10:3178-84.
2. Tutarel O, Kempny A, Alonso-Gonzalez R, Jabbour R, Li W, Uebing A, et al. Congenital heart disease beyond the age of 60: emergence of a new population with high resource utilization, high morbidity, and high mortality. *Eur Heart J*. 2014;35:725-32.
3. Wallis GA, Debich-Spicer D, Anderson RH. Congenitally corrected transposition. *Orphanet J Rare Dis*. 2011;6:22-9.
4. Martins P, Castela E. Transposition of the great arteries. *Orphanet J Rare Dis*. 2008;3:27-34.
5. Hornung TS, Calder L. Congenitally corrected transposition of the great arteries. *Heart*. 2010;96:1154-61.
6. Warnes CA. Transposition of the great arteries. *Circulation*. 2006;114:2699-709.
7. Sharland G, Tingay R, Jones A, Simpson J. Atrioventricular and ventriculoarterial discordance (congenitally corrected transposition of the great arteries): echocardiographic features, associations, and outcome in 34 fetuses. *Heart*. 2005;91:1453-8.
8. Escobar-Diaz MC, Freud LR, Bueno A, Brown DW, Friedman KG, Schidlow D, et al. Prenatal diagnosis of transposition of the great arteries over a 20-year period: improved but imperfect. *Ultrasound Obstet Gynecol*. 2015;45:678-82.
9. Cohen MS, Eidem BW, Cetta F, Fogel MA, Frommelt PC, Ganame J, et al. Multimodality imaging guidelines of patients with transposition of the great arteries. *J Am Soc Echocardiogr*. 2016;29:571-621.
10. Bajolle F, Zaffran S, Kelly RG, Hadchouel J, Bonnet D, Brown NA, et al. Rotation of the myocardial wall of the outflow tract is implicated in the normal positioning of the great arteries. *Circ Res*. 2006;98:421-8.
11. Pelberg R, Mazur W. *Basic Principles in Computed Tomography (CT). Cardiac CT angiography manual*. London: Springer; 2015. p. 19-58.
12. Rashkind WJ, Miller WW. Creation of an atrial septal defect without thoracotomy. A palliative approach to complete transposition of the great arteries. *Jama*. 1966;196:991-2.
13. Nievelstein RA, van Dam IM, van der Molen AJ. Multidetector CT in children: current concepts and dose reduction strategies. *Pediatr Radiol*. 2010;40:1324-44.
14. Pelberg R. *Basic Principles in Computed Tomography (CT). Cardiac CT Angiography Manual*: Springer London; 2015. p. 19-58.
15. Liu J, Li H, Liu Z, Wu Q, Xu Y. Complete Preoperative Evaluation of Pulmonary Atresia with Ventricular Septal Defect with Multi-Detector Computed Tomography. *PLoS One*. 2016;11:14-30.
16. Alam T, Munir MK, Hamidi H. Congenital heart disease frequency in children undergoing MDCT angiography; a 4-year tertiary care hospital experience from Kabul, Afghanistan. *BJR Open*. 2019;1:20-32.

17. Lin MT, Wang JK, Chen YS, Lee WJ, Chiu HH, Chen CA, et al. Detection of pulmonary arterial morphology in tetralogy of Fallot with pulmonary atresia by computed tomography: 12 years of experience. *Eur J Pediatr.* 2012;171:579-86.
18. Tabari A, Lo Gullo R, Murugan V, Otrakji A, Digumarthy S, Kalra M. Recent Advances in Computed Tomographic Technology: Cardiopulmonary Imaging Applications. *J Thorac Imaging.* 2017;32:89-100.
19. Cohen MS, Eidem BW, Cetta F, Fogel MA, Frommelt PC, Ganame J, et al. Multimodality Imaging Guidelines of Patients with Transposition of the Great Arteries: A Report from the American Society of Echocardiography Developed in Collaboration with the Society for Cardiovascular Magnetic Resonance and the Society of Cardiovascular Computed Tomography. *J Am Soc Echocardiogr.* 2016;29:571-621.
20. Bu G, Miao Y, Bin J, Deng S, Liu T, Jiang H, et al. Comparison of 128-Slice Low-Dose Prospective ECG-Gated CT Scanning and Trans-Thoracic Echocardiography for the Diagnosis of Complex Congenital Heart Disease. *PLoS One.* 2016;11:16-22.
21. Nie P, Yang G, Wang X, Duan Y, Xu W, Li H, et al. Application of prospective ECG-gated high-pitch 128-slice dual-source CT angiography in the diagnosis of congenital extracardiac vascular anomalies in infants and children. *PLoS One.* 2014;9:15-9.
22. Abd El-Rahman HM, Hassan TA, Elfawal MM, Hassan BA, Ali AsA, Abdel-Rahman HM. Role of 128 slice MSCT angiography in evaluation of congenital extra-cardiac intra-thoracic vascular anomalies in children. *EJRNM.* 2017;48:581-91.
23. Hazekamp MG, Gomez AA, Koolbergen DR, Hraska V, Metras DR, Mattila IP, et al. Surgery for transposition of the great arteries, ventricular septal defect and left ventricular outflow tract obstruction: European Congenital Heart Surgeons Association multicentre study. *Eur J Cardiothorac Surg.* 2010;38:699-706.