
KLUVER BUCY SYNDROME: An Overview of the Clinical interplay

ABSTRACT

Kluver Bucy Syndrome (KBS) was initially reported by Sanger Brown and Edward Albert Sharpey-Schafer. In 1939, a bilateral temporal lobectomy was conducted on a Rhesus monkey named Aurora. Three weeks after this procedure, Aurora began to exhibit behavioral changes. These behavioral changes exhibited by Aurora were observed and recorded by Paul Clancy Bucy, a neurosurgeon, and Heinrich Kluver, a neuropsychiatrist; these behavioral changes were given the name Kluver-Bucy syndrome. The first human Kluver-Bucy case was diagnosed in 1955 in a 22-year-old male patient.

Kluver-Bucy syndrome (KBS) is a complex neuropsychiatric disease that usually occurs after bilateral damage to the medial temporal lobes. The syndrome is mainly seen in adults, male and female equally. However, although the syndrome can also be seen in children, the symptoms in children are slightly different from how the symptoms manifest in adults. There are a plethora of etiologies and manifestations of KBS, but it most commonly manifests as a triad of hypersexuality, hyperorality, and hyperphagia.

The diagnosis of KBS is primarily centered around the identification of damages to the medial lobe of the brain, using signs and symptoms and imaging studies, and most importantly, Magnetic Resonant Imaging(MRI). It is also essential to rule out and confirm possible differentials and etiologies in the course of the management of KBS. KBS has no known cure, but the various manifestations can be ameliorated with medications like antidepressants and antipsychotics. The prognosis is generally poor for KBS.

Keywords: *Kluver-Bucy syndrome, Dorsomedial temporal lobe (Cortex), Thalamus, Hippocampus, Limbic system/circuit.*

INTRODUCTION

The clinical features of Kluver Bucy Syndrome were earlier reported by Sanger Brown and Edward Albert Sharpey-Schafer, two British experimental neurologists, in 1888. In 1939, a bilateral temporal lobectomy was conducted on a Rhesus monkey named Aurora. Three weeks after this procedure, Aurora began to exhibit behavioral changes. These behavioral changes were observed and recorded by Paul Clancy Bucy, a neurosurgeon, and Heinrich Kluver, a neuropsychiatrist, hence the name Kluver-Bucy syndrome.[1][3][4][15]

Later in the year 1955, the first human Kluver-Bucy case was discovered. Dr. Guiseppe Ore and Dr. Hrayr Terzian recorded this case after a 19-year-old male

patient with a history of seizures exhibited behavioral changes a few weeks following a bilateral temporal lobectomy. [1]The first identified and reported Kluver-Bucy syndrome was seen in a 22-year-old male patient with bilateral temporal damage caused by Herpes Simplex meningoencephalitis by Marlowe et al.[1][2][16]

Kluver-Bucy syndrome (KBS) is a complex neuropsychiatric disease that usually occurs after bilateral damage to the medial temporal lobes. [1][4] The syndrome is mainly seen equally in adults, male and female. However, although the syndrome can also be seen in children, the symptoms in children are slightly different from how the symptoms manifest in adults. [2][3] Kluver Bucy Syndrome (KBS), also called Bilateral Temporal Lobe Disorder, is a complex and rare cerebral neuropsychiatric disease caused by bilateral lesions/damage to the medial temporal lobes (including the amygdala, the ventromedial nucleus, and the hippocampus). [1][4][5][6]

The anatomical basis of KBS is still controversial. It is thought to occur due to irritations in the temporal portions of limbic networks that connect with multiple cortical and subcortical circuits to modulate emotional behavior and affect. [1][7][17] It affects the part of the brain that performs functions such as facilitating the formation of new memories, storing old memories, processing emotions and sensory information, and regulating sexual and food behaviors. A patient with KBS would present with symptoms that would display a lack of function of a healthy temporal lobe. [2] While KBS is always thought to follow bilateral malfunction of the temporal lobes, the uncus, amygdala, orbitofrontal, hippocampus, cingulate gyri, and insular cortex have a great role in its pathogenesis. [8]

The complete syndrome is usually reduced in humans because humans have less severe anterior temporal lobe dysfunction than monkeys following total temporal lobe resection.[7][17]

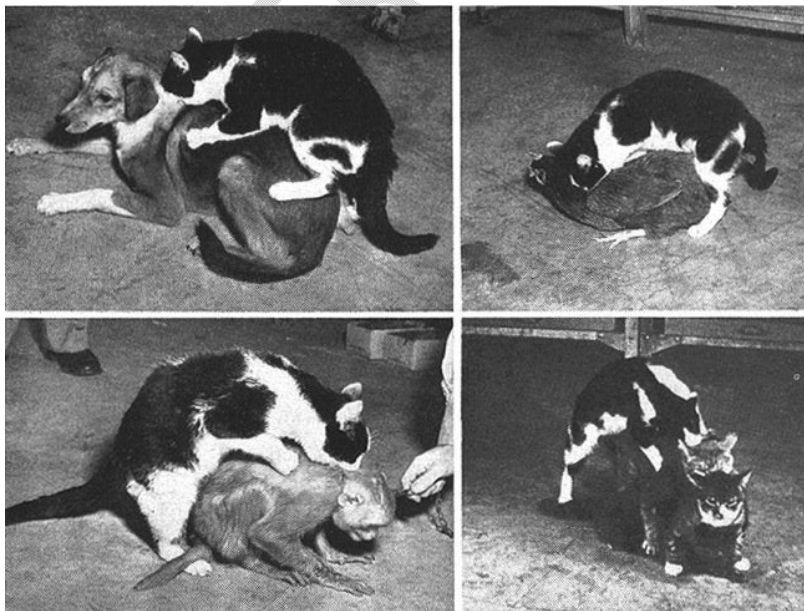


FIG 1: Showing animals (cat) with bilateral damaged to the temporal lobes (KBS)

Source: <https://www.bing.com/images/search>

CLINICAL MANIFESTATIONS

The symptoms of KBS include hypersexuality, dementia, placidity, amnesia, visual agnosia, bulimia nervosa, seizures, pica, hyper-metamorphosis, hyperorality, compulsive smoking/drinking alcohol, and reduced emotional affect. [1][9][11][12]

Patients may present with aggressiveness/rage instead of placidity. This occurs when the ventromedial nucleus of the thalamus and amygdala is affected. [9][10][13][14][20] Most patients do not present with all symptoms. Those with 3-5 symptoms typical of KBS may be described as having partial KBS. [1][6]

Hypersexuality, an Inappropriate sexual behaviour may be seen. There are recorded cases where some KBS patients (adults) were involved with abnormal sexual behaviors. These behaviors were harmful to oneself and others, socially unacceptable, and sometimes legally wrong (sexual perversion). [14] In children, this may be characterized by rubbing genitals on the bed while lying prone, constant touching of genitals, and frequent pelvic thrusting movements when not engaged in an activity. [3][15] A permanent "hypersexuality" is produced by bilateral lesions of the lateral amygdaloid nucleus. Temporal lobe seizures may produce a transient state.

Dementia is seen in some patients with KBS with significant impairment of cognitive function. [7][15][16]. Placidity (complacency) is another manifestation in KBS, which is an aberrant state of peace (flat affect) or can be described as a significantly reduced response to emotional stimuli such as fear or joy. [2] Impaired ability to recall memories (Amnesia) could be retrograde or anterograde in KBS [5] [15] [16]

Visual Agnosia (Psychic vision), an impaired ability to identify/recognize a familiar person, place, or object without losing their sense of sight. Visual agnosia results from bilateral ventral temporal ablations and temporal lobectomies. [8][11] Other manifestations are;

- *Binge eating and purging (Bulimia Nervosa). [9]*
- *Unplanned/unexpected involuntary disturbances of the brain's electrical activities (Seizures). [10]*
- *An irresistible desire to consume things/substances that are generally not considered food (Pica). [11]*
- *Tendency to notice, react and attend to every visual stimulus (Hyper-metamorphosis). [3]*
- *An irresistible urge to examine objects (both inedible and edible) by tongue or mouth (Hyperorality). [3][15]*
- *Reduced emotional affect and lack of emotional expression, even to friends and family. [1][15]*

KBS symptoms in children

KBS in children usually occurs following Herpes Simplex encephalopathy, with classic features occurring only in a few patients. [5] These features are marked indifference, bulimia and hyperorality, lack of emotional attachment toward the family

and the frequent holding of genitals, Intermittent pelvic thrusts, and rubbing of genitals to the bed while lying prone(Hypersexuality).[17]

ETIOPATHOGENESIS

Theories Regarding etiopathogenesis of KBS

- 1) Norman Geschwind's theory: Disruption of visual input to the limbic circuit leads to disconnection syndrome(KBS).[18]
- 2) Muller theory: Disconnection of the pathways connecting the dorsomedial thalamus with the prefrontal cortex and other limbic areas leads to KBS.[19]

The most acceptable hypothesis and theory of the pathophysiology of KBS is bilateral damage or lesions in medial temporal lobe or the Ammon horn, the involvement of amygdala, uncus, hippocampus, orbitofrontal and cingulate gyri are likewise important. [4][6][9][15] Listed below are possible documented categorized conditions associated with KBS. [1] [3] [7] [20] [21] [28]

1. CNS insults: Temporal lobectomy, Traumatic brain injury, subdural hygroma, Non-Hodgkin's lymphoma, Epilepsy, Heat stroke, Stroke (temporal lobe infarction - usually bilateral) and Cerebrovascular diseases.
2. Immunological disorders: Susac syndrome and Systemic Lupus Erythematosus (SLE).
3. Substance abuse: Methamphetamine withdrawal, Cocaine and Exposure to cannabis.
4. Neurodegenerative diseases: Parkinson disease, Huntington disease, Alzheimer's disease and Frontotemporal Dementia (Pick's disease).
5. CNS infections: Herpes Simplex Encephalitis in children, Whipple disease, Shigellosis, Listeriosis, Tuberculosis, Toxoplasmosis Syphilis and possibly other Herpes family.
6. Others: Carbon monoxide poisoning, Porphyria and Hypoglycemia.

Head injury and stroke (Cerebrovascular accident) is the most common cause of KBS in adults, while herpes simplex encephalitis is remains the common in children. [5]

DIAGNOSIS

Diagnosis of KBS is usually made after taking the patient's history, physical exam, blood work/toxicology/culture, total blood count, viral PCR , blood sugar, and imaging studies such as computed tomography (CT) scan, magnetic resonance imaging (MRI) scan, or electroencephalogram (EEG). [21] These tests are done to identify possible etiologic factors and rule out other differential diagnoses such as Autism, Alzheimer's disease, Korsakoff syndrome, Russell's syndrome, Bipolar disorder, Frontal lobe disease, Kleine-Levin syndrome, Prader-willi syndrome, and Pick's disease. [2]

Magnetic resonance imaging of the brain is useful in identifying the extent of temporal lobe damage. An electroencephalogram is useful to identify seizures originating especially from the temporal lobe. In head injury and other conditions producing a long duration of loss of consciousness. Consciousness is staged appropriately with the Modified Innsbruck remission Scale, which includes the Kluver Bucy phase. [21][28]

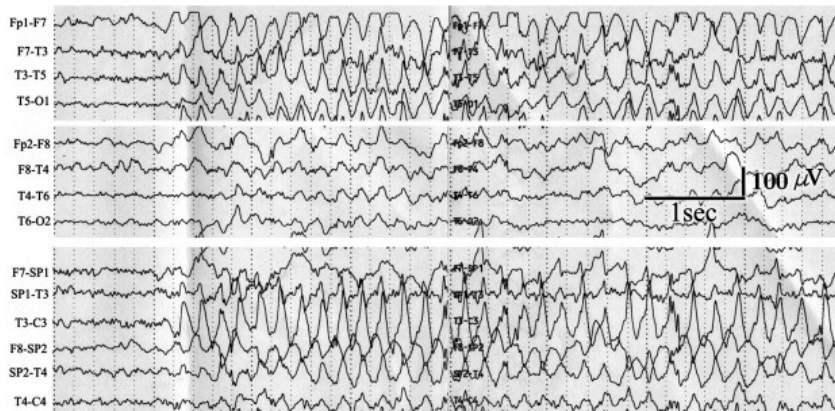


Fig 2: Abnormal electroencephalogram (EEG) in epileptic patient with transient KBS.

Source: <https://els-jbs-prod-cdn.jbs.elsevierhealth.com>

DIFFERENTIAL DIAGNOSIS

KBS may have clinical manifestations similar to a lot of other neuropsychiatric disorders. Few of them are itemized below;

- i. Bipolar disease: It is a neuropsychiatric disorder characterized by depression and mania/hypomania lasting for few weeks. It is a result of damage or dysfunction of the ventral system (amygdala) and dorsal system (hippocampus). [22]
- ii. Kleine-Levin syndrome (Familial hibernation syndrome): This is a very rare disorder usually of unknown cause with similar manifestations due to damage to the medial temporal region of the thalamus and frontal lobe. It is typically characterized by periodic and prolonged sleep (hypersomnia), apathy, hyperphagia, derealization, hypersexuality, confusion and some other features seen in KBS. Most investigations like brain MRI/CT scan, CNS hormonal profile, CSF analysis and acute phase reactant (c-Reactive protein) are normal, only SPECT may show hypoperfusion of the affected frontotemporal area. [23][24]
- iii. Frontal lobe syndromes: These are a spectrum of disorders characterized by damage to the frontal lobe from cancers (Foster Kennedy syndrome), alcohol (Fetal Alcohol Spectrum Disorder), and Frontal abulic syndrome (Akinetic mutism). [25] These patients usually present with emotional liabilities similarly those patients with KBS, loss of executive functions, behavioral disorders, movement and language signs abnormalities. [25]
- iv. Tumor or dysfunction of the diencephalic-hypothalamic axis (Russell's syndrome): A rare condition characterized by abnormal appetite usually seen in children. Other features seen are hydrocephalus, hypoglycemia, developmental delay and pallor without anemia. There are documented associations with central nervous system neoplasms (Gliomas and astrocytoma). [26]
- v. Others possible differentials are *Autism, Alzheimer's disease, Korsakoff syndrome, Russell's syndrome, Prader-willi syndrome, and Pick's disease (Fronto-temporal dementia)*. [2][9][15]

TREATMENT

There is no cure for KBS. The treatment options available function in helping to manage the disease and promote a more comfortable life for the patient, these treatment options include, antiseizure drugs/Mood stabilizers, antidepressants, beta-blockers(Propranolol) and antiviral medications.[1][27] Trial of hormonal therapy like Leuprolide may be useful in some cases [1,2]

Carbamazepine and leuprolide are used to lower hypersexuality, while haloperidol and anticholinergics help manage behavioral abnormalities associated with KBS. [27] Carbamazepine has proven beneficial in patients with KBS secondary to traumatic brain injury. [28]

PROGNOSIS

There is currently no documentation of a specific course of progression in patients presenting with KBS, as the disease varies with each case. However, it has been noted that KBS secondary to traumatic brain injuries, infections and epilepsy has a much better prognosis than KBS secondary to all other risk factors. Also, the damage to the temporal lobe could sometimes be reversed if the appropriate treatment is started early. [1][28]

Lastly, it is essential to note that although KBS does not lead to death, it can considerably reduce the patient's quality of life and community. [1] Complications can result from some of the features, such as hyperorality which can expose the patient to dangerous substances, and hypersexuality can expose the patient to criminal charges.

CONCLUSION

In conclusion, Kluver Bucy syndrome is a rare cerebral neurological disorder associated with damage to both temporal lobes resulting in abnormalities in memory, social and sexual functioning, and idiosyncratic behaviors. It was first discovered by Dr. Paul Clancy Bucy and Dr. Heinrich Kluver in 1939. The diagnosis of KBS is mainly clinical. Once diagnosed, proper evaluation to determine the underlying pathology will be helpful in the overall management. Such evaluation includes MRI, EEG, and CT scans. The clinical course of the disease varies among the case reports. The exact prevalence of human KBS is difficult to estimate due to the restriction to case series and reports. [1][27][28]

Because there is no specific treatment for the condition, the treatment of KBS can be challenging, and the clinical course will vary from patient to patient. Most of the treatment focuses on managing the symptoms. Carbamazepine and leuprolide reduce sexual behavioral abnormality, whereas haloperidol and anticholinergics help treat behavioral abnormalities associated with KBS. Carbamazepine has improved outcomes in patients with KBS secondary to traumatic brain injury. [9][27]

Unfortunately, the outcomes for these patients are poor. They often require physical restraints, and medications to suppress abnormal behavior are needed. Many end up in psychiatric institutions, where they remain for life.

KBS is not a life-threatening condition, but it can profoundly affect the patient's quality of life and carers to a great extent. Any behavioral change following lesions of temporal lobes should be watched with suspicion for the development of KBS. More research is needed into the

pathophysiology of the symptoms of KBS and pharmacological and nonpharmacological management methods. [1]

REFERENCES

- [1] M Das J, Siddiqui W. Kluver Bucy Syndrome. [Updated 2022 July 20]. In: StatPearls [Internet]. Treasure Island (FL): StatPearls Publishing; 2022 Jan-. Available from: <https://www.ncbi.nlm.nih.gov/>
- [2] Kar SK, Das A, Pandey S, Gupta B. Kluver-Bucy Syndrome in an Adolescent Girl: A Sequel of Encephalitis. *J Pediatr Neurosci*. 2018 Oct-Dec; 13(4):523-524
- [3] Jha KK, Singh SK, Kumar P, Arora CD. Partial Kluver-Bucy syndrome secondary to tubercular meningitis. *BMJ Case Rep*. 2016; 2016:bcr2016215926. Published 2016 Aug 16. doi: 10.1136/bcr-2016-215926
- [4] "Klüver-Bucy Syndrome." *NORD (National Organization for Rare Disorders)*, 8 May 2018, rarediseases.org/rare-diseases/kluver-bucy-syndrome/
<https://rarediseases.org/rare-diseases/kluver-bucy-syndrome/>
- [5] Afifi A, Bergman R. *Functional Neuroanatomy*. McGraw-Hill. The Kluver-Bucy syndrome is a clinical syndrome observed in humans and other animals after bilateral lesions in the temporal lobe that involve the amygdala, hippocampal formation, and adjacent neural structures, 1998.
- [6] Al-Attas, A.A., Aldayel, A.Y., Aloufi, T.H. *et al*. Klüver–Bucy syndrome secondary to a non-dominant middle cerebral artery ischemic stroke: a case report and review of the literature. *J Med Case Reports* **15**, 346 (2021). <https://doi.org/10.1186/s13256-021-02932-0>
- [7] Kile SJ, Ellis WG, Olichney JM, Farias S, DeCarli C. Alzheimer abnormalities of the amygdala with Klüver-Bucy syndrome symptoms: an amygdaloid variant of Alzheimer disease. *Arch Neurol*. 2009 Jan; 66(1):125-9.
- [8] Ridley RM, Warner KA, Maclean CJ, Gaffan D, Baker HF. Visual agnosia and Klüver-Bucy syndrome in marmosets (*Callithrix jacchus*) following ablation of inferotemporal cortex, with additional mnemonic effects of immunotoxic lesions of cholinergic projections to medial temporal areas. *Brain Res*. 2001 Apr 13;898(1):136-51. doi: 10.1016/s0006-8993(01)02187-4. PMID: 11292457.
- [9] Cohen MJ, Park YD, Kim H, Pillai JJ. Long-term neuropsychological follow-up of a child with Klüver-Bucy syndrome. *Epilepsy Behav*. 2010 Dec;19(4):643-6. doi: 10.1016/j.yebeh.2010.09.003. PMID: 20926352.
- [10] Naito K, Hashimoto T, Ikeda S. Klüver-Bucy syndrome following status epilepticus associated with hepatic encephalopathy. *Epilepsy Behav*. 2008; 12(2):337-339. doi:10.1016/j.yebeh.2007.09.017
- [11] Salloway SP, Malloy PF, Cummings JL. editors. *The Neuropsychiatry of Limbic and Subcortical Disorders*. Washington, DC: American Psychiatric Press; 1997. p. 125-6
- [12] Kumar Kar S, Jaiswal A, Kumar Panda A. A case report of partial Kluver-Bucy syndrome with anterior opercular syndrome in childhood: a sequel of limbic encephalitis. *Journal of Indian Association for Child and Adolescent Mental Health*. 2013 Jul;9(3):80-8.
- [13] Rajmohan V, Mohandas E. The limbic system. *Indian J Psychiatry*. 2007 Apr;49(2):132-9. doi: 10.4103/0019-5545.33264. PMID: 20711399; PMCID: PMC2917081.

- [14. Mendez MF, Chow T, Ringman J, Twitchell G, Hinkin CH. Pedophilia and temporal lobe disturbances. *J Neuropsychiatry Clin Neurosci*. 2000 winter; 12(1):71-6. doi: 10.1176/jnp.12.1.71. PMID: 10678516.
- [15] Vannemreddy PSSV, Stone JL. Sanger Brown and Edward Schäfer before Heinrich Klüver and Paul Bucy: their observations on bilateral temporal lobe ablations. *Neurosurg Focus*. 2017 Sep; 43(3): E2.
- [16] Marlowe WB, Mancall EL, Thomas JJ. Complete Klüver-Bucy syndrome in man. *Cortex*. 1975 Mar; 11(1):53-9.
- [17] Lanska DJ. The Klüver-Bucy Syndrome. *Front Neurol Neurosci*. 2018; 41:77-89
- [18] Geschwind N. Disconnexion syndromes in animals and man: Part I. 1965. *Neuropsychol Rev*. 2010 Jun; 20(2):128-57
- [19] Müller A, Baumgartner RW, Röhrenbach C, Regard M. Persistent Klüver-Bucy syndrome after bilateral thalamic infarction. *Neuropsychiatry Neuropsychol Behav Neurol*. 1999 Apr; 12(2):136-9.
- [20] Adolphs R, Tranel D, Damasio H, Damasio AR. Fear and the human amygdala. *J Neurosci*. 1995 Sep;15(9):5879-91. doi: 10.1523/JNEUROSCI.15-09-05879.1995. PMID: 7666173; PMCID: PMC6577662.
- [21] von Wild K, Laureys ST, Gerstenbrand F, Dolce G, Onose G. The vegetative state--a syndrome in search of a name. *J Med Life*. 2012 February 22; 5(1):3-15.
- [22] Chen CH, Suckling J, Lennox BR, Ooi C, Bullmore ET. A quantitative meta-analysis of fMRI studies in bipolar disorder. *Bipolar Disord*. 2011; 13(1):1-15. doi:10.1111/j.1399-5618.2011.00893.x
- [23]. Arnulf I, Rico TJ, Mignot E. Diagnosis, disease course, and management of patients with Kleine-Levin syndrome. *Lancet Neurol*. 2012; 11(10):918-928. Doi:10.1016/S1474-4422(12)70187-4]
- [24][Yu-Shu Huang, MD, Christian Guilleminault, MD, Biol D, Kuang-Lin Lin, MD, Fang-Ming Hwang, PhD, Feng-Yuan Liu, MD, Yen-Ping Kung, MD, Relationship between Kleine-Levin Syndrome and Upper Respiratory Infection in Taiwan, *Sleep*, Volume 35, Issue 1, 1 January 2012, Pages 123–129, <https://doi.org/10.5665/sleep.1600>]
- [25] Ozdemir H, Rezaki M. Beyin Damar Hastalığı Sonrası Gelişen Frontal Belirtiler ve Klüver-Bucy Benzeri Sendrom [Klüver-Bucy-like syndrome and frontal symptoms following cerebrovascular disease]. *Turk Psikiyatri Derg*. 2007 Summer;18(2):184-8. Turkish. PMID: 17566885.
- [26]. Kim A, Moon JS, Yang HR, Chang JY, Ko JS, Seo JK. Diencephalic syndrome: a frequently neglected cause of failure to thrive in infants. *Korean J Pediatr*. 2015; 58(1):28-32. doi:10.3345/kjp.2015.58.1.28
- [27] Hooshmand H, Sepdham T, Vries JK. Klüver-Bucy syndrome. Successful treatment with carbamazepine. *JAMA*. 1974 Sep 23; 229(13):1782.
- [28] Clay et al. Klüver-Bucy Syndrome Following Traumatic Brain Injury: A Systematic Synthesis and Review of Pharmacological Treatment From Cases in Adolescents and Adults. *J Neuropsychiatry Clin. Neurosci*. 2019 winter; 31(1):6-16.

UNDER PEER REVIEW