

# Extensive Foveoschisis in an Emmetropic Patient Associated with Vitreomacular Traction: A Case Report

## ABSTRACT

**Aims:** To report a rare case of foveoschisis caused by vitreomacular traction in a young emmetropic female patient.

**Presentation of the case:** A 37-year-old woman, without any systemic or ocular disorders, presented with progressively reduced visual acuity in her right eye over the last 3 months. Best-corrected visual acuity (BCVA) was counting fingers in the right eye and 10/10 in the left eye. Optical coherence tomography revealed foveoschisis with foveal detachment in her right eye, which was successfully treated with pars plana vitrectomy without internal limiting membrane peeling and gas tamponade. Three months post-operatively the BCVA improved to 5/10

**Discussion and Conclusion:** Although high myopia is the main cause of foveoschisis, vitreomacular traction can rarely be associated with foveoschisis, specially in young patients without myopia or any other ocular history. In these cases pars plana vitrectomy with extensive posterior vitreous detachment induction may have favorable visual outcomes.

*Keywords: foveoschisis; vitreomacular traction; retina; vitreoretinal surgery*

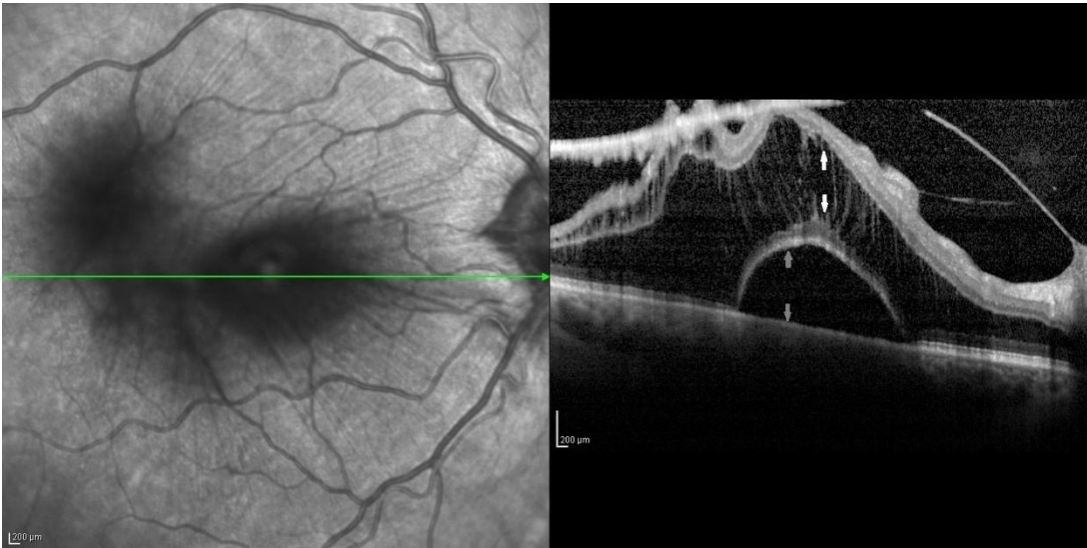
## 1. INTRODUCTION

Foveoschisis is a rare cause of vision loss in adults which has been mainly associated with high myopia [1]. It represents a splitting of the inner retinal layers at the fovea, due to the progressive scleral ectasia and constitutes one of several complications of high myopia. Myopic foveoschisis can be isolated or, more often, accompanied by other macular abnormalities, namely foveal detachment, lamellar or full-thickness macular hole, retinal microfolds, and photoreceptor defects at the inner and outer segment junction [2].

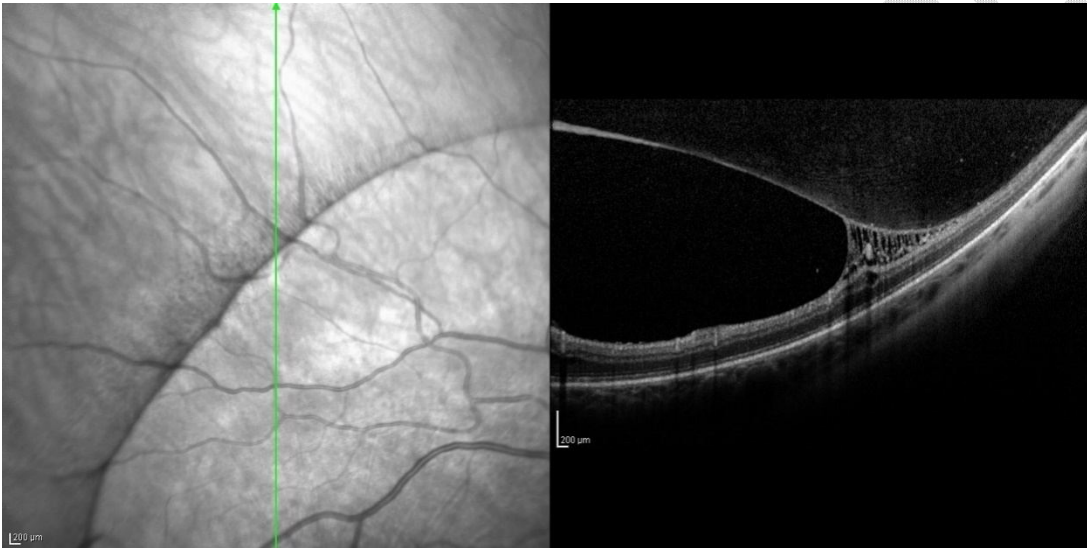
Despite the strong association of foveoschisis with myopia, case reports of emmetropic patients with foveoschisis have been reported in the literature, mainly associated with X-linked genetic mutations and epiretinal membrane [3, 4]. Although in these cases the pathogenetic mechanism of retinal splitting may differ from that of myopic foveoschisis, the visual outcomes are similar, with patients reporting gradual worsening of vision, with their visual acuity usually ranging from 20/25 to counting fingers. We herein report a rare case of extensive foveoschisis in an emmetropic patient without any additional ocular disorders, caused by isolated severe vitreomacular traction (VMT).

## 2. PRESENTATION OF CASE

A 37-year-old female patient was referred to our tertiary vitreoretinal department (Vitreoretinal Unit, First Department of Ophthalmology, General Hospital "G. Gennimatas", Athens, Greece), with progressive worsening of visual acuity in her right eye over the last 3 months. Her past medical, family and ocular history were unremarkable, while her best-corrected visual acuity (BCVA) was 10/10 in both eyes at her last ophthalmological examination 1 year ago.

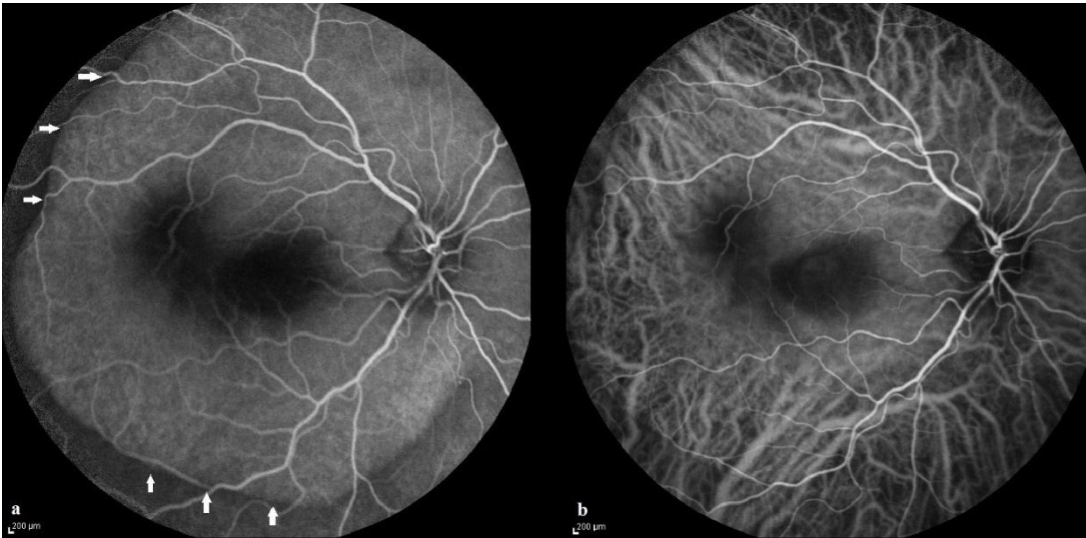

**Fig. 1. Optical coherence tomography demonstrating the foveoschisis (white arrows) and the foveal detachment (grey arrows)**



**Fig. 2. Optical coherence tomography demonstrating multiple vitreous layers (vitreoschisis) exerting traction onto the inner retinal layers**

Upon pre-station in our department, Snellen BCVA was counting fingers in the right eye and 10/10 in the left eye. Intraocular pressure (IOP) was 12mmHg and 14mmHg in her right and left eye, respectively. Slit-lamp biomicroscopy was unremarkable regarding the anterior segment and fundus examination revealed a thickened taut posterior hyaloid over the foveal area, as well as a round elevated posterior pole. Examination of the peripheral retina was within normal limits. Optical coherence tomography (OCT) (Heidelberg Spectralis, Heidelberg Engineering, Heidelberg, Germany) showed foveoschisis with foveal detachment (Fig. 1) and multiple vitreous layers (vitreoschisis) exerting traction onto the inner retinal layers (Fig. 2). Moreover, a computer tomography scan was performed, which was normal, as well as, fluorescein and indocyanine green angiography in order to exclude exudative, degenerative or inflammatory causes (Fig. 3). The diagnosis of foveoschisis due to severe VMT was made and we decided to proceed with 25-gauge 3-port pars plana vitrectomy with extensive posterior vitreous detachment induction without internal limiting membrane (ILM) peeling and gas tamponade. The patient agreed with our treatment plan and written informed consent was obtained from her.



**Fig. 3. Fluorescein angiography (a) and indocyanine green (b) of the right eye. Absence of leakage on both examinations. FA also highlights the presence of the traction (white arrows)**

In the first post-operative day BCVA in her right eye was 1/10 and the intraocular pressure was normal. Anterior chamber was deep and quiet and the retina was flat. Three months post-operatively the BCVA improved to 5/10 and the retina remained flat. OCT imaging showed no separation between the inner and outer layers of the retina.

### 3. DISCUSSION

To the best of our knowledge, a case of such extensive foveoschisis as a result of VMT has not been previously reported in the literature. Due to the relatively high heterogeneity in the clinical presentation of retinoschisis, it remains a challenging clinical entity, where its differential diagnosis should include several ocular diseases like myopic foveoschisis, optic disc pit maculopathy, X-linked retinoschisis and central serous chorioretinopathy [1]. However, during the last decade, the advances in ophthalmic imaging, namely OCT, in combination with detailed history taking and clinical examination have significantly helped in the accurate diagnosis of foveoschisis [5].

In our case, the use of OCT was critical in the diagnosis of foveoschisis. The limited contrast of the areas of chorioretinal atrophy poses a challenging clinical diagnosis, exceptionally in highly myopic eyes [5]. Histological and OCT-based studies have shown an association between foveoschisis and retinoschisis at multiple retinal levels, that is the outer and inner plexiform, the ganglion cells, and the nerve fiber layers [6]. The pathogenesis of foveoschisis seems to be multifactorial and yet remains largely unknown. It has been postulated that it could be a result of the greater flexibility of outer retina compared to inner retina [7]. The posterior vitreous adhering to the retina, the epiretinal membrane, the ILM, and the retinal vessels are recognized as areas that limit such flexibility. In high myopia, a deep posterior staphyloma generates a larger vector component from the tangential traction of epiretinal membrane and ILM, which acts on the retina as an inward tractional force that celebrates the inner from the outer retinal layers. In our case, however, none of the above mention pathogenetic mechanisms was relevant, and foveoschisis was possibly developed due to isolated extensive VMT. More studies are necessary to elucidate the possible mechanism of traction caused by the taut vitreomacular adhesion and the separation of the retinal layers.

There are numerous complications associated with foveoschisis including full thickness macular hole, foveal and retinal detachment, which are frequently associated with poor visual prognosis [1]. Moreover, in young patients without significant medical or ophthalmic history presenting with foveoschisis and VMT, additional examinations should be performed in order to exclude secondary causes of VMT such as uveitis. The gold standard treatment of symptomatic foveoschisis is a 3-port pars plana vitrectomy with posterior vitreous detachment induction, staining of the ILM with brilliant blue, ILM peeling and gas tamponade, especially in cases with myopic foveoschisis [8]. Although our case developed idiopathic extensive VMT without high myopia (axial length = 22.73mm), it was treated in a similar manner as a myopic foveoschisis.

## 4. CONCLUSION

Despite foveoschisis being strongly associated with high myopia, it can rarely result from isolated VMT traction. The exact pathogenetic mechanism of this entity is not clearly understood, however, pars plana vitrectomy with extensive posterior vitreous detachment induction can have favorable visual outcomes.

## CONSENT

All authors declare that 'written informed consent was obtained from the patient for publication of this case report and accompanying images. A copy of the written consent is available for review by the Editorial office/Chief Editor/Editorial Board members of this journal.

## ETHICAL APPROVAL (WHERE EVER APPLICABLE)

As per international standard or university standard written ethical approval has been collected and preserved by the authors.

## REFERENCES

1. Gohil R, Sivaprasad S, Han LT, Mathew R, Kioussis G, Yang Y. Myopic foveoschisis: a clinical review. *Eye (Lond)*. 2015;29(5):593-601.
2. Cho BJ, Shin JY, Yu HG. Complications of Pathologic Myopia. *Eye Contact Lens*. 2016;42(1):9-15.
3. Molday RS, Kellner U, Weber BHF. X-linked juvenile retinoschisis: clinical diagnosis, genetic analysis, and molecular mechanisms. *Prog Retin Eye Res*. 2012;31(3):195-212.
4. Vogt D, Stefanov S, Guenther SR, Hagenau F, Wolf A, Priglinger SG, et al. Comparison of Vitreomacular Interface Changes in Myopic Foveoschisis and Idiopathic Epiretinal Membrane Foveoschisis. *Am J Ophthalmol*. 2020;217:152-61.
5. Sayanagi K, Morimoto Y, Ikuno Y, Tano Y. Spectral-domain optical coherence tomographic findings in myopic foveoschisis. *Retina*. 2010;30(4):623-8.
6. Tang J, Rivers MB, Moshfeghi AA, Flynn HW, Chan CC. Pathology of macular foveoschisis associated with degenerative myopia. *J Ophthalmol*. 2010;2010.
7. Ikuno Y. Current concepts and cutting-edge techniques in myopic macular surgeries. *Taiwan Journal of Ophthalmology*. 2014;4(4):147-51.
8. Yun L-N, Xing Y-Q. Long-term outcome of highly myopic foveoschisis treated by vitrectomy with or without gas tamponade. *International journal of ophthalmology*. 2017;10(9):1392-5.