

## Case report

# Rare Presentation of Disseminated Tuberculosis in the Present Era of Modern Tuberculosis Management

Abstract

---

**Background:** Disseminated tuberculosis (TB) is defined as two or more noncontiguous sites resulting from lymphohematogenous dissemination of *Mycobacterium tuberculosis*. In an immunocompetent host, it is uncommon. The presentation varies, and non-specific early infection symptoms can be noted on chest radiography. Early medication beginning is linked to significantly better outcomes in cases of disseminated tuberculosis. The current case report describes the series of incidents that resulted from a 50-year-old man's excessive usage of the corticosteroid medication tablet Betamethasone, which he was taking for a cough and cold related to his chronic obstructive pulmonary disease (COPD).

**Case Presentation:** A 50-year-old Indian male patient with osteoporosis, drug-induced adrenal insufficiency, and bilateral pleural effusion who is receiving anti-tuberculosis therapy which he is on now is presented to the outpatient department of a tertiary hospital with complaints of fever associated with shivering on & off for 4 months, generalized tiredness. He had a history of loose stools for 2-3 days, small joint pain, left knee joint pain and swelling, loss of weight, and loss of appetite.

**Conclusion:** The right diagnosis, treatment, patient counseling, diet, and family support helped him recover despite his turbulent recovery phase. As far as steroid therapy is concerned, it is a double-edged sword, meaning that taking over-the-counter steroid drugs without first seeking adequate medical advice could have serious negative effects.

**Keywords:** Disseminated tuberculosis, Adrenal insufficiency, Corticosteroid, Betamethasone

## 1. INTRODUCTION

A progressive, potentially fatal condition known as "Disseminated tuberculosis" is caused by the lymphohematogenous spread of the "*Mycobacterium tuberculosis*" bacilli as a result of either primary dissemination or development from years of untreated tuberculosis [1]. A typical finding that is crucial for the early diagnosis of the disease is the miliary pattern on chest radiography. Although the precise global incidence of disseminated tuberculosis is yet unknown, in immunocompetent people, it is believed to represent 2% of all tuberculosis cases and up to 20% of cases of extrapulmonary tuberculosis [2]. Patients with risk factors such as HIV immunodeficiency, chronic immunosuppressive medication usage, poorly managed diabetes, hematologic conditions, and alcohol addiction are more likely to have dissemination.[3]. Fever, weight loss, anorexia, anemia, pancytopenia, hepatosplenomegaly,

and raised inflammatory markers including the erythrocyte sedimentation rate (ESR) are all possible clinical characteristics[4]. It is believed that 5.4% of tuberculosis patients will acquire disseminated tuberculosis, making it a rare occurrence with the potential to increase mortality in tuberculosis patients. To reduce morbidity and mortality in the case of disseminated tuberculosis, it's critical to focus on the promptness and accuracy of the diagnosis.[5] The therapy is the same for pulmonary tuberculosis, however disseminated TB typically requires a longer course of antibiotics. The entire infection may need to be treated for 6 to 12 months.[6]

## 2. CASE PRESENTATION

A 50-year-old Indian male patient with osteoporosis, drug-induced adrenal insufficiency, and bilateral pleural effusion receiving anti-tuberculosis therapy, which he is on, was presented to the outpatient department of a tertiary hospital with complaints of fever associated with fever shivering on and off for four months, generalized tiredness. He had a history of loose stools for 2-3 days, minor joint pain, left knee joint pain and swelling, loss of weight, and loss of appetite. In the past, the patient experienced generalized body swelling. After being examined in a local hospital, fluid retention due to drug-induced adrenal insufficiency was determined to be the cause and there was osteoporosis as well. He has a family history of tuberculosis; his daughter suffered from abdominal tuberculosis, while his father had pulmonary tuberculosis. On examination, he was conscious, oriented, and febrile. His vitals showed, oxygen saturation: 95% on room air, Blood pressure: 130/70mmHg, in the right upper lobe in the supine position, Respiratory rate: 25/minute, Pulse rate: 100/minute, rhythm-regular and Temperature: 100.7F. The respiratory system displayed reduced breath sound intensity in both basal segments and the presence of bibasilar crepitations.

After using tablet Betamethasone for a cough and cold in the past, the patient experienced drug-induced secondary adrenal insufficiency. It was administered for Chronic Obstructive Pulmonary Disease (COPD), which resulted in decreased blood pressure, steroid toxicity, and immunosuppression, and was accompanied by Disseminated Tuberculosis.

### Hospital course:

#### ***On hospital day 1,***

Blood Picture revealed Microcytic hypochromic with mild anisopoikilocytosis. The patient was treated with Anti-Tuberculosis therapy, IV Antibiotics, IV Proton pump inhibitors, aerosolized bronchodilators, and all other supportive measures, along with nutrient supplements.

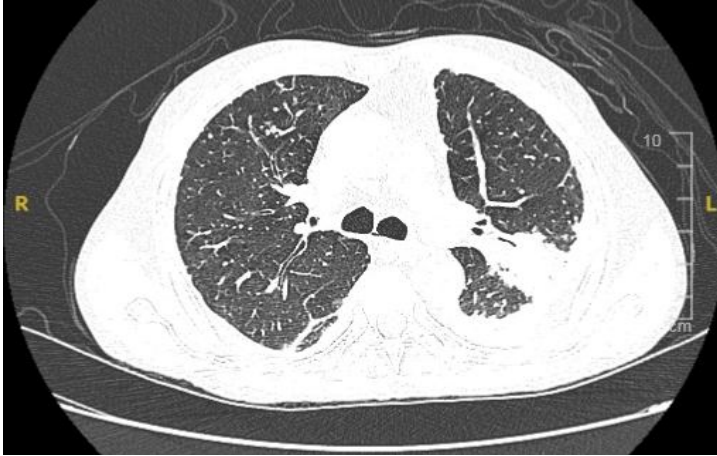
#### ***High-resolution computed tomography (HRCT) Chest:***

Bilateral loculated mild to moderate pleural effusion was seen with pleural thickening and associated basal consolidation as shown in figure 1.

A few patchy areas of consolidation were seen in both lungs.

Multiple tiny random alveolar and miliary nodules are scattered in both lungs.

Few calcified mediastinal lymph nodes were seen.



**Fig. 1. Radiological findings of the patient's CT of the chest**

**On hospital day 2,**

**ECHO report showed:**

Left ventricular ejection fraction was 64%, no regional wall motion abnormalities, mild left ventricular diastolic dysfunction, trivial mitral regurgitation/tricuspid regurgitation, pulmonary artery systolic pressure was 32mmHg, and no pulmonary artery hypertension.

**On hospital day 3,**

The total calcium level was found to be 11.2mg/dl. The serum albumin level was 3.1g/dl. Given hypercalcemia, albumin-corrected calcium was done and reported to be 11.9mg/dl. In view of Secondary adrenal insufficiency, an Endocrinologist's opinion was obtained, and advice was carried out.

**On hospital day 4,**

**The ultrasound abdomen report showed:**

Simple hepatic cysts and otherwise no abnormality detected in visualized organs.

**On hospital day 5,**

Given the loculated pleural effusion, Ultrasound-guided left-side diagnostic pleural tapping was done. About 15ml of fluid was drained and sent for analysis. Thick contents were present in the pleural fluid and it showed: Acid-Fast Bacilli (AFB) smear: no acid-fast bacilli seen, gram stain: many pus cells and no organism seen. Gene Xpert: *Mycobacterium tuberculosis* complex not detected, cytology: no atypical/malignant cells were noted.

**On hospital day 6,**

A bronchoscopy for Bronchoalveolar lavage was done and it showed: Carina sharp, mild frothy mucoid secretion noted in the right upper lobe/right lower lobe & left lower lobe bronchial segments.

**On hospital day 7,**

Bronchoalveolar lavage analysis showed: Acid-Fast Bacilli (AFB) smear: No Acid-fast bacilli seen, Gene Xpert for MTB: Very low *Mycobacterium tuberculosis* complex detected. Rifampicin Resistance was not detected.

Regarding tenderness and swelling of the left knee, an Orthopedician opinion was obtained and advised for the ultrasound of the left knee, which showed no fluids to drain. The ultrasound also showed features suggestive of left knee synovitis.

**On hospital day 8,**

A Medical Oncologist's opinion was obtained to exclude malignancy. In view of the diagnostic dilemma and multisystem involvement, Positron emission tomography-computed tomography (PET-CT) for the whole body was carried out and is shown in figures 2 and 3.

**Positron emission tomography-computed tomography (PET-CT) whole body:**

Metabolically active consolidations with adjacent nodularity and fibrotic bands are seen involving the apicoposterior segment of the left lung upper lobe, and the apical segment of the right lung upper lobe and right lung middle lobe as described.

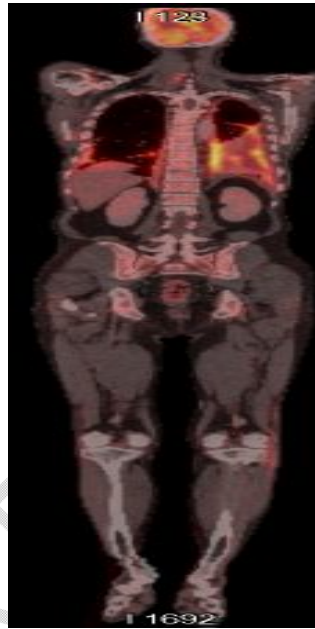
Hypermetabolic enhancing pleural thickening in bilateral basal pleura with loculated pleural effusion - likely empyema

Hypermetabolic mediastinal lymphadenopathy.

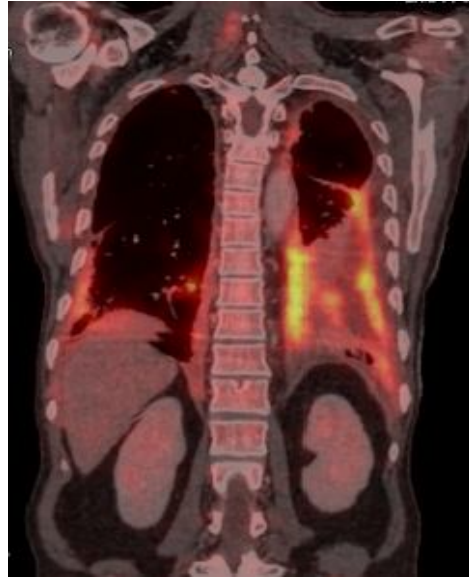A low-grade metabolically active enhancing lesion in the brain's right parietal lobe in the periventricular region with mild perilesional edema.

Ill-defined hypermetabolic enhancing soft tissue thickening involving the left iliac muscle.

Hypermetabolic enhancing subcutaneous soft tissue thickening in the anterior aspect of the left knee and lateral aspect of the right knee.

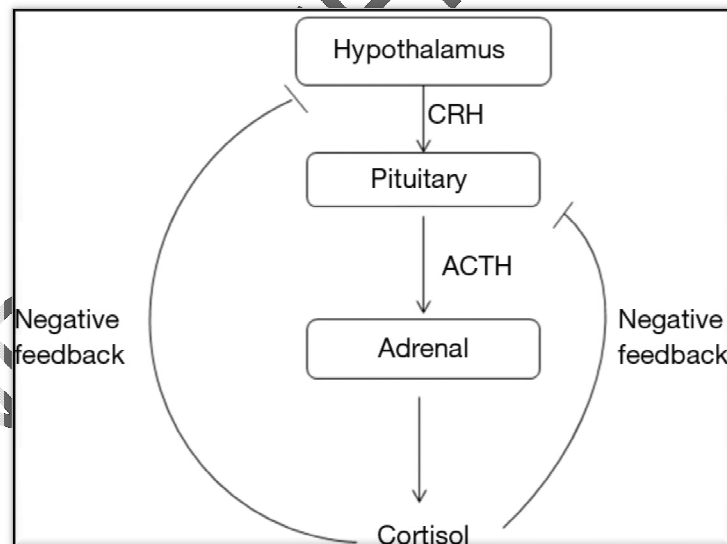


**Fig. 2. PET-CT of the whole body**



**Fig. 3. PET-CT of the chest**

As the patient had a fever and his adrenals were still recovering, the tablet Prednisolone, a corticosteroid, was prescribed for better support of the adrenals. As a result, the patient got hemodynamically stable and symptomatically better. Hence he was discharged on next day.



**Fig. 4. The hypothalamic-pituitary-adrenal axis**

The hypothalamic-pituitary-adrenal axis is depicted in the above figure. Exogenous and endogenous glucocorticoids both have a negative feedback effect on pituitary and hypothalamic levels. This negative feedback effect of exogenous glucocorticoid administration may lead to secondary adrenal insufficiency. ACTH and CRH stands for Adrenocorticotropic hormone and Corticotropin-releasing hormone, respectively.[7]

Glucocorticoid treatment may cause adrenal insufficiency via feedback suppression of CRH and ACTH, eventually inducing adrenocortical hypoplasia and atrophy, and rendering the HPA axis unable to produce an adequate cortisol response to stress. Adrenal insufficiency may persist after cessation of glucocorticoid treatment.[8]

## DISCUSSION

The hematogenous spread of *Mycobacterium tuberculosis* causes a severe health problem known as "disseminated tuberculosis," which is linked to a heavy burden of morbidity and mortality on a global scale. Disseminated tuberculosis occurs because of the inadequacy of host defenses in containing the infection, allowing the organism to proliferate and disseminate throughout the body. Because other sites may not be tested after the organism is discovered in any specimen, multi-organ involvement is likely to be considerably more common.

The patient experienced a turbulent course of events, including high-grade fever flare-ups, significant breathing problems, joint pain, fatigue, and a severe cough that did not respond to treatment. Several systems, including the immune system, pleura, joints, adrenal glands, bones, brain, and lungs are involved in the present case. The rare progression of a common disease into a multisystem condition is demonstrated. This instance is a good illustration of the effects of unreasonable drug use. It acknowledges that taking over-the-counter medications without proper consultation might lead to severe consequences

Up to 10% of extrapulmonary TB involves the bones and joints. Left knee synovitis developed in our patient and was identified through a knee ultrasound. This ultrasound (US) revealed signs of synovitis in the left knee. The appropriate medical treatment was started. Another case of tuberculosis arthritis was described by Sayad B *et al.* (2022). As it was often misdiagnosed as reactive arthritis or septic arthritis and treated as such, the diagnosis, in this case, was delayed.[9]

Our report revealed elevated calcitriol levels and normal 25-(OH) Vitamin D levels. Wauthier L *et al.* (2020) offered a similar interpretation and described an exceptional occurrence of hypercalcemia in the context of disseminated TB in a patient with rheumatoid arthritis. A stimulated 1-hydroxylase activity of the macrophages within the granulomatous response sites of tuberculosis patients can be the cause of this rise in calcitriol concentrations.[10]

In our case, the patient had drug-induced adrenal insufficiency brought on by oral steroid medication and hypotension. Following a low-maintenance dose of steroid therapy, the patient had a turbulent recovery. Chronic usage of glucocorticoids may result in negative feedback that suppresses the hypothalamus pituitary adrenal axis. Adrenal secondary insufficiency could result from this. After stopping glucocorticoids, the hypothalamus pituitary adrenal axis usually returns to normal. A case study by Kempegowda, P *et al.* (2019) reported similar findings. Despite halting the prescribed steroid drugs, their patient continued to have secondary adrenal insufficiency.[11]

## 4. CONCLUSION

The correct diagnosis, treatment, patient counseling, diet, and family support helped our patient recover despite his turbulent recovery. However, as far as steroid therapy is concerned, it is a double-edged sword, meaning that taking over-the-counter steroid drugs without seeking adequate medical advice could have serious adverse effects.

## CONSENT

As per international standards or university standards, patients' written consent has been collected and preserved by the authors.

## ETHICAL APPROVAL

It is not applicable.

## REFERENCES

1. Esposito, SB, Levi, J., Matuzsan, ZM, Amaducci, AM, Richardson, DM. A Case Report of Widely Disseminated Tuberculosis in Immunocompetent Adult Male. *Clin Pract Cases Emerg Med* 2020;4(3), 375-379.
2. Khan FY. Review of literature on disseminated tuberculosis with emphasis on the focused diagnostic workup. *Journal of Family and Community Medicine* 2019;26(2):83-91.
3. Ye Y, Yang N, Zhou J, Qian G, Chu J. Case Report: Metagenomic Next-Generation Sequencing in Diagnosis of Disseminated Tuberculosis of an Immunocompetent Patient. *Frontiers in Medicine*. 2021 Jul 12;8:687984.
4. Emuze ME, Esan A, Olalusi O, Adegoke OO, Ogunsanya TE, Akunwata C, Akulue J. An Unusual Presentation of Disseminated Tuberculosis in South-West Nigeria: A Case Report. *Journal of Infectious Diseases and Epidemiology*, 7(11), 236.
5. Fauzi A, Permatasari A. Disseminated tuberculosis with symptoms of decreased consciousness: A rare case in Indonesian male. *Annals of Medicine and Surgery*. 2022Jan;73:103209.
6. Ada's Medical Knowledge Team. Disseminated Tuberculosis. Ada.com. Accessed 27 November 2022. Available: <https://ada.com/conditions/disseminated-tuberculosis/>
7. Younes AK, Younes NK. Recovery of steroid induced adrenal insufficiency. *TranslPediatr*. 2017;6(4):269-273
8. Laugesen K, Broersen LHA, Hansen SB, Dekkers OM, Sørensen HT, Jorgensen JOL. Management of Endocrine Disease: Glucocorticoid-induced adrenal insufficiency: replace while we wait for evidence? *European Journal of Endocrinology*, 2021 Apr;184(4):R111-R122. doi: 10.1530/EJE-20-1199.
9. Sayad B, Babazadeh A, Shabani S, Hosseinzadeh R, Barary M, Ebrahimpour S & Mohseni Afshar. Tuberculosis arthritis of ankle: A case report. *Clin Case Rep* 2022;10(7) doi.org/10.1002/ccr3.6112
10. Wauthier L, Theunssens X, Durez P, Fillee C, Maisin D, Gruson D. A rare case of tuberculosis-induced hypercalcemia. *Biochem Med (Zagreb)*. 2020 Oct 15;30(3):030801. doi: 10.11613/BM.2020.030801.
11. Kempegowda P, Quinn L, Shepherd L, et al. Adrenal insufficiency from steroid-containing complementary therapy: importance of detailed history. *Endocrinol Diabetes Metab Case Rep*. 2019;(1):1-4. Published 2019 Jul 26. doi:10.1530/EDM-19-0047