

Case report

Rare Presentation of Disseminated Tuberculosis in the Present Era of Modern Tuberculosis Management

Abstract

Background: Disseminated tuberculosis (TB) is defined as having two or more noncontiguous sites resulting from lymphohematogenous dissemination of Mycobacterium tuberculosis. In an immunocompetent host, it is uncommon. The presentation varies, and non-specific early infection symptoms can be noted on chest radiography. In cases of disseminated tuberculosis, early medication beginning is linked to significantly better outcomes. The current case report describes the series of incidents that resulted from a 50-year-old man's unreasonable usage of the corticosteroid medication, tablet Betamethasone which he was taking for cough and cold related to his chronic obstructive pulmonary disease (COPD).

Case Presentation: A 50-year-old Indian male patient with osteoporosis, drug-induced adrenal insufficiency, and bilateral pleural effusion who is receiving anti-tuberculosis therapy which he is on now was presented to the outpatient department of a tertiary hospital with complaints of fever associated with shivering on & off for 4 months, generalized tiredness. He had a history of loose stools for 2-3 days, small joint pain, left knee joint pain and swelling, loss of weight, and loss of appetite.

Conclusion: The right diagnosis, treatment, patient counseling, diet, and family support helped him recover despite his turbulent recovery phase. As far as steroid therapy is concerned, it is a double-edged sword, meaning that taking over-the-counter steroid drugs without first seeking adequate medical advice could have serious negative effects.

Keywords: Disseminated tuberculosis, Adrenal insufficiency, Corticosteroid, Betamethasone

Comment [CHP1]: Disseminated tuberculosis (TB) is defined as two or more noncontiguous sites resulting from lymphohematogenous dissemination of Mycobacterium tuberculosis.

Comment [CHP2]: Early medication beginning is linked to significantly better outcomes in cases of disseminated tuberculosis.

Comment [CHP3]: The current case report describes the series of incidents that resulted from a 50-year-old man's excessive usage of the corticosteroid medication tablet Betamethasone, which he was taking for a cough and cold related to his chronic obstructive pulmonary disease (COPD).

Comment [CHP4]: ...is...

Comment [CHP5]: Corticosteroid...

1. INTRODUCTION

A progressive, potentially fatal condition known as "Disseminated tuberculosis" is caused by the lymphohematogenous spread of the "Mycobacterium tuberculosis" bacilli as a result of either primary dissemination or development from years of untreated tuberculosis [1]. A typical finding that is crucial for the early diagnosis of the disease is the miliary pattern on chest radiography. Although the precise global incidence of disseminated tuberculosis is yet unknown, in immunocompetent people, it is believed to represent 2% of all cases of tuberculosis and up to 20% of cases of extrapulmonary tuberculosis [2]. Fever, weight loss, anorexia, anemia, pancytopenia, hepatosplenomegaly, and raised inflammatory markers including the erythrocyte sedimentation rate (ESR) are all possible clinical characteristics [3].

Comment [CHP6]: ...tuberculosis cases...

2. CASE PRESENTATION

A 50-year-old Indian male patient with osteoporosis, drug-induced adrenal insufficiency, and bilateral pleural effusion who is receiving anti-tuberculosis therapy which he is on now was presented to the outpatient department of a tertiary hospital with complaints of fever associated with shivering on & off for 4 months, generalized tiredness. He had a history of loose stools for 2-3 days, small joint pain, left knee joint pain and swelling, loss of weight, and loss of appetite. In the past, the patient experienced generalized body swelling. After being examined in a local hospital, fluid retention due to drug-induced adrenal insufficiency was determined to be the cause and there was osteoporosis as well. Family history of tuberculosis, that is his daughter suffered from abdominal tuberculosis, while his father had pulmonary tuberculosis. On examination, he was conscious, oriented, and febrile. His vitals showed SpO₂: 95% on room air, Blood pressure:130/70mmHg, in the right upper lobe in the supine position, Respiratory rate:25/minute, Pulse rate:100/minute, rhythm-regular and Temperature:100.7F. The respiratory system displayed reduced breath sound intensity in both basal segments and the presence of bibasilar crepitations.

After using tablet Betamethasone for a cough and cold in the past, the patient experienced drug-induced secondary adrenal insufficiency. It was administered for Chronic Obstructive Pulmonary Disease (COPD), which resulted in decreased blood pressure, steroid toxicity and immunosuppression, and was accompanied by Disseminated Tuberculosis.

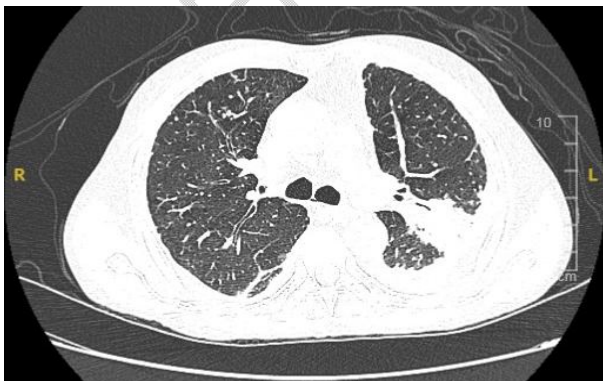Course in hospital:

On hospital day 1,

Blood Picturerevealed Microcytic hypochromic with mild anisopoikilocytosis. The patient was treated with Anti-Tuberculosis therapy, IVAntibiotics, IV Proton pump inhibitors, aerosolized bronchodilators, and all other supportive measures along with nutrient supplements.

HRCT Chest showed (Figure 1):

1. Bilateral loculated mild to moderate pleural effusion was seen with pleural thickening and associated basal consolidation.
2. A few patchy areas of consolidation were seen in both lungs.
3. Multiple tiny random alveolar and miliary nodules were seen scattered in both lungs.
4. Few calcified mediastinal lymph nodes were seen.



Comment [CHP7]: A 50-year-old Indian male patient with osteoporosis, drug-induced adrenal insufficiency, and bilateral pleural effusion receiving anti-tuberculosis therapy, which he is on, was presented to the outpatient department of a tertiary hospital with complaints of fever associated with fever shivering on & off for four months, generalized tiredness.

Comment [CHP8]: ...minor joint pain,...

Comment [CHP9]: He has a family history of tuberculosis; his daughter suffered from abdominal tuberculosis, while his father had pulmonary tuberculosis.

Comment [CHP10]: ...steroid toxicity, and...

Comment [CHP11]: Hospital course:

Comment [CHP12]: ...measures, along with...

Comment [CHP13]: 3. Multiple tiny random alveolar and miliary nodules are scattered in both lungs.

Fig. 1. Radiographical findings of the patient chest

On hospital day 2,

ECHO report showed:

Left ventricular ejection fraction was 64%, no regional wall motion abnormalities, mild left ventricular diastolic dysfunction, trivial mitral regurgitation/tricuspid regurgitation, pulmonary artery systolic pressure was 32mmHg, and no pulmonary artery hypertension.

On hospital day 3,

The total calcium level was found to be 11.2mg/dl. Serum albumin level was 3.1g/dl. In view of hypercalcemia, albumin corrected calcium was done and reported to be 11.9mg/dl. In view of Secondary adrenal insufficiency, an Endocrinologist's opinion was obtained, and advice was carried out.

On hospital day 4,

The USG Abdomen report showed:

Simple hepatic cysts and otherwise no abnormality detected in visualized organs.

On hospital day 5,

In view of Loculated Pleural effusion, USG-guided left-side diagnostic pleural tapping was done. About 15ml of fluid was drained and sent for analysis. Thick contents were present in the pleural fluid and it showed: Acid-Fast Bacilli (AFB) smear: no acid-fast bacilli seen, gram stain: many pus cells and no organism seen. Gene Xpert: Mycobacterium tuberculosis complex not detected, cytology: no atypical/malignant cells were noted.

On hospital day 6,

Bronchoscopy for Bronchoalveolar lavage was done and it showed: Carina sharp, mild frothy mucoid secretion noted in right upper lobe/right lower lobe & left lower lobe bronchial segments.

On hospital day 7,

Bronchoalveolar lavage analysis showed: Acid-Fast Bacilli (AFB) smear: No Acid-fast bacilli seen, Gene Xpert for MTB: Very low Mycobacterium tuberculosis complex detected. Rifampicin Resistance was not detected.

In view of tenderness and swelling of the left knee, an Orthopedician opinion was obtained and advised for USG Left Knee and it showed no fluids to drain. USG shows features suggestive of left knee synovitis.

On hospital day 8,

A Medical Oncologist's opinion was obtained to exclude malignancy. In view of the diagnostic dilemma and multisystem involvement, PET CT for the whole body was carried out.

PET CT whole body showed (Fig. 2 & Fig. 3):

1. Metabolically active consolidations with adjacent nodularity and fibrotic bands are seen involving the apicoposterior segment of the left lung upper lobe, and the apical segment of the right lung upper lobe and right lung middle lobe as described.
2. Hypermetabolic enhancing pleural thickening in bilateral basal pleura with loculated pleural effusion - likely empyema
3. Hypermetabolic mediastinal lymphadenopathy.
4. A low-grade metabolically active enhancing lesion in the right parietal lobe of the brain in the periventricular region with mild perilesional edema.
5. Ill-defined hypermetabolic enhancing soft tissue thickening involving the left iliac muscle.

Comment [CHP14]: Fig. 1. Radiological findings of the patient's CT of the chest

Comment [CHP15]: The serum albumin...

Comment [CHP16]: Given hypercalcemia, albumin-corrected calcium was done and reported to be 11.9mg/dl.

Comment [CHP17]: Given the loculated pleural effusion, US-guided...

Comment [CHP18]: A bronchoscopy...

Comment [CHP19]: ...in the right upper...

Comment [CHP20]: Regarding tenderness and swelling of the left knee, an Orthopedician opinion was obtained and advised for the US of the left knee, which showed no fluids to drain. The US also showed features suggestive of left knee synovitis.

Comment [CHP21]: 4. A low-grade metabolically active enhancing lesion in the brain's right parietal lobe in the periventricular region with mild perilesional edema.

Comment [CHP22]: ...iliac...

6. Hypermetabolic enhancing subcutaneous soft tissue thickening in the anterior aspect of the left knee and lateral aspect of the right knee.

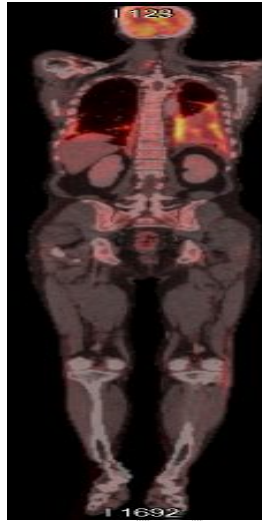


Fig. 2. PET CT of the whole body

Comment [CHP23]: PET-CT of the whole body

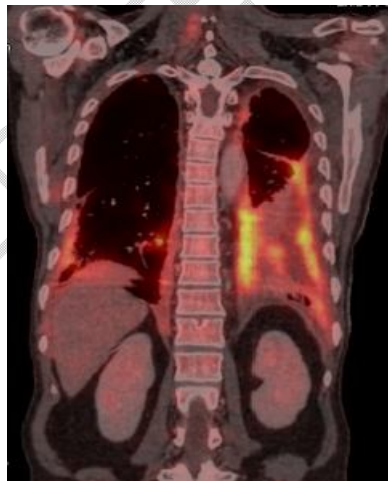

Fig. 3. PET CT of the chest

Comment [CHP24]: PET-CT of the chest

As the patient was having a fever and his adrenals were still recovering, the tablet Prednisolone, which is a corticosteroid was prescribed for better support of the adrenals. The patient got hemodynamically stable and symptomatically better, hence he was discharged on next day.

Comment [CHP25]: As the patient had a fever and his adrenals were still recovering, the tablet Prednisolone, a corticosteroid, was prescribed for better support of the adrenals. As a result, the patient got hemodynamically stable and symptomatically better. Hence he was discharged on next day.

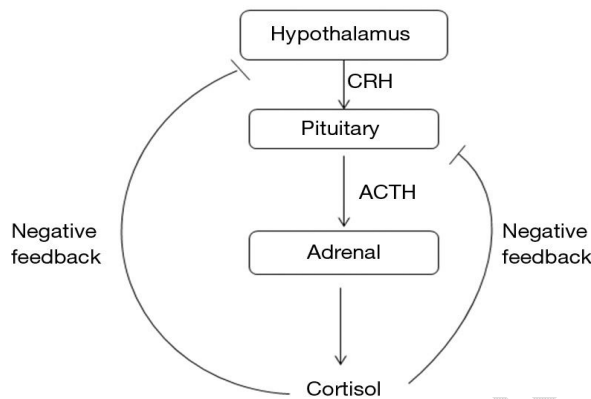


Fig. 4. The hypothalamic-pituitary-adrenal axis

Comment [CHP26]: Please note the new position of figure 4 and its legend.

DISCUSSION

The hematogenous spread of *Mycobacterium tuberculosis* causes a serious health problem known as "disseminated tuberculosis," which is linked to a heavy burden of morbidity and mortality on a global scale. Disseminated tuberculosis occurs because of the inadequacy of host defenses in containing the infection, allowing the organism to proliferate and disseminate throughout the body. Because other sites may not be tested after the organism is discovered in any specimen, multi-organ involvement is likely to be considerably more common in this case.

Comment [CHP27]: ...severe health problem...

The patient experienced a turbulent course of events including high-grade fever flare-ups, significant breathing problems, joint pain, fatigue, and a severe cough that did not respond to treatment. Several systems, including the immune system, pleura, joints, adrenal glands, bones, brain, and lungs are involved in the present case. The rare progression of a common disease into a multisystem condition is demonstrated. This instance is a good illustration of the effects of unreasonable drug use. It acknowledges the fact that taking over-the-counter medications without any proper consultation might lead to severe consequences.

Comment [CHP28]: Because other sites may not be tested after the organism is discovered in any specimen, multi-organ involvement is likely to be considerably more common.

Comment [CHP29]: ...events, including...

Exogenous and endogenous glucocorticoids both have a negative feedback effect on pituitary and hypothalamic levels. This negative feedback effect of exogenous glucocorticoid administration may lead to secondary adrenal insufficiency. ACTH and CRH stand for Adrenocorticotropic hormone and Corticotropin-releasing hormone respectively.[4]

Comment [CHP30]: It acknowledges that taking over-the-counter medications without proper consultation might lead to severe consequences.

Comment [CHP31]: ...hormone, respectively.

Up to 10% of extrapulmonary TB involves the bones and joints. Left knee synovitis developed in our patient, and it was identified through a knee ultrasound. The Ultrasonography (USG) revealed signs of synovitis in the left knee. The appropriate medical treatment was started. Another case of tuberculosis arthritis was described by *Sayad B et al.* As it was often misdiagnosed as reactive arthritis or septic arthritis and treated as such, the diagnosis in this case was delayed.[5]

Comment [CHP32]: Left knee synovitis developed in our patient and was identified through a knee ultrasound.

Comment [CHP33]: This ultrasound (US)...

Comment [CHP34]: ...diagnosis, in this case, was delayed.

Our report revealed elevated calcitriol levels and normal 25-(OH) Vitamin D levels. A similar interpretation was offered by *Wauthier L et al.*, who described an exceptional occurrence of hypercalcemia in the context of disseminated TB in a patient with rheumatoid arthritis. A stimulated 1-hydroxylase activity of the macrophages within the granulomatous response sites of tuberculosis patients can be the cause of this rise in calcitriol concentrations.[6]

Comment [CHP35]: *Wauthier L et al.* offered a similar interpretation and described an exceptional occurrence of hypercalcemia in the context of disseminated TB in a patient with rheumatoid arthritis.

In our case, the patient had drug-induced adrenal insufficiency brought on by oral steroid medication along with hypotension. Following a low-maintenance dose of steroid therapy, the patient had a turbulent phase of recovery. Chronic usage of glucocorticoids may result in negative feedback that suppresses the hypothalamus pituitary adrenal axis. Adrenal secondary insufficiency could result from this. After stopping the use of glucocorticoids, the hypothalamus pituitary adrenal axis usually returns to normal. A case study by **Kempegowda, P et al.** reported similar findings. Despite stopping the prescribed steroid drugs, their patient continued to have secondary adrenal insufficiency.[7]

Comment [CHP36]: In our case, the patient had drug-induced adrenal insufficiency brought on by oral steroid medication and hypotension.

Comment [CHP37]: Following a low-maintenance dose of steroid therapy, the patient had a turbulent recovery. Chronic usage of glucocorticoids may result in negative feedback that suppresses the hypothalamus pituitary adrenal axis.

4. CONCLUSION

The right diagnosis, treatment, patient counseling, diet, and family support helped him recover despite his turbulent recovery phase. As far as steroid therapy is concerned, it is a double-edged sword, meaning that taking over-the-counter steroid drugs without first seeking adequate medical advice could have serious negative effects.

Comment [CHP38]: Adrenal secondary insufficiency could result from this. After stopping glucocorticoids, the hypothalamus pituitary adrenal axis usually returns to normal. A case study by **Kempegowda, P et al.** reported similar findings. Despite halting the prescribed steroid drugs, their patient continued to have secondary adrenal insufficiency.[7]

CONSENT

As per international standard or university standard, patients' written consent has been collected and preserved by the authors.

Comment [CHP39]: The correct diagnosis, treatment, patient counseling, diet, and family support helped our patient recover despite his turbulent recovery. However, as far as steroid therapy is concerned, it is a double-edged sword, meaning that taking over-the-counter steroid drugs without seeking adequate medical advice could have serious adverse effects.

ETHICAL APPROVAL

It is not applicable.

Comment [CHP40]: As per international standards or university standards,...

REFERENCES

1. Esposito S, Levi J, Matuzsan Z, Amaducci A, Richardson D. A Case Report of Widely Disseminated Tuberculosis in Immunocompetent Adult Male. *Clinical Practice and Cases in Emergency Medicine*. 2020 Jun 4;4(3):375-9.
2. Khan FY. (2019). Review of literature on disseminated tuberculosis with emphasis on the focused diagnostic workup. *Journal of Family & Community Medicine*, 26(2), 83–91.
3. Emuze ME, Esan A, Olalusi O, Adegoke OO, Ogunsanya TE, Akunwata C, Akulue J. An Unusual Presentation of Disseminated Tuberculosis in South-West Nigeria: A Case Report. *J Infect Dis Epidemiol*. 2021 Nov 11;7(11)
4. Younes AK, Younes NK. Recovery of steroid induced adrenal insufficiency. *Transl Pediatr*. 2017 Oct;6(4):269-73.
5. Sayad B, Babazadeh A, Shabani S, Hosseinzadeh R, Barary M, Ebrahimpour S & Mohseni Afshar. Tuberculosis arthritis of ankle: A case report. *Clinical Case Reports*. 2022 Jul;10(7)
6. Wauthier L, Theunssens X, Durez P, Fillee C, Maisin D, Gruson D. A rare case of tuberculosis-induced hypercalcemia. *Biochem med*. 2020 Oct 15;30(3):471-4.
7. Kempegowda P, Quinn L, Shepherd L, Kauser S, Johnson B, Lawson A & Bates A. Adrenal insufficiency from steroid-containing complementary therapy: importance of detailed history. *Endocrinology, Diabetes & Metabolism Case Reports*. 2019 Jul 26;2019

Comment [CHP41]: 1. Esposito, SB, Levi, J, Matuzsan, ZM, Amaducci, AM, Richardson, DM. A Case Report of Widely Disseminated Tuberculosis in Immunocompetent Adult Male. *Clin Pract Cases Emerg Med* 2020;4(3), 375-379.

Comment [CHP42]: 2. Khan FY. Review of literature on disseminated tuberculosis with emphasis on the focused diagnostic workup. *Journal of Family and Community Medicine* 2019;26(2):83-91.

Comment [CHP43]: Please add a correct reference

Comment [CHP44]: *Transl Pediatr*. 2017;6(4):269-273

Comment [CHP45]: *Clin Case Rep* 2022;10(7)doi.org/10.1002/ccr3.6112

Comment [CHP46]: *Biochem Med (Zagreb)*. 2020 Oct 15;30(3):030801. doi: 10.11613/BM.2020.030801.

Comment [CHP47]: 7. Kempegowda P, Quinn L, Shepherd L, et al. Adrenal insufficiency from steroid-containing complementary therapy: importance of detailed history. *Endocrinol Diabetes Metab Case Rep*. 2019;(1):1-4. Published 2019 Jul 26. doi:10.1530/EDM-19-0047