

Original Research Article

Cardio-protective Effect of the Leaf Extract of *Andrographis paniculata* in Isoproterenol-Induced Myocardial Infarction

ABSTRACT

Background: Nowadays, myocardial infarction has been regarded as one of the chronic diseases with increasing mortality rate worldwide. The use of medicinal plants in the treatment of this chronic disease is gaining wide acceptance globally. *Andrographis paniculata* (Acanthaceae) is a medicinal plant commonly known as king of bitters in Nigeria and has been acclaimed with several therapeutic activities. **Materials and methods:** This study investigated the cardio-protective effect of the leaf extract of *A. paniculata* in isoproterenol-induced myocardial infarction. Fresh green leaves of *A. paniculata* were harvested from the Faculty of Agriculture farmland, Nnamdi Azikiwe University, Awka, Nigeria. Identification and authentication of the plant was carried at the Department of Botany, Nnamdi Azikiwe University and a voucher specimen was deposited at the herbarium. The plant material was then shredded, air-dried under shade and pulverized. The fine powders obtained was weighed and extraction was done via solvent combination of water and ethanol (3:7) for 72 hr via maceration. The filtrate gotten was evaporated to dryness to obtain the ethanol extract which was used for further bioassay study. The bioactive constituents of the plant extract were quantitatively analyzed by Gas chromatography mass spectrometry (GC-MS). The animals were administered with the extract of *A. paniculata* orally for seven days at a divided dose of 100 mg/kg, 200 mg/kg and 400 mg/kg body weights. On the eight day, myocardial infarction was induced through subcutaneous administration of isoproterenol at a dose of 150 mg/kg/day diluted in 2 ml of saline on two consecutive days. Subsequently, the blood pressures were monitored and blood collected for bioassay studies. **Results:** The results of the study showed that the leaf extract of *A. paniculata* was rich in 2,5-Octadecadiynoic acid, methyl ester (28.21 %); 1,2,3,5-Cyclohexanetetrol,(1 α ,2 α ,3 α ,5 α)- (15.10 %) and 10-12-Pentacosadiynoic acid (13.05 %). The findings also showed a significant decrease ($p > 0.05$) in the Mean arterial blood pressure, heart rate, aspartate transaminase, alanine transaminase, creatinine kinase and lactate dehydrogenase activities of the treatment group compared with the untreated control group while the antioxidant (superoxide dismutase, catalase and glutathione) activities were significantly increased in the treatment group, compared with the untreated control group. **Conclusion:** The findings of this work have shown that leaf of *A. paniculata* was rich in bioactive compounds which could be synthesized to produce plant based products to fight cardiovascular diseases especially myocardial infarction.

Keywords: Cardiovascular disease, Myocardial infarction, Medicinal plant, *Andrographis paniculata*, Isoproterenol.

INTRODUCTION

Cardiovascular diseases (CVD) is currently the leading cause of morbidity and mortality worldwide with annual mortality rate of 17.5 million people, which constitute about 31% of all deaths worldwide [1], with more than 75% occurrence in low and middle income countries [2, 3]. About 80% CVD deaths occur due to stroke and myocardial infarction [4]. Myocardial infarction (MI) is described as the necrosis of heart muscle following total occlusion of blood supply to the heart [5].

MI is now recognized as an overwhelming burden to the healthcare status of the human population and it is one of the significant type cardiovascular diseases [5]. MI is reflective when blood clot blocks the blood flow to the heart, resulting from decades of mismatched lifestyle choices. Addressing myocardial infarction in the populace will be a way to resolve chronic conditions of cardiovascular diseases.

Despite landmark achievement in medicine, the continuous use of synthetic cardio-protective drugs have been characterized with varying side effects ranging from joint pain to loss of memory [6]. Thus, the use of plants, abundant in our environment to combat cardiovascular diseases is a strategy that should provide an alternative approach to solve this perennial problem. Herbal medicine is gaining wide acceptance in the fight against chronic diseases especially myocardial infarction owing to better understanding of the mechanisms by which they positively influence health and improves quality of life [7].

Andrographis paniculata (Nees) is one of the promising plants that could help to ameliorate the negative impact of myocardial infarction. *A. paniculata* belongs to the natural order Acanthaceae and it is commonly known as king of bitters. It was reported to possess anti-inflammatory [8], anticancer [9], anti-hyperglycemic [10] and anti-oxidative [11] effects.

Despite several studies on *A. paniculata*, its potentials in ameliorating cardiovascular disorders have not been well explored and documented in the literature. Hence, the need for this study.

From the experience in this study, it could be possible to use this extract as a protective medicament in patients at high risk of myocardial infarction and those with stable and unstable angina. This could be life saving, cheaper and safer alternative to other conventional medications used for similar purposes.

MATERIALS AND METHODS

Sample Collection and Preparation

Fresh green leaves of *Andrographis paniculata* were collected from a farmland in Owerri, Imo-State, Nigeria. Identification and authentication of the plant was carried out at the Department of Botany, Nnamdi Azikiwe University, Awka and a voucher specimen was deposited at the herbarium of the Department for future references. The plant material was shredded with a knife and air-dried under shade for 21 days. The dried leaf was pulverized using a laboratory blender and the fine powders obtained was weighed and stored in an air-tight container at room temperature for further use.

3.2 Extraction of plant materials

The weighed powdered sample (245.79 g) was then used for the extraction with solvent combination of water and ethanol (3:7) (2500ml) for 72 hr via macceration. The mixture was decanted and filtered using sterile Whatman paper No. 1. The filtrate was evaporated to dryness using a rotary evaporator to obtain crude ethanol extract which was stored in an airtight container for further analysis. The yield of the crude extract (12.36g) was calculated according to the method of Nkafamiya *et al.* [12] using the formula below:

$$\text{Percentage yield} = \frac{\text{mass of extract (g)}}{\text{mass of sample (g)}} \times 100$$

GC-MS Elucidation

The method of Uchegbu *et al.* [13] was used to carry out GC-MS analysis at the Central Research and Diagnostic Laboratory, 132, University road, Tanke, Ilorin, Kwara State.

Determination of Median Lethal Dose (LD₅₀)

The median lethal dose was determined using Lorke's method [14].

ANIMAL STUDIES

Procurement of study animals

Wistar albino rats (30) weighing between 150 - 200 g were purchased from Chris Farm Ltd Mgbakwu, Awka, Anambra State and were brought to the animal house of the Department of Applied Biochemistry, Nnamdi Azikiwe University, Awka. The rats were kept in standard cages with saw dust as bedding and standard housing conditions of 12:12 light: dark cycles and fed with standard rat pellets and water *ad libitum*. The animals were allowed to acclimatize to the new environment for seven days. All the experimental procedures and protocols used in this study were in accordance with the guidelines principles of animal Research Ethics Committee of the Nnamdi Azikiwe University (aREC-NAU) guide for the care and use of laboratory animals.

Dose Preparation and Treatment

The hydro-ethanolic leaf extract of *Andrographis paniculata* was prepared with distilled water in three divided dose (100, 200, and 400) mg / kg, Atorvastatin (10 mg/kg) used as a reference drug and distilled water was used as vehicle for the untreated group. The animals were administered the extract and drug for fourteen consecutive days prior to induction with water *per os* and feed *ad libitum*.

Experimental design

The animals were randomly divided into five groups of six animals each, and the treatment was as follows: Groups A, B and C animals (designated as *A. paniculata* treatment group) were pre-treated with the ethanol leaf extract of *A. paniculata* at 100 mg/kg, 200 mg/kg and 400 mg/kg, respectively, for 14 days and thereafter 0.2 ml isoproterenol (ISO) at 150 mg/kg was injected subcutaneously at an interval of 24 h on days 15 and 16. Group D animals (designated as isoproterenol control) received 0.2 ml of 10 mg artovastatin for 14 days and thereafter 0.2 ml isoproterenol (ISO) at 150 mg/kg was injected subcutaneously at an interval of 24 h on days 15

and 16. Group E animals (designated as vehicle control group) received 0.2 ml normal saline for 14 days; and on day 15 and 16, 0.2 ml 0.2 ml isoproterenol (ISO) at 150 mg/kg was injected subcutaneously at an interval of 24 h on days 15 and 16 [15].

Blood pressure measurement

Blood pressure measurement of all the animals was carried out on day 17. Baseline cardiovascular parameters were collected prior to the commencement of the experiment. The equipment used was a non-invasive tail cuff BP monitor, the 6-channel CODA blood pressure monitor for rats and mice. Blood pressure parameters including the systolic, diastolic and mean arterial blood pressure parameters were determined indirectly in non-anaesthetised rats by tail plethysmography with the use of an electrospygomanometer (CODA, Kent Scientific, USA). The average of at least ten most consistent readings, taken in the quiescent state, following acclimatization, was recorded per animal.

Blood sample collection

At the end of the experimental period, blood samples were collected for serum chemistry before the rats were sacrificed by cervical dislocation. The serum in plain bottles was rapidly centrifuged at 4000 revolutions per minute (rpm) for 15 min and processed for determination of aspartate transaminase (AST), and alanine aminotransferase (ALT). The heart of each rat was carefully removed and homogenized on ice and then used to assay for some cardiac (creatinine kinase and lactate dehydrogenase) and oxidative stress biomarkers (superoxide peroxidase, catalase, glutathione peroxidase).

Preparation of tissue homogenate

The heart tissues of the rats were harvested on ice, rinsed with normal saline and homogenized in aqueous potassium buffer (0.1 M, pH 7.4), and the homogenate was centrifuged at 12 000 rpm (4 °C) for 15 min to obtain the supernatant fraction.

Biochemical assays

Assay of aspartate transaminase, alanine transaminase, creatinine kinase and lactate dehydrogenase activities were carried out with standard assay kit while the method of Rotruck *et al.* [16] was used to determine glutathione peroxidase (GPx) activity.

Superoxide dismutase (SOD) assay, on the other hand, was carried out by the method of Kakkar *et al.* [17] with slight modification whereas Catalase activities were determined following the method of Sinha [18].

Data Analysis

The results obtained in this study were expressed as Mean \pm S.D of triplicate determinations. One way analysis of variance (ANOVA) was carried out on the results and significance was accepted at $p < 0.05$. The graphical analyses were carried out using GraphPad Prism5 Program (GraphPad Software, San Diego, CA, USA).

RESULTS

The acute toxicological test of the plant extract on experimental rats is presented in table 1. The plant extract showed a toxic effect at a dose of 5000 mg/kg when one mortality was recorded. The median lethal dose (LD₅₀) which is the dose required to kill half of the members of a tested population after specified test duration is calculated to be 3,807.88 mg/kg.

Table 1: Acute toxicological study of hydro-ethanolic leaf extract of *A. paniculata*

Phase 1

Groups	Number of animals	Dose (mg/kg)	Number of deaths
1	3	10	0
2	3	100	0
3	3	1000	0

Phase II

Groups	Number of animals	Dose (mg/kg)	Number of deaths
1	1	1600	0
2	1	2900	0
3	1	5000	1

$$LD_{50} = \sqrt{(D_0 \times D_{100})}$$

Where:

D₀ = Highest dose that gave no mortality,

D₁₀₀ = Lowest dose that produced mortality

$$LD_{50} = \sqrt{(2900 \times 5000)}$$

$$LD_{50} = 3,807.88 \text{ mg/kg}$$

The GC-MS analysis of the plant extract is presented in table 2. The leaf extract of *A. paniculata* was found to be rich in 2, 5-Octadecadiynoic acid methyl ester (28.21%), 1,2,3,5-Cyclohexanetetrol,(1à,2á,3à,5á)- (15.10 %) and 10-12-Pentacosadiynoic acid (13.05 %). Other compounds present include 1, 3-Propanediol, 2-(hydroxymethyl)-2-nitro- content (7.22 %), 3-O-Methyl-d-glucose (6.02 %) while Dibutyl phthalate (2.11 %), Phytol (2.54 %) and Hexanedioic acid, bis (2-ethylhexyl) ester (1.02 %) are present in minute quantities.

Table 2: Bioactive compounds identified from the leaf extract using GC-MS

S/N	Compound	Molecular Formula	Molecular Weight (g/mol)	Retention Time (min)	Content (%)
1	2,5-Octadecadiynoic acid, methyl ester	C ₁₉ H ₃₄ O ₂	294.5	31.36	28.21
2	1,2,3,5-Cyclohexanetetrol, (1à,2á,3à,5á)-	C ₆ H ₁₂ O ₄	148.20	10.56	15.10
3	10-12-Pentacosadiynoic acid	C ₂₅ H ₄₂ O ₂	374.6	28.65	13.05
4	2H-Pyran, 2-(7-heptadecynyloxy)tetrahydro-2H-pyran	C ₂₂ H ₄₀ O ₂	336.6	34.01	8.92
5	1,3-Propanediol, 2-(hydroxymethyl)-2-nitro-	C ₄ H ₉ NO ₅	151.12	8.57	7.22
6	3-O-Methyl-d-glucose	C ₇ H ₁₄ O ₆	194.18	9.75	6.02
7	Dibutyl phthalate	C ₁₆ H ₂₂ O ₄	278.34	13.01	2.11
8	Phytol	C ₂₀ H ₄₀ O	296.53	14.5	2.54
9	Hexanedioic acid, bis(2-ethylhexyl) ester	C ₂₂ H ₄₂ O ₄	370.6	19.30	1.02
10	Nitric acid, nonyl ester	C ₉ H ₁₉ NO ₃	189.25	6.05	0.97

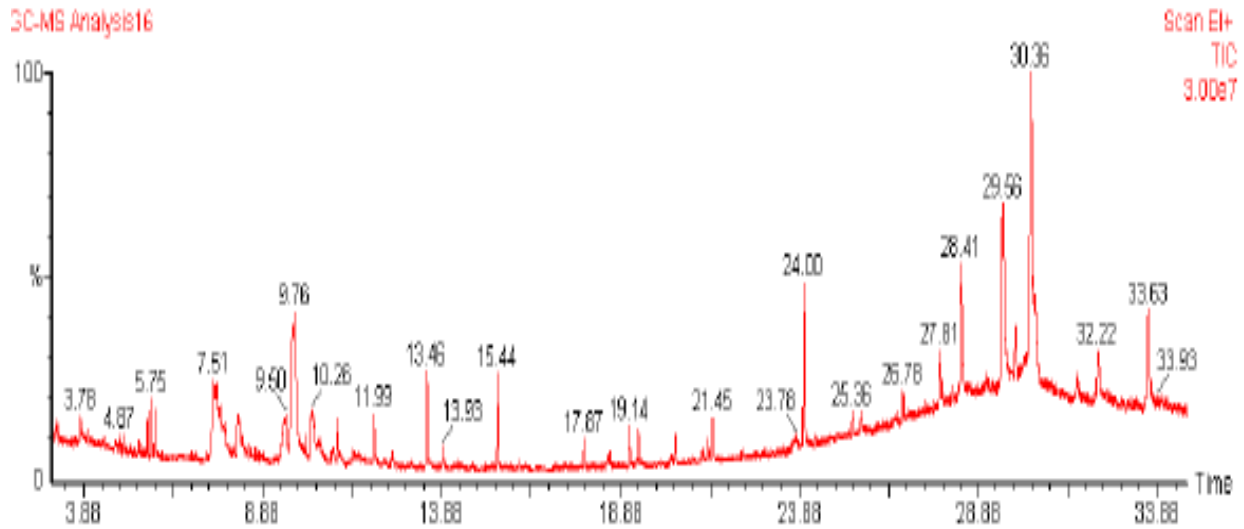


Fig. 1: GC-MS chromatogram of the leaf extract of *A. paniculata*

Table 3: Effect of the ethanolic leaf extract of *Andrographis paniculata* on blood pressure (BP) and heart rate in isoproterenol-induced myocardial infarction

Group	Treatment	Mean arterial blood pressure (MAP) (mmHg)	Heart rate (HR)(beats/ mins)
A	Myocardial infarction plus 100 mg/kg extract sample	102.50	260
B	Myocardial infarction plus 200 mg/kg extract sample	118.00	300
C	Myocardial infarction plus 400 mg/kg extract sample	122.00	315
D	Myocardial infarction plus 10 mg/kg Atorvastatin	100.00	220
E	Myocardial infarction with distilled water	130.50	350

The results showing the effect of *A. paniculata* leaf extract on the activity of aspartate transaminase (AST) in isoproterenol-induced myocardial infarction is presented in figure 2. Result showed a significant ($p>0.05$) decrease in AST activity in a dose dependent manner (100 mg/kg > 200 mg/kg > 400 mg/kg) in the extract treated group with marked activity increase in the untreated control.

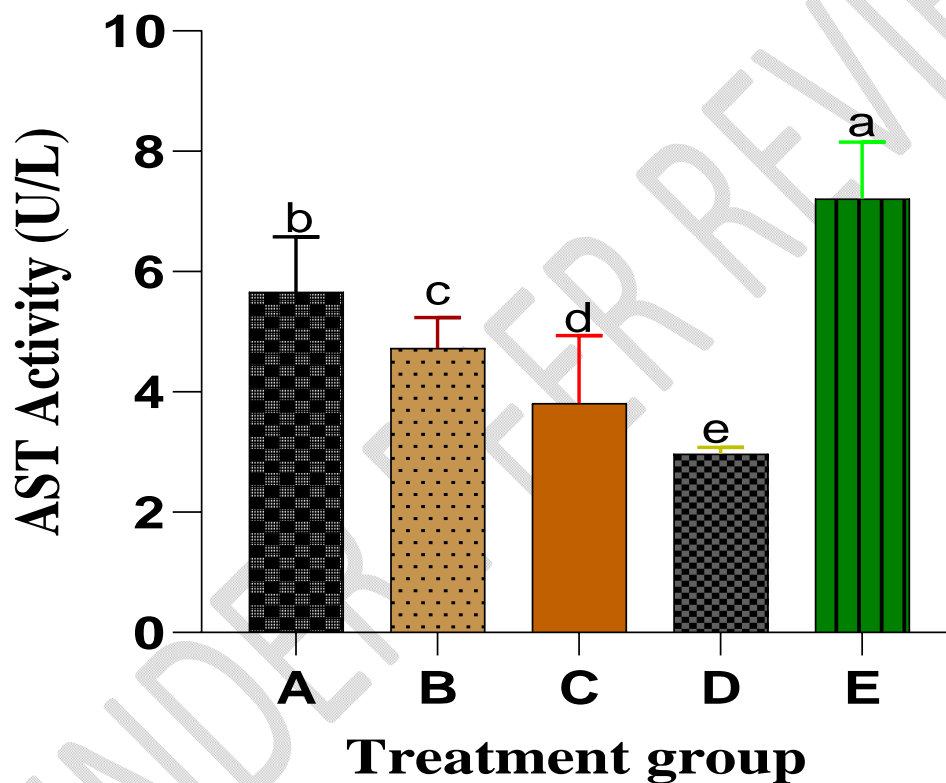


Figure 2: Effect of *A. paniculata* leaf extract on the activity of aspartate transaminase (AST) in isoproterenol induced myocardial infarction

Columns with different alphabets are significantly different at $P < 0.05$

The results showing the effect of *A. paniculata* leaf extract on the activity of alanine transaminase (ALT) in isoproterenol-induced myocardial infarction is presented in figure 3. Result showed a significant ($p > 0.05$) decrease in ALT activity in a dose dependent manner (100 mg/kg > 200 mg/kg > 400 mg/kg) in the extract treated group with marked activity increase in the untreated control.

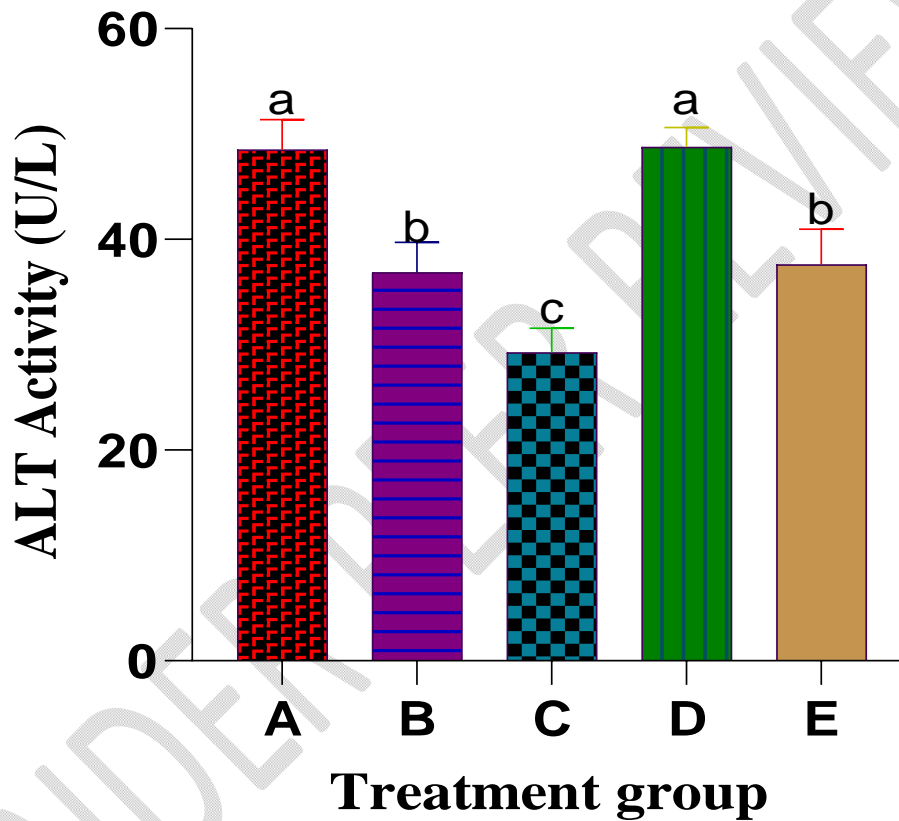


Figure 3: Effect of *A. paniculata* leaf extract on the activity of alanine transaminase (ALT) in isoproterenol induced myocardial infarction

Columns with different alphabets are significantly different at $P < 0.05$

Table 4: Effect of the ethanol leaf extract of *Andrographis paniculata* on cardiac biomarkers in isoproterenol-induced myocardial infarction

Group	Treatment	CK-MB (IU/mg protein)	LDH (IU/mg protein)
A	Myocardial infarction plus 100 mg/kg extract sample	79.44 ± 13.65	150.62 ± 31.44
B	Myocardial infarction plus 200 mg/kg extract sample	128.76 ± 17.80	158.20 ± 28.55
C	Myocardial infarction plus 400 mg/kg extract sample	146.50 ± 22.26	186.46 ± 23.27
D	Myocardial infarction plus 10 mg/kg Atorvastatin	152.40 ± 14.63	208.40 ± 7.32
E	Myocardial infarction with distilled water	57.58 ± 15.77	76.54 ± 1.45

Values are mean ± standard error of mean

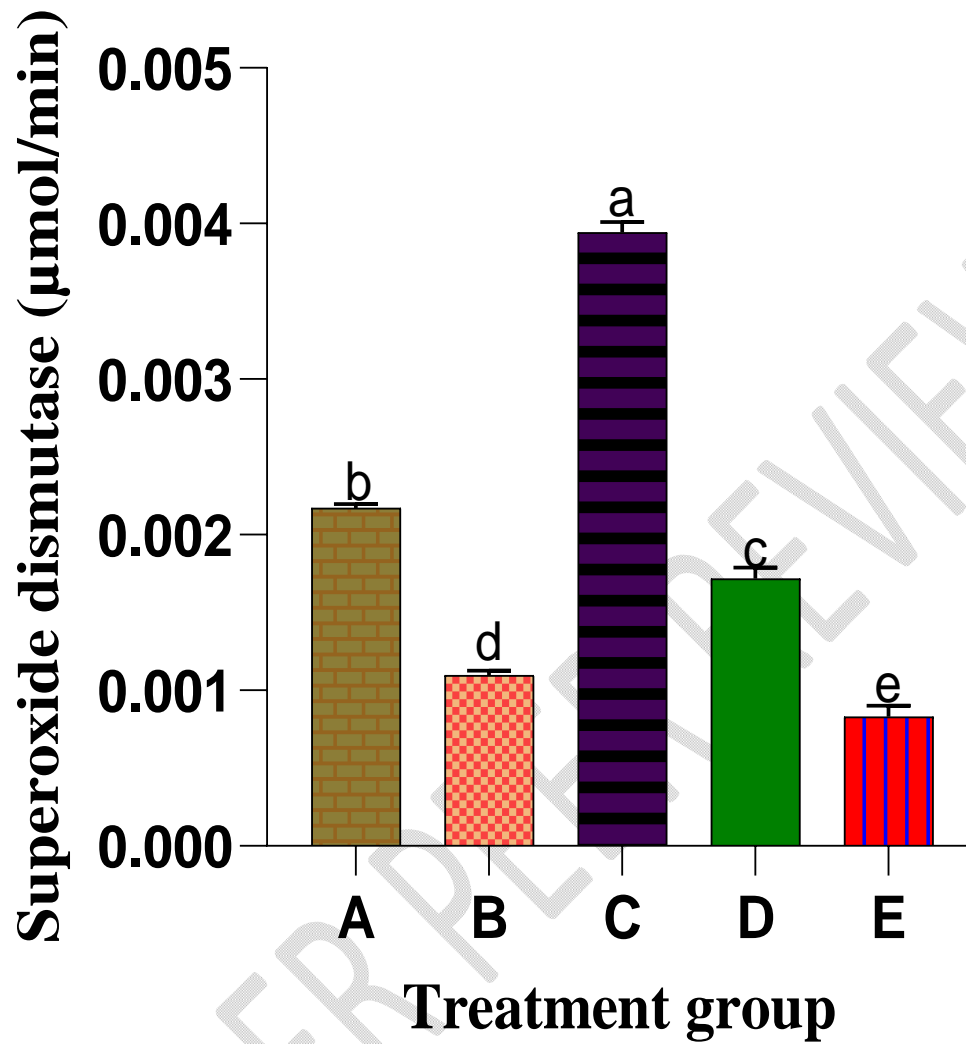


Figure 4: Effect of *A. paniculata* leaf extract on the activity of superoxide dismutase in isoproterenol-induced myocardial infarction

Columns with different alphabets are significantly different at $P < 0.05$

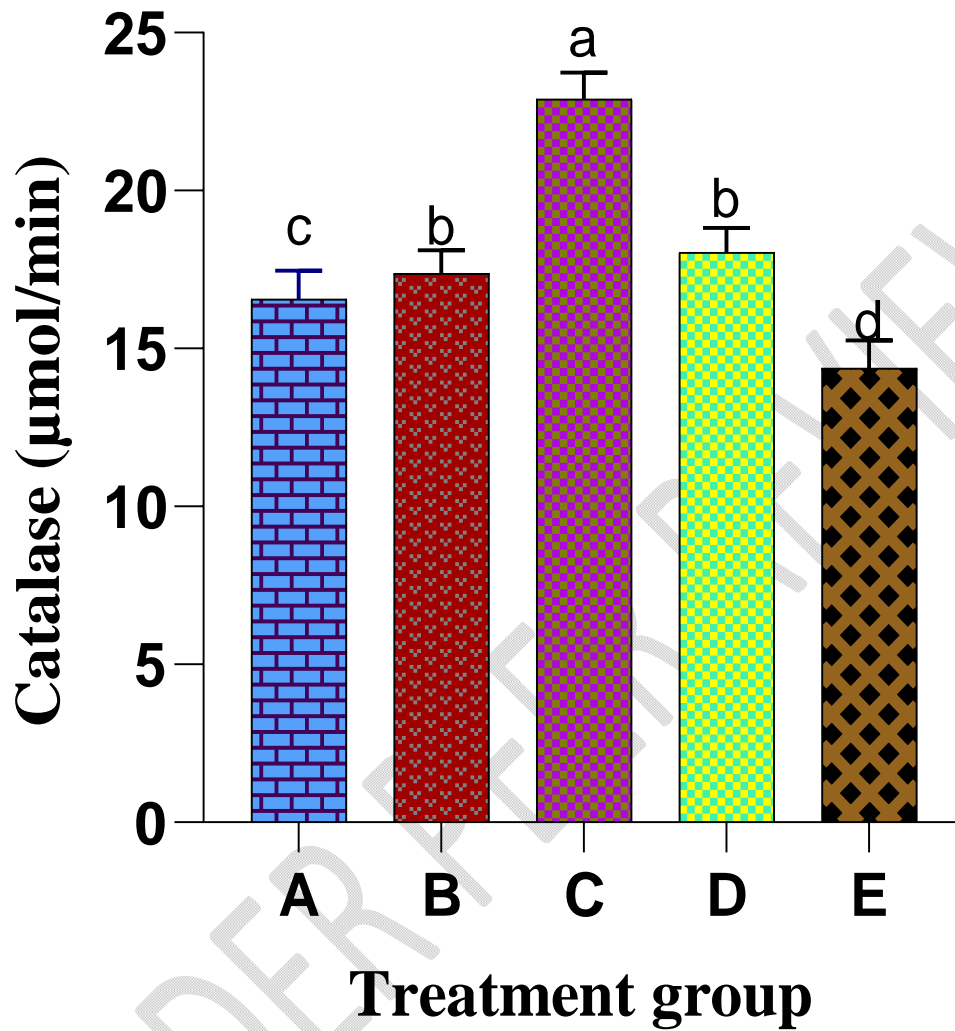


Figure 5: Effect of *A. paniculata* leaf extract on the activity of Catalase in isoproterenol-induced myocardial infarction

Columns with different alphabets are significantly different at $P < 0.05$

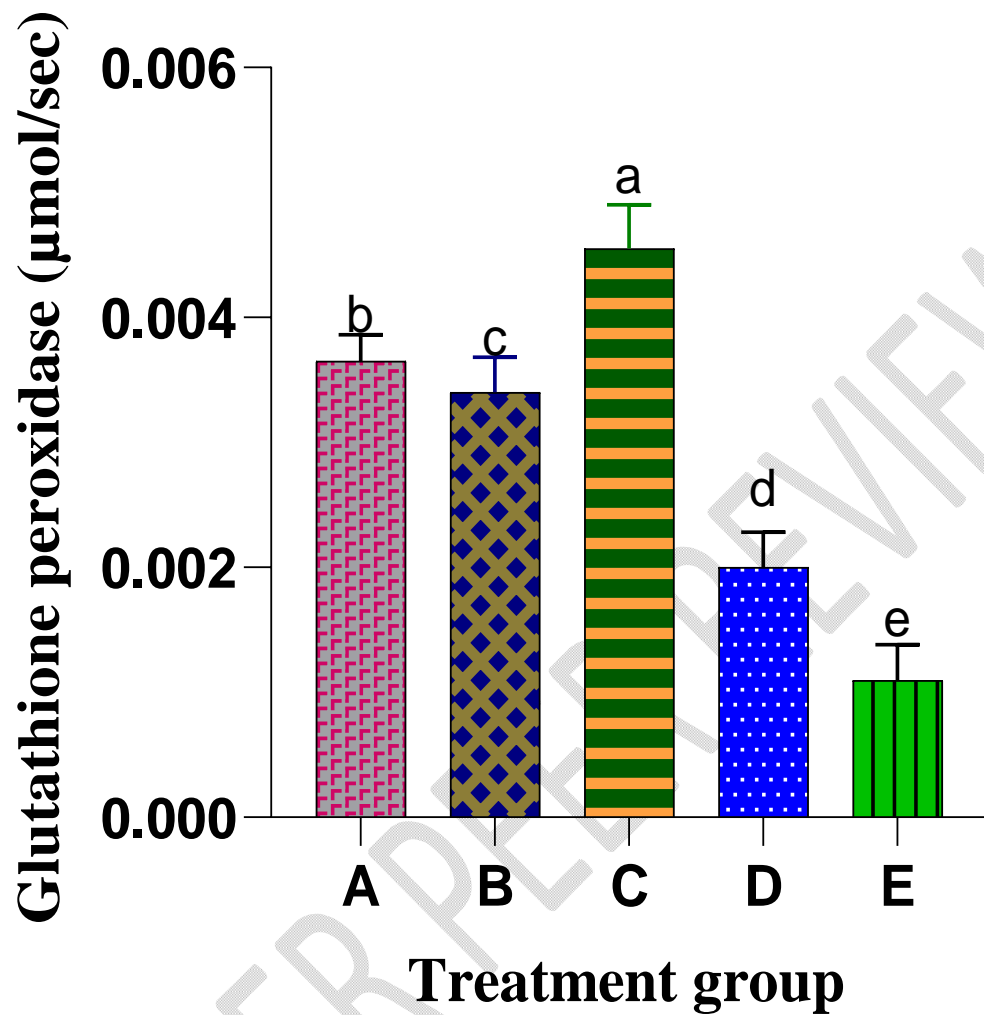


Figure 6: Effect of *A. paniculata* leaf extract on the activity of glutathione peroxidase in isoproterenol induced myocardial infarction

Columns with different alphabets are significantly different at $P < 0.05$

DISCUSSION

Medicinal plants especially *Andrographis paniculata* has long been used for the treatment and prevention of many ailments [19] because they have been adjudged to be rich source of phytochemicals and other bioactive substances [20].

Phytochemical analysis of plants remains crucial in evaluating their therapeutic index. Hence, the quantitative phytochemical analysis of the leaves of *Andrographis paniculata* were carried out and a number of bioactive compounds including 2,5-Octadecadiynoic acid, methyl ester; 1,2,3,5-Cyclohexanetetrol,(1à,2á,3à,5á)-;10-12-Pentacosadiynoic acid; 2H-Pyran, 2-(7-heptadecynyloxy)tetrahydro-2H-pyran; 1,3-Propanediol, 2-(hydroxymethyl)-2-nitro-; 3-O-Methyl-d-glucose; Dibutyl phthalate; Phytol; Hexanedioic acid, bis(2-ethylhexyl) ester as well as Nitric acid, nonyl ester were identified in the plant sample.

The plant was found to be rich in 2, 5-Octadecadiynoic acid methyl ester (28.21%) (table 2). This is consistent with the report of Kalaiselvan *et al.* [21]. 2,5-Octadecadiynoic acid methyl ester is an unsaturated fatty acid which have been shown to play a significant role in the prevention and treatment of cardiovascular disorders, auto immune diseases as well as aiding learning ability [22].

The 1, 3-Propanediol, 2-(hydroxymethyl)-2-nitro- content (7.22 %) (table 2) in the plant samples implies that its leaves could be used as a disinfectant. Clinical studies have suggested that these health-promoting components affect the immune systems in ways that help to protect the human body against infectious diseases [23].

Another compound found in appreciable quantity in the plant is 3-O-Methyl-d-glucose (6.02 %); a non-metabolizable glucose analogue that is not phosphorylated by hexokinase. 3-O-Methyl-d-

glucose is used as a marker to assess glucose transport by evaluating its uptake within various cells and organ systems.

Other compounds such as Dibutyl phthalate (2.11 %), Phytol (2.54 %) and Hexanedioic acid, bis (2-ethylhexyl) ester (1.02 %) (Table 2) are present in minute quantities. This is consistent with the findings of Imad *et al.* [24].

In the present study, isoproterenol-induced myocardial injury has been shown to produce a significant cardiac dysfunction as evidenced by decreased mean arterial pressure (MAP) and heart rate (HR) after isoproterenol administration (table 3).

A. paniculata pretreatment significantly prevented the decrease in MAP and HR (determinants of myocardial oxygen demand), thereby decreased workload and facilitated the heart to maintain myocardial oxygen balance in ischemic tissues. This aligns with the report of Ojha *et al* [15]. Restoration of altered MAP and HR also increased blood flow through the sub-endocardial region, which bears the maximal burnt of ischemic insult in isoproterenol-induced myocardial infarction. The pretreatment with *A. paniculata* might have improved the perfusion to sub endocardium. Similar assertion was made by Mohammad *et al.* [25] and Peng *et al.* [26] in their separate studies.

Although AST and ALT are not specific enzymes for MI because of their wide distribution in the body, they can be used as an early predictor of tissue damage. In this study, we observed an increase in the serum activities of AST and ALT in rats induced with isoproterenol (figures 2 and 3). The release of cellular enzymes reflects the alterations in plasma membrane integrity and/or permeability as a response to α -adrenergic stimulation [27]. This might be because of the damage caused to the sarcolemma by the α -agonist that has rendered it leaky. Isoproterenol induction has been shown to produce free radicals via adrenoceptor mechanism and affects the cell metabolism

to such a degree that cytotoxic free radicals are formed, producing myocardial necrosis [28]. Extract of *A. paniculata* decreased the activities of these enzymes in serum. This could be because of the protective effect of plant extract on the myocardium, thus reducing the cardiac damage thereby restricting the leakage of these enzymes.

Creatinine kinase (CK-MB) and lactate dehydrogenase (LDH), localized in myocytes, are released during isoproterenol-induced irreversible myocardial injury and are considered as characteristic of cardiac muscle injury [29]. The reduction in the leakage of CK-MB and LDH enzymes from heart as evidenced by increased levels of CK-MB and LDH in heart tissue is suggestive of the cardioprotective effect of *A. paniculata* pretreatment.

Various researches have reported the use of high concentration of isoproterenol in the induction of severe to chronic oxidative stress and this has been shown to result in necrotic lesions in the myocardium of rats [30]. The increased generation of ROS and/or depletion of the antioxidants in the defense system may contribute to oxidative stress and affect the pathogenesis of MI [31]. Free radical scavenging enzymes such as superoxide dismutase (SOD), catalase (CAT) and glutathione peroxidase (GPx) are the first-line cellular defence against oxidative stress [32], eliminating reactive oxygen radicals such as superoxide anion and hydrogen peroxide, and preventing the formation of more reactive radical of hydroxyl radical [20]. In this study, rats pretreated the extract of *A. paniculata* showed increased activities of these enzymes, which strongly suggested that the plant extract has the ability to check the deleterious effects of free radicals in isoproterenol-induced rats. This corroborates the assertion of Sivakumar and Rajeshkumar [33] that *A. paniculata* enhanced antioxidant enzymes.

CONCLUSION

The results from this research showed that the ethanol leaf extract of *A. paniculata* has a protective effect on isoproterenol-induced myocardial infarction; hence, the plant could serve as cheap alternative for the prevention and treatment of cardiovascular related disorders especially myocardial infarction.

UNDER PEER REVIEW

REFERENCES

1. Taggart, C., Wereski, R., Mills, N. L., Chapman, A. R. (2021). Diagnosis, Investigation and Management of Patients with Acute and Chronic Myocardial Injury. *Journal of Clinical Medicine*,10:2331.
2. Onwubuya, E. I., Ahaneku, G. I., Analike, R. A., Agbo, J. S., Ahaneku, J. E. and Oladejo, A. A. (2021). Cardiovascular Risk Factor Profile among Public Servants in a Developing Country: A Look at the Prevalence of Metabolic Syndrome in a Nigerian University Community. *Asian Journal of Research in Cardiovascular Diseases*, 3(2): 32-46.
3. Cediël, G., Gonzalez-del-Hoyo, M., Carrasquer, A., Sanchez, R., Boqué, C. and Bardají, A. (2017). Outcomes with type 2 myocardial infarction compared with non-ischæmic myocardial injury. *Heart*, 103:616–622.
4. Kadesjö, E., Roos, A., Siddiqui, A., Desta, L., Lundbäck, M. and Holzmann, M.J. (2019). Acute versus chronic myocardial injury and long term outcomes. *Heart*, 105:1905–1912.
5. Bardají, A., Bonet, G., Carrasquer, A., Gonz, M., Ali, S. and Boqu, C. (2019). Clinical Features and Prognosis of Patients with Acute and Chronic Myocardial Injury Admitted to the Emergency Department. *American Journal of Medicine*, 132:614–621.
6. Sostres, C., Gargallo, C. J., Lanas, A. (2013). Nonsteroidal anti-inflammatory drugs and upper and lower gastrointestinal mucosal damage. *Arthritis Research and Therapy*, 15(3): S3.
7. Onwubuya E.I. and Oladejo, A. A. (2022). Possible Effects of Free Radical Scavengers on Dissolution of Inflammatory Granuloma: An Experience with Wistar Rats. *Current Research in Complementary and Alternative Medicine*, 5(149):1-8.

8. Lowin, T., Tingting, R., Zurmahr, J., Classen, T., Schneider, M. and Pongratz, G. (2020). Cannabidiol (CBD): A killer for inflammatory rheumatoid arthritis synovial fibroblasts. *Cell Death and Disease*, 11:1–11.
9. Pucci, C., Martinelli, C. and Ciofani, G. (2019). Innovative approaches for cancer treatment: current perspectives and new challenges. *Ecancer Medical Science*, 13: 961.
10. Febrika, W., Gumilar, A. N., Zahra, F., Berna, E., Heri, S. and Tjandrawati, M. (2020). Hypoglycemic Effect of a Combined *Andrographis paniculata* and *Caesalpinia sappan* Extract in Streptozocin-Induced Diabetic Rats. *Advances in Pharmacological and Pharmaceutical Sciences*, 2(9):1-9.
11. Eugenie, M., Annabelle, C., Eric, L., Brigitte, L., Sabine, B-R. and Hechmi, T. (2019). Andrographolide, a Natural Antioxidant: An Update. *Antioxidants* 8:571.
12. Nkafamiya, I. I., Maina, H. M., Osemeahon, S. A. and Modibbo, U. U. (2010). Percentage oil yield and physiochemical properties of different groundnut species (*Arachis hypogaea*). *African Journal of Food Science*, 4(7):418-421.
13. Uchegbu, R. I, Bako S. S, Ngozi-Olehi, L. C. and Achinihu, I. O. (2015). GC-MS Analysis and Identification of Phytochemicals Present in the Fruits of *Mormodica balsamina* Linn. *Journal of Applied Chemistry*, 8(8): 39-42.
14. Lorke, D. (1983). A new approach to practical acute toxicity testing. *Archives of Toxicology*, 54:275–87.
15. Ojha, S.K., Nandave, M., Kumari, S. and Ary, D.S. (2009). Antioxidant activity of *Andrographis paniculata* in ischemic myocardium of rats. *Global Journal of Pharmacology*, 3:154-157.

16. Rotruck, J.T., Pope, A.L, Ganther, H.E., Swanson, A.B. and Hafeman, D.G. (1973). Selenium: Biochemical role as a component of glutathione peroxidase. *Science* 179: 588-590.
17. Kakkar, P., Das, B. and Viswanathan, P.N. (1984). A modified spectrophotometric assay of superoxide dismutase. *Indian Journal of Biochemistry and Biophysics*, 21:130–132.
18. Sinha, A.K. (1972). Colorimetric assay of catalase. *Anal Biochem* 47: 389-394.
19. Adeoye, B.O., Ajibade, T.O., Oyagbemi, A.A., Omobowale, T.O., Yakubu, M.A., Adedapo, A.D., Ayodele, A.E. and Adedapo, A.A. (2019). Cardioprotective effects and antioxidant status of *Andrographis paniculata* in isoproterenol-induced myocardial infarction in rats', *Journal of Medicinal Plants for Economic Development* 3(1): a49.
20. Oladejo, A.A., Onwubuya E.I., Ogbunugafor, H. A., Okafor, C.S. and Ogbodo, C.U. (2021). Inhibitory Effects of *Bryophyllum pinnatum* Leaf Extract on Inflammatory Biomarkers. *Journal of Advances in Medical and Pharmaceutical Sciences*, 23(2): 7-13.
21. Kalaiselvan, A., Gokulakrishnan, K. and Anand, T. (2012). Gas chromatography-Mass spectrum analysis of bioactive components of the ethanol extract of *Andrographis paniculata*. *Journal of Pharmaceutical and Biomedical Sciences*, 20(15):1-4.
22. Sirisha, N. and Rao, T. R. (2016). Lipid Profiles of Five Varieties *Artocarpus* Seed Oils by GC MS- A Comparative Study. *International Journal of Advanced Research*. 4(11): 1251-1257.
23. Lorent, J.H., Quetin-Leclercq, J. and Mingeot-Leclercq, M.P. (2020). The Amphiphilic Nature of Saponins and their Effects on Artificial and Biological Membrane and Potential

Consequences for Red Blood and Cancer Cells. *Organic and Biomolecular Chemistry*, 12:8803-8822.

24. Imad, H.H., Huda, J.A. and Salah, A.I. (2016). *Artemisia annua*: Biochemical products analysis of methanolic aerial parts extract and anti-microbial capacity. *Research Journal of Pharmaceutical, Biological and Chemical Sciences*, 7(2): 1843.
25. Mohammad, A.B.N., Abdul, M., Mohammad, N., Kamrujjaman, K.M. and Samir, K.D. (2017). Indigenous king of bitter (*Andrographis paniculata*): A review. *Journal of Medicinal Plants Studies*, 5(2): 318-324.
26. Peng, S., Gao, J., Liu, W., Jiang, C., Yang, X., Sun, Y., Guo, W. and Xu, Q. (2016). Andrographolide ameliorates OVA-induced lung injury in mice by suppressing ROS mediated NF- κ B signaling and NLRP3 inflammasome activation. *Oncotarget*, 7:80262-80274.
27. Dianita, R., Jantan, I., Amran, A.Z. and Jalil, J. (2015). Protective effects of *Labisia pumila* var. *alata* on biochemical and histopathological alterations of cardiac muscle cells in isoproterenol-induced myocardial infarction in rats', *Molecules* 47:4746–4763.
28. Upaganlawar, A. and Balaraman, R., (2011). Cardioprotective effects of *Lagenaria siceraria* fruit juice on isoproterenol-induced myocardial infarction in Wistar rats: A biochemical and histoarchitecture study. *Journal of Young Pharmacists*, 3: 297– 303.
29. Berg, D.D. Wiviott, S.D. Braunwald, E., Guo J, I.m. K. , Kashani , A., Gibson, C.M., Cannon, C.P. Morrow, D.A. Bhatt, D.L. (2018). Modes and timing of death in 66 252 patients with non-ST-segment elevation acute coronary syndromes enrolled in 14 TIMI trials. *European Heart journal*. 39(42):3810-3820.

30. Yerra, L., Anavekar, N., Skali, H., Zelenkofske, S., Velazquez, E. and McMurray, J. (2006). Association of QRS duration and outcomes after myocardial infarction: The VALIANT trial. *Heart Rhythm*, 3(3):313–316.
31. Sawyer, D.B., Siwik, D.A., Xiaol, L., Pimentel, D.R., Singh, K. and Colucci, W.S. (2022). Role of oxidative stress in myocardial hypertrophy and failure. *Journal of Molecular and Cellular Cardiology*, 34 (4): 379–388.
32. Onwubuya, E. I., Ogbunugafor, H.A., Okafor, C.S., and Oladejo, A.A. (2021). Acute and Chronic Anti-inflammatory effect of *Bryophyllum pinnatum* Leaf Extract on Wistar Rats. *European Journal of Medicinal Plants*, 32(6): 6-14.
33. Sivakumar, V. and Rajeshkumar, S. (2015). Protective effect of *Andrographis paniculata* on hyperglycemic mediated oxidative damage in renal tissues of diabetic rats. *Journal of Phytopharmacology*, 4(6): 287–294.