

Case study

Ischemic cerebral infarction following thrombolytic therapy for acute inferior myocardial infarction : the third reported case

Abstract

Background : Ischemic stroke following thrombolysis for ST-segment elevation myocardial infarction(STEMI) is a rare and perplexing complication. We present an intriguing case of ischemic stroke following fibrinolytic therapy with tenecteplase for a STEMI.

This is an extremely rare condition, and our case appears to be the third one reported in our department. The three cases had one thing in common: ST-segment elevation in the inferior leads.

Case presentation: We describe the case of a 50-year-old north-african woman who suffered an acute inferior STEMI 6 hours after chest pain onset. Thrombolysis with tenecteplase was performed and few hours later an extensive right sylvian artery stroke occurred with subfalcine herniation.

Decision-making : The refractory intracranial hypertension despite medical therapy compelled a decompressive craniectomy. On the follow up, neurological deficits had increased, congestive heart failure developed, and finally the patient died on the tenth day in the intensive care unit.

Conclusion : Hemorrhagic complications are not the only one, ischemic stroke can also occur after thrombolysis even if it is extremely odd. The pathophysiology is still poorly established.

The prevalent implication of the inferior territory in the three cases described in the literature may open to future research prospects.

Keywords : acute ST-elevation myocardial infarction, thrombolytic therapy, ischemic stroke, complication of treatment.

Background :

ST-elevation myocardial infarction (STEMI) is a life-threatening condition caused by acute occlusion of the infarct-related coronary artery. Primary treatment is the restoration of complete antegrade flow by percutaneous coronary intervention (PCI).

Early reperfusion therapy with tissue plasminogen activator (tPA) for STEMI is a viable option when access to PCI is limited. All thrombolytic agents use the same mechanism to convert plasminogen to plasmin, which then activates the fibrin degradation pathway. The efficacy and safety of the various thrombolytics have been well documented in large clinical trials. Intracranial hemorrhage is the most threatening complication of thrombolytic therapy.

Acute ischemic stroke after the use of tPA is a rare complication with unknown incidence that is rarely reported. Few cases have been reported in the literature, and the mechanisms are still unclear.

Case presentation :

A 50-year-old female patient presented to the emergency department with severe constrictive chest pain radiating to the upper limbs. There was a 4-hour interval between the onset of pain and admission to the hospital. She was a smoker, did not have diabetes, was not hypertensive or dyslipidemic, and had no history of stroke. She had no personal or family history of cardiac disease or arrhythmia and was not receiving treatment before diagnosis. At the time of admission, she was conscious, with a Glasgow Coma Scale (GCS) score of 15/15 and no motor deficits or sensory disturbances. The patient's physical examination showed no signs of heart failure, heart sounds were auscultated with no cardiac or carotid murmur, and her blood pressure was 137/80 mmHg symmetric. Peripheral pulses were perceived symmetrically. The rest of the examination was completely normal.

Electrocardiography revealed a regular rhythm of 85 beats per minute (bpm) and ST-segment elevation in leads D2, D3, and AVF (fig. 1). Because PCI was not available at that time, tenecteplase (intravenous bolus of 35 mg for a weight of 65 kg) was administered in conjunction with 300 mg p.o. aspirin and 300 mg p.o. clopidogrel. It is important to remember that the first dose of heparin was omitted. Laboratory results were as follows: Creatinine kinase-MB: 183 UI /l, troponin HS: 1284.7 ng/ml, normal liver function tests, glomerular filtration rate (GFR) according to the Modification of

Diet in Renal Disease (MDRD) method at 87 ml/1.73 m² body surface area (BSA) per minute; hemoglobin, 15.4 g/dl; platelet count, 280,000/mm³; white blood cell (WBC) count, 20,110 mm³; and C-reactive protein (CRP), 3.9 mg/l.

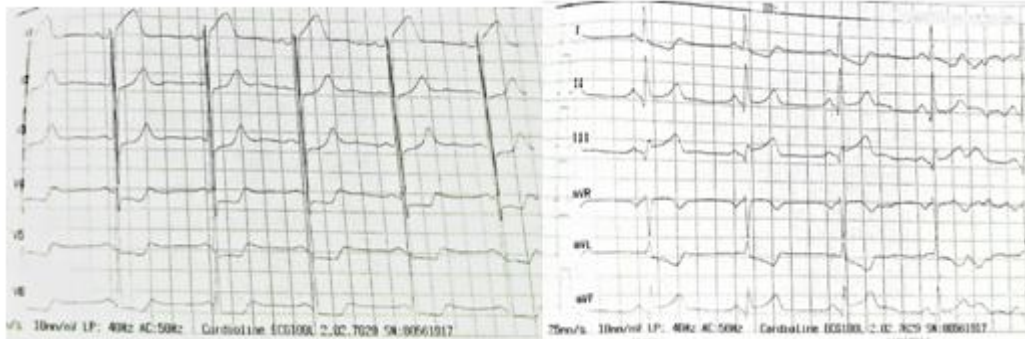

Fig. 1 : Electrocardiogram with inferior lead ST elevations and reciprocal depressions.

After therapy, an echocardiographic examination was performed at the bedside. It revealed segmental wall motion abnormalities, an ejection fraction of 45%, no mitral or aortic valve regurgitation, a 25 mmHg pulmonary artery pressure, and no thrombus or mechanical complication was detected. One hour later, she developed left hemiplegia with dysarthria and drowsiness: GCS of 13/15, NIH stroke scale of 12/42. The first cerebral CT, performed 1 hour later, showed hypodensity of the right lentiform nucleus and cortical sulcal effacement without hemorrhagic infarct. Neurologists were consulted about the case, aspirin (75 mg o.d.) and clopidogrel (75 mg o.d.) were continued, but heparin was discontinued. An echo-Doppler of the supra-aortic vessels was normal.

At follow-up, neurologic deficits had increased with a GCS of 7/15. On the second CT, 12 hours later, an extensive right middle cerebral artery (MCA) stroke with subfalcine herniation was detected (Fig. 2). The refractory intracranial hypertension despite medical therapy, forced a decompressive craniectomy. Her neurologic condition progressively worsened, congestive heart failure developed and finally, the patient passed away on the tenth day in the intensive care unit.

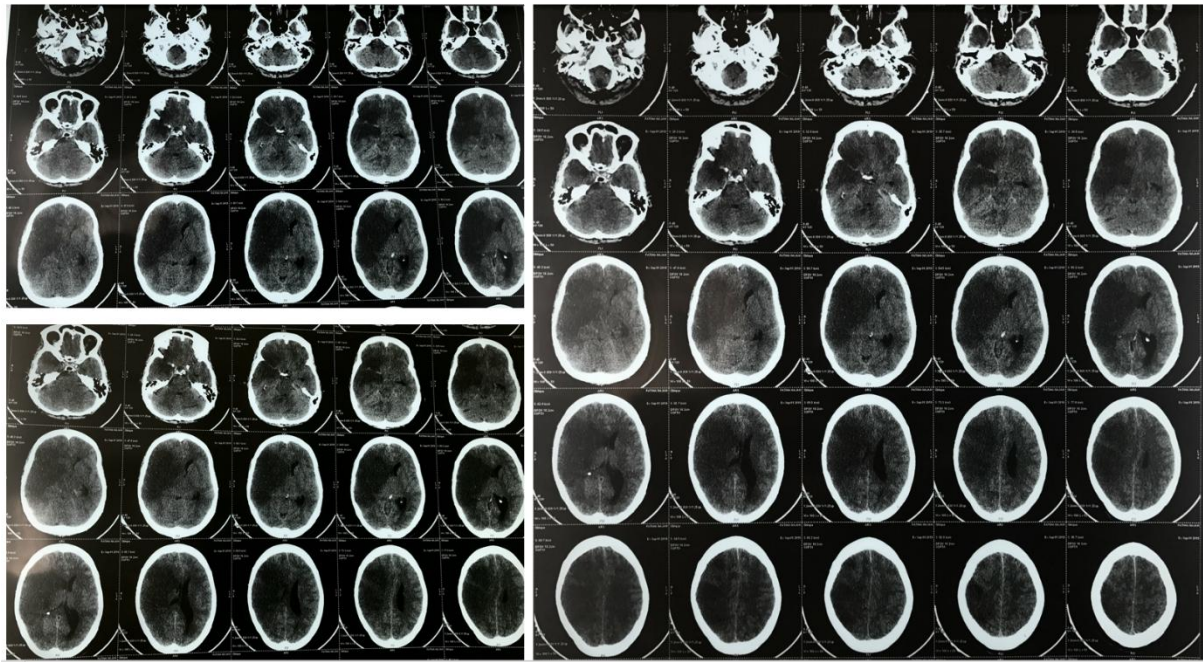


Fig. 2 : CT scan showing a right sylvian artery stroke with subfalcine herniation.

Discussion :

Our case shows a clear temporal relationship between the administration of tPA and the occurrence of ischemic stroke. The event was delineated under direct observation, making this unusual phenomenon unique. At the time of admission and initial evaluation for myocardial infarction, the patient had normal neurologic status. The rapid onset of right hemiplegia and the results of CT scans were suggestive of ischemic stroke. In a few published cases, the acute onset of ischemic stroke within 1 hour of thrombolytic therapy has been rarely documented.

Thrombolytic therapy, like all therapeutic options, has limitations and complications. Bleeding, particularly intracranial hemorrhage is the most serious and feared complication of fibrinolytic therapy. Bleeding after fibrinolytic treatment is caused by depletion of clotting factors and lysis of newly formed platelet plugs[1,2].

Although cerebrovascular accident (CVA) is a relatively rare consequence of acute myocardial infarction (AMI), it is associated with a significant risk of morbidity and mortality. An observational study of the Nationwide Inpatient Sample found a 2% rate of cerebrovascular accidents (ischemic stroke: 1.47%, transient ischemic attack: 0.35%, and hemorrhagic stroke: 0.21%) among the 1,924,413 patients admitted for acute myocardial infarction [3,4]. Despite this lower rate, CVA during hospitalization was associated with an in-hospital mortality rate 3.4 times higher than in patients who

did not have CVA [2,5]. Female sex, age older than 65, black race, anterior or apical wall motion abnormalities, atrial arrhythmias, heart failure, and reduced left ventricular ejection fraction were all risk factors for stroke after an AMI [1,6]. Witt et al.[7] discovered that anterior MI was a risk factor for stroke after MI. Anterior wall MI can lead to potential focal dyskinesia leading to left ventricular aneurysm or thrombus complication, which is estimated to occur in one-third of people within the first two weeks after an anterior wall MI [8,9]. In another analysis, anterior wall MI was associated with an increased risk of stroke (AOR, 1.16; 95% CI, 1.10-1.22; p=0.001). Echocardiographic studies indicate that most patients with visible mural thrombi have anterior wall infarction, whereas patients with good left ventricular function and inferior wall infarction rarely have detectable thrombi [10–12]. Substance abuse, including alcohol abuse and cocaine abuse/dependence, has also been linked to post- MI CVA [13]. The majority of cases were attributed to cerebral embolism [6,11].

Regarding MI type, analysis of the American Nationwide Inpatient Sample revealed that STEMI was associated with a higher risk of CVA, ischemic stroke, and overall hemorrhagic stroke than NSTEMI [3,14]. Surprisingly, NSTEMI was found to be a significant risk factor for transient ischemic attack. Other studies have shown that ischemic stroke is the most common type of stroke in patients with NSTEMI, whereas ICH accounts for a significant proportion of STEMI strokes after thrombolysis. CVA and AMI share several risk factors, including hypertension, hypercholesterolemia, smoking, diabetes, and advanced age [10,13,15]. Furthermore, the pathophysiology of AMI may predispose patients to stroke through several mechanisms, including emboli during revascularization, atrial fibrillation, or other arrhythmias associated with AMI, or blood stasis and thrombi in a poorly functioning left ventricle [16,17].

The pathophysiological processes underlying ischemic stroke after a coronary event are multifactorial. Ischemia causes a systemic procoagulant effect that promotes cardiac thrombus and embolism formation. In addition, ischemia causes the release of inflammatory cytokines that can cause plaques in the cerebral circulation to destabilize and rupture [18–20]. In some cases, this has been explained by the procoagulant effect of thrombolytic agents after thrombolysis.

In this case, although no thrombus was detected on echocardiographic examination, it is likely that thrombolytic therapy triggered embolization of undetected microthrombi

that had formed in the left ventricle or from carotid plaques and caused cerebral infarction [1,17].

Management of antithrombotic treatment and bleeding risk in acute stroke after administration of tPA in a cardiac event is particularly complex. Kajermo et al. discovered coronary artery bypass graft (CABG) as a risk factor for stroke (AOR, 1.64; 95% CI: 1.32-2.03; p=0.001) and PCI as predictor of reduced stroke risk (AOR, 0.69; 95% CI: 0.62-0.76; p=0.001) in AMI patients [11,21]. In addition, Uchechukwu et al. [22] discovered that the use of PCI was a negative risk factor for stroke in AMI patients (AOR, 0.64; 95%CI: 0.48-0.85; p=0.002).

Conclusion :

Stroke after thrombolysis for STEMI is an extremely rare clinical condition with significantly higher morbidity and mortality. Acute and chronic heart disease as well as inflammation may play a role in short-term stroke events.

We recommend that physicians be aware of this rarely documented but potentially fatal side effect of thrombolytic therapy.

List of abbreviations :

STEMI : ST-segment elevation myocardial infarction ; NSTEMI : non ST-elevation myocardial infarction ; PCI : percutaneous coronary intervention ; CABG : coronary artery bypass graft ; CVA : cerebrovascular accident ; AMI : acute myocardial infarction ; MCA : middle cerebral artery ; GFR : glomerular filtration rate ; GCS : Glasgow Coma Scale ; tPA : tissue plasminogen activator ; MDRD : Modification of Diet in Renal Disease.

Availability of data and materials :

The published information is available from the corresponding author on reasonable request.

Ethics approval and consent to participate :

This study was conducted in accordance with the fundamental principles of the Declaration of Helsinki.

Consent for publication :

Written informed consent was obtained from the patient for the publication of this case report and any accompanying images. A copy of the written consent is available for review by the Editor-in-Chief of this journal.

References :

1. BOSTAN M, KANAT AA, SEN M, KAZDAL I, HABIB B. Cerebral embolism following thrombolytic therapy for acute myocardial infarction: the second reported case. *Cardiovasc J Afr.* 2010 Jun;21(3):155–7.
2. Mohmand B, Naqvi A, Singh A. Paradoxical Myocardial Infarction After Thrombolytic Therapy for Acute Ischemic Stroke. *Cureus.* 13(7):e16659.
3. Naderi N, Masoomi H, Mozaffar T, Malik S. Patient Characteristics and Comorbidities Associated With Cerebrovascular Accident following Acute Myocardial Infarction in the United States. *Int J Cardiol.* 2014 Aug 1;175(2):323–7.
4. Bateman BT, Schumacher HC, Boden-Albala B, Berman MF, Mohr J p., Sacco RL, et al. Factors Associated With In-Hospital Mortality After Administration of Thrombolysis in Acute Ischemic Stroke Patients. *Stroke.* 2006 Feb;37(2):440–6.
5. Sloan MA, Price TR, Terrin ML, Forman S, Gore JM, Chaitman BR, et al. Ischemic Cerebral Infarction After rt-PA and Heparin Therapy for Acute Myocardial Infarction. *Stroke.* 1997 Jun;28(6):1107–14.
6. Behar S, Tanne D, Abinader E, Agmon J, Barzilai J, Friedman Y, et al. Cerebrovascular accident complicating acute myocardial infarction: Incidence, clinical significance, and short-long-term mortality rates. *Am J Med.* 1991 Jul 1;91(1):45–50.
7. Witt BJ, Ballman KV, Brown RD, Meverden RA, Jacobsen SJ, Roger VL. The Incidence of Stroke after Myocardial Infarction: A Meta-Analysis. *Am J Med.* 2006 Apr 1;119(4):354.e1-354.e9.
8. Arous S, Haboub M, El Ghali Benouna M, Bentaoune T, Habbal R. Ischemic stroke complicating thrombolytic therapy with tenecteplase for ST elevation myocardial infarction: two case reports. *J Med Case Reports.* 2017 Jun 11;11(1):154.
9. Lamas GA, Vaughan DE, Pfeffer MA. Left ventricular thrombus formation after first anterior wall acute myocardial infarction. *Am J Cardiol.* 1988;62(1):31–5.
10. Kassem-Moussa H, Mahaffey KW, Graffagnino C, Tasissa G, Sila CA, Simes RJ, et al. Incidence and characteristics of stroke during 90-day follow-up in patients stabilized after an acute coronary syndrome. *Am Heart J.* 2004 Sep 1;148(3):439–46.
11. Tanne D, Goldbourt U, Zion M, Reicher-Reiss H, Kaplinsky E, Behar S. Frequency and prognosis of stroke/TIA among 4808 survivors of acute myocardial infarction. The SPRINT Study Group. *Stroke.* 1993 Oct;24(10):1490–5.

12. Vaitkus PT, Barnathan ES. Embolic potential, prevention and management of mural thrombus complicating anterior myocardial infarction: A meta-analysis. *J Am Coll Cardiol*. 1993 Oct 1;22(4):1004–9.
13. Kajermo U, Ulvenstam A, Modica A, Jernberg T, Mooe T. Incidence, Trends, and Predictors of Ischemic Stroke 30 Days After an Acute Myocardial Infarction. *Stroke*. 2014 May;45(5):1324–30.
14. Maggioni AP, Franzosi MG, Farina ML, Santoro E, Celani MG, Ricci S, et al. Cerebrovascular events after myocardial infarction: analysis of the GISSI trial. Gruppo Italiano per lo Studio della Streptochinasi nell'Infarto Miocardico (GISSI). *BMJ*. 1991 Jun 15;302(6790):1428–31.
15. Jakobsson S, Bergström L, Björklund F, Jernberg T, Söderström L, Mooe T. Risk of Ischemic Stroke After an Acute Myocardial Infarction in Patients With Diabetes Mellitus. *Circ Cardiovasc Qual Outcomes*. 2014 Jan;7(1):95–101.
16. Hess DC, D'Cruz IA, Adams RJ, Nichols FT. Coronary artery disease, myocardial infarction, and brain embolism. *Neurol Clin*. 1993;11(2):399–417.
17. Fruster V, Halperin JL. Left Ventricular Thrombi and Cerebral Embolism. *N Engl J Med*. 1989 Feb 9;320(6):392–4.
18. Gore JM, Sloan M, Price TR, Randall AM, Bovill E, Collen D, et al. Intracerebral hemorrhage, cerebral infarction, and subdural hematoma after acute myocardial infarction and thrombolytic therapy in the Thrombolysis in Myocardial Infarction Study. Thrombolysis in Myocardial Infarction, Phase II, pilot and clinical trial. *Circulation*. 1991;83(2):448–59.
19. Hachet O, Guenancia C, Stamboul K, Daubail B, Richard C, Béjot Y, et al. Frequency and Predictors of Stroke After Acute Myocardial Infarction. *Stroke*. 2014 Dec;45(12):3514–20.
20. Sloan MA, Price TR, Terrin ML, Forman S, Gore JM, Chaitman BR, et al. Ischemic cerebral infarction after rt-PA and heparin therapy for acute myocardial infarction: the TIMI-II pilot and randomized clinical trial combined experience. *Stroke*. 1997;28(6):1107–14.
21. Kaarisalo MM, Immonen-Räihä P, Marttila RJ, Salomaa V, Torppa J, Tuomilehto J. The risk of stroke following coronary revascularization—a population-based long-term follow-up study. *Scand Cardiovasc J*. 2002;36(4):231–6.
22. Sampson UK, Pfeffer MA, McMurray JJ, Lokhnygina Y, White HD, Solomon SD. Predictors of stroke in high-risk patients after acute myocardial infarction: insights from the VALIANT trial. *Eur Heart J*. 2007;28(6):685–91.