

Case study

Asymptomatic acute dissection of the abdominal aorta as a rare complication of Takayasu disease

Abstract :

Aortic dissection is a rare complication of Takayasu's disease, reported in few times in the literature; we report the case of a 24-year-old, who presented an asymptomatic acute dissection of the abdominal subrenal aorta with an inflammatory syndrome, indicative of Takayasu disease. The type of aortic dissection (type III b, according to the classification of De Bakey and Stanford) confirmed by angioscan in our patient. The patient underwent conservative medical treatment.

Keywords: Takayasu's disease, Asymptomatic Aortic dissection, abdominal subrenal aorta, Angioscan

Introduction :

Takayasu's arthritis (TA) is a large vessel vasculitis involving the aorta and its major branches. The clinical presentation varies between the finding of an absent pulse (pulse less disease) due to occlusive lesions or aneurysmal disease due to inflammatory bulges in the arterial wall. What is apparent from the literature is aortic dissection (AD) is a rarely observed feature of TA (1), this report is a case of a 24-year-old female presenting with acute complicated type AD

Case report :

Mrs. Z.B, 24 years old, with a history of anemia in childhood that was not investigated. She presented to the emergency room for a facial fracture and a mandibular fracture secondary to an aggression, with the fortuitous discovery of hemodynamic instability during the surgical procedure, requiring to stop the procedure. The patient did not report any chest pain or abdominal pain.

On clinical examination the patient had a blood pressure asymmetry between the 2 upper limbs. Blood Pressure=158/58 mmHg right upper limb and 94/61 mmHg left upper limb, Heart Rate= 75bpm, without murmur on cardiac auscultation with bilateral carotid murmurs, left subclavian murmur, murmur at the abdominal level and at the renal arteries course. Intermittent claudication of both lower limbs, the peripheral pulses were decreased in both lower limbs without signs of ischemia (right systolic pressure index= 0.8, left systolic pressure index= 0.9) with a decrease in the left radial pulse compared to the right side. The

rest of the clinical examination: pulmonary, neurological, osteoarticular and dermatological was unremarkable.

Electrocardiogram is in RRS at 75bpm, electrical left ventricular hypertrophy with Cornell score at 25 mm

A thoraco-abdominal CT scan was performed urgently with diffuse intimal thickening of the thoraco-abdominal aorta, raising the suspicion of vasculitis , responsible for a significant stenosis of the left common carotid artery(CCA), partial thrombosis of the right primary iliac artery with the presence of a 14-mm dissection of the supra- and sub-renal abdominal aorta lateralized on the right (Figure 1).

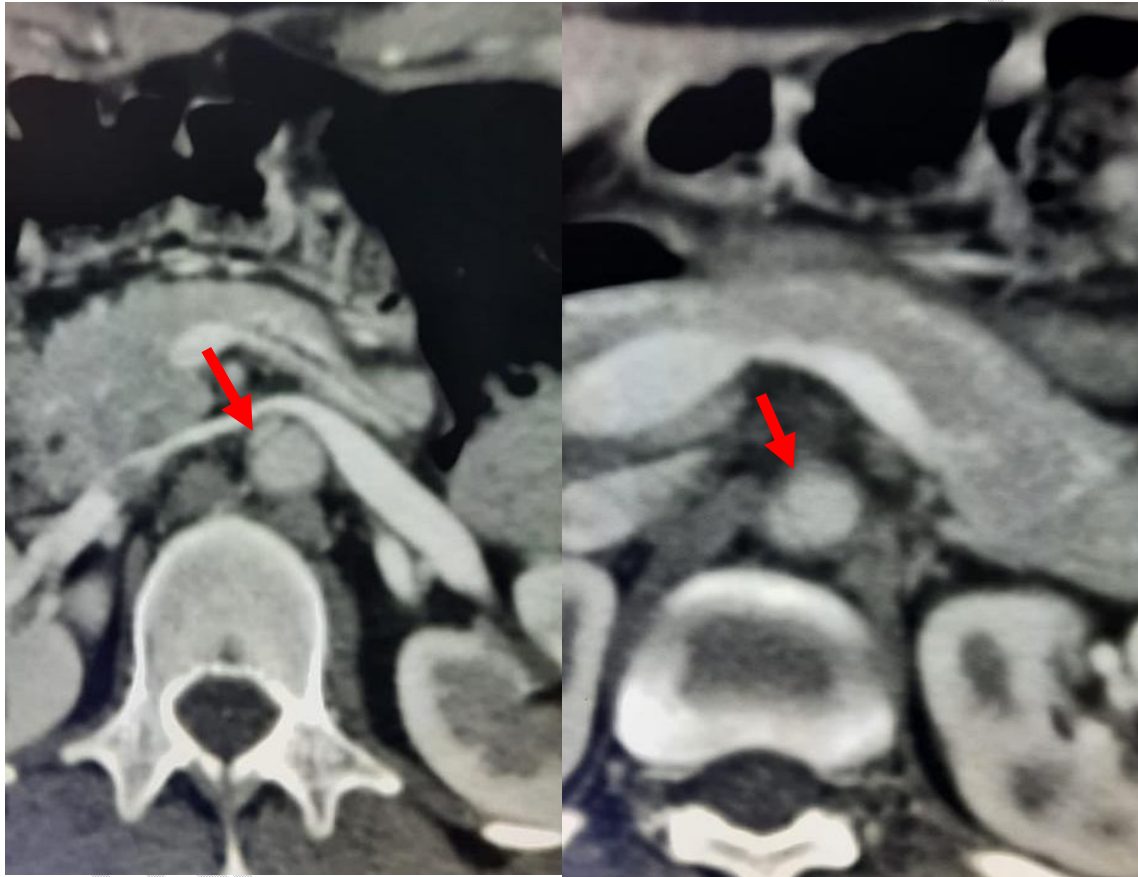


Figure 1: Presence of a 14-mm dissection of the supra- and sub-renal abdominal aorta lateralized on the right.

Emergency surgery was ruled out because of the location of the dissection and the absence of ischemic manifestations.

Arterial Doppler of the supra-aortic trunk and upper extremities:

Right side:

- Common carotid artery(CCA): diffuse parietal thickening of 2.2 mm, with subocclusion at its middle part with moderately demodulated flow downstream (Figure 3 et 4).
- Internal carotid artery (ICA): diffuse parietal thickening without significant stenosis, with good flow

Left side :

- Common carotid artery(CCA): significant parietal thickening with demodulated flow with presence of collateral circulation
- Internal carotid artery (ICA) and external carotid artery(ECA): diffuse parietal thickening without stenosis with moderate demodulated flow
- Subclavian : tight stenosis at its origin VSM: 639 cm/s with demodulated flow downstream (Figure 2)
- Radial: normal flow but decreased compared to the right
- Brachial: no stenosis with moderate demodulated flow

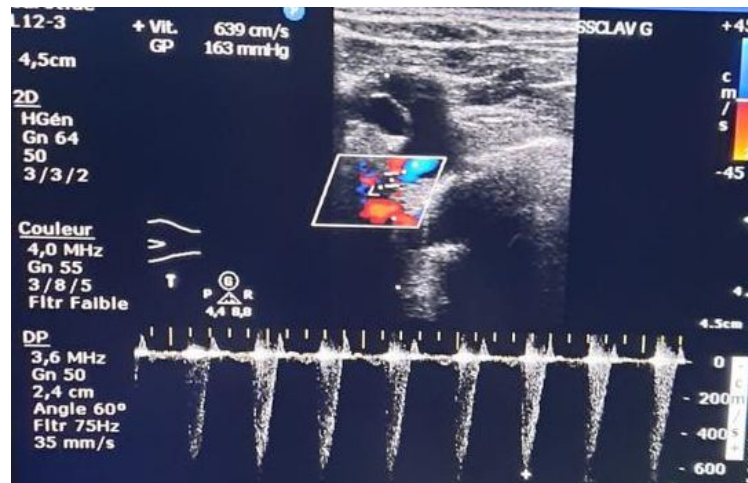


Figure2: Stenosis of the left subclavian artery SMV=639 cm/s

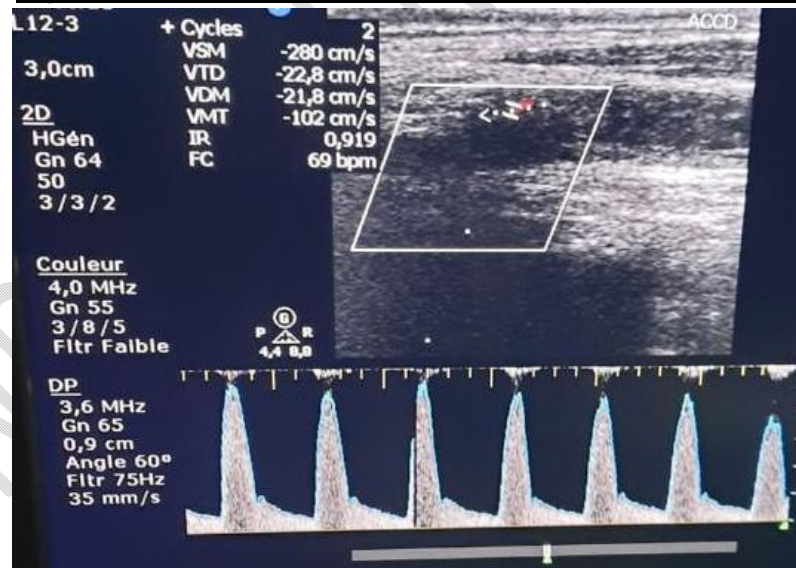


Figure 3 : Tight stenosis of the right common carotid artery with circumferential intimal thickening

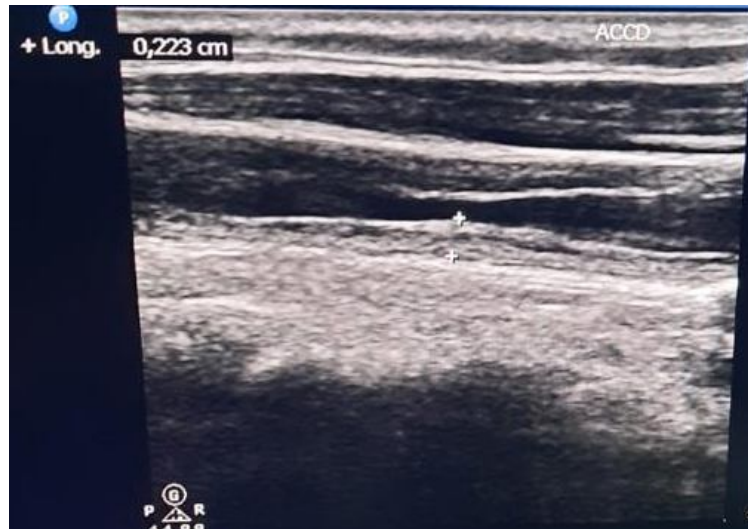

Figure 4 : circumferential parietal thickening of the right common carotid artery of 2.2mm

Abdominal aorta echography:

- Supra-renal abdominal aorta: Diffuse parietal thickening with normal flow.
- Subrenal aorta: Presence of a tight stenosis with presence of collaterality

Trans-thoracic echocardiography:

- Concentric hypertrophy
- LVEF: 64%
- Moderate Aortic regurgitation .
- Initial dilated aorta with no detectable intimal flap image on this day
- The aortic arch is dilated without detectable intimal flap
- Initial 26mm abdominal aorta with 4mm diffuse calcified intimal thickening

Biological check-up: normocytic normochromic anemia at 10.1g/dl, Wight blood cells: 9460 g/dl with neutrophilic polynuclear cells: lymphocytes: 2240, platelet cells: 357000, inflammatory work-up: C-reactive protein (CRP) elevated to 42.9mg; ferritinemia: 33; accelerated sedimentation rate (VS) at 79mm first hour; normal hepatic work-up, normal renal function, negative viral serologies and negative immunological tests.

At the end of the clinical and paraclinical examination and considering the criteria of the American College of Rheumatology, the diagnosis of Takayasu disease was retained. Medical treatment was based on corticosteroid therapy 1mg/kg/d with adjuvant treatment + Methotrexate 25mg/week, with control of heart rate and blood pressure by calcium channel blockers and beta-blockers.

The evolution was marked by clinical improvement with blood pressure and biological control (inflammatory work-up), the control angioscanner showed the same radiological image. The progressive decrease of the corticosteroid therapy was started after one month of initial treatment, with biological and radiological monitoring.

Discussion :

This patient had a classic clinical and arteriographic finding of TA, as defined by the American College of Rheumatology classification criteria, which were primarily designated to distinguish this disorder from other forms of vasculitis (2). These criteria, include:

- 1) Age of onset younger than 40 years;
- 2) Claudication of the extremities;
- 3) Decreased pulsation of one or both brachial arteries;
- 4) Difference of at least 10 mmHg systolic pressure between arms;
- 5) Bruits over one or both subclavian arteries or the abdominal aorta; and
- 6) Arteriographic narrowing or occlusion of the entire aorta, its primary branches, or large arteries in the proximal upper or lower extremities, not caused by arteriosclerosis, fibromuscular dysplasia, or other causes.

The diagnosis is most likely when three of these six criteria are met (2). Our patient had 6 criteria (1,2, 3, 4, 5 and 6) of these criteria. In addition, clinical and serological workups did not support the presence of other large-vessel or medium-vessel vasculitis.

Other than non specific inflammatory symptoms, AT maybe complicated by either ischemic symptoms attributed to stenotic lesions or by aortic wall disruption, dilation, and dissection(3). Systemic hypertension maybe associated with a higher risk for arterial vessel wall dissection, a rare but life threatening complication which is less common in pediatric than in adult TA. Discrepancy of any of four limbs blood pressure >10 mm Hg (which constitutes a classification criteria) as well as bruits over aorta and its major branches are present in over 50% of patients. Aortic type B dissection in the setting of Takayasu disease represents an unusual and challenging situation, as the marked thickening of the wall, due to the fibrosis of the intima and adventitia, renders the vessel enough impervious to dissection or rupture and often difficult to manage through conventional surgical approach(4).

Diagnostic evaluation of vasculitis relies on non invasive imaging: color Doppler ultrasound is the method of choice for evaluating aortic vessel involvement, whereas computed tomography and cardiovascular magnetic resonance are useful in assessing the thoracic and abdominal aorta; positron emission tomography imaging allows direct visualization of the extent of vascular inflammation(5).

The essential imaging finding is the mural thickening of an arterial segment, typically smooth, circumferential, and exceeding 3 mm, forming the « macaroni » sign. This aspect is found at 97% in the preocclusive phase, with a high prevalence in the carotid and subclavian arteries (6; 7)

Our patient presents a non aneurysmal and asymptomatic dissection Stanford type B of the subrenal aorta sparing the iliac arteries (Figure 1). Dissection Stanford type B is more frequent than type A in association with Takayasu disease (8).

Medical treatment for Takayasu aortitis includes steroids and immunosuppressive drugs; recently. The goal of the medical treatment is inflammatory arterial decrease with the use of immunosuppressors: 50% respond to steroids and 50% to methotrexate. Many new biological

agents have been discovered for refractory cases, such as the interleukin-6 inhibitor tocilizumab (9). In our case, methotrexate induced an improvement in the inflammatory parameters (erythrocyte sedimentation rate, CRP); however, clinical and radiological signs remain stable.

The current consensus document on the management of type-B aortic dissection recommends medical treatment and imaging follow-up for uncomplicated patients (10). The surgical treatment indications of aortic dissection complicating Takayasu disease are not clearly defined, dominated by ischemic manifestations. Nevertheless, it is recommended to perform the surgery beyond the inflammatory phase of the disease (11).

Conclusion :

In conclusion, our patient with an abdominal aortic dissection is an example of the heterogeneity of vascular lesions in TA. Young patients with aortic dissection should be managed by a team including medical specialists in vascular pathologies, pathologists, and surgeons with experience in the management of this disease, to offer a highly individualized treatment and follow-up strategy.

Bibliographie :

1. Mason JC. Takayasu arteritis – advances in diagnosis and management. *Nat Rev Rheumatol* 2010; 6: 406–415.
2. Arend WP, Michel BA, Bloch DA, Hunder GG, Calabrese LH, Edworthy SM, et al. The American College of Rheumatology 1990 criteria for the classification of Takayasu arteritis. *Arthritis Rheum* 1990;33:1129–34.
3. Isobe M. Takayasu arteritis revisited: current diagnosis and treatment. *Int J Cardiol.* 2013;168:3–10. doi: 10.1016/j.ijcard.2013.01.022. 2.
4. Tyagi S, Nigam A. Aortic dissection: a rare presenting manifestation of Takayasu's aortitis. *Indian Heart J* 2008;60:58–60.
5. Czihal M, Förster S, Hoffmann U. Imaging diagnostics of large vessel vasculitis [in German]. *Radiologe.* 2010;50:855–860. doi: 10.1007/s00117-010-2001-1.
6. Mirault T, Messas E. La maladie de Takayasu. *Rev Med Int* 2016;37(4):223–9.
7. Ma LY, Li CL, Ma LL, Cui XM, Dai XM, Sun Y, et al. Value of contrast-enhanced ultrasonography of the carotid artery for evaluating disease activity in Takayasu arteritis. *Arthritis Res Ther* 2019;21:24.
8. Yang, KQ; Yang, YK; Meng, X; Zhang, Y; Zhang, HM and al (2017). *Aortic Dissection in Takayasu Arteritis. The American Journal of the Medical Sciences, 353(4), 342–352.*
9. Loricera J, Blanco R, Castañeda S, Humbría A, Ortego-Centeno N, Narváez J, Mata C, Melchor S, Aurrecochea E, Calvo-Alén J, Lluch P, Moll C, Mínguez M, Herrero-Beaumont G, Bravo B, Rubio E, Freire M, Peiró E, González-Vela C, Rueda-Gotor J, Pina T, Palmou-Fontana N, Calvo-Río V, Ortiz-Sanjuán F, González-Gay MÁ. Tocilizumab in refractory aortitis: study on 16 patients and literature review. *Clin Exp Rheumatol.* 2014;32(3 suppl 82):S79–S89.

10. Fattori R, Cao P, De Rango P, Czerny M, Evangelista A, Nienaber C et al. Interdisciplinary expert consensus document on management of type B aortic dissection. *J Am Coll Cardiol* 2013;61:1661–78.
11. Theresa K, Jean-Marc A, Jean-Paul DVH, Jean EF. Diagnosis and surgical treatment of a Takayasu disease on an abdominal aortic dissection. *Ann Vasc Surg* 2011;25:556

UNDER PEER REVIEW