

ACUTE AORTIC DISSECTION MASQUERADING A RARE TYPE OF CONGENITAL BICUSPID AORTIC : A CASE REPORT

Abstract

Acute aortic dissection on bicuspid aortic valve (BAV) type 0 is a rare especially in young masculine. Risk factors like smoking and intensive sport activities can hasten their apparition especially in non-diagnosed population. Trans thoracic echocardiography is very important in the diagnosis of BAV whereas Angio CT scan helps to confirm acute aortic dissection. Treatment is based on surgery for type A Stanford classification for acute aortic dissection. We report a rare case of acute aortic dissection masquerading a rare type of BAV, type 0 in a young sportive male with no history of heart disease who presented for the first-time with acute chest pain after lifting a heavy weight metal at the complex sport center. Patient was initially placed on medical treatment before surgery for heart valve and root replacement (Bentall procedure).

Key words: Aortic, bicuspid aortic valve, heart disease

Introduction

Type A aortic dissection is a potentially devastating complication that commonly presents for emergent cardiac surgery. It can be associated with aortic valve (AV) pathology such as bicuspid AV (BAV) or damaged leaflets [1]. BAV predisposes to the development of ascending/root dilatation, which may be associated with dissection and rupture of the aorta, even in the absence of marked aortic valve dysfunction [2]. Trans thoracic echocardiography is very important in the diagnosis of BAV, if default trans esophageal echocardiography helps in the confirmations of the number of aortic leaflets. Sometimes diagnosis can be retarded in case of concomitant suspicion of acute coronary syndrome especially this case in which a rapid dosage of the cardiac enzymes was not significative and symptoms presented by the patient was typic for aortic dissection.

Case Report

A 33-year-old young man was brought by a non-medical emergency service to the emergency department at 10:30 p.m. for onset discomfort secondary to sudden chest pain at a sport's complex venue. He had only personal history which is active smoking at 15 packet per year (PY) in withdrawal for less than 8 months. He has no notable family history, takes no treatment and is not followed for congenital heart disease. He reported the spontaneous onset of chest discomfort around 10:00 p.m. caused by sudden retrosternal chest pain radiating to both upper limbs after lifting heavy weights in the gym associated with significant functional symptoms (nausea, sweating).

The patient did not present any syncope symptoms but palpitations prior to the discomfort. Upon arrival at the emergency department, the patient was conscious and oriented with a Glasgow score of 15/15. He was afebrile, the systolic blood

pressure was measured at 190 mmHg, and the diastolic blood pressure at 100mmHg, his cardiac frequency at 115 beats per minute. He was polypneic, with a respiratory rate of 21 cycles per minute with a capillary oxygen saturation in ambient air at 96%. Cardiac auscultation found a 4/6 diastolic murmur at the aortic focus. The pulmonary examination was without abnormality. The peripheral pulses are well perceived and symmetrical. The abdomen was painful on palpation at the epigastric and periumbilical level without hepatosplenomegaly or palpable lymphadenopathy in the superficial lymph node areas. The electrocardiogram shows a regular sinus rhythm at 85 beats per minute, with no anomaly in the PR distance on the ECG, with the presence of biphasic T waves in leads V2 and V3 (Figure 1).

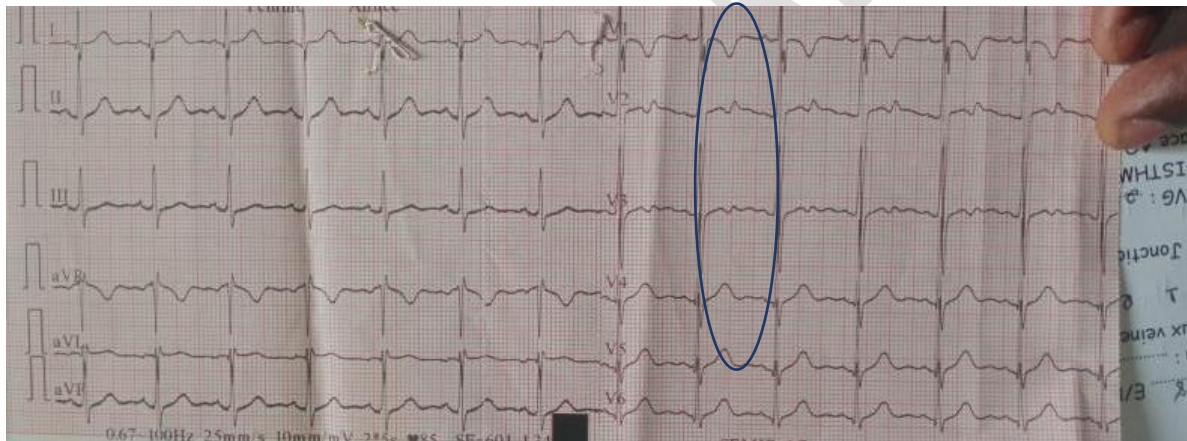


Figure 1; Electrocardiogram (ECG): Sinus rhythm with biphasic T waves in precordial leads V2 and V3.

Initially the diagnosis of acute coronary syndrome was evoked in front of the cardiovascular risk factors and acute chest pain symptoms presented by the patient. The initial biological assessment found a level of ultrasensitive troponins slightly elevated at 39.5 ng/l and D-Dimer at 1500.

In front of this clinical presentation, acute aortic dissection was suspected. The thoracic CT angiography with injection of contrast product confirms the diagnosis which objectified a Stanford type A aortic dissection on dilated initial segments of the aorta which extended to the supra-aortic trunk with the presence of hypodense areas at the level of segments VII and VIII of the liver, probable ischemic origins (Figure 2).

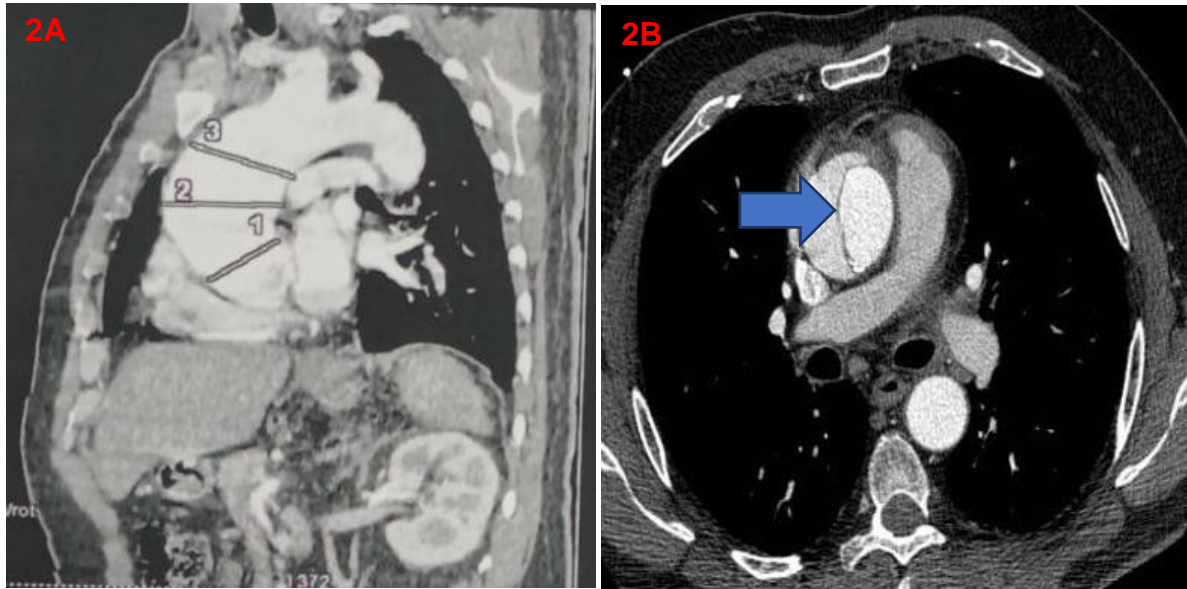


Figure 2A; CT angio-scan: showing dilation of the aorta at the aortic valve and sino-tubular junction associated with type A Stanford acute aortic dissection.

Figure 2B; CT angio-scan: transversal section passing through the thoracic vertebrae showing an aortic dissection type A Stanford (arrow)

The transthoracic echocardiography (TTE) performed showed a Stanford type A aortic dissection with an intimal flap 3mm from the outflow chamber of the left ventricle on a congenital heart disease of fortuitous discovery, bicuspid aortic type 0 antero-posterior on a left hypertrophied heart with good bi-ventricular function LVEF: 55% associated with moderate aortic insufficiency (PHT=474ms) of chronic appearance (Figures 3 and 4), responsible for the dilation of the aorta on its segments especially sinus of valsalva with obliteration of the sino-tubular junction and dilation of the ascending aorta with a diameter of 4.5 cm. The right cavities were unremarkable with a low probability of pulmonary hypertension. Absence of other cardiac abnormality.

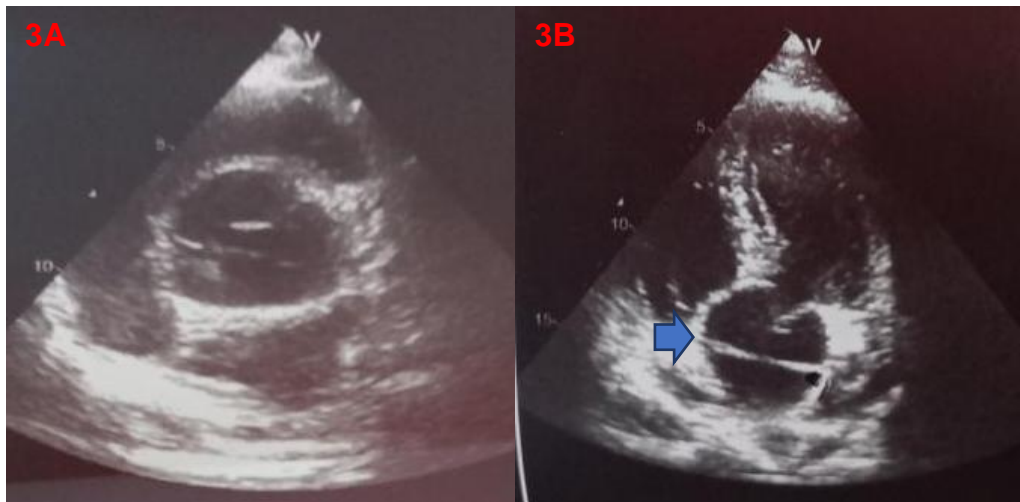


Figure 3; TTE: Short axis view: A- Aspect of bicuspid aortic valve type 0 antero-posterior associated with dilation of the initial segments of the aorta.

B- TTE; 4 chambers apical view: Intimal flap on the antero-posterior walls of the aorta 3mm from the outflow chamber of a dilated aorta.

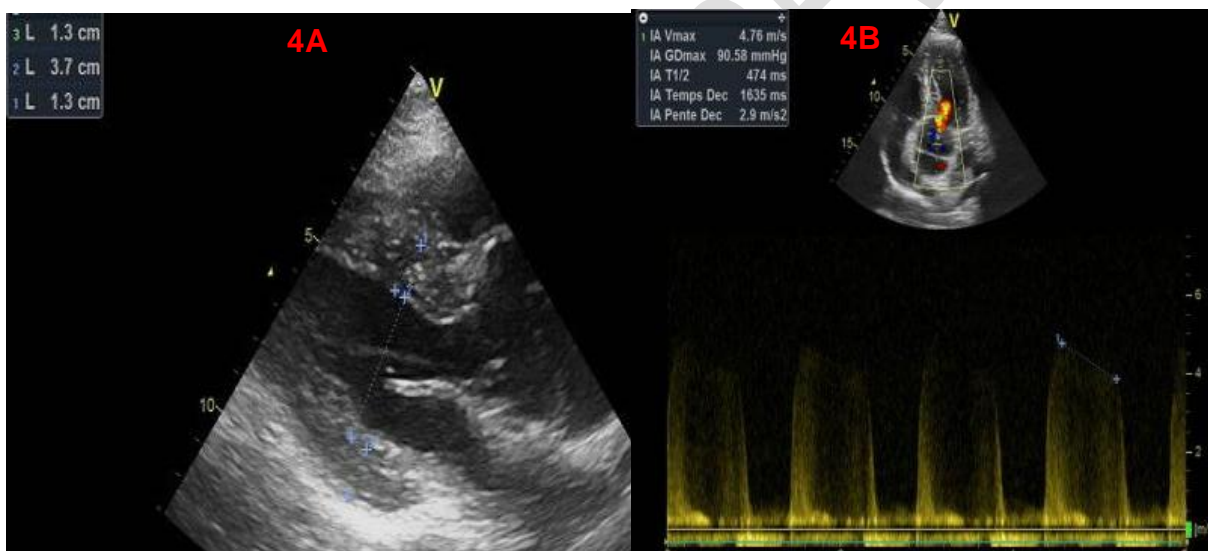


Figure 4A; TTE: Long axis view: Significant concentric left ventricle hypertrophy non obstructive without significant gradient trans ventricle

4B; Moderate aortic insufficiency with a PHT value of 474ms responsible for dilation of the thoracic aorta

Initially the patient was put on medical treatment in the first 48 hours with a beta-blocker (Zotrol=Atenolol), a dose of 100mg starting with a small dose up to the maximum tolerated dose with an objective heart rate of less than 60bpm and a calcium channel blocker (Amlodipine= Amep) dose of 10mg per day with an objective blood pressure less than 120mmHg systolic and 90mmHg diastolic. Pain management was based on injectable analgesics based on paracetamol (Perfalgan) by intravenous infusion.

The evolution was marked by stabilization of the blood pressure figures with slowing of the heart rate and sedation of pain by medical treatments.

The patient was proposed for Bentall-type surgery and aortic valve replacement which was delayed for 1 month since patient was asymptomatic 24 hours after medical treatment and lack of patient consent.

Discussion

The primary method of diagnosis for aortic dissection is either TTE or TEE with a sensitivity of 92% and specificity of 96% [3,4]. As the morphological characteristics of AVs are usually assessed by transthoracic echocardiography (TTE) or transesophageal echocardiography (TEE), however, the difference in the diagnostic ability of these imaging modalities to detect TAV remains unclear [13]. In this case, after dosage of cardiac enzymes for acute coronary syndrome which was not significant, CT aortogram was performed which concluded aortic dissection type A without confirmation of aortic bicuspid valve later discovered on the transthoracic echocardiography findings. Bicuspid aortic valve (BAV) disease is the most common congenital heart defect among the general population, and individuals with BAV have a considerably increased risk for aortic events [5]. However, in our case the patient presents a rare type of bicuspid aortic valve which is type 0 antero-post which accounts for 0,3% of all type of bicuspid aortic valve [6].

Other diagnostic modalities such as MRI, magnetic resonance angiography (MRA), and computed tomography (CT) enable views of the AV without interference from calcification [7], however in our case there was failure of description of the aortic valve in the results of the CT Angio scan.

Although the exact incidence is not known, it has been reported that the frequency of BAV in aortic dissection is approximately 4% of all cases [8]. It's rare in our routine practice to see patients with aortic dissection especially associated with BAV which make this case special as our patient intensive sportive activity was one of the leading factors of aggravating his asymptomatic non-diagnosed congenital heart disease. The incidence of aortic dissection was 0.1% per patient year of follow-up in a Toronto study involving more than 600 patients with a BAV [9]. Similarly, Michelena and colleagues [10] documented no increase in mortality or dissection over age-matched control subjects over a period of 20 years in a young adult cohort with a normal functioning BAV receiving routine cardiac care.

The patient was stabilized with medical therapy which rapidly resolved his acute chest pain and associated symptoms before surgery as its recommended by the ESC guidelines to indicate surgery in type A aortic dissection (class I Level A) [11]. Our patient was delayed for surgery since he had a moderate aortic regurgitation and absolutely asymptomatic after 24 hrs medical therapy and lack of patient consent for surgery.

It is important to note a high incidence of post-implantation RA, which appears to be mitigated by sizing the transcatheter aortic valve TAV based on MSCT. Given the suboptimal echocardiographic results, further study is needed to evaluate long-term efficacy.

Coronarography was not performed in our patients at the early stage after non-significant results of the cardiac enzymes for acute coronary syndrome as the increased in blood D-Dimers helped to orient the diagnosis for acute aortic dissection [11,12]. This case report study may contribute to the management of young and

symptomatic patients with acute chest pain and a sequence of clinical, graphic and imaging exams prescribed for emergency diagnosis.

Conclusion

Acute aortic dissection on bicuspid valve (BAV) type 0 is rare especially in young masculine. Risk factors like smoking and intensive sport activities can hasten their apparition especially in non diagnosed population. Angio CT -scan confirm diagnosis but transthoracic echocardiography plays an important role in identifying congenital heart disease non diagnosed by the angio-CT scan. Treatment for acute aortic dissection type A is emergency surgery except for unstable.

Ethical Approval:

As per international standard or university standard written ethical approval has been collected and preserved by the author(s).

Consent

As per international standard or university standard, patient(s) written consent has been collected and preserved by the author(s).

Reference

1. Harendra Arora, Priya Ajit Kumar, Aortic dissection masquerading as a bicuspid aortic valve. Department of Anesthesiology, University of North Carolina, Chapel Hill, North Carolina, USA. *Journal of Anaesthesiology Clinical Pharmacology*: 2017 ;33
2. Christian D., Konstantin von Aspern, Alexandro Hoyer, Felix F. Gurrbach, Sergey Leontyev, Farhad Bakhtiary, Martin Misfelda and Friedrich W. Mohr. Acute type A aortic dissection: characteristics and outcomes comparing patients with bicuspid versus tricuspid aortic valve. *European Journal of Cardio-Thoracic Surgery*: 2015; 48; 142–150
3. Michelena HI, Khanna AD, Mahoney D, Margaryan E, Topilsky Y, Suri R, Met al. Incidence of aortic complications in patients with bicuspid aortic Valves. *JAMA* 2011 ;306 :1104–12.
4. Davorin Sef, Stewart Brown, Omar A. Jarral, Azhar Hussain, Elizabeth Haslam, Cha Rajakaruna, Christopher J. McAloon. Subtle aortic dissection in a patient with severe aortic regurgitation and undiagnosed bicuspid aortic valve: A case report with a literature review. *J Card Surg*. 2021;1-4.
5. Maximilian Kreibich, Bartosz Rylski, Martin Czerny, Clarence Pingpoh, Matthias Siepe, Friedhelm Beyersdorf, Fabliha Khurshan, Prashanth Vallabhajosyula, Wilson Y. Szeto, Joseph E. Bavaria, Nimesh D. Desai and Emanuela Branchetti. Type A Aortic Dissection in Patients With Bicuspid Aortic Valve Aortopathy. *Ann Thorac Surg* 2019
6. Robicsek F, Thubrikar MJ, Cook JW, Fowler B. The congenitally bicuspid aortic valve: how does it function? Why does it fail? *Ann Thorac Surg* 2004;77:177–85.

7. Borger MA, Fedak PWM, Stephens EH, et al. The American Association for Thoracic Surgery consensus guidelines on bicuspid aortic valve-related aortopathy: full online-only version. *J Thorac Cardiovasc Surg* 2018;156(2):e41–74.
8. Januzzi JL, Isselbacher EM, Fattori R, Cooper JV, Smith DE, Fang J et al. Characterizing the young patient with aortic dissection: results from the International Registry of Aortic Dissection (IRAD). *J Am Coll Cardiol* 2004; 43:665–9.
9. Timothy B. Cotts, Katherine B. Saliccioli, Sara K. Swanson, Anji T. Yetman. Aortopathy in Congenital Heart Disease. *Cardiol Clin* 38 (2020) 325–336
10. Michelena HI, Desjardins VA, Avierinos JF, et al. Natural history of asymptomatic patients with normally functioning or minimally dysfunctional bicuspid aortic valve in the community. *Circulation* 2008;117(21):2776–84.
11. Raimund Erbel (Chairperson) (Germany), Victor Aboyans (Chairperson) (France), Catherine Boileau (France), Eduardo Bossone (Italy), Roberto Di Bartolomeo (Italy), Holger Eggebrecht (Germany), Arturo Evangelista (Spain), Volkmar Falk (Switzerland), Herbert Frank (Austria), Oliver Gaemperli (Switzerland), Martin Grabenwöger (Austria), Axel Haverich (Germany), Bernard Lung (France), Athanasios John Manolis (Greece), Folkert Meijboom (Netherlands), Christoph A. Nienaber (Germany), Marco Roffi (Switzerland), Hervé Rousseau (France), Udo Sechtem (Germany), Per Anton Sirnes (Norway), Regula S. von Allmen (Switzerland), Christiaan J.M. Vrints (Belgium). ESC Committee for Practice Guidelines (CPG): Jose Luis Zamorano (Chairperson) (Spain), Stephan Achenbach (Germany), Helmut Baumgartner (Germany), Jeroen J. Bax (Netherlands), Hector Bueno (Spain), Veronica Dean (France), Christi Deaton (UK), Çetin Erol (Turkey), Robert Fagard (Belgium), Roberto Ferrari (Italy), David Hasdai (Israel), Arno Hoes (The Netherlands), Paulus Kirchhof (Germany/UK), Juhani Knuuti (Finland), Philippe Kolh. 2014 ESC Guidelines on the diagnosis and treatment of aortic diseases Document covering acute and chronic aortic diseases of the thoracic and abdominal aorta of the adult The Task Force for the Diagnosis and Treatment of Aortic Diseases of the European Society of Cardiology (ESC) Authors/Task Force members. *European Heart Journal* 2014; 35, 2873–2926
12. Helmut Baumgartner (Chairperson) (Germany), Julie De Backer (Chairperson) (Belgium), Sonya V. Babu-Narayan (United Kingdom), Werner Budts (Belgium), Massimo Chessa (Italy), Gerhard-Paul Diller (Germany), Bernard Lung (France), Jolanda Kluijn (Netherlands), Irene M. Lang (Austria), Folkert Meijboom (Netherlands), Philip Moons (Belgium), Barbara J. M. Mulder (Netherlands), Erwin Oechslin (Canada), Jolien W. Roos-Hesselink (Netherlands), Markus Schwerzmann (Switzerland), Lars Sondergaard (Denmark), Katja Zeppenfeld (Netherlands). 2020 ESC Guidelines for the management of adult congenital heart disease The Task Force for the management of adult congenital heart disease of the European Society of Cardiology (ESC) Endorsed by: Association for European Paediatric and Congenital Cardiology (AEPC), International Society for Adult Congenital Heart Disease (ISACHD) Authors/Task Force Members. *European Heart Journal* :2021 ; 42, 563645
13. Flavien Vincent, Julien Ternacle, Tom Denimal, Mylène Shen, Bjorn Redfors, Cédric Delhayé, Matheus Simonato, Nicolas Debry, Basile Verdier, Bahira Shahim, Thibault Pamart, Hugues Spillemaecker, Guillaume Schurtz, François Pontana, Vinod H Thourani, Philippe Pibarot, Eric Van

Belle Transcatheter Aortic Valve Replacement in Bicuspid Aortic Valve Stenosis. *Circulation* 2021; 9; 1043-1061

UNDER PEER REVIEW