

## Case study

**Title:** Radiation-induced cataract in a hospital radiology staff.

### **ABSTRACT:**

Among the etiologies of cataracts, the action of ionizing radiation, known for a century, constitutes an original entity. Radiation-induced cataract seems to have to be considered from now on as a more frequent pathology than previously thought. Its original pathogenesis has both: certain specificities of deterministic effects: probable (but no longer certain) presence of a threshold, a certain proportionality of the severity of the effect with the dose, as well as certain specificities of stochastic effects: initial genomic damage that neither kills nor seriously damages the target cell but which will be transmitted to the cells of the lineage.

A worker is considered to be at risk insofar as he is likely to receive an equivalent dose to the lens of more than 150 mSv (milli-sieverts) per year. This is particularly the case for certain hospital staff, in interventional radiology.

Thus, to avoid ocular effects, professionals exposed to ionizing radiation must not only benefit from dosimetric monitoring to detect any excess of doses but also from regular ophthalmological monitoring, which will allow early diagnosis of these lens opacities.

It is also important to insist on the continuous training of workers in radiation protection. To this end, these workers must now wear leaded goggles (since they reduce the dose received by 80%).

**Keywords :** Cataract, ionizing radiation, radiation protection.

### **1. INTRODUCTION :**

Cataract is defined as a clouding of the lens leading to a decrease in visual acuity. Among the etiologies of cataracts, the action of ionizing radiation, known for a century, constitutes an original entity **(1)**.

We report a case of radiation-induced cataract in a hospital radiology professional to describe its pathogenesis, its clinical aspect in order to prevent it.

### **2. CASE REPORT:**

We report the case of a 38-year-old radiology staff with no particular history who consulted for a progressive decline in visual acuity in his right eye.

The ophthalmological examination finds: A visual acuity of 7/10 in his left eye, rising to 10/10 after correction, and an acuity of 10/10 in the right eye. Intraocular pressure is normal in both eyes. The oculomotor examination is without abnormality.

The slit lamp examination is normal in the right eye and shows in the left eye:

In diffuse lighting: we notice a clear cornea, a normal anterior chamber and a posterior subcapsular cataract (**Figure 1**). In section: the opacities of the posterior subcapsular region constitute a sort of plaque comprising granulations and yellowish vacuoles (**Figure 2**). Dilated fundus is normal in both eyes.

Given his good corrected visual acuity, the patient is fitted with corrective lenses. Phacoemulsification surgery with placement of an intraocular implant will be considered depending on the evolution.

### 3. DISCUSSION:

As early as the end of the 19th century, Chaluppecky suggested that the newly discovered X-rays could cause cataracts **(2)**. Thirty years later, Rohrschneider published the first clinical description of it: opacities of the posterior subcapsular region constituting a sort of plaque comprising granulations and vacuoles, sometimes yellowish in color and with a "beaten copper" appearance **(3)**.

The epithelial cells of the germinative zone (paramedian anterior subcapsular region of the lens) will constitute the specific targets of ionizing radiation. The irradiation will first be followed by an inhibition, of variable duration, of the mitotic activity of these cells. When mitosis resumes, and during the weeks following the irradiation, the daughter cells of the irradiated cells will migrate towards the "equatorial layers" of the lens where a first pathological aspect consists of a disorganization of the normally very regular arrangement of these cells. Subsequently, as the migration continues, dysmorphic fibrous cells that are still nucleated will begin to accumulate in the posterior subcapsular region. These cells, which will take on a rounded shape with a "bladder" appearance, often have a pyknotic nucleus (announcing their imminent death) and are called Wedl cells. These Wedl cells will then rupture, spill their eosinophilic contents, and scatter cellular debris among other seemingly intact cells. Dysmorphic cells may also begin to appear in the anterior cortex, eventually ending up occupying the periphery of the cortex. These cyto-architectural modifications are the basis of the alteration of the transparency of the lens **(1)**.

We can therefore see that radiation-induced cataract, through its original pathogenesis, has both:

- Certain specificities of deterministic effects: probable (but no longer certain) presence of a threshold, a certain proportionality of the severity of the effect with the dose;
- Certain specificities of stochastic effects: initial genomic damage which neither kills nor seriously damages the target cell but which will be transmitted to the cells of the line **(1)**.

In 1950, Merriam proposed a range between 5 and 15 Gy (Grays) likely to cause radiation-induced cataracts **(4)**. In 1957, Merriam and Focht, using an anthropomorphic dummy (skull of a human skeleton covered with wax and possessing an artificial crystalline lens equipped with a dosimetric device in the orbit), were able to carry out a relatively precise comparative dosimetry of the doses delivered to the lens of carriers of various tumors of the face: they proposed a threshold of 2 Gy in a single dose and 4 Gy in a divided dose and/or spread over time **(5)**. Time to onset is inversely proportional to dose and lengthened by dose splitting. It can vary between 6 months and 35 years; the average would be around 2 to 3 years **(4)**. With regard to cataractogenicity, experiments on rat lenses do not find any difference between the action of cobalt-60  $\gamma$  and that of X-rays with an energy (maximum) of 200 keV (kilo-electronvolt) **(6)**.

The International Commission on Radiological Protection (ICRP) considers radiation-induced cataract as a deterministic effect of ionizing radiation, that is to say as direct tissue damage, of gravity proportional to the dose received and only appearing from a certain rate of cells killed or severely impaired functionally **(7)**.

The dose required to achieve this minimum number of killed or severely damaged cells within the tissue constitutes the threshold for the effect in question. The order of magnitude of the radiation-induced cataract threshold is currently estimated at around 2 Grays. In reality, this threshold varies according to several parameters which are mainly the type of radiation, the dose rate, taking into account the simple observation of visible opacities with the slit lamp or taking into account alterations in visual function ("clinical" or symptomatic cataract). More specifically, the ICRP in its publication 103 gives the following thresholds **(8)**:

- for detectable opacities: { 0.5 to 2 Gy in single brief exposure, { 5 Gy in cumulative dose for very divided or spread out exposures;
- for impairment of function: { 5 Gy for single exposures, { > 8 Gy for cumulative exposures;
- from the point of view of radiation protection regulations, the labor code stipulates that: "for the lens, the exposure received during twelve consecutive months cannot exceed 150 mSv (milli-sieverts)" **(9)**.

A worker is considered to be at risk insofar as he is likely to receive an equivalent dose to the lens of more than 150 mSv per year ("public" dose). This is particularly the case for certain hospital staff, particularly in interventional radiology, where lens dosimetry can be performed by wearing a lithium fluoride pellet (thermoluminescent dosimeter) on the forehead. The doses received by the lens (without protection) by the worker (vascular radiologist and gastroenterologist, among others) vary, according to studies and practices, between 0.05 and 3.2 mSv per examination **(10)**. Wearing specific protection (lead glasses) is recommended, despite its restrictive nature (weight), for the most irradiating examinations, especially if they are frequent.

A recent American cohort study followed 35,705 electromanipulators in medical radiology, aged 24 to 44 and with healthy lenses at the start of the study, from 1983 to 2004 **(11)**. Two types of exposure were simultaneously studied:

- medical exposure: the fact of having themselves undergone 3 or more radiological examinations of the face and/or neck was correlated with a Relative Risk (R.R.) of 1.25 appearance of a cataract ( $1.06 < 95\% \text{ CI} < 1.47$ ), i.e. a 25% increase;
- occupational exposure: 2 groups have been defined; one having received an average of 60 mGy to the lens, the other 5 mGy. An R.R. of 1.18 ( $0.99 < \text{IC95} < 1.4$ ), either an excess relative risk of 18% of the appearance of a cataract, was found in the most exposed group.

In 1993, an American study examining the lens of 4,926 subjects established a significant association between the presence of posterior subcapsular opacities and the fact of having undergone a CT scan of the brain in their lifetime **(12)**. However, if we look at the order of magnitude of the dose delivered to the lens by such an examination, we realize that it is relatively moderate: Gambini gives 43.4 mGy (milli-grays) when the cutting plane passes through the orbits (the most irradiating case) **(13)**.

Thus, to avoid ocular effects, professionals exposed to ionizing radiation must not only benefit from dosimetric monitoring to detect any excess doses, but also from special medical surveillance. An ophthalmological examination must be required every six months. This regular ophthalmological monitoring will allow early diagnosis of these lens opacities and therefore early avoidance of exposure to ionizing radiation, particularly in the absence of compliance with exposure standards and the wearing of means of eye protection **(14)**.

To this end, these workers must now wear leaded goggles (since they reduce the dose received by 80%) like other personal protective equipment. These lead glasses can be adapted to the view. It is also important to insist on the continuous training of workers in radiation protection, which must be renewed periodically.

Finally, on the forensic level, this radiation-induced cataract was declared as an occupational disease. Nevertheless, all means must be implemented to avoid the appearance of this pathology **(15)**.

#### **4. CONCLUSION:**

Subject to confirmation by subsequent studies, radiation-induced cataracts now seem to have to be considered as a more frequent pathology than previously thought. In particular, the predictable onset thresholds probably deserve to be reassessed. Consequently, the protection and monitoring of populations exposed to this specific risk (essentially patients and workers) must be reinforced, if necessary. People competent in radiation protection have an important role to play in encouraging people to wear protective glasses, but also ophthalmologists and occupational physicians.

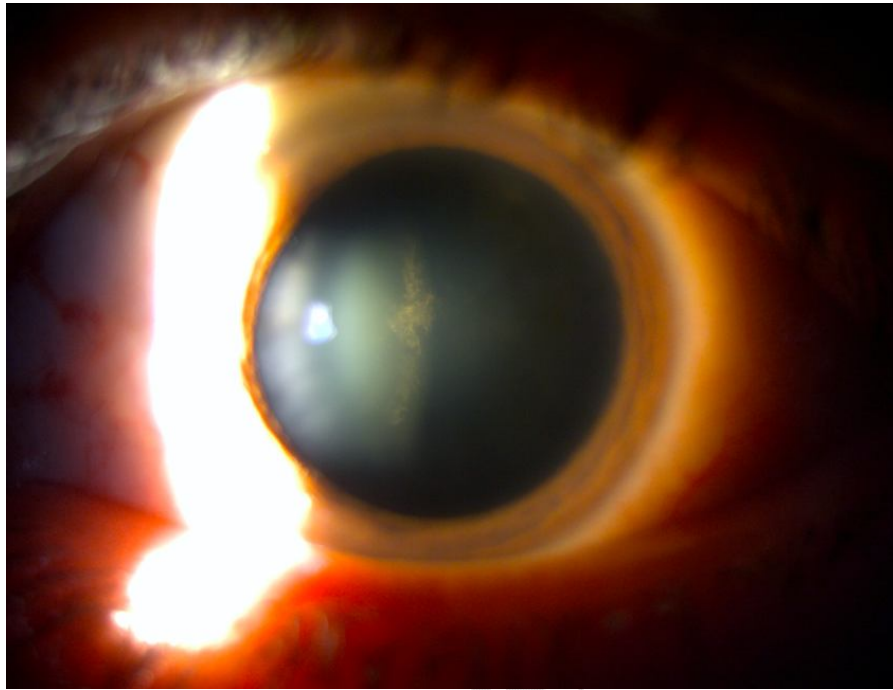
#### **CONSENT**

All authors declare that written informed consent was obtained from the patient for publication of this case report and preserved by the authors.

#### **ETHICAL APPROVAL**

As per international standard or university standard written ethical approval has been collected and preserved by the authors.

**FIGURES:**



**Figure 1:** Slit lamp examination of the right eye showing a posterior subcapsular cataract in diffused lighting.



**Figure 2:** In section: the opacities of the posterior subcapsular region constitute a sort of plaque comprising granulations and yellowish vacuoles.

**REFERENCES:**

1. S. Wassilieff. Cataract and ionizing rays. *Radioprotection* 2009. Vol. 44, no. 4, pages 505 to 517.
2. Chaluppecky H. (1897) Ueber die Wirkung der rontgenstrahlen auf das Auge und die Haut, *Z. Prakt. Augenheilk (Leipzig)* 21, 234-239.
3. Rohrschneider W. (1930) Experimentelle Katarakt Nach Mehrfacher Bestrahlung Mit Kleinen Rontgenstrahlendosen, *Ophth. Gesellach.* 48241-48244.
4. Merriam G.R. Jr., Worgul B.V. (1983) Experimental radiation cataract – Its clinical relevance, *Bull. N.Y. Acad. Med.* 59, 372-392.
5. Merriam G.R. Jr., Focht E.F. (1957) A clinical study of radiation cataracts and the relationship to dose, *Am. J. Roentgenol.* 77, 759-785.
6. Focht E.F., Merriam G.R. Jr., Schwartz M.S., Parsons R.W. (1968) The relative biological effectiveness of cobalt 60 gamma and 200 KV X-radiation for cataract induction, *Am. J. Roentgenol. Rad. ther. Nuc. Med.* 102, 71-80.
7. ICRP Publication 60 (1991) 1990 Recommendations of the International Commission on Radiological Protection – Users' Edition, *Ann. ICRP* 21(1-3).
8. ICRP Publication 103 (2007) Recommendations of the ICRP, *Ann. ICRP* 37(2-4).
9. Code du travail (2008) Edition du 1er mai 2008 – Article R.4451-13.
10. Aubert B., Paul D., Sabattier R. (1997) Dosimétrie du personnel en milieu hospitalier, *Radioprotection* 32, 163-179.
11. Chodick G. et al. (2008) Risk of cataract after exposure to low doses of ionizing radiation: A 20-year prospective cohort study among US radiologic Technologists, *Am. J. Epidemiol.* 168, 620-631.
12. Klein B.E.K., Klein R., Linton K.L.P., Franke T. (1993) Diagnostic X-ray exposure and lens opacities: The Beaver Eye Dam eye study, *Am. J. Publ. Health* 83, 588-590.
13. Gambini D.J., Granier R. (2007) *Manual pratique de radioprotection – 3e édition*, Lavoisier.
14. A. Benzarti Mezni et al. The occupational radiation-induced cataract in five industrial radiographers. Doi: 10.1016/j.jfo.2011.05.008.
15. Notices explicatives d'aide au diagnostic des maladies professionnelles, *Rapports EUR.* 14768 FR. Health and safety 1994; 183–9.