

## Case study

### **Subepithelial corneal infiltrates following intravitreal injection of Ranibizumab**

#### **ABSTRACT**

##### **PURPOSE:**

To describe an unusual appearance of corneal subepithelial infiltrates in a patient after receiving intravitreal injection of Ranibizumab.

##### **METHODS:**

60 year-old female patient who has diabetic macular edema received the 1<sup>st</sup> intravitreal injection of Ranibizumab in her right eye.

##### **RESULTS:**

The day following the injection the patient presented with discomfort in her right eye, anterior segment examination of the same eye revealed multiple subepithelial marginal corneal infiltrates separated from each other and separated from the limbus by clear zone, no cells or flare in the anterior chamber, she was treated by

topical moxifloxacin 0.5 % eye drops and dexamethasone eye drops which led to complete resolution of the corneal infiltrates.

## **CONCLUSIONS:**

Intravitreal Ranibizumab injection may induce immune reaction affecting the cornea in the form of subepithelial infiltrates.

Key words: Corneal infiltrates - Ranibizumab - Intravitreal injection

## **INTRODUCTION**

Intravitreal injection of anti-vascular endothelial growth factor (anti-VEGF) has been tried with success for treatment of diabetic macular edema. [1]

As many patients with diabetic macular edema receiving intravitreal anti- VEGF nowadays and multiple injections are needed to improve and stabilize vision, we should pay attention to adverse effects from these injections especially vision threatening and rare ones. [2]

In this case, treatment of diabetic macular edema with intravitreal Ranibizumab led to the appearance of multiple peripheral corneal subepithelial infiltrates the day following the 1<sup>st</sup> injection.

Ethical approval was obtained from our local ethical committee and written informed consent was taken from the patient.

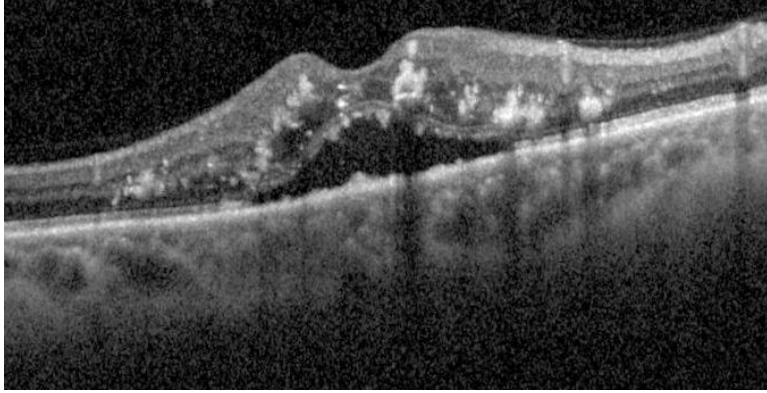
## CASE REPORT

A 60- years old female was referred to Minia University Hospital retina clinic with diabetic macular edema in her right eye, she has type 2 diabetes mellitus for 15 years and hypertension for 10 years, she complains of progressive diminution of vision in last six months more in right eye.

Her uncorrected visual acuity (UCVA) was 0.7 and 0.3 log MAR, best corrected visual acuity (BCVA) was 0.4 and 0.1 log MAR in right and left eye respectively. Intraocular pressure was normal and slit lamp examination revealed clear cornea with faint posterior sub capsular cataract.

Fundus examination revealed diabetic retinopathy; FA and OCT was performed to the patient and revealed diffuse macular edema on the right eye.

Intravitral ranibizumab injection was scheduled in her right eye after thorough discussion with the patient about potential benefits and complications of the procedure and she signed a written informed consent.

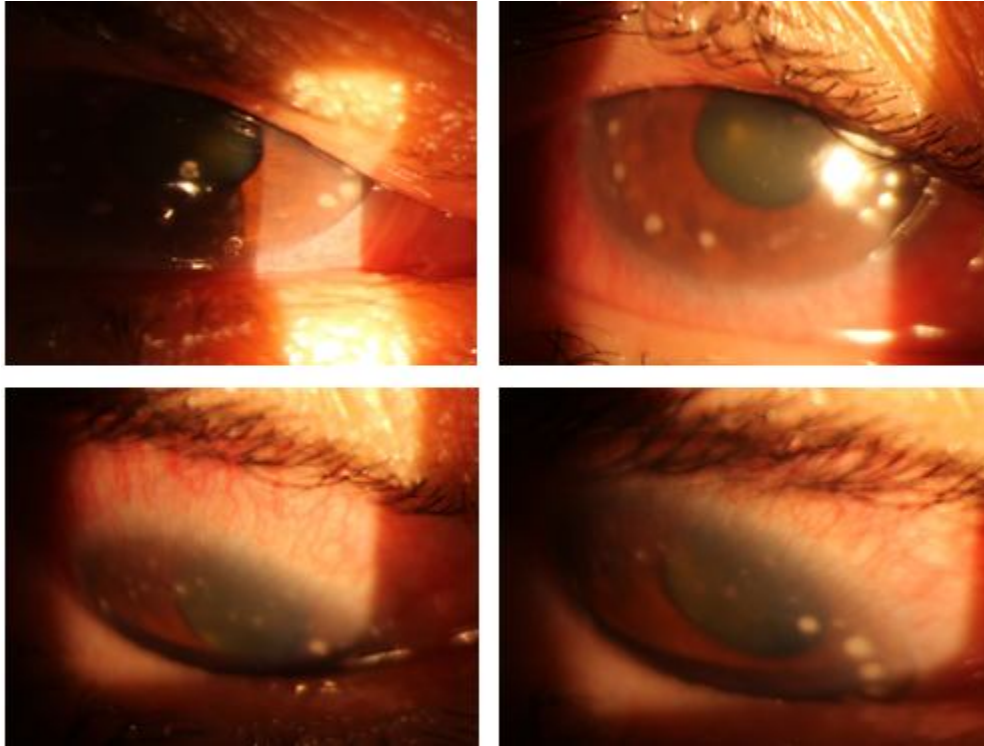


*Figure 1: OCT of right macular area showing intraretinal hyper-reflective lesions with back shadowing effects indicating hard exudates and hemorrhage, cystoid and spongy macular edema with neurosensory detachment.*

The patient received 0.05 mg/0.05 mL intravitreal ranibizumab injection to her right eye under standard aseptic conditions in the operative room.

The first day after injection, the patient presented with mild discomfort but no severe pain or drop of vision in the treated eye.

Slit lamp examination revealed multiple small peripheral corneal subepithelial infiltrates of different sizes in a circinate pattern separated from each other and separated from limbus by clear zone with clear corneal center. (Figure 2) No anterior chamber reaction.



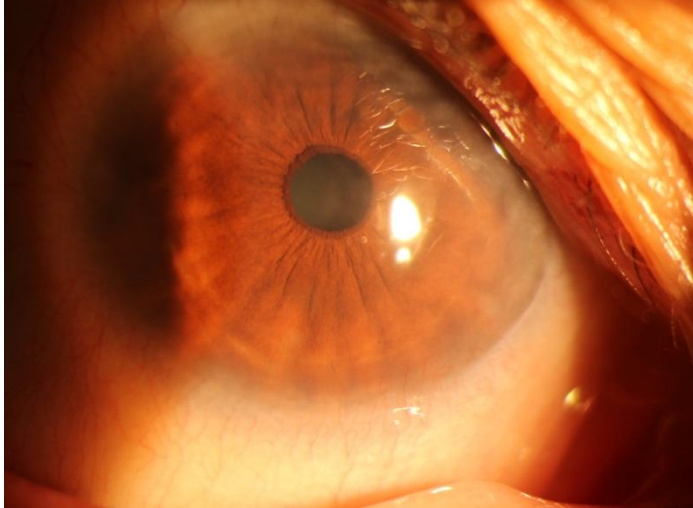
*Figure 2: Slit lamp photos of right eye showing multiple small peripheral corneal subepithelial infiltrates of different sizes.*

Bacterial and fungal cultures were negative. Gram stain scraping from one of the infiltrates found no bacteria.

The patient was evaluated in cornea clinic in our department and was thought to be noninfectious due to quiet eye and peripheral location of the lesions, and the patient was treated with moxifloxacin 0.5 % eye drops 4 times per day, dexamethasone eye drops 5 times and daily follow up.

The condition started to improve from the 3<sup>rd</sup> day with gradual resolution of the infiltrates.

On the 7<sup>th</sup> day; the infiltrates almost disappeared completely and the cornea was clear. (Figure 3)



*Figure 3: Slit lamp photo of right eye 1 week after intravitreal injection showing the cornea is clear with complete disappearance of subepithelial infiltrates.*

### **DISCUSSION:**

Management of diabetic macular edema involve many interventional modalities, the most common is intravitreal injection of antiVEGF. Repeated injections has corneal complications that include corneal edema , corneal epithelial defects, stem cell insufficiency and delayed healing but only small case series and case reports document those complications.[3]

Other ocular side effects of intravitreal anti VEGF include but not limited to uveitis, increased intraocular pressure (IOP), endophthalmitis, central retinal artery occlusion and lens injury.[4]

Our case only developed subepithelial corneal infiltrate but no flare that was reported in a similar case report after Ranibizumab injection. [5]

Our female patient had multiple infiltrates that were arranged in a circinate pattern that were sharply demarcated and separated from each other and from the limbus by 2mm clear zone.

The infiltrate appeared the next day following Ranibizumab injection and the patient's only complaint was mild discomfort but no visual complaint, the IOP was normal and the eye was quiet.

The patient was treated with topical moxifloxacin 0.5 % eye drops and topical dexamethasone eye drops with close follow up.

The distribution of corneal lesions, excellent response to topical steroid and negative culture swabs confirm the immunological basis of the conditions and the diagnosis of marginal keratitis was justified. Only few case reports describe similar condition.[5,6]

The exact pathogenesis of the development of this reaction after Ranibizumab injection is still unclear. Corneal epithelium express VEGF-A which with its receptors is thought to be the basis of this infiltrate. [7]

Reflux of Ranibizumab from intraocular injection onto the ocular surface can occur and the amount of this reflux is related to degree of vitreous liquefaction, intraocular pressure and thickness of sclera at site of injection. [8]

The refluxed Ranibizumab can react with corneal epithelium receptors and results in marginal keratitis. Some studies had shown that inhibition of VEGF may lead to adverse effects on corneal health and induce immunologically based inflammatory reaction. [9]

We thought that block of VEGF receptors, rani or its excipient toxicity, allergy to rani and its excipient and rebound inflammation due to VEGF block may attribute to development of this subepithelial corneal infiltrate.

Subepithelial corneal infiltrate may develop after intravitreal Ranibizumab injection and should be put in mind in following patient receiving this drug.

## REFERENCES

1. Wells JA. et al. Aflibercept, Bevacizumab, or Ranibizumab for Diabetic Macular Edema: Two-Year Results from a Comparative Effectiveness Randomized Clinical Trial. *Ophthalmology*. 2016 Jun; 123(6):1351-9.
2. Wykoff CC, Eichenbaum DA, Roth DB, Hill L, Fung AE, Haskova Z. ranibizumab induces regression of diabetic retinopathy in most patients at high risk of progression to proliferative diabetic retinopathy. *Ophthalmol Retina*. 2018; 2:997-1009.
3. Bayar SA, Altinors DD, Kucukerdonmez C, et al. Severe corneal changes following intravitreal injection of bevacizumab. *Ocul Immunol Inflamm*. 2010; 18:268–274.
4. Xu K., Chin E.K., Bennett S.R. Endophthalmitis after intravitreal injection of vascular endothelial growth factor inhibitors: management and visual outcomes. *Ophthalmology*. 2018 Aug; 125(8):1279-1286.
5. Aslan Bayhan S, Bayhan HA, Adam M, Gürdal C Marginal keratitis after intravitreal injection of ranibizumab. *Cornea*. 2014 Nov; 33(11):1238-9.
6. Dan H. Bourla, Assaf Dotan, Dov Weinberger, et al Consecutive Appearance of Corneal Subepithelial Infiltrates after Intravitreal Bevacizumab Injections. *Cornea*. 2010;29:686–687

7. Ambati BK, Nozaki M, Singh N, et al. Corneal avascularity is due to soluble VEGF receptor-1. *Nature*. 2006;443:993–997.
8. Boon CJ, Crama N, Klevering BJ, et al. Reflux after intravitreal injection of bevacizumab. *Ophthalmology*. 2008;115:1270.
9. Colombres GA, Gramajo AL, Arrambide MP, et al. Delayed corneal epithelial healing after intravitreal bevacizumab: a clinical and experimental study. *J Ophthalmic Vis Res*. 2011;6:18–25