

Case study

VOGT KOYANAGI HARADA SYNDROME: A PANDORA'S BOX!

ABSTRACT:

Vogt-Koyanagi-Harada syndrome is a rare systemic granulomatous autoimmune condition that affects melanocyte-rich organs including the eyes, inner ears, meninges, skin, and hair. It causes severe bilateral, chronic granulomatous panuveitis associated with serous retinal detachments and disc oedema. The etiology of **Vogt-Koyanagi-Harada** syndrome is extremely variable. Here, we report 4 cases diagnosed with **Vogt-Koyanagi-Harada** syndrome, who presented with completely different backgrounds. The first case was a 34M who presented with a 3 months history of **diminution of vision** with headache and tinnitus. The second case was a 21F who presented with a 1-day history of sudden **diminution of vision** associated with a headache on day 2 after undergoing an emergency **lower segment cesarean section**. The third patient was a 30F who was a case of **systemic lupus erythematosus** associated with type 4 lupus nephritis. She presented with a 2-day history of **diminution of vision** associated with headache and tinnitus. She had an active herpes zoster infection involving the trunk at the time of presentation. The fourth case was a 30F who presented to us 7 days post-vaccination with a 5-day history of sudden diminution of vision in both eyes.

All the patients had choroiditis with exudative retinal detachment confirmed on OCT suggestive of **Vogt-Koyanagi-Harada** syndrome. This case series throws light on variable etiology and multisystem involvement of **Vogt-Koyanagi-Harada** syndrome and management criteria. **Vogt-Koyanagi-Harada** syndrome is an important differential diagnosis in all patients presenting with the sudden blurring of vision with the headache.

KEYS WORDS:

Vogt Koyanagi Harada, headache, diminution of vision, retinal detachment

INTRODUCTION:

“Vogt-Koyanagi-Harada disease syndrome is a systemic granulomatous autoimmune disease that targets melanocyte-rich tissues mainly affecting the eye, inner ear, meninges, skin, and hair” [1].

“The history dates back to the 19th century when Alfred Vogt in Switzerland first described a patient with premature whitening of eyelashes of sudden onset and bilateral subacute iridocyclitis in 1906. Harada reported a case series with bilateral serous retinal detachment in association with cerebrospinal fluid (CSF) pleocytosis in 1926. In 1929 Koyanagi published a review article associating unequivocally the posterior eye involvement with auditory and integumentary manifestations. In 1932, Babel suggested that these cases represented a single entity, which was then named Vogt-Koyanagi-Harada Disease” [2].

"The disease is more commoner among people with pigmented skin. Asians, Native Americans, and Hispanics are most frequently affected. It predominates in patients aged between 20 and 50 years, with a female: male ratio of 2:1".[3]

In this case series, we discuss 4 different patients who presented with a completely different clinical backgrounds. However, all of them had signs of choroiditis and exudative retinal detachment suggestive of VKH syndrome. We wish to stress the variable etiology and the multi-system involvement of VKH syndrome.

CASE SERIES:

Case 1:

A 34-year-old male presented to us with complaints of headache, painful blurring of vision with redness, and photophobia in LE > RE for 3 months. The patient also gave a history of ringing in both ears for 3 months. The patient gave the history of brother diagnosed with pulmonary tuberculosis 6 months ago with positive contact history. The patient visited a local ophthalmologist for the above-mentioned complaints who prescribed him an IV steroid followed by oral steroids and lubricating eye drops. He was not relieved by the medication and presented to us 3 months after symptom onset with a flare of symptoms.

On ophthalmological examination vision in RE was FC at 2m and LE vision was FC at 3m with near vision in both eyes being N.36. On slit lamp examination patient had deep vascular congestion, scleral oedema, clear cornea, the anterior chamber had +2 cells in RE and +3 cells in LE, rest of anterior segment examination including pupils were normal. Fundus examination revealed a hyperaemic swollen disc, with multiple choroidal folds around the macula and optic disc and areas of exudative retinal detachment in both eyes up to mid-periphery.[Fig 1]

USG B scan showed sclerochoroidal thickening with the widening of sub tenons space [Fig 2]. OCT showed choroidal folds and loss of normal vasculature in BE with macular oedema in LE.

FFA revealed multiple RPE-level hyperfluorescent leaks with pooling in areas of exudation. [Fig 3]

Hematological investigations revealed elevated ESR with normal serum ACE and serum lysozyme levels. His rheumatoid factor, serum antinuclear antibodies, and serum HLA B27 were negative. A cerebrospinal examination revealed no abnormality. Mantoux test revealed strongly positive 20 by 35mm induration, but chest X-ray was normal. ENT consult revealed moderate **sensorineural hearing loss**. Neurology also suspected **incomplete VKH syndrome**.

A consultation with a chest physician was done and the patient was started on **anti-tubercular treatment**. We started the patient on topical cycloplegic, topical, and oral long-acting NSAIDs and **oral steroids at the dose of 1.2mg/kg/day with gradual tapering over 3 months**.

The patient showed improvement in vision with a resolution of pain and redness when started with steroids and **anti-tubercular treatment** at the end of 3 months. The patient has been counseled about the possibility of recurrences and the need for regular evaluation. The patient is being followed up by multi-specialty including neurology, dermatology, and ENT approach to discern VKH manifestations of later disease.

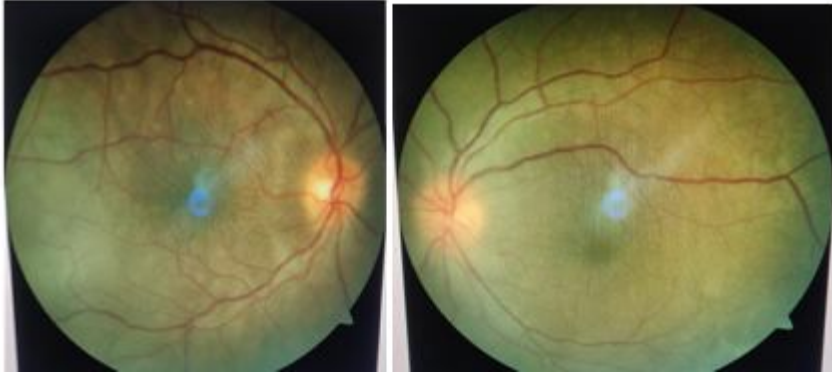

Fig 1 -Fundus Photo showing hyperaemic swollen disc, with multiple choroidal folds around the macula and optic disc and areas of exudative retinal detachment in both eyes up to mid-periphery

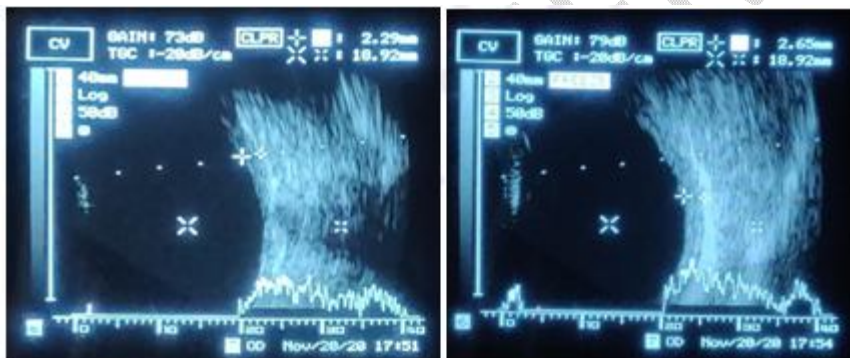


Fig 2- USG B Scan showing sclerochoroidal thickening with the widening of sub-tenons space.

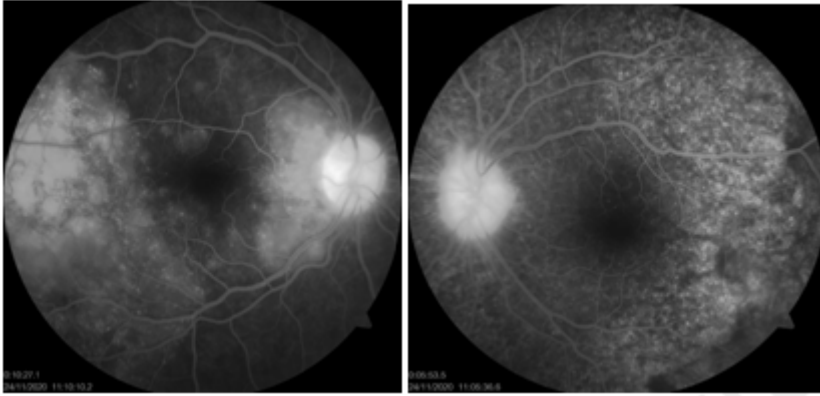


Fig 3- FFA: Late venous phase showing starry sky appearance in both eyes.

Case 2:

A 21-year post partum female on day 2 of emergency **lower segment cesarean section** which was done in view of induction of labor, presented with a 2-day history of bilateral blurring of vision along with the appearance of black spots bilaterally.

Her distant visual acuity was Finger counting at 2m in both eyes with a near vision of less than N.36. She had metamorphopsia on Amsler's grid with no appreciation of any plate on Ishihara's color vision chart in both eyes. Extraocular muscle movements in both eyes were full, free, and painless in all gazes. The anterior chamber of both eyes showed a +1 reaction. The anterior segment was otherwise unremarkable in both eyes. However, fundus examination disclosed a temporally pale disc bilaterally with attenuated and tortuous blood vessels, multiple hypopigmented spots suggestive of choroiditis with multiple exudative retinal detachments with macular folds and edema in both eyes [Fig 4]. The patient was followed up with noninvasive investigation like OCT which was suggestive of Subretinal fluid accumulation with septae along with the outer nuclear layer showing multiple cystic spaces and choroiditis [Fig 5]. USG B-Scan showed choroidal thickening in both eyes. A patient refused to undergo FFA. Despite the absence of auditory complaints, she was found to have bilateral sensorineural deafness on clinical testing which was later confirmed on Pure tone audiometry. Her general examination was normal. A team of specialists, involving a physician, neuro physician, dermatologist, and otorhinolaryngologist was consulted. Blood pressure monitoring, hemoglobin, Complete blood count, MRI Brain with a venogram was done. The patient was followed up with all the reports which happened to be normal. On basis of clinical findings, she was diagnosed as a case of "**Probable VKH** with multiple exudative retinal detachments with macular edema". After due clearance patient was started on **oral high-dose steroids in a dose of 1.2mg/kg/day tapered gradually over 1 month**. At 1 monthly follow up patient

showed an excellent prognosis with distant visual acuity of 6/9 in both eyes and near visual acuity of N6 with normal color vision and Amsler's grid. Both eyes were quiet and the fundus showed a flat retina and normal optic disc with mild pigmentary changes at the macula. On OCT, the retina appeared to be re-attached with the absorption of SRF. However, Mild foveal thinning was noticed. The patient is currently on low-dose steroids and is being followed up regularly. However foveal thinning is noticed at this stage. Currently, the patient is on tapering dosage of steroids and being routinely followed up to monitor the progression of the disease and any possible complications because of steroids.

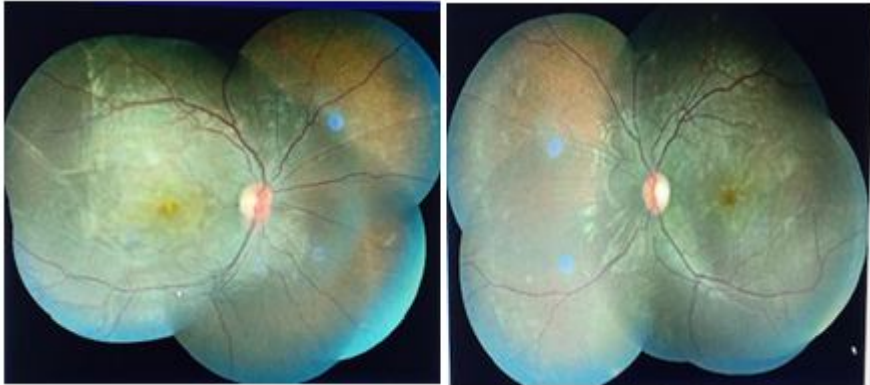

Fig 4- Fundus Photo at Presentation showing temporally pale disc bilaterally with attenuated and tortuous blood vessels, multiple hypopigmented spots suggestive of choroiditis with multiple exudative retinal detachments with macular folds and edema in both eyes

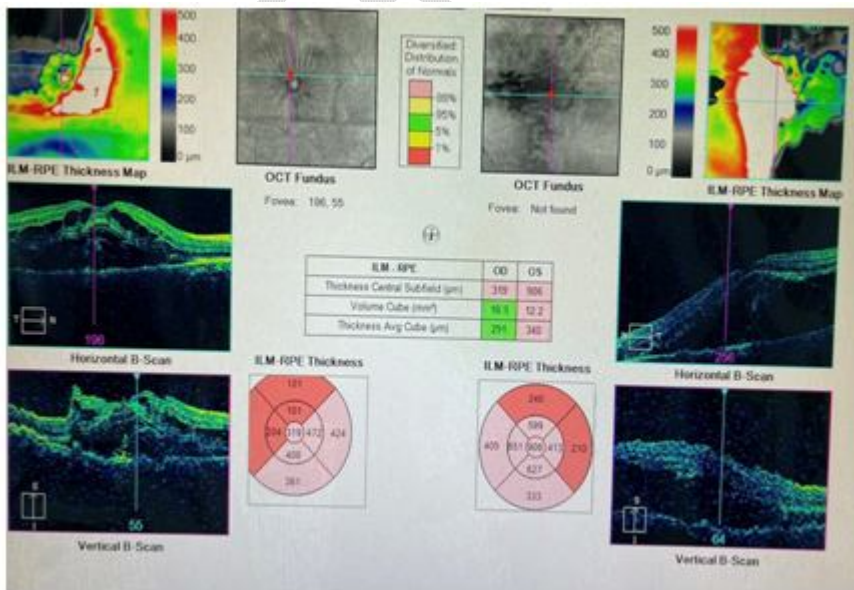


Fig 5-OCT-Macular Cube OU analysis showing subretinal fluid accumulation with septae along with outer nuclear layer showing multiple cystic spaces and choroiditis

Case 3:

A 30-year-old female patient presented to the opd with a chief complaint of sudden onset blurring of vision in both eyes which was gradually progressive and associated with generalized headache. On presentation, she had a 10-day history of herpes zoster infection involving the trunk after which her immunosuppressant treatment was withheld and systemic steroid dosage was tapered.

On examination, her distant visual acuity was Finger counting at 3M in the right eye improving to 6/24 with pinhole and 6/36 not improving in the left eye. Her near visual acuity was N10 in the right eye and <N36 in the left eye. Her right eye color vision was 12/17 in the right eye with normal Amsler's grid and she was unable to read the color vision and Amsler's charts from the left eye.

The anterior chamber had +2 cells in RE and +3 cells in LE, the rest of the anterior segment examination including pupils was normal. On fundus examination, both eyes showed patchy choroiditis, and microangiopathy with a blurring of disc margins and additionally, the left eye showed inferior exudative retinal detachment with shifting fluid [Fig 6]. On OCT, Optic nerve head thickening was present in both eyes. In addition to this, left eye OCT showed sub-retinal fluid at the macula along with sub-retinal septae [Fig 7]. A provisional diagnosis of **incomplete VKH syndrome** was made on basis of clinical findings. A multidisciplinary approach was undertaken involving a dermatologist, ENT, rheumatologist, and urologist. On ENT examination, the patient had bilateral **sensorineural hearing loss** which was supportive of the diagnosis. The patient did not have any dermatological findings. On rheumatology consultation, the patient has advised ivig transmission which she was not afforded. This made the situation more complicated. After extensive thinking and discussion, a mutual decision of increasing the steroid dosage was taken by the whole team. She was started on **high-dose systemic steroids at a dose of 84mg/day with gradual tapering over 1 month** under strict antibiotic and antiviral cover. On follow-up after a month, patients' symptoms ameliorated. Fundus examination showed resolution of exudative retinal detachment which was confirmed on OCT.

She is currently subjected to regular follow-ups and shows good improvement however, long terms effects still remain a matter of query.

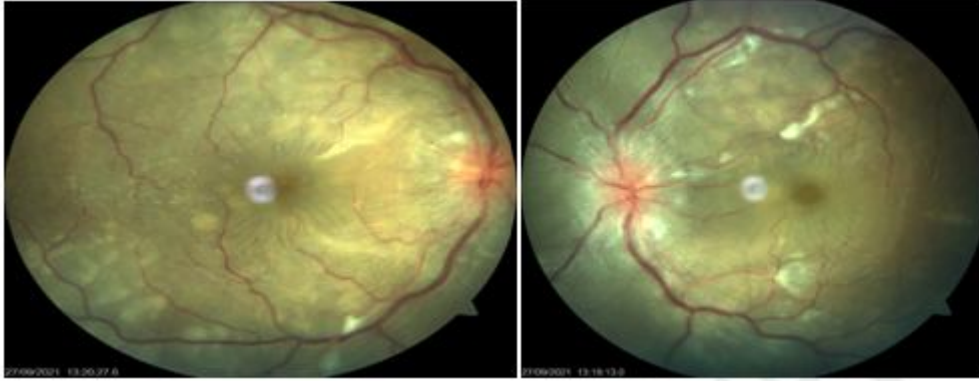

Fig 6- Fundus Photo of both eyes showed patchy choroiditis, microangiopathy with blurring of disc margins, and additionally, the left eye showed inferior exudative retinal detachment with shifting fluid

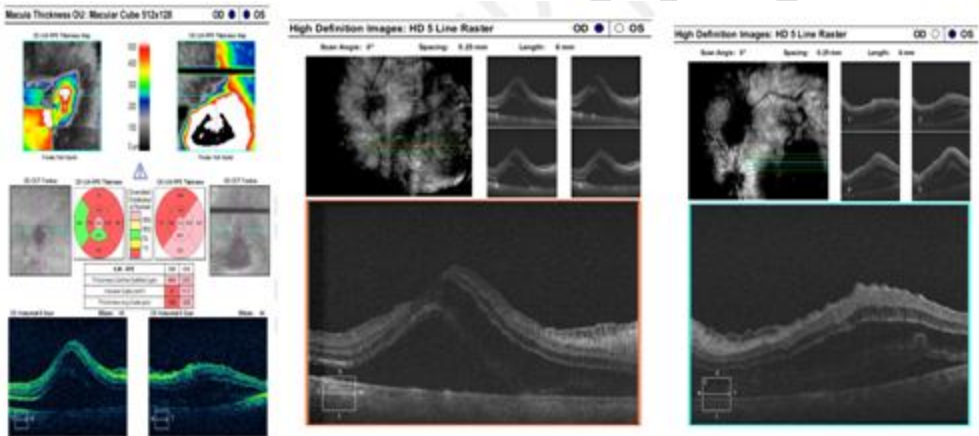


Fig 7- OCT-Macular and HD 5 raster showed optic nerve head thickening present in both eyes. In addition to this, left eye OCT showed sub-retinal fluid at the macula along with sub-retinal septae

Case 4:

“A 30-year-old female presented to our clinic with a 5-day history of sudden onset painless blurring of vision in both eyes 7 days post first dose of Covishield vaccination. This was the only complaint on presentation and no similar episodes in the past were present. She denied a history of ocular trauma and ocular procedure. Her past medical history, personal history, and family history were unremarkable”. [13]

On examination, distant visual acuity was Finger Counting at 1 meter in the right eye and Finger Counting in front of the face in the left eye with a near visual acuity was <N36. On slit lamp examination, keratic precipitates (KPs) on endothelium, 3+ anterior chamber cells, and a few vitreous cells were seen in both eyes [Fig 8]. Intra-ocular pressure was within normal limits in both eyes. On fundus examination, both eyes showed hyperaemic discs and exudative retinal detachment with shifting fluid with no retinal breaks [Fig 9]. On Fundus Fluorescein Angiography, pinpoint leaks were seen in both eyes along with disc hyper fluorescence [Fig 10] and Ultrasound Biomicroscopy showed retinal detachment with choroidal thickening in both eyes suggestive of VKH syndrome. "A diagnosis of **probable Harada disease** was made after ruling out the involvement of other systems and she was treated with **high-dose oral steroids of 70 mg per day which was tapered gradually**. At this juncture, the vaccination was believed to be just incidental although the scenario appeared suspicious. The patient was regularly followed up and showed good improvement with remission of uveitis. Over a period of 7 weeks, her visual acuity improved to 6/9 with quiet eyes and resolution of RD bilaterally. However, a second dose of the covishield vaccine was taken during this period and she had an alarming drop in vision to 6/36 in both eyes on the following day. On examination, there was the reactivation of uveitis, with fresh KPs, 3+ cell reaction in both eyes, and additionally posterior synechiae at 6 o clock in the left eye. Nevertheless, the retina was flat this time accountable to the **ongoing steroids of 20mg per day**. Her systemic steroid dosage is stepped up with the addition of topical steroids and cycloplegic. She shows good improvement currently". [13]

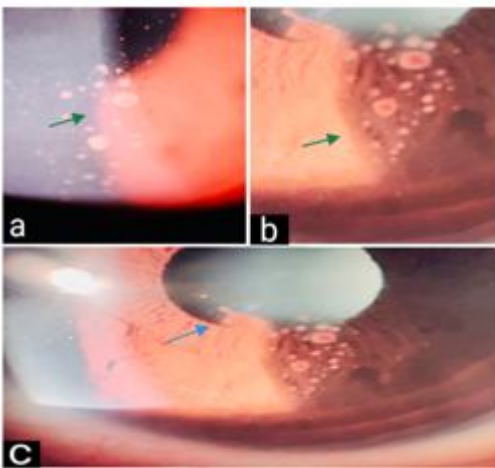


Fig 8-Slit Image showing keratic precipitates (KPs) on endothelium, 3+ anterior chamber cells, and few vitreous cells were seen in both eyes

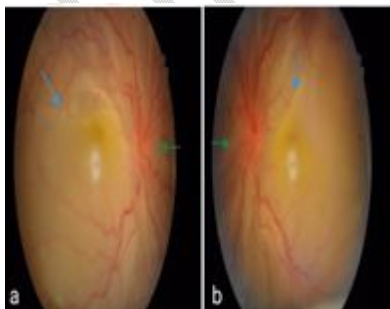


Fig 9- Fundus Photo showed hyperaemic discs, exudative retinal detachment with shifting fluid with no retinal breaks

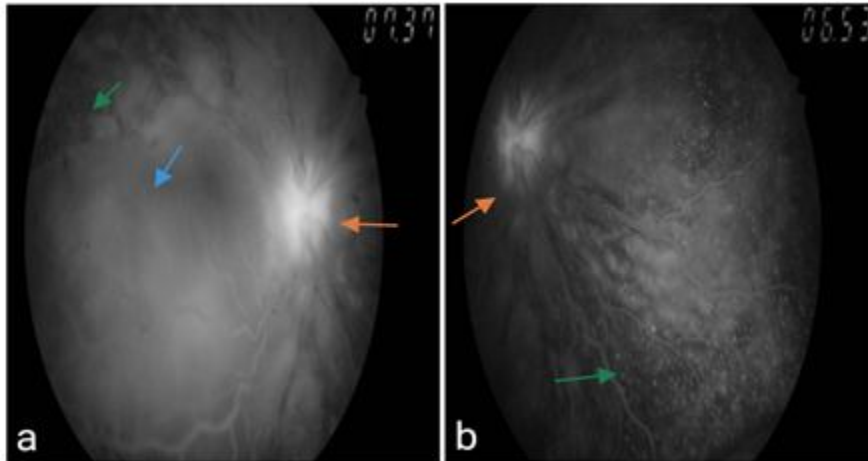


Fig 10- FFA image showed pinpoint leaks in both eyes along with disc hyper fluorescence

DISCUSSION:

The exact etiology of the disease is incompletely understood. Although, the most proposed mechanism is an autoimmune reaction allegedly CD4+ T lymphocytes against melanocytes in a genetically susceptible individual usually after a viral trigger.[3]

The disease presents in 4 distinct phases namely, the prodromal stage presents with fever, headache, nausea, vertigo, orbital pain, photophobia, tearing, tinnitus, vertigo, and neurologic symptoms. In this stage, photophobia, tearing, tinnitus, vertigo, and neurologic symptoms predominate. In this stage, cerebrospinal fluid may reveal pleocytosis.

Next is the acute uveitic stage showing diffuse choroiditis with Exudative RD, and optic disc swelling, convalescent stage shows integumentary findings like poliosis, vitiligo, and alopecia lasting for months to years. Pathognomic ocular finding in this is the sunset glow fundus. Last is the recurrent or chronic stage with recurrent anterior uveitis.[4]

VKH can sometimes present as sclerouveitis leading to a diagnostic dilemma as observed in our first patient who was diagnosed as a case of TB sclerouveitis keeping in mind that India is endemic to TB.

Vice versa, cases of TB uveitis which were mistakenly diagnosed as VKH were reported previously.[5]

Pregnancy is known to cause depression of cellular immunity which is reversed during the postpartum period. These changes in cellular immunity during pregnancy can influence the course of VKH, as the pathological mechanism of the condition is believed to be a cellular autoimmune response to melanocyte-containing tissues.

However, the immunological influence of pregnancy on VKH has not been clarified yet. Various cases have been reported of patients with VKH in pregnancy.[6,7]

The cases reported previously, majorly showed two patterns. One is where known cases had gone into remission during pregnancy with later recurrences and the others developed VKH during pregnancy and were treated. Various treatment modalities are also proposed including topical and steroids depending on the trimester of pregnancy.[7] Our second case shows the second pattern. She improved dramatically with high-dose oral steroids.

Varicella zoster virus is actually stated as the most common viral infection reported in systemic lupus erythematosus patients. Chen D et al observed that there is a 3.6% incidence of VZV in **systemic lupus erythematosus** patients, lymphopenia and high-dose steroids being the main culprits. They also stated that the highest risk is between 3-6 months of SLE diagnosis which reduces later.[8]

A similar instance is observed in our third patient. The significance of viral triggers in the incidence of VKH disease is well established although incompletely understood.

This supports the possibility of causation of VKH post-herpes infection in our patient.

“VKH has been associated with various vaccines such as Hepatitis B, Hepatitis C, and yellow fever as well as a few biological drugs used in anti-cancer therapy”.[9,10,11] “This can be attributed to the immunogenetic dysregulation that can be caused by the latter. The etiology of the occurrence of autoimmune diseases post-vaccination is unclear. However, Molecular mimicry, Bystander activation of sequestered self-antigens, Cytokines secretion from macrophages, and genetic polymorphisms are the 4 possible mechanisms of the same. There is a high chance that similar effects can trigger an autoimmune response post-Covid vaccination. This is also supported by the reported cases of other autoimmune conditions like Guillain-Barre Syndrome, and Systemic Lupus Erythematosus post-vaccination”.[12] Our fourth patient showed an intriguing association between the onset of Harada syndrome and Covishield vaccination which is justified by the acute worsening of the condition on the second dose despite ongoing steroid.

CONCLUSIONS:

This study shows variable etiology and multisystem involvement of VKH syndrome and the management criteria. VKH syndrome is an important differential diagnosis in all patients presenting with sudden blurring of vision with a headache. Patients presenting with VKH should be started on high-dose steroids with regular monitoring.

Ethical Approval:

As per international standard or university standard written ethical approval has been collected and preserved by the author(s).

Consent

As per international standard or university standard, patient(s) written consent has been collected and preserved by the author(s).

REFERENCES:

- 1.Lavezzo, M.M., Sakata, V.M., Morita, C. et al. Vogt-Koyanagi-Harada disease: review of a rare autoimmune disease targeting antigens of melanocytes. *Orphanet J Rare Dis* 11, 29 (2016).
- 2.Herbort CP, Mochizuki M. Vogt-Koyanagi-Harada disease: inquiry into the genesis of a disease name in the historical context of Switzerland and Japan. *Int Ophthalmol*. 2007;27(2–3):67–79.
- 3.Greco A, Fusconi M, Gallo A, et al. Vogt-Koyanagi-Harada syndrome. *Autoimmun Rev*. 2013 Sep;12(11):1033-8. doi: 10.1016/j.autrev.2013.01.004
- 4.Burkholder, Bryn M. Vogt-Koyanagi-Harada disease, *Current Opinion in Ophthalmology*: November 2015 - Volume 26 - Issue 6 - p 506-511
- 5.Tian-Wei Qian et al, *Int J Ophthalmol* 2018;11(8):1430-1432.
- 6.Nohara, M & Norose, Kazumi & Segawa, K. (1995). Vogt-Koyanagi-Harada disease during pregnancy. *The British journal of ophthalmology*. 79. 94-5. 10.1136/bjo.79.1.94.
- 7.Miyata N, Sugita M, Nakamura S, et al. Treatment of Vogt-Koyanagi- Harada's disease during pregnancy. *Jpn J Ophthalmol*. 2001 Mar-Apr;45(2):177-80. doi: 10.1016/s0021-5155(00)00357-9.
- 8.Chen D, Li H, Xie J, Zhan Z, Liang L, Yang X. Herpes zoster in patients with systemic lupus erythematosus: Clinical features, complications and risk factors. *Exp Ther Med*. 2017 Dec;14(6):6222-6228. doi: 10.3892/etm.2017.5297. Epub 2017 Oct 12. PMID: 29285180; PMCID: PMC5740583.
- 9.Campos WR, Cenachi SPF, Soares MS, et al. Vogt-Koyanagi-Harada-like disease following yellow fever vaccination. *Ocul Immunol Inflamm* 2021;29(1):124–7.

10.Sood AB, O'Keefe G, Bui D, Jain N. Vogt-Koyanagi-Harada Disease Associated with Hepatitis B Vaccination. *Ocul Immunol Inflamm*. 2019;27(4):524-527.

11. Crosson JN, Laird PW, Debiec M, et al. Vogt-Koyanagi-Harada-like syndrome after CTLA-4 inhibition with ipilimumab for metastatic melanoma. *J Immunother*. 2015 Feb-Mar;38(2):80-4.

12. Patel SU, Khurram R, Lakhani A, Quirk B. Guillain-Barre syndrome following the first dose of the chimpanzee adenovirus-vectored COVID-19 vaccine, ChAdOx1. *BMJ Case Rep* 2021;14(4): e242956.

13. Reddy Y, Pandey A, Ojha A, Ramchandani S. Harada-like syndrome post-Covishield vaccination: A rare adverse effect. *Indian journal of ophthalmology*. 2022 Jan;70(1):321.

UNDER PEER REVIEW