

## Case study

# VOGT KOYANAGI HARADA SYNDROME: A PANDORA'S BOX!

### ABSTRACT:

Vogt-Koyanagi-Harada syndrome is a rare systemic granulomatous autoimmune condition that affects melanocyte-rich organs including the eyes, inner ears, meninges, skin, and hair. It causes a severe bilateral, chronic granulomatous panuveitis associated with serous retinal detachments and disc oedema. The etiology of Vogt-Koyanagi-Harada syndrome is extremely variable. Here, we report 4 cases diagnosed with Vogt-Koyanagi-Harada syndrome, who presented with completely different backgrounds. First case was a 34M who presented with a 3 months history of diminution of vision with headache and tinnitus. Second case was a 21F who presented with a 1day history of sudden diminution of vision associated with headache on day 2 after undergoing emergency lower segment caesarean section. Third patient was a 30F who was a case of systemic lupus erythematosus associated type 4 lupus nephritis. She presented with a 2 day history of diminution of vision associated with headache and tinnitus. She had an active herpes zoster infection involving the trunk at time of presentation. Fourth case was a 30F who presented to us 7 days post vaccination with a 5 day history of sudden diminution of vision in both eyes.

All the patients had choroiditis with exudative retinal detachment confirmed on OCT suggestive of Vogt-Koyanagi-Harada syndrome. This case series throws light on variable etiology and multisystem involvement of Vogt-Koyanagi-Harada syndrome and management criteria. Vogt-Koyanagi-Harada syndrome is an important differential diagnosis in all patient's presenting with sudden blurring of vision with headache.

### KEYS WORDS:

*Vogt Koyanagi Harada, headache, diminution of vision, retinal detachment*

### INTRODUCTION:

Vogt-Koyanagi-Harada disease syndrome is a systemic granulomatous autoimmune disease that targets melanocyte-rich tissues mainly affecting the eye, inner ear, meninges, skin and hair [1].

The history dates back to 19th century when Alfred Vogt in Switzerland first described a patient with premature whitening of eyelashes of sudden onset and bilateral subacute iridocyclitis in 1906. Harada reported a case series with bilateral serous retinal detachment in association with cerebrospinal fluid (CSF) pleocytosis in 1926. In 1929 Koyanagi published a review article associating unequivocally the posterior eye involvement with auditory and integumentary manifestations. In 1932, Babel suggested that these cases represented a single entity, which was then named Vogt-Koyanagi-Harada Disease [2].

The disease is commoner among people with pigmented skin. Asians, Native Americans, and Hispanics are most frequently affected. It predominates in patients aged between 20 and 50 years, with a female:male ratio of 2:1.[3]

In this case series, we discuss about 4 different patients who presented with completely different clinical background. However, all of them had signs of choroiditis and exudative retinal detachment suggestive of VKH syndrome. We wish to stress on the variable etiology and the multi system involvement of VKH syndrome.

## **CASE SERIES:**

### Case 1:

A 34 year old male presented to us with complaints of headache, painful blurring of vision with redness and photophobia in LE > RE since 3 months. Patient also gave history of ringing in both ears since 3 months. Patient gave history of brother diagnosed with pulmonary tuberculosis 6 months ago with positive contact history. Patient visited local ophthalmologist for above mentioned complaints who prescribed him IV steroid followed by oral steroids and lubricating eyedrops. He was not relieved by the medication and presented to us 3 months after symptom onset with flare up of symptoms.

On ophthalmological examination vision in RE was FC at 2m and LE vision was FC at 3m with near vision in both eyes being N.36. On slit lamp examination patient had deep vascular congestion, scleral oedema, clear cornea, anterior chamber had +2 cells in RE and +3 cells in LE, rest of anterior segment examination including pupils were normal. Fundus examination revealed, hyperaemic swollen disc, with multiple choroidal folds around macula and optic disc and areas of exudative retinal detachment in both eyes up to mid-periphery.[Fig 1]

USG B scan showed sclerochoroidal thickening with widening of sub tenons space [Fig 2]. OCT showed choroidal folds and loss of normal vasculature in BE with macular oedema in LE.

FFA revealed multiple RPE level hyperfluorescent leaks with pooling in areas of exudation. [Fig 3]

Haematological investigations revealed elevated ESR with normal serum ACE and serum lysozyme levels. His rheumatoid factor, serum antinuclear antibodies, serum HLA B27 were negative. Cerebrospinal examination revealed no abnormality. Mantoux test revealed strongly positive 20 by 35mm induration, but chest X ray was normal. ENT consult revealed moderate **sensorineural hearing loss**. Neurology also suspected **incomplete VKH syndrome**.

Consultation with chest physician was done and patient was started on **anti-tubercular treatment**. We started the patient on topical cycloplegic, topical and oral long acting NSAIDs and **oral steroid in the dose of 1.2mg/kg/day with gradual tapering over 3 months**.

Patient showed improvement in vision with resolution of pain and redness when started with steroids and **anti-tubercular treatment** at the end of 3 months. Patient has been counselled about the possibility of recurrences and the need for regular evaluation. Patient is being followed up by multi-specialty including neurology, dermatology and ENT approach to discern VKH manifestations of later disease.

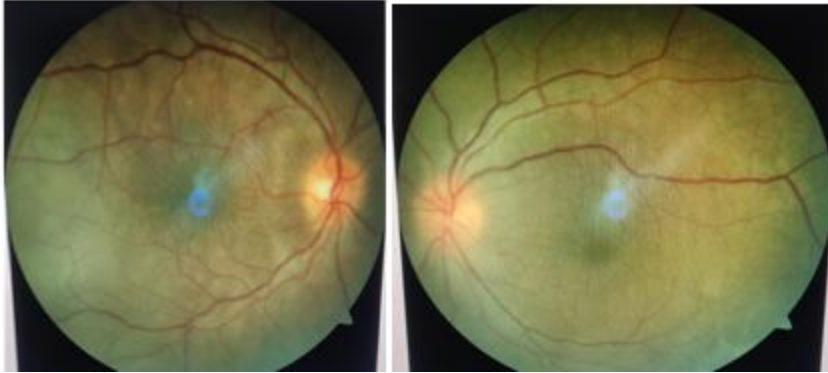


Fig 1 -Fundus Photo showing hyperaemic swollen disc, with multiple choroidal folds around macula and optic disc and areas of exudative retinal detachment in both eyes up to mid-periphery

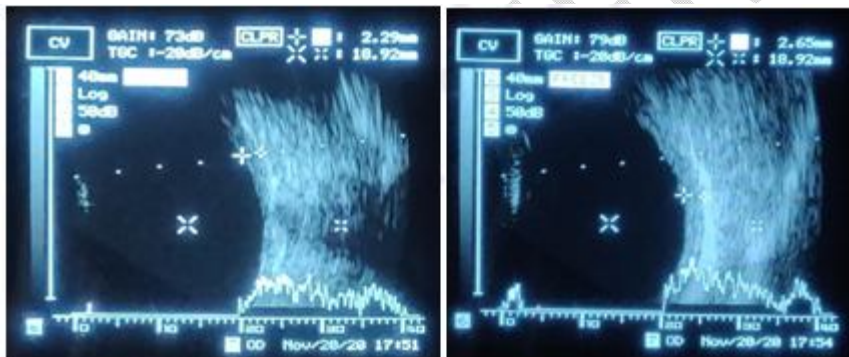


Fig 2- USG B Scan showing sclerochoroidal thickening with widening of sub tenons space.

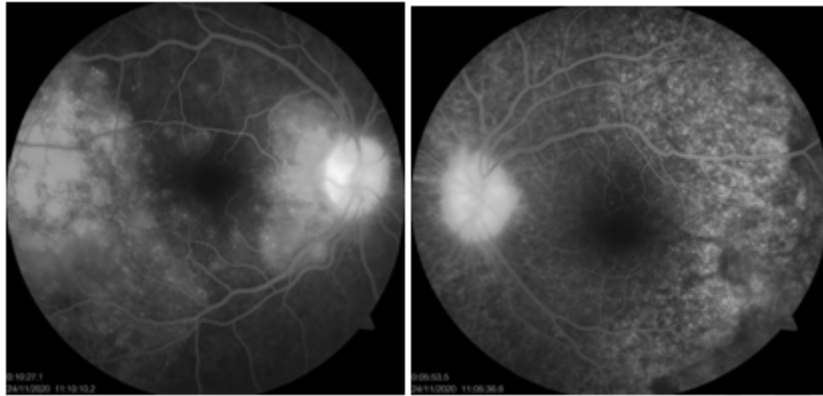


Fig 3- FFA: Late venous phase showing starry sky appearance in both eyes.

#### Case 2:

A 21 year post partum female on day 2 of emergency lower segment caesarean section which done in view of induction of labour, presented with a 2 day history of bilateral blurring of vision along with appearance of black spots bilaterally.

Her distant visual acuity was Finger counting at 2m in both the eyes with a near vision of less than N.36. She had metamorphopsia on Amsler's grid with no appreciation of any plate on Ishihara's colour vision chart in both eyes. Extra ocular muscle movements in both eyes was full, free and painless in all gazes. Anterior chamber of both eyes showed +1 reaction. Anterior segment was otherwise unremarkable in both eyes. However, fundus examination disclosed temporally pale disc bilaterally with attenuated and tortuous blood vessels, multiple hypopigmented spots suggestive of choroiditis with multiple exudative retinal detachments with macular folds and edema in both eyes [Fig 4]. Patient was followed up with noninvasive investigation like OCT which was suggestive of Subretinal fluid accumulation with septae along with outer nuclear layer showing multiple cystic spaces and choroiditis [Fig 5].USG B-Scan showed choroidal thickening in both eyes. Patient refused to undergo FFA. Despite absence of auditory complaints, she was found to have bilateral sensorineural deafness on clinical testing which was later confirmed on Pure tone audiometry. Her general examination was normal. A team of specialists, involving physician, neurophysician, dermatologist, otorhinolaryngologist was consulted. Blood pressure monitoring, haemoglobin, Complete blood count, MRI Brain with venogram was done. Patient was followed up with all the reports which happened to be normal. On basis of clinical findings, she was diagnosed as a case of "Probable VKH with multiple exudative retinal detachment with macular edema". After due clearance patient was started on oral high dose steroids in a dose of 1.2mg/kg/day tapered gradually over 1 month. At 1 monthly follow up patient showed excellent prognosis with distant visual acuity of 6/9 in both eyes

and near visual acuity of N6 with normal colour vision and amsler's grid. Both eyes were quiet and fundus showed flat retina and normal optic disc with mild pigmentary changes at macula. On OCT, retina appeared to be re attached with absorption of SRF. However, Mild foveal thinning was noticed. Patient is currently on low dose steroids and being followed up regularly. However foveal thinning is noticed at this stage. Currently patient is on tapering dosage of steroids and being routinely followed up to monitor the progression of the disease and any possible complications because of steroids.

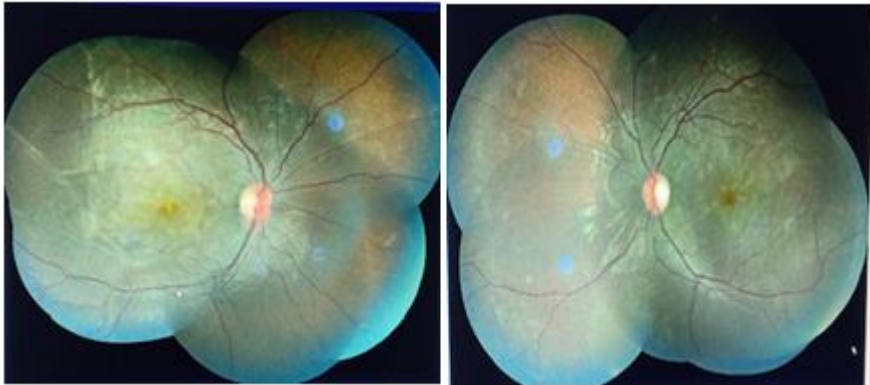

Fig 4- Fundus Photo at Presentation showing temporally pale disc bilaterally with attenuated and tortuous blood vessels, multiple hypopigmented spots suggestive of choroiditis with multiple exudative retinal detachments with macular folds and edema in both eyes

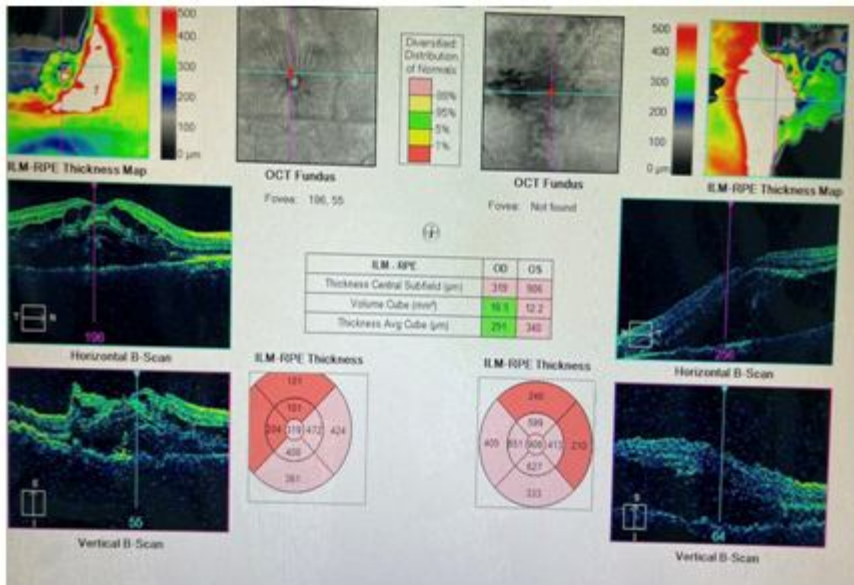


Fig 5-OCT-Macular Cube OU analysis showing subretinal fluid accumulation with septae along with outer nuclear layer showing multiple cystic spaces and choroiditis

### Case 3:

A 30 year old female patient presented to the opd with a chief complaint of sudden onset blurring of vision in both eyes which was gradually progressive and associated with generalized headache. On presentation, she had a 10 day history of herpes zoster infection involving the trunk after which her immunosuppressant treatment was withheld and systemic steroid dosage was tapered.

On examination, her distant visual acuity was Finger counting at 3M in the right eye improving to 6/24 with pinhole and 6/36 not improving in the left eye. Her near visual acuity was N10 in right eye and <N36 in the left eye. Her right eye colour vision was 12/17 in the right eye with normal amsler's grid and she was unable to read colour vision and amsler's charts from the left eye.

Anterior chamber had +2 cells in RE and +3 cells in LE, rest of anterior segment examination including pupils were normal. On fundus examination, both eyes showed patchy choroiditis, micro angiopathy with blurring of disc margins and additionally, left eye showed inferior exudative retinal detachment with shifting fluid [Fig 6]. On OCT, Optic nerve head thickening was present in both eyes. In addition to this, left eye OCT showed sub retinal fluid at macula along with sub retinal septae [Fig 7]. A provisional diagnosis of **incomplete VKH syndrome** was made on basis of clinical findings. A multidisciplinary approach was undertaken involving dermatologist, ENT, rheumatologist and urologist. On ENT examination, patient had bilateral **sensorineural hearing loss** which was supportive of the diagnosis. Patient did not have any dermatological findings. On rheumatology consultation, patient was advised ivig transmission which she was not affording. This made the situation more complicated. After extensive thinking and discussion a mutual decision of increasing the steroid dosage was taken by the whole team. She was started on **high dose systemic steroid in a dose of 84mg/day with gradual tapering over 1 month** under strict antibiotic and antiviral cover. On follow up after a month, patients symptoms ameliorated. Fundus examination showed resolution of exudative retinal detachment which was confirmed on OCT.

She is currently subjected to regular follow ups and shows good improvement however, long terms effects still remain a matter of query.

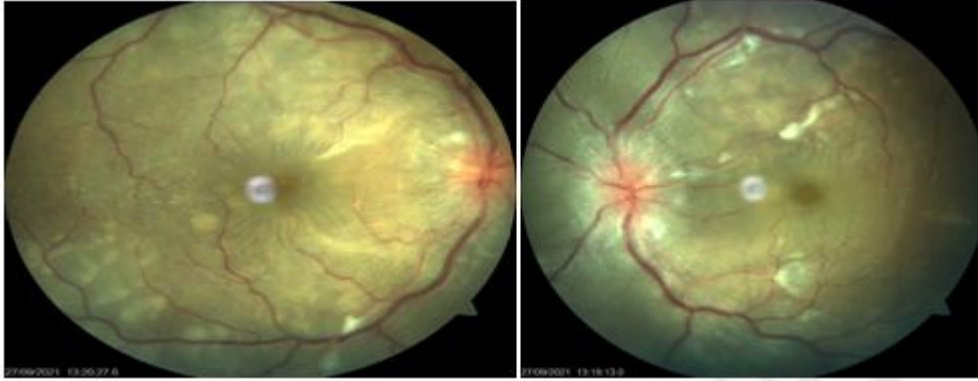

Fig 6- Fundus Photo of both eyes showed patchy choroiditis, micro angiopathy with blurring of disc margins and additionally, left eye showed inferior exudative retinal detachment with shifting fluid

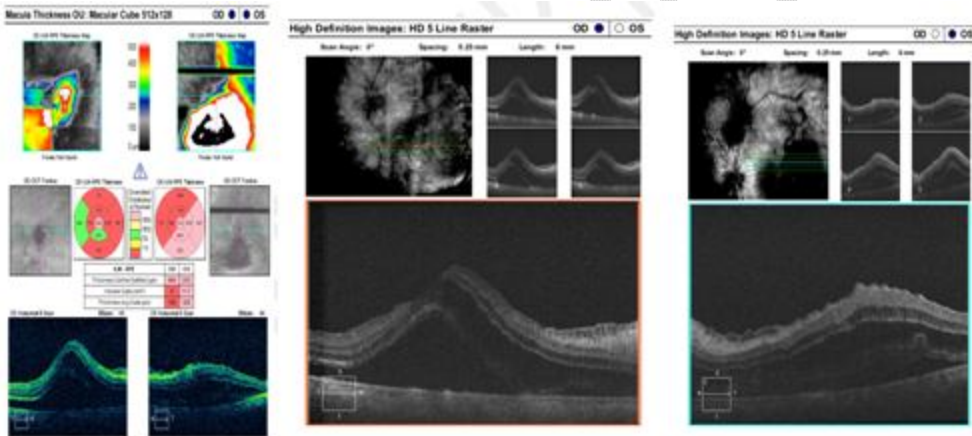


Fig 7- OCT-Macular and HD 5 raster showed optic nerve head thickening present in both eyes. In addition to this, left eye OCT showed sub retinal fluid at macula along with sub retinal septae

Case 4:

A 30 year old female, presented to our clinic with a 5 day history of sudden onset painless blurring of vision in both eyes 7 days post first dose of Covishield vaccination. This was the only complaint on presentation and no similar episodes in the past were present. She denied history of ocular trauma, ocular procedure. Her past medical history, personal history and family history were unremarkable.

On examination distant visual acuity was Finger Counting at 1 meter in the right eye and Finger Counting in front of face in left eye with a near visual acuity was <N36. On slit lamp examination, keratic precipitates(KPs) on endothelium, 3+anterior chamber cells and few vitreous cells were seen in both eyes [Fig 8]. Intra ocular pressure was within normal limits in both eyes. On fundus examination, both eyes showed hyperaemic discs, exudative retinal detachment with shifting fluid with no retinal breaks [Fig 9].On Fundus Fluorescein Angiography, pin point leaks were seen in both eyes along with disc hyper fluorescence [Fig 10] and Ultrasound Biomicroscopy showed retinal detachment with choroidal thickening in both eyes suggestive of VKH syndrome. A diagnosis of **probable Harada disease** was made after ruling out involvement of other systems and she was treated with **high dose oral steroids of 70 mg per day which was tapered gradually**. At this juncture, the vaccination was believed to be just incidental although the scenario appeared suspicious. Patient was regularly followed up and showed good improvement with remission of uveitis. Over a period of 7 weeks her visual acuity improved to 6/9 with quiet eyes and resolution of RD bilaterally. However, second dose of covishield vaccine was taken during this period and she had an alarming drop of vision to 6/36 in both eyes on the following day. On examination, there was reactivation of uveitis, with fresh KPs, 3+ cell reaction in both eyes and additionally posterior synechiae at 6 o clock in left eye.Nevertheless, the retina was flat this time accountable to the **ongoing steroids of 20mg per day**. Her systemic steroid dosage is stepped up with addition of topical steroids and cycloplegic. She shows good improvement currently.

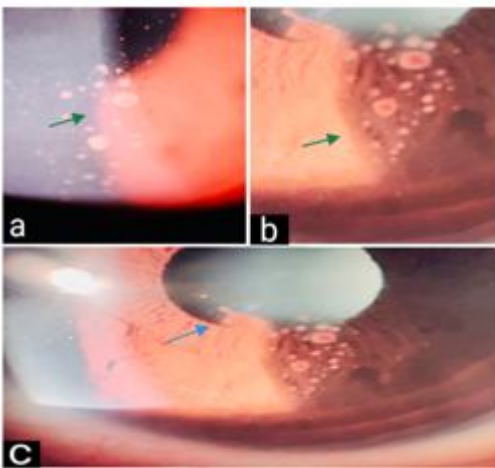


Fig 8-Slit Image showing keratic precipitates (KPs) on endothelium, 3+anterior chamber cells and few vitreous cells were seen in both eyes

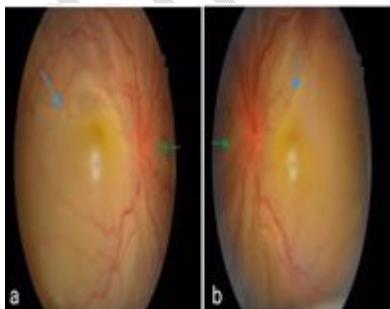


Fig 9-Fundus Photo showed hyperaemic discs, exudative retinal detachment with shifting fluid with no retinal breaks

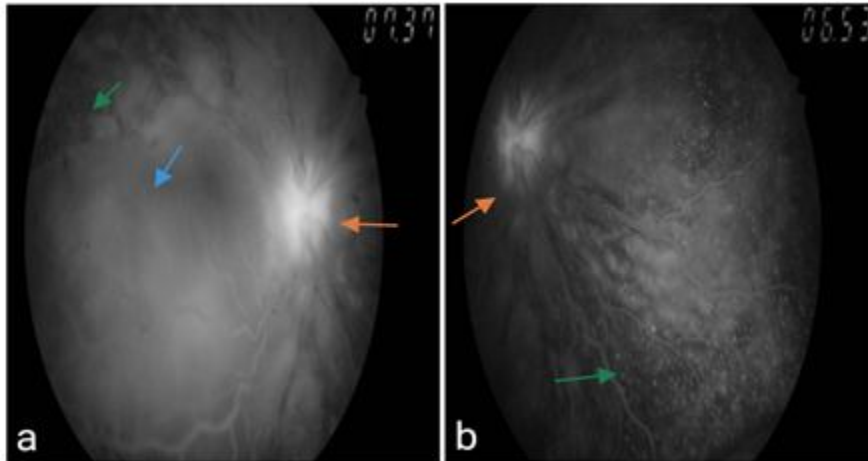


Fig 10- FFA image showed pin point leaks in both eyes along with disc hyper fluorescence

## DISCUSSION:

The exact etiology of the disease is incompletely understood. Although, the most proposed mechanism is an autoimmune reaction allegedly CD4+ T lymphocytes against melanocytes in a genetically susceptible individual usually after a viral trigger.[3]

The disease presents in 4 distinct phases namingly, prodromal stage presenting with fever, headache, nausea, vertigo, orbital pain, photophobia, tearing, tinnitus, vertigo and neurologic symptoms. In this stage, photophobia, tearing, tinnitus, vertigo and neurologic symptoms predominate. In this stage, cerebrospinal fluid may reveal pleocytosis.

Next is acute uveitic stage showing diffuse choroiditis with Exudative RD, optic disc swelling, convalescent stage shows integumentary findings like poliosis, vitiligo, and alopecia lasting for months to years. Pathognomic ocular finding in this being the sunset glow fundus. Last is recurrent or chronic stage with recurrent anterior uveitis.[4]

VKH can sometimes present as sclerouveitis leading to a diagnostic dilemma as observed in our first patient who was diagnosed as a case of TB sclerouveitis keeping in mind that India is endemic to TB.

Vice versa, cases of TB uveitis which were mistakenly diagnosed as VKH were reported previously.[5]

Pregnancy is known to cause depression of cellular immunity which is reversed during the post partum period. These changes in the cellular immunity during pregnancy can influence the course VKH, as the pathological mechanism of the condition is believed to be cellular autoimmune response to melanocyte containing tissues.

However, immunological influence of pregnancy on VKH has not been clarified yet. Various cases have been reported of patients with VKH in pregnancy.[6,7]

The cases reported previously, majorly showed two patterns. One is where known cases had gone into remission during pregnancy with later recurrences and the others developed VKH during pregnancy and were treated. Various treatment modalities are also proposed including topical and steroids depending on the trimester of pregnancy.[7] Our second case shows the second pattern. She improved dramatically with high dose oral steroids.

**Varicella zoster virus** is actually stated as the most common viral infection reported in systemic lupus erythematosus patients. Chen D et al observed that there is a 3.6% incidence of VZV in **systemic lupus erythematosus** patients, lymphopenia and high dose steroids being the main culprits. They also stated that highest risk is between 3-6 months of SLE diagnosis which reduces later.[8]

Similar instance is observed in our third patient. The significance of viral trigger in incidence of VKH disease is well established although incompletely understood.

This supports the possibility of causation of VKH post herpes infection in our patient.

VKH has been associated with various vaccines such as Hepatitis B, Hepatitis C, and yellow fever as well as a few biological drugs used in anti-cancer therapy.[9,10,11] This can be attributed to the immunogenetic dysregulation that can be caused by the latter. The etiology of the occurrence of autoimmune diseases post-vaccination is unclear. However, Molecular mimicry, Bystander activation of sequestered self-antigens, Cytokines secretion from macrophages, genetic polymorphisms are the 4 possible mechanisms of the same. There are high chances that similar effects can trigger autoimmune response post-Covid vaccination. This is also supported by the reported cases of other autoimmune conditions like Guillain-Barre Syndrome, Systemic Lupus Erythematosus post-vaccination.[12] Our fourth patient showed an intriguing association of onset of Harada syndrome and Covishield vaccination which is justified by the acute worsening of the condition on the second dose despite ongoing steroid.

## CONCLUSIONS:

This study shows variable etiology and multisystem involvement of VKH syndrome and the management criteria. VKH syndrome is an important differential diagnosis in all patient's presenting with sudden blurring of vision with headache. Patients presenting with VKH should be started on high dose steroids with regular monitoring.

## REFERENCES:

- 1.Lavezzo, M.M., Sakata, V.M., Morita, C. et al. Vogt-Koyanagi-Harada disease: review of a rare autoimmune disease targeting antigens of melanocytes. *Orphanet J Rare Dis* 11, 29 (2016).
- 2.Herbort CP, Mochizuki M. Vogt-Koyanagi-Harada disease: inquiry into the genesis of a disease name in the historical context of Switzerland and Japan. *Int Ophthalmol.* 2007;27(2–3):67–79.
- 3.Greco A, Fusconi M, Gallo A, et al. Vogt-Koyanagi-Harada syndrome. *Autoimmun Rev.* 2013 Sep;12(11):1033-8. doi: 10.1016/j.autrev.2013.01.004
- 4.Burkholder, Bryn M. Vogt–Koyanagi–Harada disease, *Current Opinion in Ophthalmology*: November 2015 - Volume 26 - Issue 6 - p 506-511
- 5.Tian-Wei Qian et al, *Int J Ophthalmol* 2018;11(8):1430-1432.
- 6.Nohara, M & Norose, Kazumi & Segawa, K. (1995). Vogt-Koyanagi-Harada disease during pregnancy. *The British journal of ophthalmology.* 79. 94-5. 10.1136/bjo.79.1.94.
- 7.Miyata N, Sugita M, Nakamura S, et al. Treatment of Vogt-Koyanagi- Harada's disease during pregnancy. *Jpn J Ophthalmol.* 2001 Mar-Apr;45(2):177-80. doi: 10.1016/s0021-5155(00)00357-9.
- 8.Chen D, Li H, Xie J, Zhan Z, Liang L, Yang X. Herpes zoster in patients with systemic lupus erythematosus: Clinical features, complications and risk factors. *Exp Ther Med.* 2017 Dec;14(6):6222-6228. doi: 10.3892/etm.2017.5297. Epub 2017 Oct 12. PMID: 29285180; PMCID: PMC5740583.
- 9.Campos WR, Cenachi SPF, Soares MS, et al. Vogt-Koyanagi-Harada-like disease following yellow fever vaccination. *Ocul Immunol Inflamm* 2021;29(1):124–7.
- 10.Sood AB, O'Keefe G, Bui D, Jain N. Vogt-Koyanagi-Harada Disease Associated with Hepatitis B Vaccination. *Ocul Immunol Inflamm.* 2019;27(4):524-527.
- 11.Crosson JN, Laird PW, Debiec M,et al. Vogt-Koyanagi-Harada-like syndrome after CTLA-4 inhibition with ipilimumab for metastatic melanoma. *J Immunother.* 2015 Feb-Mar;38(2):80-4.
- 12.Patel SU, Khurram R, Lakhani A, Quirk B. Guillain-Barre syndrome following the first dose of the chimpanzee adenovirus-vectored COVID-19 vaccine, ChAdOx1. *BMJ Case Rep* 2021;14(4):e242956.

UNDER PEER REVIEW