

Oxidative Stress Potential, Genotoxic and Histopathological Effects of Ethanolic Extract of *Alternantheraphiloxeroides* on *Clariasgariepinus*(Cat Fish)

ABSTRACT

This study used static bioassay to evaluate oxidative and genotoxic effect caused by ethanolic extract of *A. philoxeroides* in the liver of *C. gariepinus* as well as the Histopathological damages caused by the extract on the liver, gills and intestine of the fish. LC₅₀ of the ethanolic extract of *A. philoxeroides* was determined by probit regression analysis. Fishes were exposed to the sublethal concentration of the extract at the rate of 1% and 10% concentration of the LC₅₀ value in replicate for 21 days. During the course of exposure the fishes exhibited some behavioral changes such as erratic swimming pattern, restlessness and excessive mucus secretion. The oxidative stress study revealed that antioxidant enzyme activities were lower in the liver suggesting deficiency of the antioxidant system to compensate for oxidative stress. DNA damage was high in liver of the exposed fish indicating genotoxic effects. The histological structure of the liver of the fish showed the presence of traces to mild onset of nuclei degeneration. The gills of fish exposed to the extract showed severe collapse of the secondary lamella in conjunction with hyperplasia of the pillar cells within the lamella as well as severe atrophy of the cells, degeneration of the primary lamella and severe cellular and structural damages of the gills. The intestine of the fish group exposed to the extract revealed a small amount of PAS-positively stained substances in the lamina propria, mucus cells and the apical borders of the epithelial cells showing the presence of mucous substances. This study concluded that exposure of *C. gariepinus* to ethanolic extract of *Alternantheraphiloxeroides* have the ability to negatively affect the behavior, suppress the activities of major antioxidant enzymes of the liver thereby causing oxidative stress, with consequent degeneration of liver and gill tissue which expresses its genotoxicity.

Keywords: Oxidative stress; genotoxic; hyperplasia; probit.

1. INTRODUCTION

A leafy vegetable called *Alternantheraphiloxeroides* (Mart.) Griseb is frequently referred to as "Alligator weed" in English and "Malancha" in Bengali [1,2,3]. Alligator weed contains phytochemicals like saponin, alkaloids, flavonoids, tannin, and cardiac glycoside [4]. It is collected and sold in the local markets on a large scale [5]. Studies have also shown that this plant contains significant levels of nutrients, minerals, amino acids and secondary metabolites [6,7]. It has also been shown to have great potential phytoremediation and antioxidant activities [8,9].

Being an invasive weed around the globe, the plant *A. philoxeroides* has been regarded to have long-standing traditional medicinal uses, especially against viral infectious diseases [3]. According to Akbar et al. [2], this plant is of great therapeutic potential. Other studies have also

shown the plant to be very popular in the treatment of different health complications such as night blindness, coughing up blood, hematuria, measles, cold and pyrexia, stranguria with turbid urine, encephalitis B, anthracis, eczema, venomous snake bite, and furunculosis [10,11].

Alternantheraphiloxeroides have been reported to have a potential performance in free radical scavenging capacity with high antioxidant activity against in vitro oxidative stress [12]. In in-vitro studies, Glutathione-S-transferases, superoxide dismutase, catalase, reduced glutathione, and the lipid peroxidation biomarker malondialdehyde are examples of commonly used oxidative stress indicators in ecosystem monitoring [13] including the aquatic ecosystem. These biomarkers give an indication of how well organismal systems are able to combat the assault of free radicals and reactive oxygen species [14].

However, despite all the medicinal and antioxidant qualities of this plant on human and other terrestrial mammals, there is a dearth of information on its significance on culturable fish species. This study therefore focused on the antioxidant effect of *A. philoxeroides* extract on *Clariasgariepinus*, being a universally cultured fish species. This study also evaluated the effect of this plant extract on the fish health using organs histological changes since histological changes have been described as a sensitive bio monitoring tool on fish health [15,16]. Also, formation of micronucleus cells was also monitored using genotoxicity test to determine the safety of this plant extract on the fish [17]. The objective of this study was to evaluate the oxidative, genotoxic and the histopathological effect of the ethanolic extract of *Alternantheraphiloxeroides* on *Clariasgariepinus*.

2. MATERIALS AND METHODS

2.1 Plant Collection and Preparation

Fresh plants of *Alternantheraphiloxeroides* was collected from Lagos mainland at the University of Lagos with the coordinate of 6.50259° N, 3.39689° E. The plant was sorted and air dried at room temperature for 14 days. The whole plant was grinded using a mechanical grinder and the powdered form of the plants was then stored in a tight transparent container and clearly labeled before the extraction procedure begins.

2.2 Phytochemical Screening

The grinded plant sample was subjected to phytochemical tests to identify and determine the chemical constituents present quantitatively and qualitatively. This was carried out at the Biochemistry Department of the Nigerian Institute of Medical Research (NIMR). Phytochemical screening was carried out on the aqueous, ethanol extracts and the powdered sample to identify the constituents as described by Edeogaet *al.*, [18] with slight modification.

2.3 Experimental Animals Collection and Acclimatization

Two hundred fingerlings of *Clariasgariepinus* (catfish) were obtained from the area of Makoko, Lagos state. The fishes were kept in a nylon bag and were oxygenated, it was then transported to the laboratory for acclimatization. The fishes were transferred into a pre-cleaned transparent container and the tank

was covered with a net without feeding for 24hrs. The water was changed after 24 hrs and dechlorinated water was added to the tank and left for another 12hrs before feeding. Immediately the process of acclimatization started with daily feeding and water was changed at an interval of 2 days within the 14 days acclimatization so that they can properly adapt to the laboratory environment.

2.4 Experimental Procedures

2.4.1 Range finding test

Range finding test was conducted following standard procedures, to determine range of concentration for the definitive test (Acute toxicity test). The test was conducted in a white rectangular plastic container (37.5 × 24 × 22cm, 10L capacity). The range finding test was carried out using four treatments (0.1g/L, 0.5g/L, 1g/L and 1.5g/L). Each treatment had two replicates with ten (10) fishes introduced into them. The experiments were carried out under standard bioassay procedures and the experiment was monitored at 3 hours interval and lasted for 24 hours. *Clariasgariepinus* mortality was recorded and failure to respond to external stimuli was used as criteria for death.

2.4.2 Acute toxicity test

Four (4) different bioassays were prepared with different concentration in 2 litres of water, the concentrations are as follows; 500mg/l, 700mg/l, 900mg/l, 1100mg/l and a control was also provided as a blank bioassay, 5 fingerlings of catfish was introduced into each bioassay making a total of 10 fishes per concentration. The setup was observed for 96hrs, observation was taken at 24hrs interval.

2.4.3 Sublethal toxicity testing

The concentration used for the sublethal testing was determined by the LC₅₀. The least concentration was 1% and the highest concentration was 10% of the LC₅₀ value as described by Muyiwa, *et al* [19]. Each concentration was prepared in duplicates (A&B) and also a control (having zero concentration of the plant extract). Each concentration was made in a transparent plastic container having 2L of water and 10 fishes was introduced into each of the plastic container and the fishes and fed with 0.5mm of aller feed containing 60% crude protein, 15% crude fat, 12.6% Ash, 0.7% Fibre. The fishes in each exposure containers were fed

once in two days and the water is changed at four days interval where observations will as well be recorded. The exposure lasted 21 days, and the feeding was stopped 24hrs to the end of the exposure and the test organisms were prepared for further testing.

2.5 Behavioral Studies

The behavioral responses of *Clarias gariepinus* fingerlings to ethanolic extract of *A. Philoxeroide* in the treatment groups and the mortality rate was observed on daily basis and recordings was made at 3 days interval for 21 days exposure time. The expected responses are aggressiveness, erratic swimming pattern, loss of reflex, discoloration, moulting, gulping of air, restlessness, spiral movements and excessive mucus secretion.

2.6 Antioxidants and Oxidative Stress

2.6.1 Homogenizing sample

The dissected liver and intestine were removed and weighed. The organs were homogenized with 0.1 phosphate buffer (PH 7.2) putting the organ each into the mortar and was blended with a pestle together. The resulting homogenate was centrifuged at 2500RPM for 15minutes. The supernatant was decanted and stored at -20°C.

2.6.2 Determination of catalase activity

Catalase (CAT) was assayed using colorimetric method at 620nm and expressed as moles of hydrogen peroxide (H_2O_2) consumed/min/mg protein. 1.0ml of 0.01M pH 7.0 phosphate buffer, 0.1ml of Plasma and 0.4ml of 2M H_2O , made up the reaction mixture (1.5ml). The addition of 2.0ml of dichromate-acetic acid reagent (5% potassium dichromate and glacial acetic acid were mixed in 1:3 ratio) stopped the process.

2.6.3 Determination of Reduced Glutathione (GSH)

The method of Ellman, G. L. [20] was used to determine reduced glutathione (GSH) was determined. 10% TCA (equal volume) was added to the homogenate added and centrifuged. 0.5 ml of Ellmans reagent (19.8 mg of 5, 5'-dithiobisnitro benzoic acid (DTNB) in 100 ml of 0.1% sodium nitrate) and 3.0 ml of phosphate buffer (0.2M, pH 8.0) were added to 1.0 ml of supernatant. At a wavelength of 412 nm, the absorbance was measured.

2.6.4 Determination of Glutathione Peroxidase (GPx)

0.2ml of 0.4M phosphate buffer pH 7.0, 0.1ml of 10mM sodium azide, 0.2ml of plasma, 0.2ml of glutathione salt (GSH) and 0.1ml of 0.2mM H_2O_2 were added to evaluate glutathione peroxidase (GPx) activity. The mixture was incubated at 37°C for 10mins. The reaction was arrested by 0.4ml of 10% TCA, and centrifuged. Ellman's reagent was used to measure the glutathione content of the supernatant.

2.6.5 Lipid peroxidation

Malondialdehyde (MDA) an index of lipid peroxidation was determined using the method of Buege and Aust (1978). 1.0 ml of the supernatant was added to 2 ml of (1:1:1 ratio) TCA- TBA-HCl reagent (thiobarbituric acid 0.37%, 0.24N HCl and 15% TCA) tricarboxylic acid- thiobarbituric acid-hydrochloric acid reagent boiled at 100°C for 15 minutes and allowed to cool. Flocculent materials were removed by centrifuging at 3000 rpm for 10 min. The supernatant was removed and the absorbance read at 532 nm against a blank. MDA was calculated using the molar extinction coefficient for MDATBA- complex of $1.56 \times 10^5 \text{ M}^{-1}\text{CM}^{-1}$.

2.6.6 Determination of superoxide dismutase (SOD) activity

Total SOD activity in tissue homogenates assessed using a modified version of the Marklund and Marklund technique. The approach is based on SOD's ability to inhibit the autoxidation of pyrogallol. In 970uL of buffer (100mMTris-HCl, 1mM EDTA, pH 8.2), 10uL of homogenates and 20uL pyrogallol (13Mm) were combined. At 25°C, assay was carried out in thermostated cuvettes and variations of absorbance were measured using a spectrophotometer set to 480nm. The amount of enzyme can inhibit the auto-oxidation of 50% the total pyrogallol in the process is defined as one unit of SOD activity.

2.7 Methodology for Micronucleus Assay

Blood samples were obtained from the caudal vein of the fish using a syringe [21]. The blood was then smeared on glass slides per concentration. According to the method used by George *et al.* [14], the smeared slides were air-dried overnight at room temperature, then, fixed in absolute ethanol and allowed to dry for 15 minutes. They were stained with May-Grunwald stain for 10 minutes, and then counter stained

with 5% Giemsa for another 10 minutes, rinsed very slightly through tap water and allowed to dry. The slides were analyzed at 100x (oil immersion) for micronucleus and other nuclear abnormalities under a light microscope (Olympus CHC Model). The micronuclei were characterized by the presence of a small cell inclusion detached from a larger definite nucleus, while those with two joined nuclei of equal size were defined as binucleated. Other cells with eight-shape and notched were also observed. The cells were counted using a hand-held counter (Counter Compass: No. 7777, China).

2.8 Histopathology Studies

The fingerlings were dissected to collect the gills, intestine and livers. The harvested organs were then preserved with Bouin's fluid, stored in a universal bottle. These tissues were fixed in 10% formal saline, dehydrated in graded alcohol, cleared in xylene before embedding in paraffin wax. Serial sections of 5-6 μm thickness were cut using rotary microtome (Model: MSLK236, manufacturer: Lake-link Nigeria company, Agege), then passed through xylene followed by absolute alcohol and water. The sections were stained with haematoxylin and eosin, dehydrated in graded alcohol, cleared in more xylene and mounted in Canada balsam. The slides were left to dry on a hot plate for 2 hours before observation under the light microscope.

2.9 Methods of Data Analysis

Data obtained were subjected to statistical analyses using the Statistical Package for Social Sciences (SPSS) version 20.0 [22]. Mean values were compared using one-way analysis of variance (ANOVA). Results were presented as Mean \pm Standard deviation. Post hoc test was done using the Student-Newman-Keuls (SNK). P – value less than 0.05 was considered to be statistically significant.

3. RESULTS

3.1 Phytochemical Screening Result

The tables below show the Phytochemical parameters carried out on the ethanol extracts and the powdered sample of *Alternantheraphiloxeroides*.

Table 1. Qualitative parameters of dried *Alternantheraphiloxeroides*

S/N	Metabolites	Result
-----	-------------	--------

1	Saponins	+
2	Alkaloids	+
3	Flavonoids	+
4	Tannins	+
5	Cardiac glycoside	-
6	Steroids	-
7	Phenolic	+

Table 2. Quantitative parameters of dried *Alternantheraphiloxeroides*

S/N	Metabolites	Result (%)
1	Saponins	2.1
2	Alkaloids	3.2
3	Flavonoids	3.14
4	Tannins	1.34
5	Phenolic	0.32

3.2 Behavioral Studies

Table 3 reveals the behavioral studies of the exposed fishes at 21days having the control set up to be free of all reactions. The 1% and 10% set up was observed to have experienced restlessness, spiral movement and excessive mucus secretion.

Table 3. Physical responses of *Clariasgariiepinusto* the ethanolic extract of *A. Philoxeroide*

S/N	Reactions	Control	1%	10%
1	Aggressiveness	-	-	-
2	Erratic swimming pattern	-	-	+
3	Loss of reflex	-	+	+
4	Discoloration	-	-	-
5	Molting	-	-	-
6	Incessant gulping of air	-	+	+
7	Restlessness	-	+	+
8	Spiral movement	-	+	+
9	Excessive mucus secretion	-	+	+

3.3 Levels of Oxidative Stress Markers

3.3.1 Reduced glutathione (GSH)

The levels of reduced glutathione (GSH) recorded in the liver of *Clariasgariiepinus* exposed to ethanolic extract of Alligator weed, *Alternantheraphiloxeroides* are shown in Fig. 1. Levels of GSH recorded in the control *C. gariiepinus* group and those exposed to 1% ethanolic extract of alligator weed were higher and not significantly different ($p > 0.05$). On the other hand, level of GSH was lowest in the *C. gariiepinus* exposed to 10% ethanolic extract of alligator weed.

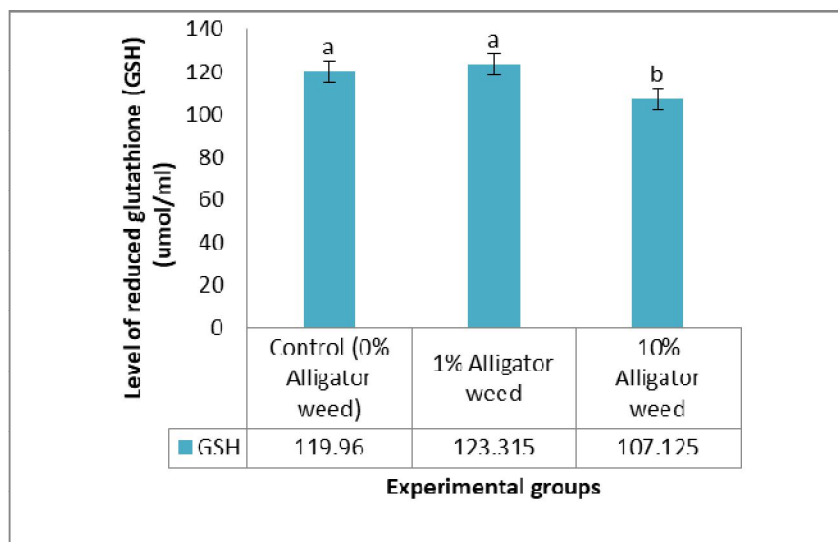


Fig. 1. Level of reduced glutathione (GSH) in the liver of *C. gariepinus* exposed to ethanolic extract of Alligator weed; ^{abc}Bars with similar alphabets are not significantly different ($p > 0.05$); Error bars represents standard deviation

3.3.2 Superoxide dismutase (SOD)

Fig. 2 shows the levels of superoxide dismutase (SOD) recorded in the liver of the experimental *C. gariepinus* exposed to ethanolic extract of alligator weed. Level of SOD was significantly highest ($p < 0.05$) in the control *C. gariepinus*. This was followed by those exposed to 1% ethanolic extract of alligator weed. Level of SOD was however lowest in the *C. gariepinus* exposed to 10% ethanolic extract of alligator weed.

3.3.3 Catalase (CAT)

Level of catalase was highest in the liver of *C. gariepinus* exposed 1% ethanolic extract of alligator weed (Fig. 3). This was followed by the control *C. gariepinus*. Level of catalase was lowest in the *C. gariepinus* exposed to 10% ethanolic extract of alligator weed. However, the level of catalase recorded in the control *C. gariepinus* and those exposed to 1% and 10% ethanolic extract of alligator weed were not significantly different.

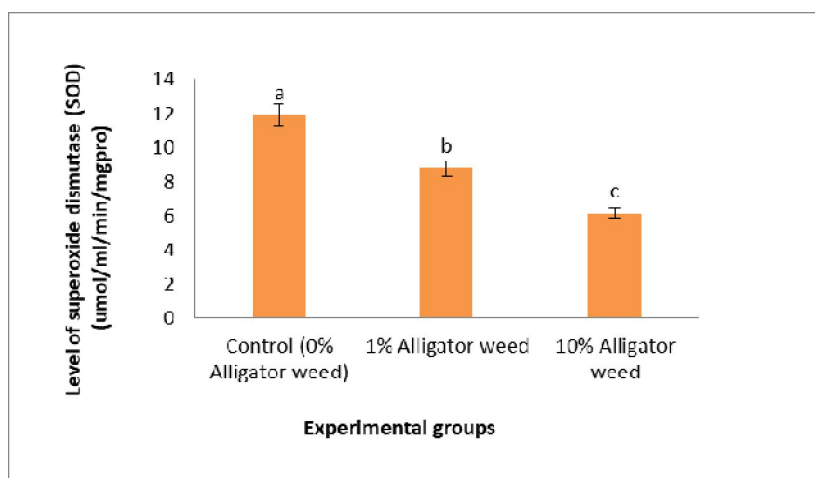


Fig. 2. Level of superoxide dismutase (SOD) in the liver of *C. gariepinus* exposed to varying proportion of Alligator weed; ^{abc}Bars with similar alphabets are not significantly different ($p > 0.05$); Error bars represents standard deviation

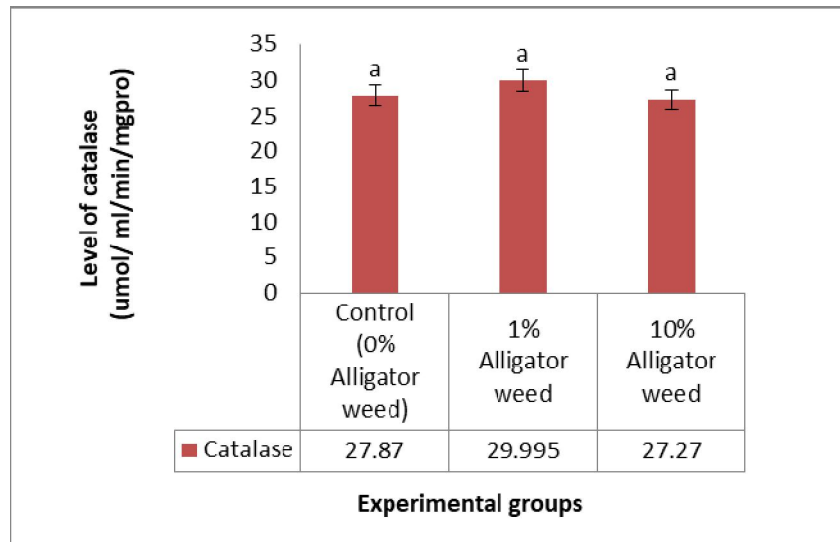


Fig. 3. Level of catalase in the liver of *C. gariepinus* exposed to varying proportion of Alligator weed; ^{abc}Bars with similar alphabets are not significantly different ($p > 0.05$); Error bars represents standard deviation

3.3.4 Glutathione-S-transferase (GST)

Level of glutathione-S-transferase (GST) was observed to significantly reduce in the liver of the experimental *C. gariepinus* with increase in the percentage of exposure to ethanolic extract of alligator weed (Fig. 4). Level of GST was significantly highest in the control *C. gariepinus*. This was followed by those exposed to 1% ethanolic extract of alligator weed. *C. gariepinus* exposed to 10% ethanolic extract of alligator weed however recorded the lowest GST level.

3.3.5 Malondialdehyde (MDA)

The levels of malondialdehyde (MDA) used as lipid peroxidation marker in the liver of the experimental *C. gariepinus* are represented in Fig. 5. Levels of MDA recorded in all the experimental were not significantly different. However, level of MDA was highest in the control *C. gariepinus*. This was followed by those exposed to 1% and 10% ethanolic extract of alligator weed.

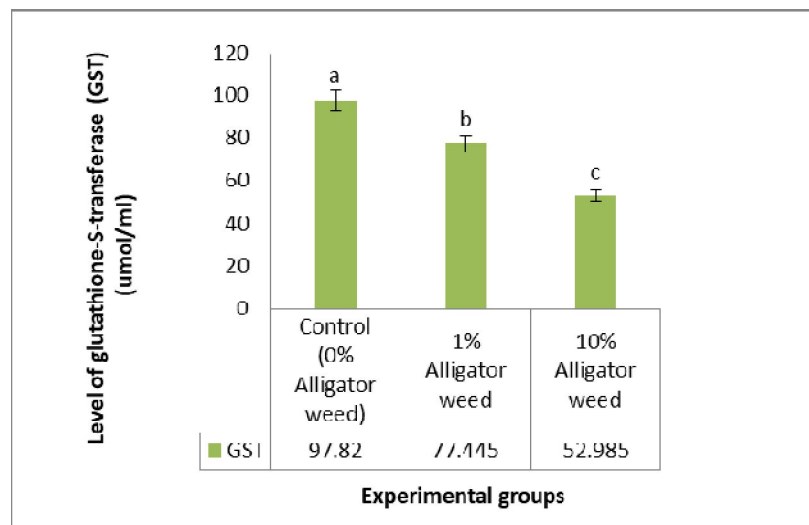


Fig. 4. Level of glutathione-S-transferase (GST) in the liver of *C. gariepinus* exposed to varying proportion of Alligator weed; ^{abc}Bars with similar alphabets are not significantly different ($p > 0.05$); Error bars represents standard deviation

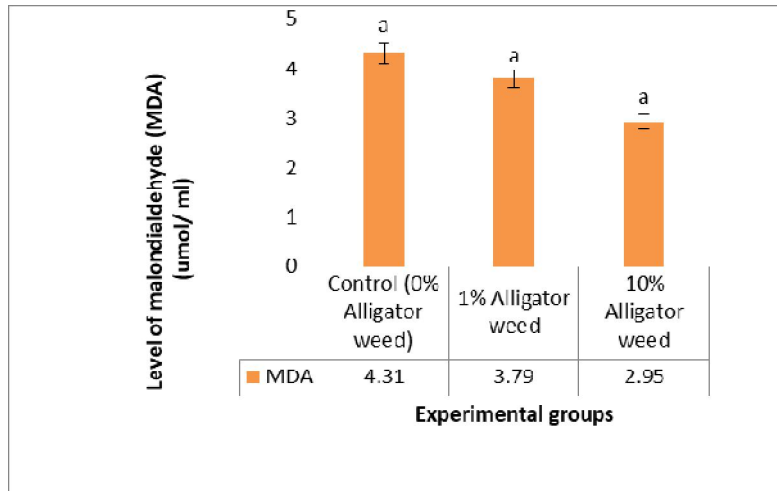


Fig. 5. Level of lipid peroxidation [Malondialdehyde – MDA] in the liver of *C. gariepinus* exposed to varying proportion of Alligator weed; ^{abc} Bars with similar alphabets are not significantly different ($p > 0.05$); Error bars represents standard deviation

3.4 Micronucleus Assay

ethanolic extract of Alligator weed and lowest in the control.

3.4.1 Numbers of micronucleated cells

The mean numbers of micronucleated cells of tilapia fish exposed to ethanolic extract of Alligator weed, *Alternanthera philoxeroides* are shown in Figure 6. Results showed significant increase in the mean number of micronucleated cells in the experimental fish with increased concentration of exposure to ethanolic extract of Alligator weed. Mean number of micronucleated cells was significantly highest in the fish exposed to 10% ethanolic extract of Alligator weed. This was followed by those exposed to 1%

3.4.2 Numbers of bi-nucleated cells

Fig. 7 represents the mean numbers of bi-nucleated cells in the tilapia fishes exposed to ethanolic extract of Alligator weed. Mean number of bi-nucleated cells was significantly lowest in the control fishes. On the other hand, mean number of bi-nucleated cells recorded in the fishes exposed to 1% and 10% ethanolic extract of Alligator weed were high and not significantly different.

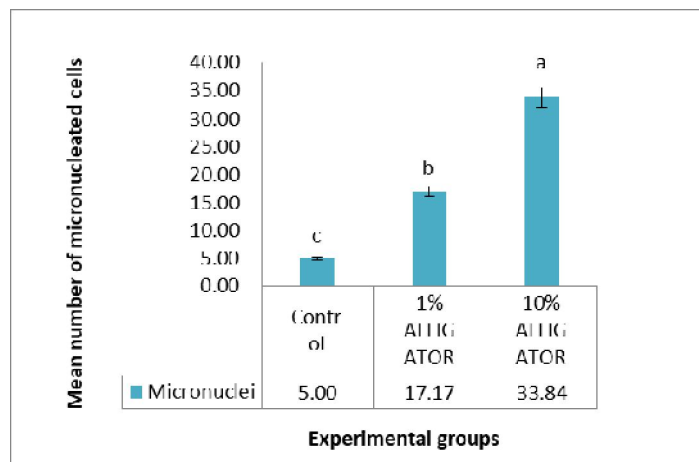


Fig. 6. Mean numbers of micronucleated cells of tilapia fish exposed to ethanolic extract of Alligator weed, *Alternanthera philoxeroides*; ^{abc} Bars with similar alphabets are not significantly different ($p > 0.05$); Error bars represents standard deviation

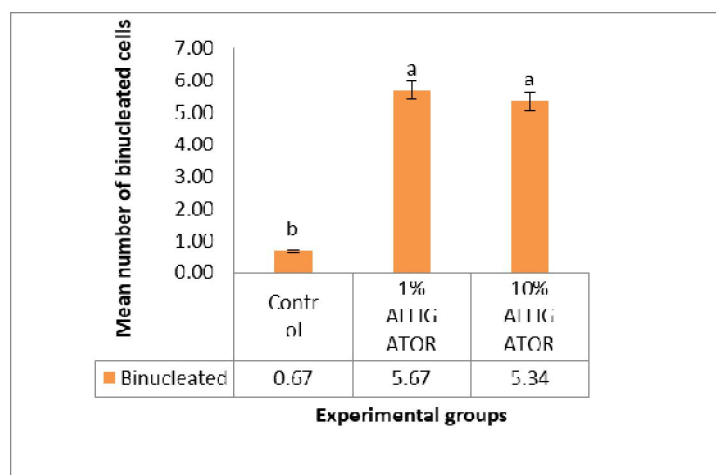


Fig. 7. Mean numbers of bi-nucleated cells of tilapia fish exposed to ethanolic extract of Alligator weed, *Alternantheraphiloxeroides*; ^{abc} Bars with similar alphabets are not significantly different ($p > 0.05$); Error bars represents standard deviation

3.4.3 Numbers of eight-shaped cells

The mean number of eight-shaped cells of cat fish exposed to ethanolic extract of Alligator weed is presented in Figure 8. Mean number of eight-shaped cells was highest in the tilapia fishes exposed to 10% ethanolic extract of Alligator weed. This was not significantly different from those exposed to 1% ethanolic extract of Alligator weed. Mean number of eight-shaped cells was significantly lowest in the control group. Mean numbers of eight-shaped cells was however observed to increase in the cat fishes

with increased concentration of exposure to ethanolic extract of Alligator weed.

3.4.4 Numbers of notched cells

Fig. 8. The mean numbers of notched cells recorded in the control tilapia fish and those exposed to 1% and 10% ethanolic extract of Alligator weed are shown in Fig. 9. Mean number of notched cells recorded in the all the experimental groups was not significantly different. However, this was lowest in the group exposed to 1% ethanolic extract of Alligator weed.

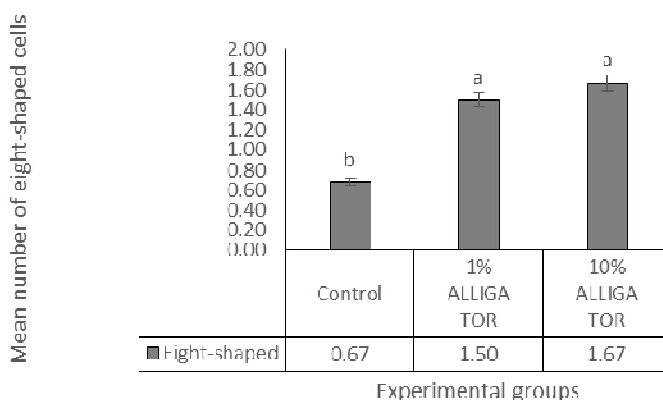


Fig. 8. Mean numbers of eight-shaped cells of cat fish exposed to ethanolic extract of Alligator weed, *Alternantheraphiloxeroides*; ^{abc} Bars with similar alphabets are not significantly different ($p > 0.05$); Error bars represents standard deviation

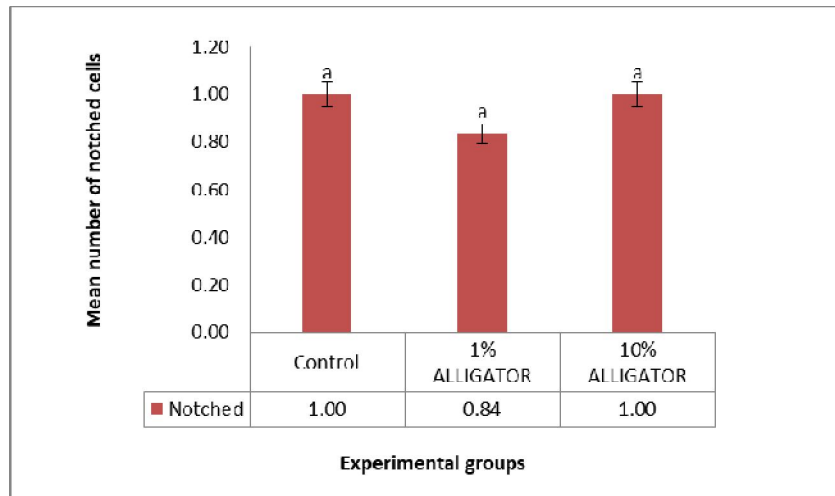


Fig. 9. Mean numbers of notched cells of tilapia fish exposed to ethanolic extract of Alligator weed, *Alternanthera philoxeroides*; ^{abc}Bars with similar alphabets are not significantly different ($p > 0.05$); Error bars represents standard deviation

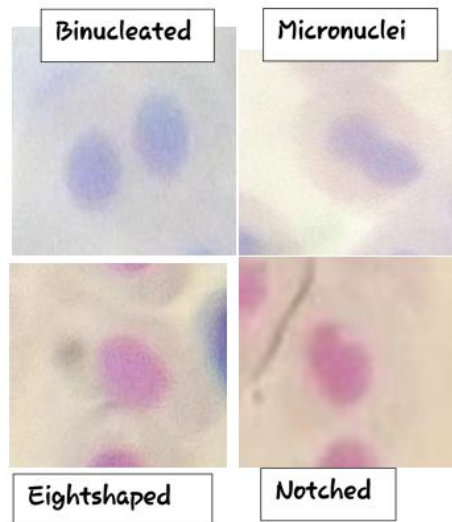


Fig. 10. Photomicrograph of typical blood smear showing abnormalities observed in the erythrocyte of some of the juvenile African Catfish, *Clarias gariepinus* exposed to the alligator weed extracts

3.5 Histopathological Evaluation

3.5.1 Histopathology of the liver

The histopathological evaluation of the liver of catfish exposed to ethanolic extract of Alligator weed, *Alternanthera philoxeroides* is shown in Fig. 1. The liver structure of the control catfishes showed normal histology architecture. Similarly,

the histological structure of the liver of the catfish exposed to 1% ethanolic extract of alligator weed showed normal histology of the liver hepatocytes central vein epithelial layer and hepatocytes. However, liver of catfish exposed to 10% ethanolic extract of alligator weed showed normal histoarchitectural arrangement with presence of traces to mild onset of nuclei degeneration.

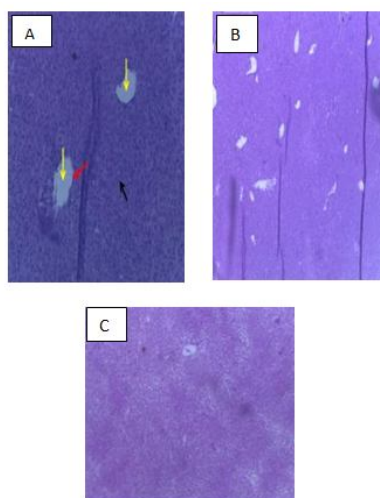


Plate 1. Histopathology of the liver of catfish exposed to ethanolic extract of Alligator weed, *Alternanthera philoxeroides*; A = Control; B = 1% ethanolic extract of alligator weed; C = 10% ethanolic extract of alligator weed; liver hepatocytes Central vein (Yellow arrow); Epithelial layer (Red arrow); Hepatocytes (Black arrow); Haematoxylin and Eosin stain, $\times 400$

3.5.2 Histopathology of the gills

Plate 2 shows the histopathological evaluation of the gills of catfish exposed to ethanolic extract of Alligator weed, *Alternanthera philoxeroides*. Normal pillar cells and epithelial cells located within and lining the secondary lamella respectively were observed in the gills of the control fish. Also, the nuclei material of the cells appeared darkly stained inferring active mitotic activities. On the other hand, the gills of catfish exposed to 1% ethanolic extract of alligator weed showed severe collapsed of the secondary lamella in conjunction with hyperplasia of the pillar cells within the lamella as well as severe atrophy of the cells and degeneration of the primary lamella. The gills of catfish exposed to 10% ethanolic extract of alligator weed however revealed a severe cellular and structural damage of the gills.

3.5.3 Histopathology of the intestine

Histopathological evaluation of the intestine of catfish exposed to ethanolic extract of Alligator weed, *Alternanthera philoxeroides* is shown in Fig. 1. The intestine of the control fish group showed neutral mucous substances secreted by the stomach epithelium. However, the intestine of the catfish group exposed to 1% ethanolic extract of alligator weed revealed a small amount of PAS-positively stained substances in the lamina propria. On the other hand, the intestine of the fish exposed to 10% ethanolic extract of alligator weed extract revealed mucus cells and the apical

borders of the epithelial cells showing the presence of mucous substances.

4. DISCUSSION

This study has evaluated the effect of ethanolic extract of Alligator weed, *Alternanthera philoxeroides* exposure on the antioxidant system of the liver of *Clarias gariepinus*. Levels of glutathione-S-transferase (GST) and superoxide dismutase (SOD) were observed to significantly reduce with increased percentage exposure to ethanolic extract of *Alternanthera philoxeroides*. Glutathione S-transferases have been described as enzymes that generally catalyse the formation of conjugates between glutathione (GSH) and a wide variety of electrophilic compounds such as carcinogens, toxins, and drugs (Loguercio *et al.*, 1998; Hayes *et al.*, 2005). A high GST activity is therefore assumed to be strongly correlated with increased resistance to oxidative stress [23]. According to Rameshthangam and Ramasamy [24], reduction in the level SOD has been associated with increasing amount of reactive oxygen and hydroxyl radicals that inactivate the chemical structure of SOD and results into loss of enzyme activity. Thus, reduction in these two antioxidants in the liver of *C. gariepinus* exposed to ethanolic extract of Alligator weed suggests that this plant extract is capable of inhibiting the enzymes production by increasing free radical and peroxide processes which are mainly involved in the control of host antioxidant status (Skuratovskaya and Zavyalov, 2008). Levels of catalase recorded in the liver of *C. gariepinus*

exposed to 1% and 10% ethanolic extract of Alligator weed and those of the control group were not significantly different. This could be as a result of the shared role played by catalase in the antioxidant system. Previous study of Lijun et al. (2005) explained that superoxide radicals that are generated during oxidative stress are converted to H₂O₂ by the action of SOD, while the accumulation of H₂O₂ is jointly prevented in the cell by glutathione and catalase. However, consumption of *A. Philoxeroides* have been shown to pose health risks and health issues due to the presence of high level of heavy metals such as iron, zinc and cadmium which can cause tissue damage due to free radicals [5]. The presence of these metals in the alligator weed samples could possibly be the reason behind the suppression of antioxidant enzymes in catfish liver recorded in this study.

This study has also shown that exposure of *Clarias gariepinus* to ethanolic extract of Alligator weed, *Alternanthera philoxeroides* could be genotoxic, leading to the production of more micronucleated cells, bi-nucleated cells and eight-shaped cells. Micronucleus evaluation has been previously used to assess the level genetic damage in fish species as a result of their exposure to toxicants [25]. Elevation of the number of mucronucleated cells is therefore an

indication of genetic damage. The presence of micronucleus in cells is a reflection of structural and/or numerical chromosomal aberrations arising during mitosis [26]. Hence, exposure to ethanolic extract of alligator weed has the potential to initiate genetic damage in the *Clarias gariepinus*.

Lastly, this study has also evaluated the histopathology of the liver, gills and intestine of catfish exposed to ethanolic extract of Alligator weed, *Alternanthera philoxeroides*. Exposure of catfish to this plant extract does not show significant effect in the liver and intestine of the fish. It is therefore possible that the liver and intestine of the catfish exposed to ethanolic extract of alligator weed were not significantly affected because they were not in direct contact with this plant extract. On the other hand, structural damages of the gills were recorded in the catfish exposed to ethanolic extract of alligator weed. This structural damage was observed to increase with increased concentration of extract exposure. Changes in fish gills are among the most commonly recognized responses to environmental pollutants [27]. Hence, it is possible that the extract of alligator weed used in this study also contains some metals or toxic chemicals which have negative effects on the gills tissues.

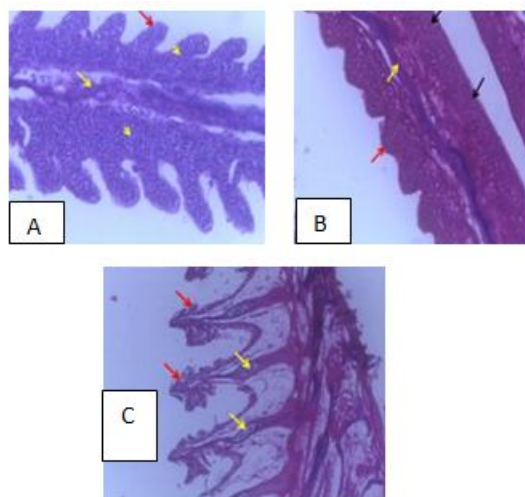


Plate 2. Histopathology of the gills of catfish exposed to ethanolic extract of Alligator weed, *Alternanthera philoxeroides*; A = Control; B = 1% ethanolic extract of alligator weed; C = 10% ethanolic extract of alligator weed; Red arrow: secondary lamella, yellow arrow: primary lamella, yellow arrow head: pillar cells, black arrow: collapsed secondary lamella; Haematoxylin and Eosin stain, x400

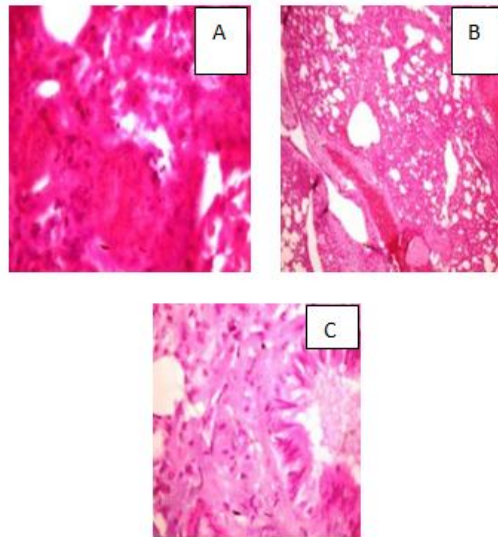


Plate 3. Histopathology of the intestine of catfish exposed to ethanolic extract of Alligator weed, *Alternanthera philoxeroides*; A = Control; B = 1% ethanolic extract of alligator weed; C = 10% ethanolic extract of alligator weed; Haematoxylin and Eosin stain, ×400

5. CONCLUSION

This study reveals that the ethanolic extract of *Alternanthera philoxeroides* have the ability to suppress the action of the antioxidants in the liver of *Clarias gariepinus* resulting into oxidative stress in catfish. Also, the study further reveals that the plant extract is capable of causing genotoxic effects of long-term exposure sublethal concentrations of ethanolic extracts of *Alternanthera philoxeroides* on *C. gariepinus*. This study has shown that exposure of *C. gariepinus* to ethanolic extract of Alligator weed, *Alternanthera philoxeroides* could be genotoxic, producing higher number of micronucleated cells, bi-nucleated cells and eight-shaped cells. This indicates that, its effect on lower biota and non-target organisms could even be far more devastating. This study also raises concerns about the mutagenicity of the ethanolic extract of the alligator weed not just on the fishes but to humans as well. Therefore, the use of the extracts of *A. philoxeroides* could lead to contamination of an ecological system, thus posing great threat to fish and other non-target organisms. Furthermore, based on the results of this study, exposure of catfish to ethanolic extract of Alligator weed, *Alternanthera philoxeroides* does not significantly affect the liver and intestine tissues. However, it resulted in the degeneration of the gills tissue at high concentration of exposure.

COMPETING INTERESTS

Authors have declared that no competing interests exist.

REFERENCES

1. Khatun, M., Hassan, M.A., Islam, S.N. and Rahman, M.O. Taxonomy of the leafy vegetables in Bangladesh. Bangladesh. Journal of Plant Taxonomy. 2013;20:95–123.
2. Akbar, M., Amin, A., Khalil, T., Iqbal, M.S., Nazir, A. and Taswar, A. (2021). Antibacterial activity of *Alternanthera philoxeroides* (Mart.) Griseb. against bacterial phytopathogens: *Erwinia carotovora*, *Ralstonia solanacearum* and *Xanthomonas axonopodis*. Allelopathy, 53:83–92.
3. Sunmathi, D. and Sivakumar, R. (2016). In Vitro cytotoxicity of ethanolic leaf extract of *Alternanthera sessilis* (L.) R. Br. Ex. DC and *Alternanthera philoxeroides* (Mart.) Griseb. Against human osteosarcoma cell line MG-63. Eur. J. Biomed. Pharm. Science, 3:416–420.
4. Oluwatoyin, A.S. (2011). Histopathology of Nile Tilapia (*Oreochromis niloticus*) juveniles exposed to aqueous and ethanolic extracts of *Ipomoea aquatica* leaf. International Journal of Fisheries and Aquaculture, 3:244–257.
5. Sateesh S, Boda R.K, and Majeti N.V. (2017). Health risks of leafy vegetable *Alternanthera philoxeroides* (Alligator weed) rich in phytochemicals and minerals.

- European Biotechnology Thematic Network Association, 1:293 – 302.
6. Bhatta R, Das TK. Chemical and amino acid composition of alligator weed (*Alternanthera philoxeroides*). *Indian Vet. J.*, 1996; pp. 799–800.
 7. Dutta P. Pharmacognostical evaluation and preliminary phytochemical analysis of *Alternanthera philoxeroides*. *Int. J. MediPharm Res* 2015; 1(1): 7–13.
 8. Prasad MNV, Freitas HM. Metal hyperaccumulation in plants – Biodiversity prospecting for phytoremediation technology. *Electronic J Biotech* 2003; 6(3): 285–321.
 9. Tukun AB, Shaheen N, Banu CP, Mohiduzzaman Md, Islam S, Begum M. Antioxidant capacity and total phenolic contents in hydrophilic extracts of selected Bangladeshi medicinal plants. *Asian Pacific J Trop Med* 2014; 7(1): S568–S573.
 10. Myanmar N. and S. America, “*Alternanthera philoxeroides* (Mart.) Griseb,” *Bulletin OEPP/EPPO Bulletin*, vol. 46, no. 1, pp. 8–13, 2016.
 11. Uddin, M. Traditional Knowledge of Medicinal Plants in Bangladesh, *Nature Info. Electronic Database*, 2019.
 12. Shahad S.K, Morshed A., Forhad U., Ummay M.S, Nafisa L., Tanusree A.M., Mahfuza M., Milon M., Md I.K., Nurul K., Md S.S., and Md Sakib Hossen (2022). Subchronic Toxicity Study of *Alternanthera philoxeroides* in Swiss Albino Mice Having Antioxidant and Anticoagulant Activities. *Journal of Toxicology*, Volume 2022, Article ID 8152820, 12 pages. <https://doi.org/10.1155/2022/8152820>
 13. Lijun, L., Xuemei, L., Yaping, G., & Enbo, M. (2005). Activity of the enzymes of the antioxidant system in cadmium-treated *Oxyechinus* (*Orthoptera: Acridoidea*). *Environmental Toxicology and Pharmacology*, 20, 412-416.
 14. George, O.O, Amaeze, N.H., Babatunde, E. and Otitoloju, A.A., (2017). Genotoxic, Histopathological and oxidative stress responses in catfish, *Clarias gariepinus*, exposed to two antifouling paints. *Journal of Health and Pollution*, 7: 71-82.
 15. Adeyemo OK. Histological alterations observed in the gills and ovaries of *Clarias gariepinus* exposed to environmentally relevant lead concentrations. *Journal of Environmental Health*. 2008; 70:48-51
 16. Van Dyk, J. C., Cochrane, M. J. and Wagenaar, G. M. (2012). Liver histopathology of the sharptooth catfish *Clarias gariepinus* as a biomarker of aquatic pollution. *Chemosphere*, 87:301-311.
 17. Ren, N., Atyah, M., Chen, W. Y., and Zhou, C. H. (2017). The Various Aspects of Genetic and Epigenetic Toxicology: Testing Methods and Clinical Applications. *Journal of Translational Medicine*, 15(1): 1-13.
 18. Edeoga, H.O., Okwu D.E. and Oyedemi B.M. (2005). Phytochemical constituents of some Nigerian medicinal plants. *African journal of biotechnology*, 4:685-688.
 19. Muyiwa, B.O., Sambo, J.S. and Oniye, S.J., (2019). Toxicological range finding test of aqueous extract of *Borreria verticillata* aerial parts in exposed African catfish *Clarias gariepinus* (Burchell 1822) Juveniles. *Toxicology: Open access*, an open access journal, 5:1-4.
 20. Ellman, G.L. (1959) Tissue Sulfhydryl Groups. *Archives of Biochemistry and Biophysics*, 82, 70-77.
 21. Mumuni, A. A., and Sogbanmu, T. O. (2018). Embryotoxic, Developmental and Genotoxic Evaluations of a Endosulfan and Deltamethrin Mixture On the African Sharptooth Catfish (*Clarias gariepinus*). *West African Journal of Applied Ecology*, 26(1): 1-10.
 22. IBM Corporation (2011) IBM SPSS statistics for Windows, version 20.0. Armonk, NY: IBM Corp.
 23. Fournier, D., Bride, J.M., Poirie, M., Berge, J.B. and Plapp, F.W. (1992). Insect glutathione S-transferases. Biochemical characteristics, of the major forms of house flies susceptible and resistant to insecticides. *Journal of Bio Chemical*, 267:1840–1845
 24. Rameshthangam, P. and Ramasamy, P. (2006). Antioxidant and membrane bound enzymes activity in WSSV-infected *Penaeus monodon* Fabricius. *Aquaculture*, 254: 32-39.
 25. Obiakor, M. O., Okonkwo, J. C., Nnabude, P. C., and Ezeonyejiaku, C. D. (2012). Eco-Genotoxicology: Micronucleus Assay in Fish Erythrocytes as in situ Aquatic Pollution Biomarker: A Review. *Journal of Animal Science Advances*, 2(1): 123-133.
 26. Sabharwal, R., Verma, P., Syed, M. A., Sharma, T., Subudhi, S. K., Mohanty, S., and Gupta, S. (2015). Emergence of Micronuclei as a Genomic Biomarker.

- Indian Journal of Medical and Paediatric Oncology, 36(4): 212-218.
27. Figueiredo-Fernandes, A.M, Fontai'nhas-Fernandes, A.A; Monteiro, R.F; Reis-Henriques, M.A.; Rocha, E. (2007). Spatial relationships of the intrahepatic vascular-biliary tracts and associated pancreatic acini of Nile tilapia, *Oreochromis niloticus* (Teleostei, Cichlidae): a serial section study by light microscopy. *Ann. Anat.*, 189:17–30.

© 2022 Ashade et al.; This is an Open Access article distributed under the terms of the Creative Commons Attribution License (<http://creativecommons.org/licenses/by/4.0>), which permits unrestricted use, distribution, and reproduction in any medium, provided the original work is properly cited.