

A RARE CASE REPORT ON BENIGN REACTIVE VASCULAR LESION WITH OSSEOUS METAPLASIA

ABSTRACT:

A plethora of pathologies occurs in the skeletal as well as the soft tissues of maxillofacial region and can be reactive. These lesions present with varied radiological and histological features and they can pose a diagnostic dilemma to the clinician. Our article reports a rare case of benign reactive vascular lesion with osseous metaplasia with an emphasis on correlating the clinical and investigational findings to arrive at the correct diagnosis and provide appropriate treatment in a systematic manner.

Keywords: Reactive vascular lesion, osseous, metaplasia

INTRODUCTION:

The tissues of the oral and maxillofacial region are constantly exposed to a plethora of inflammatory stimuli. The origin of these stimuli can be bacterial, physical, chemical, or immunologic. The reactive lesions are collectively defined as chronic/long-standing, low-grade inflammatory stimuli that can induce a heightened/escalated reparative response in the oral tissues resulting in the occurrence of non-neoplastic, hyperplastic lesions.

Low-intensity chronic irritation that stimulates an exuberant tissue repair response is the main etiologic reason for this reactive vascular lesions, which will in turn produce a soft tissue enlargement which is very much similar to a diverse group of pathologic processes. Consequently, this enlargement can be characteristic of a variation of normal anatomic structures, such as inflammation, cysts, developmental anomalies, and neoplasm. The occurrence of exophytic reactive proliferation in the oral cavity is found to be relatively common. Vascular lesions can closely mimic some certain malignant (metastatic/primary) and benign tumors, leading the clinician to misdiagnosis and sub-optimal treatment.

PATIENT INFORMATION:

A 51-year-old lady reported to the Department of Oral and maxillofacial surgery with a chief complaint of a painless hard growth in the right palatal aspect of the oral cavity with history of occasional bleeding from the lesion. (Figure 1)

HISTORY OF PRESENTING ILLNESS AND CLINICAL EXAMINATION

A 51-year-old lady reported to the Department of Oral and maxillofacial surgery with a chief complaint of a painless hard growth in the right palatal aspect of the oral cavity with history of occasional bleeding from the lesion since 2 months. On examination the surface was erythematous and ulcerated in appearance and bony hard in consistency. The size of the lesion was approximately 3 cm*3 cm*3cm. The lesion was found to be extending from mesial aspect of 16 to the distal aspect of 17 not crossing the midline. On palpation, the growth was non-tender with absence of discharge of pus or blood.

DIAGNOSTIC ASSESSMENT

Radiological evaluation by CT scan revealed bony erosion of the alveolar process of the right maxilla with soft tissue component at the level of first to third molar teeth. (Figure 2)

SURGICAL INTERVENTION

After obtaining the written consent from the patient, an incisional biopsy of the growth was performed under local anesthesia. The growth was enucleated and was sent for histopathological examination. The histopathology report revealed a salivary gland neoplasm or vascular lesion and an immunohistochemistry (IHC) study was advised to rule out the diagnosis. After ruling out any chances of malignancy, we proceeded with the excision of the lesion with placement of an obturator as the chances of oro-antral communication was anticipated. (Figure 4, 5). The procedure was done under General anesthesia taking in to consideration the size and extent of lesion. The whole sample was sent for histopathological examination and the report was suggestive of a benign reactive vascular lesion with osseous metaplasia.

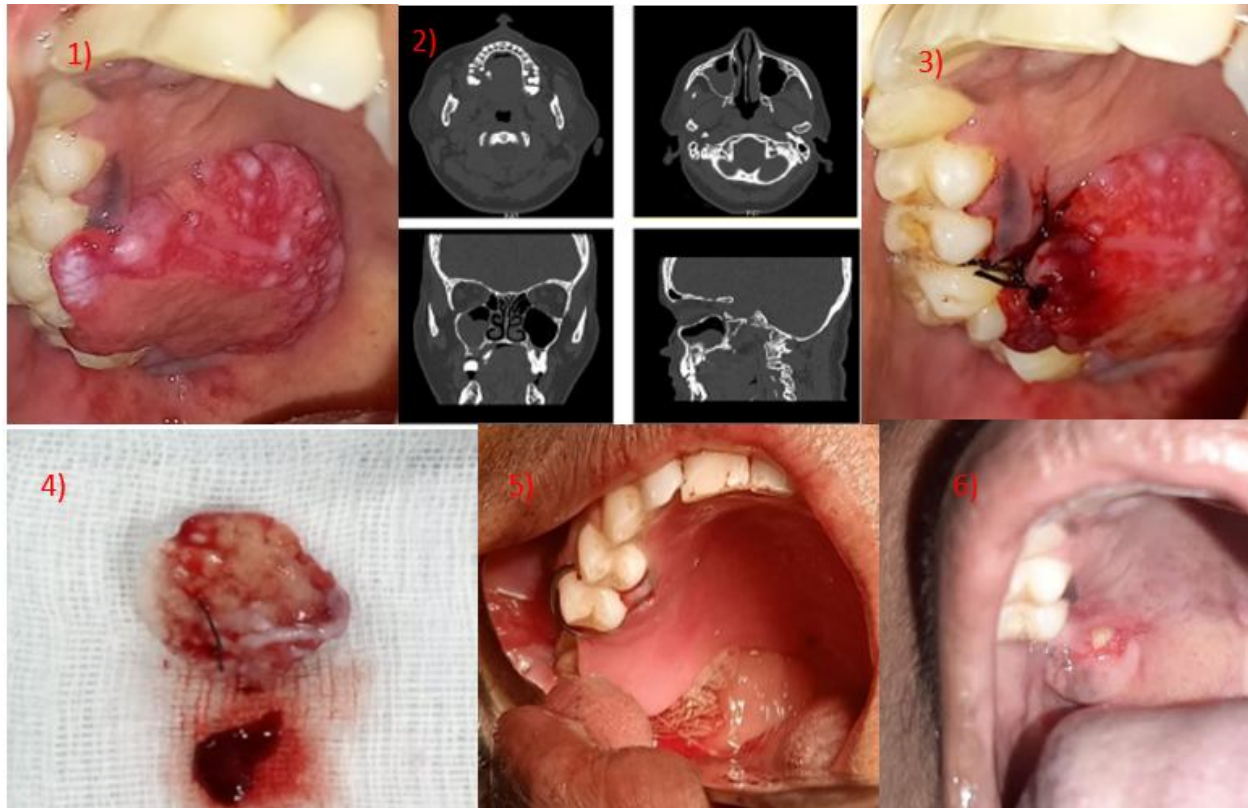


Figure 1-6: Morphological view of benign reactive vascular lesion with osseous metaplasia

FOLLOW-UP

Patient is under periodic follow-up since then. (Figure 6- Post op after one week)

DISCUSSION:

Benign vascular lesions were found to be a consequence of blood vessel abnormalities or endothelial cell proliferation [1]. The treatment plans of the lesions are based on the diagnosis and classification of the vascular malformations [2].

TERMINOLOGY AND CLASSIFICATION:

Mulliken and Glowacki proposed a terminology for classifying these lesions based on clinical and microscopic features. [3] They classified the vascular lesions into hemangiomas and vascular malformations and hemangioma is one of the true vascular tumor that results from a neoplastic overgrowth of normal vascular tissue and it is found to grow by endothelial proliferation. Compared with hemangiomas vascular malformations result from abnormal vascular or lymphatic vessel morphogenesis and it is not as a result of abnormal endothelial

growth. Vascular malformations are present at birth but often not diagnosed until the second decade of life. And they are found to show slow growth throughout life with increase in response to infection, trauma, or hormonal fluctuation and they are not involute. [4]

ETIOPATHOGENESIS AND CHARACTERISTICS:

Hypocellularity and vascular channels lined by flat mature endothelium is one of the main characteristic feature of oral vascular malformation. Pulsations can be felt by finger pressure if the lesion has an arterial origin. In ultrasound, color Doppler sonography has been developed to identify vasculature and to enable evaluation of the blood flow, velocity, and vessel resistance together with surrounding morphology [5].

The main characteristics of reactive vascular lesions are tissue growth, with fibrous or flaccid consistency, reddish color, sessile or pedunculated, and is found to occur in multiple intraoral sites. Patients may also report with the absence of symptoms; or symptoms ranging from mild pain to bleeding. Radiographic findings are not usually seen, but in rare cases of large lesions, a localized alveolar bone resorption may be seen. Histopathologic examinations of the surgical specimens from oral biopsies must confirm the clinical diagnosis, and furthermore, to provide a definitive pathological diagnosis. This helps in the appropriate treatment plan to be sought and to avoid the recurrence of the lesions. In this way, our article emphasizes a rare case report of benign reactive vascular lesion with osseous metaplasia and its treatment modalities [6].

LOCATION:

A palatal abscess has often been found to occur secondary to a periapical infection of the palatal roots of maxillary teeth which are affected by pulpal inflammation. Carious, fractured or non-vital teeth have often been found in the vicinity of the lesion. There is some degree of pain associated with the lesion and radiographs would show bone loss associated with periapical pathology. Clinically, a palatal abscess may also exhibit a patent sinus tract discharging pus or a serosanguinous fluid [7].

TREATMENT MODALITIES

Surgical excision with a blade or laser, cryosurgery, injection of corticosteroids or sclerosant (sodium tetradearyl), radiotherapy, and embolisation with steel coil, gel foam, silicone beads, or cyanoacrylate are the current treatment modalities employed in treating the benign vascular lesions. The patient's age and site and size of the lesion determines the follow-up and treatment administered. The notable disadvantages of the mentioned treatment modalities are excessive bleeding, fibrosis, scarring, cosmetic and functional deficiency due to the long-term effects of steroids and radiation. Surgical excision and cryosurgery have been found as effective treatments for small lesions and superficial ones [8]

In our case report, as the incisional biopsy report was inconclusive, to proceed with the confirmation of the report, we conducted an immunohistochemistry study. It revealed proliferated vascular spaces which showed the positivity of CD 31 and CD 34. P 40 shows positivity in overlying epithelium. Sub-epithelial region show LCA positive lymphocytes. Immunohistochemistry report features were that of an inflammatory polyp with surface ulceration of overlying mucosa. After ruling out chances of any malignancy, excision of the mass in toto was done. This was followed by cauterisation and after achieving adequate hemostasis we proceeded with placement of a palatal obturator which not only gave support to the pressure pack but also avoid any chances of oro- antral communication.

CONCLUSION:

From the case presented above and the literature analyzed, we can conclude that benign vascular lesions of the oral cavity always need a systematic approach in diagnosis and treatment and also necessitates a histopathological examination. The histological picture is still controversial, posing diagnostic challenges at times due to the lack of definite criteria for diagnosis. Prompt immunohistochemical analysis to confirm, followed by surgical treatment, should be mandatory in cases of these lesions to reduce the chance of local recurrence and metastasis.

CONSENT:

As per International standard or university standard, patients' written consent has been collected and preserved by the author(s).

ETHICAL APPROVAL:

As per International standard or university standard, patients' ethical approval has been collected and preserved by the author(s).

REFERENCES:

1. Barrett AW, Speight PM. Superficial arteriovenous haemangioma of the oral cavity. *Oral Surg Oral Med Oral Pathol Oral Radiol Endod* 2000;90:731-8
2. Ethunandan M, Mellor TK. Haemangiomas and vascular malformations of the maxillofacial region - A review. *Br J Oral Maxillofac Surg* 2006;44:263-72.
3. Langdon JD, Patel MF. *Operative Maxillofacial Surgery*. London: Chapman & Hall Medical; 1998. p. 393-6
4. Corrêa PH, Nunes LC, Johann AC, Aguiar MC, Gomez RS, Mesquita RA. Prevalence of oral hemangioma, vascular malformation and varix in a Brazilian Population. *Braz Oral Res* 2007;21:40-5.
5. Senthil KB, Nazargi M. Ultrasound in dentistry - A review. *JIADS* 2010;1:44-5.
6. Donnelly LF, Adams DM, Bisset GS 3rd. Vascular malformations and hemangiomas: A practical approach in a multidisciplinary clinic. *AJR Am J Roentgenol* 2000;174:597-608
7. Karasu HA, Aysegul M, Oncul T, Uyanik LO. Cryosurgery of a huge hemangioma of tongue: A case report. *J Oral Health Comm Dent* 2010;4:83-7.
8. Johann AC, Aguiar MC, do Carmo MA, Gomez RS, Castro WH, Mesquita RA. Sclerotherapy of benign oral vascular lesion with ethanolamine oleate: An open clinical trial with 30 lesions. *Oral Surg Oral Med Oral Pathol Oral Radiol Endod* 2005;100:579-84
9. Goldblum JR, Folpe AL, Weiss SW. Hemangioendothelioma: Vascular tumors of intermediate malignancy. In: De Francesco K, editor. *Enzinger and Weiss's Soft Tissue Tumors*. 6th ed. Philadelphia: Elsevier Saunders; 2014. p. 681-702. 5.
10. Gupta SC, Tewarson SL, Malhotra M. Haemangioendothelioma of paranasal sinuses with intracranial extension. *Indian J Otolaryngol Head Neck Surg* 2006;58:196-8.