

---

# Venous Involvement in Takayasu Disease: A Case Report

---

## ABSTRACT

Takayasu's disease (TD) is an inflammatory arteritis of the large vessels that affects with predilection the aorta and its main branches, the thickening of the vascular wall is the most characteristic early sign of the disease leading progressively to stenoses, thromboses and occasionally the development of aneurysms. It is a vasculitis that generally spares the veins, few cases of deep vein thrombosis (DVT) have been reported during this pathology. It is in this order that we report the case of a 48-year-old patient followed for a month in the internal medicine department for Takayasu's disease, a diagnosis established because of her young age, female gender, abolition of pulses in the lower limbs and the radiological aspect. The patient underwent treatment with high-dose corticosteroid therapy (prednisone 1 mg/kg per day). For DVT, she was put on DOAC. The evolution under treatment was marked by the regression of the inflammatory signs and the negativation of the infectious assessment. Addressing this issue is important as the risk of restenosis or occlusion is still high with vascular interventions.

*Keywords: Takayasu disease; deep vein thrombosis; vasculitis; aorta.*

## ABBREVIATIONS

*ACL* : anticardiolipin antibodies  
*ANA* : antinuclear antibodies  
*AOD* : direct oral anticoagulant  
*CCA* : circulating anticoagulant antibodies  
*CRP* : C-reactive protein  
*CT* : computed tomography  
*DVT* : deep vein thrombosis  
*ECG* : electrocardiogram  
*SV* : sedimentation rate  
*TM* : Takayasu disease

## 1. INTRODUCTION

"Takayasu's arteritis is a vasculitis with arterial tropism, affecting large-caliber vessels, particularly the aorta and its main branches (subclavian, carotid, vertebral, renal, digestive, iliac arteries), but also the coronary and pulmonary arteries. The disease can be segmental or diffuse to the whole thoracic and abdominal aorta and its branches"[1].

"Initially described in Japan, Takayasu's arteritis is ubiquitous but is observed with greater frequency in Asia, South America and in countries around the Mediterranean. Because of its rarity and chronic nature, the prevalence of Takayasu arteritis is difficult to assess. It is estimated that there are 40 per million people in

Japan. Takayasu arteritis affects young women in the majority of cases. The third decade of life is the period of highest incidence of occurrence. The age of onset of the disease is between 20 and 40 years, but it is difficult to estimate. Nevertheless, Takayasu's arteritis mainly affects people under the age of 50. Mostly women are affected"[1]

"The diagnosis of Takayasu's disease can be evoked in a symptomatic patient under 50 years old with general signs or ischemic symptoms on effort or arterial hypertension. But it can also be of fortuitous discovery in front of an abolition of pulses or vascular murmurs at the clinical examination, or a parietal arterial thickening of the aorta or its branches sometimes associated with arterial stenosis or aneurysms on the imaging examinations"[1]

In this report, we describe the case of a patient in whom the diagnosis of Takayasu's disease was retained in the framework of the etiological assessment of deep vein and arterial thrombosis.

## 2. CASE REPORT

Our patient, 48 years old, with a history of arterial hypertension for 4 years under antihypertensive treatment, was hospitalized in the cardiology department of the university hospital IBN ROCHD of Casablanca in April 2022 in front of a

picture of DVT and then in the internal medicine department where the diagnosis of Takayasu disease was retained.

On examination, the patient reported intermittent claudication of the lower limbs for 3 months prior to admission, associated with swelling of the left lower limb, with no fever and asthenia, without associated skin or neurological signs.

On clinical examination, there was a warm swollen left limb with abolition of the popliteal, pedal and post left tibial pulses, positive Homans sign and cyanosis of the last 3 toes of the left foot.

On auscultation of the vascular axes, there was a murmur on the path of the right and left femoral artery, the blood pressure was 165/90 mm Hg symmetrical on both limbs. There was no tumor syndrome.

The rest of the somatic examination was unremarkable.

The ECG showed a regular sinus rhythm at 88/min, fixed PR at 0.16, fine QRS, planing of the R waves.

The biology showed a biological inflammatory syndrome: sedimentation rate (SV) at 65 mm at the first hour, C-reactive protein (CRP) at 145 mg/L, hyperleukocytosis at 16370/mm<sup>3</sup> predominantly neutrophils, hyperplaquetosis at 605000/mm<sup>3</sup>, polyclonal hypergammaglobulinemia and D-dimer at 12456 ng/ml. Antinuclear antibodies (ANA), circulating anticoagulant antibodies (CCA), anticardiolipin antibodies (ACL) were negative as well as tumor markers. The coagulation protein assay (protein C, protein

S, antithrombin III) did not show any deficiency. The tuberculosis investigation was negative.

Radiologically, an angioscan of the abdominal aorta and the arteries of the lower limbs was performed, which showed a thrombosis of the splenic, pulmonary (segmental and sub-segmental), right iliofemoral and left femoral-popliteal axes with splenic and bilateral renal infarction (Figs.1-2).

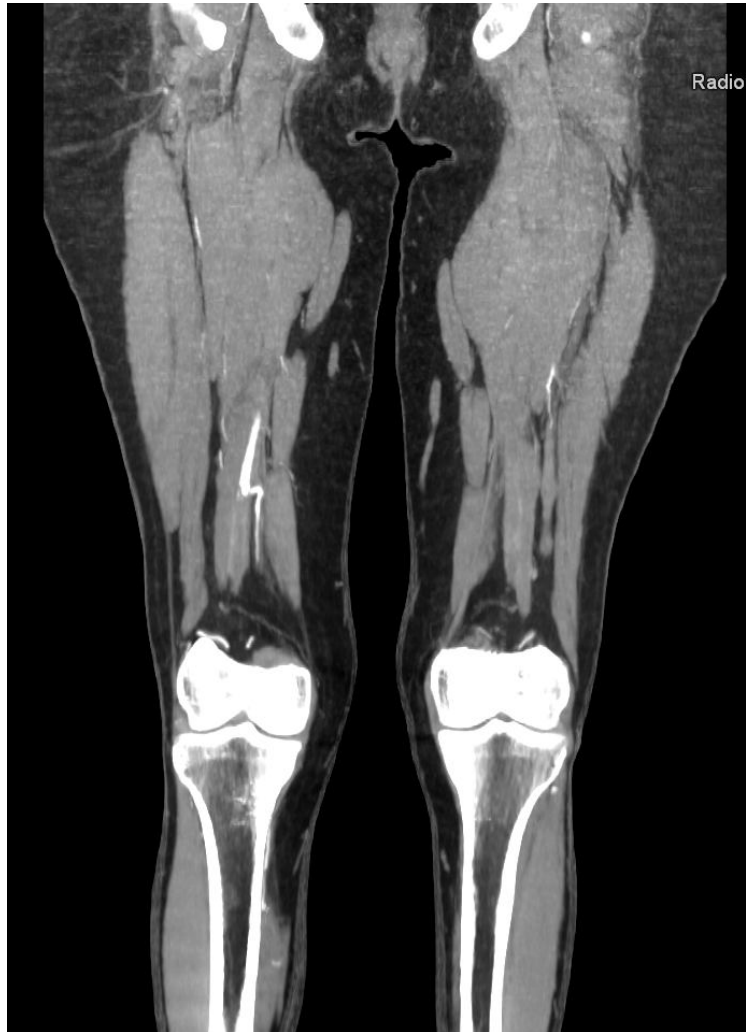Thoracic angioscanner showed a partial pulmonary embolism involving the main branches as well as almost all the segments and sub-segments on both sides (Fig.3).

Doppler ultrasound of the arteries and veins of the lower limbs showed, on the left lower limb, a cruciate occlusion of the superficial femoral, popliteal, anterior and posterior tibial veins and, on the right lower limb, an occlusion of the popliteal and anterior tibial veins associated with deep venous thrombosis on the left popliteal and the lower portion of the superficial femoral (Figs. 4,5,6).

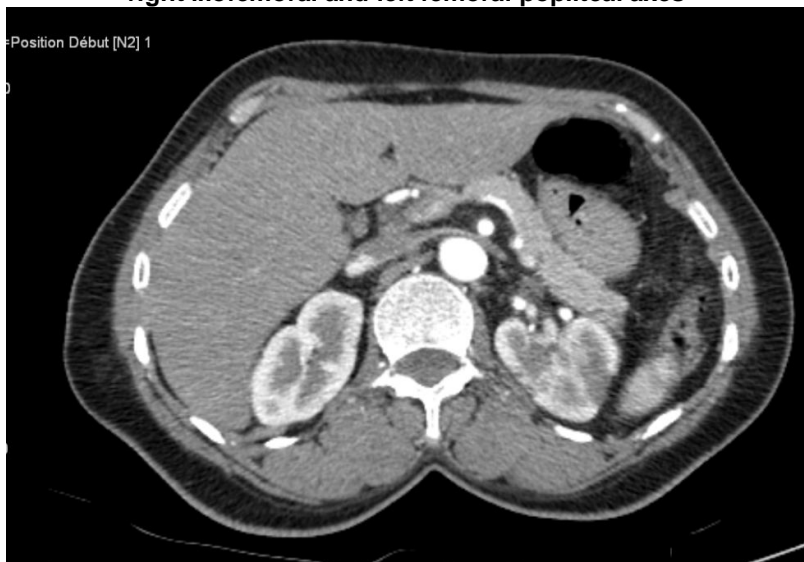Positron emission tomography (PET) showed hypermetabolism of the skin on the dorsal part of the right foot.

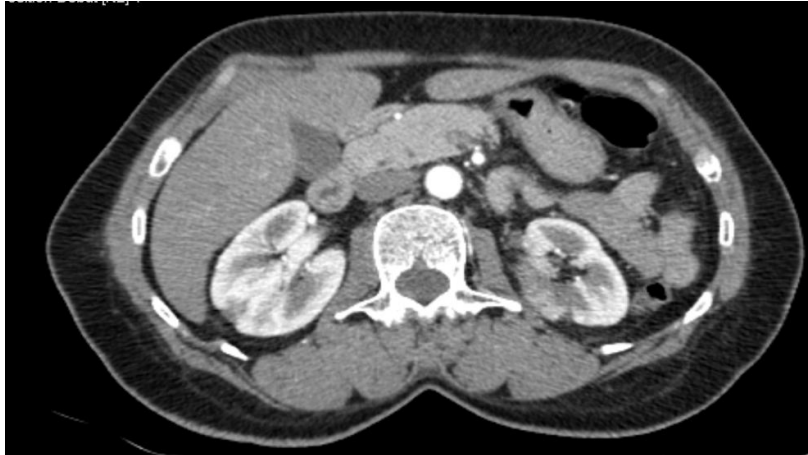In addition, cerebral CT and abdominal ultrasound were normal.

The diagnosis of takayasu's disease was retained in front of the presence of a major criterion and 4 minor criteria according to the criteria of ishikawa modified by sharma. The patient was treated with high dose corticosteroid therapy (prednisone 1 mg/kg per day). For DVT, she was put on AOD. The evolution was favorable.

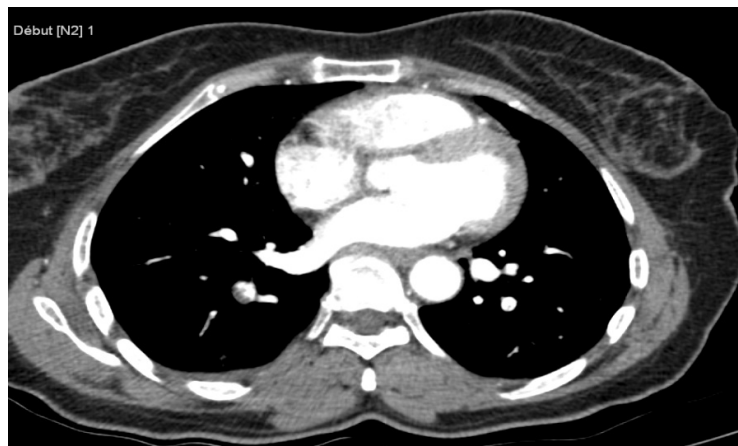

**Fig.1. Angioscan of the abdominal aorta and the arteries of the lower limbs: Thrombosis of the right iliofemoral and left femoral-popliteal axes**

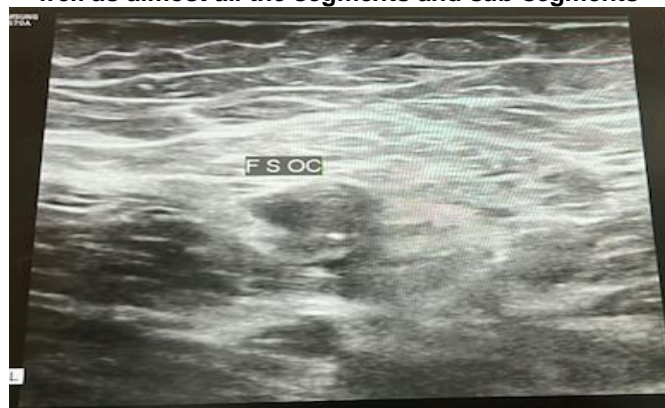



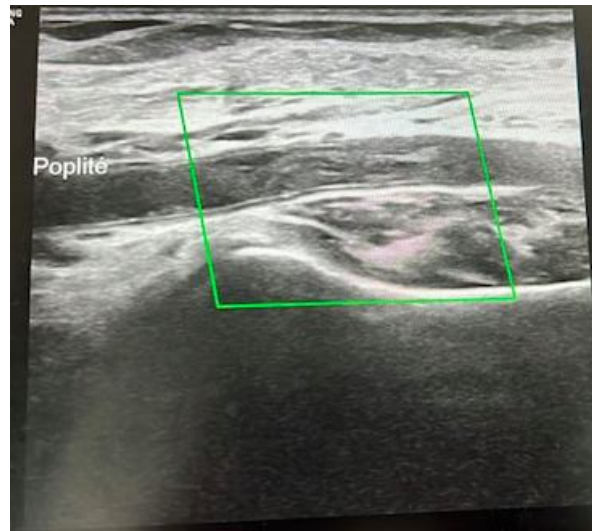
**Fig. 2. Angioscan of the abdominal aorta and the arteries of the lower limbs: Splenic artery thrombosis**



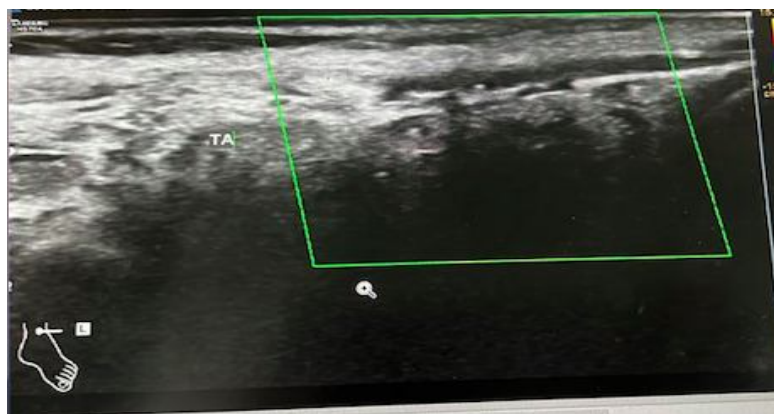**Fig. 3. Thoracic angioscanner: Partial pulmonary embolism involving the main branches as well as almost all the segments and sub-segments**



**Fig. 4. Doppler ultrasound of the arteries and veins of the lower limbs: Occlusion of the superficial femoral**



**Fig. 5. Doppler ultrasound of the arteries and veins of the lower limbs: Occlusion of the popliteal**



**Fig. 6. Doppler ultrasound of the arteries and veins of the lower limbs: Occlusion of the anterior tibial veins**

### 3. DISCUSSION

The circumstances of discovery of Takayasu disease can be very different. In some patients, the diagnosis is made during the so-called "pre-occlusive" or "systemic phase". This phase associates aspecific general signs with fever, arthralgias, myalgias, skin signs (erythema nodosum, pyodermagangrenosum), pain in the arterial tracts (in particular carotidodynia), and sometimes ophthalmologic involvement: episcleritis. In practice, the systemic phase often goes unnoticed, is absent or is only found retrospectively by questioning, or is concomitant with the occlusive phase. Most often the diagnosis is made during the "vascular phase", which is the consequence of arterial lesions (stenoses, obliterations, aneurysms) located on the aortic arch, on the thoracoabdominal aorta or

their branches, the mode of revelation depends on the territory affected. Venous involvement is very rare during Takayasu disease[1].

"There is no specific biological diagnostic marker or specific antibody for Takayasu disease. The inflammatory syndrome is confirmed by increased CRP, fibrinogen, 2-globulin, haptoglobin, orosomuroid and/or sedimentation rate (ESR). The inflammatory syndrome is inconsistent and its absence does not necessarily indicate the absence of disease activity. The search for antinuclear factors or rheumatoid factors is negative in the absence of associated connective tissue disease. The presence of anti-endothelial cell antibodies has been reported but is not specific. Pentraxin-3 has been described as a marker of disease activity. CRP belongs to the pentraxin family, but is synthesized by the liver, unlike pentraxin-3,

which is thought to be produced by immune cells and arterial wall cells. However, pentraxin-3 is not assayed in clinical routine"[1].

"Arterial imaging plays a major role in the positive diagnosis of the disease and in monitoring its evolution. The search for damage to the aorta and its branches (arterial parietal thickening and remodeling, stenosis, aneurysm) is carried out by arterial Doppler ultrasound, CT angiography or MRI angiography. Positron emission tomography or PET-scanner has been proposed to study arterial parietal inflammatory activity"[1].

In our patient, the diagnosis of TM is certain.

The diagnosis was retained in view of the young age, the female sex, the abolition of the pulses in the lower limbs, the radiological aspect and the improvement of the symptomatology under treatment. The evolution in our patient was marked clinically by the improvement of the blood pressure figures, biologically by the negativation of the inflammatory balance, the radiological check-up was not repeated.

However, this vasculitis was diagnosed at a late age (48 years). In fact, it is rather a delay in diagnosis: on questioning, we found the notion of old intermittent claudication of the lower limbs.

Although it has been mentioned in a few publications [2-5], DVT in TM is not well known. The possibility of venous involvement during TM is very rare, and was initially mentioned by Sen in 1968 [4]. During this disease, there is an activation of platelets and the coagulation cascade, which could be the cause of hypercoagulability and venous thrombosis, [6,7], moreover, these thromboses can also occur through an inflammatory syndrome.

#### 4. CONCLUSION

What we report in our patient is a DVT associated with other arterial thrombosis leading to the discovery of takayasu disease, which shows that DVT can be the revealing manifestation of this condition. To our knowledge, only two cases have been reported in the literature.

Classically defined as a disease with arterial tropism, Takayasu disease never ceases to surprise by the polymorphism of its localizations.

#### CONSENT

As per international standard or university standard, patient(s) written consent has been collected and preserved by the author(s).

#### ETHICAL APPROVAL

As per international standard or university standard written ethical approval has been collected and preserved by the author(s).

#### COMPETING INTERESTS

Authors have declared that no competing interests exist.

#### REFERENCES

1. Saadoun D, Bura-Riviere A, Comarmond C, Lambert M, Redheuil A, Mirault T. French recommendations for the management of Takayasu's arteritis. *Orphanet Journal of Rare Diseases*. 2021;16(3):1-23.
2. Neshet G, Ben-Chetrit E, Mazal B, Breuer GS. The incidence of primary systemic vasculitis in Jerusalem: A 20-year hospital-based retrospective study. *J Rheumatol*. 2016;43:1072–1077. This is an epidemiologic survey that examined the incidence rates of primary systemic vasculitides in the Jewish population of Jerusalem from Israel. Trends in incidence rates over a 20-year period were also examined.
3. Yoshida M, Watanabe R, Ishii T, et al. Retrospective analysis of 95 patients with large vessel vasculitis: a single center experience. *Int J Rheum Dis* 2016;19:87–94. This study investigates the clinical differences between 86 patients with Takayasu arteritis and nine patients with GCA followed by a single center in Tohoku Region, Japan from 1990 to 2014.
4. Kermani TA, Crowson CS, Muratore F, et al. Extra-cranial giant cell arteritis and Takayasu arteritis: How similar are they? *Semin Arthritis Rheum*. 2015;44:724–728.
5. Alibaz-Oner F, Aydin SZ, Akar S, et al. Assessment of patients with Takayasu arteritis in routine practice with Indian Takayasu Clinical Activity Score. *J Rheumatol* 2015;42:1443–1447. A multicenter controlled study that compares two outcome measures.
6. Alibaz-Oner F, Direskeneli H. Update on Takayasu's arteritis. *Presse Med* 2015;44(Pt 2):e259–e265. This is a comprehensive review and summary of the recent developments in Takayasu arteritis.

7. Kato Y, Terashima M, Ohigashi H, et al. Vesselwall inflammation of Takayasuarteritis detected by contrast-enhanced magnetic resonance imaging: Association with disease distribution and activity. *PLoS One*. 2015;10:e0145855.

---

© 2022 Mousaid et al.; This is an Open Access article distributed under the terms of the Creative Commons Attribution License (<http://creativecommons.org/licenses/by/4.0>), which permits unrestricted use, distribution, and reproduction in any medium, provided the original work is properly cited.