

Original Research Article

**Non-wedge technique for valgus subtrochanteric osteotomy in pediatric
femoral neck non-union**

UNDER PEER REVIEW

Abstract

Aims

The aim of this retrospective study was to evaluate the clinical and radiological outcomes of using valgus subtrochanteric osteotomy in pediatric femoral neck non-union.

Patients and Methods

Study Design: Case Series

Place and Duration of study: Ghurki Trust Teaching Hospital Lahore Pakistan. Study conducted between Jan 2016 to Dec 2019.

Methodology:

This was a retrospective study of 5 children with femoral neck non-union who underwent osteosynthesis and valgus subtrochanteric osteotomy at Ghurki Trust Teaching hospital between 2016 and 2019. Clinico-demographic profile of patients and functional and radiological outcomes in terms of Ratliff grading and time to union respectively are reported. All patients had a minimum of 2 years followup.

Results

This study included five patients (two males and three females with mean age of 9.8 ± 1.92 years). All patients achieved fracture union, seen within an average of 18 ± 6.37 weeks and of the osteotomy site within 13 ± 2.9 weeks. Neck shaft angle improved from average 107 degrees (range 100-110) preoperatively to 137 degrees postoperatively (range 130-140). Pre-operative radiologic signs of AVN was shown in all patients which disappeared completely in 4 patients. Mean limb-length discrepancy decreased from 2.9 cm preoperatively to 0.8 ± 0.57 cm post-operatively. According to Ratliff criteria, 4patients had good whereas one patient had fair functional outcome. There were no intra-operative or early post-operative complications recorded in our series.

Conclusion

We report that valgus subtrochanteric osteotomy in non-united femoral neck fractures in children is cost-effective and technically less demanding procedure and is associated with good clinical and radiological outcomes.

Keywords

Neck of femur fracture, non-union, valgus subtrochanteric osteotomy, pediatric, Pakistan

INTRODUCTION

Femur neck fractures in children are rare contributing to less than 1% of all pediatric fractures (1, 2). Thick periosteum and tough bone in children is considered to be reason for such low incidence (3). Pediatric femur neck fractures are fraught with complications due to premature proximal femur physeal closure and damage to precarious blood supply of femoral head leading to avascular necrosis (AVN), non-union, coxa vara and limb length inequalities (4, 5). The prevalence of non-union ranges between 7% and 10%, depending on the site of the fracture in femoral neck (5, 6).

Femoral neck non-union is defined as lack of radiographic evidence of union nine months after the fracture or non-progression of healing for 3 consecutive months (5, 7). The primary cause of nonunion is either failure to obtain or maintain an anatomic reduction with internal fixation and/or delayed presentation (3).

Published literature on pediatric femoral neck fractures and its complications has several drawbacks. Major limitations are small sample size and inadequate long-term follow-up of reported studies; which coupled with variable disease presentation, multitude of different treatment regimens and limited experience of individual surgeons makes standardization of treatment protocol difficult (2, 8, 9). Lastly, major bulk of such fractures are seen in developing countries where mismanagement by traditional bonesetters and delayed referrals have already caused femoral neck resorption or avascular necrosis of head of femur at the time of initial presentation (4). Valgus subtrochanteric osteotomy has been reported to yield satisfactory results in treating nonunion of paediatric femoral neck fractures (1). In this study, we aimed to evaluate the clinical and radiological outcomes of valgus subtrochanteric osteotomy in pediatric femoral neck non-union.

PATIENTS AND METHODS

This was a retrospective study of 5 children with femoral neck non-union who underwent osteosynthesis and valgus subtrochanteric osteotomy at Ghurki Trust Teaching hospital between 2016 and 2019. Due to retrospective nature of study, the need for ethical review approval was waived by Hospital's institutional review board as the results did not influence patient care. Consent was obtained from patients to use clinical and radiological images. Medical records were reviewed to collect information about clinico-demographic profile of patients such as age and gender of patients, mechanism of injury, previous treatment received and time elapsed since injury.

All patients were evaluated with orthogonal radiographs of hip to detect signs of AVN, degree of neck resorption, inclination of fracture lines (Pauwel's angle) and the neck-shaft angle. Fractures were classified according to system proposed by Delbet. The Ratliff's classification was used to identify type of AVN (10). Functional evaluation was done in terms of Ratliff function score (11). Radiographic healing was determined by the presence of bridging trabeculae across the osteotomy and the nonunion site on orthogonal x-rays. Clinical union was defined as pain free full weight-bearing without any support.

Surgical technique

Pre-operative radiographs of both normal and affected hip were studied for various anatomical landmarks and selection of appropriate implant for osteosynthesis. Fracture was approached via a standard lateral incision. Under image guidance, fracture was provisionally stabilized with two 2mm K wires. To achieve valgification of proximal femur, transverse cut subtrochanteric femoral osteotomy was done and shaft of femur was lateralized without removing wedge of bone. The Pauwels angle at the non-union site was converted from type 3 to type 1. The advantage of non-wedge technique is that it increases the length of the femur and restores the proximal femoral anatomy by aligning the piriformis fossa to shaft of femur. No capsulotomy, open reduction or fibrous tissue excision was done in any case. Osteosynthesis using paediatric dynamic hip screws/blade plate was performed. In some cases, screw was passed across the physis to promote stability of fixation due to severe femoral neck resorption. Postoperatively, a hip spica was applied for 6-8 weeks if the child was younger than 8 years old due to concerns of weight bearing restrictions in this age group.

Results

This study included five patients (two males and three females with a mean age of 9.8 ± 1.92 years; range 7-12). The age at initial injury ranged between 6.5 and 11 years. The duration between injury time and osteosynthesis ranged from 4 months to 9 months. The mechanisms of injury were fall from a height in three patients and road traffic accident in two cases. All five patients had Delbert type II neck of femur fracture. Two cases of femoral neck nonunion were following failed internal fixation and three cases were neglected fractures where fracture was initially managed by traditional bone setters. Of the two patients with failed internal fixation, one had undergone fixation with k wires and spica cast and cannulated screws without immobilization were used in second patient. Clinical evaluation revealed a mean limb-length discrepancy of 2.9 cm (2.5 to 3.5). In all these cases, neck-shaft angle was less than 110° . AVN was present pre-operatively in all the cases. Using Ratliff classification two were classified as type II and remaining three as type III.

All patients had a minimum of 2 years followup (mean 35.8 ± 11.66 months). All patients achieved fracture union, seen within an average of 18 ± 6.37 weeks and of the osteotomy site within 13 ± 2.9 weeks. Neck shaft angle improved from average 107 degrees (range 100-110) preoperatively to 137 degrees postoperatively (range 130-140). Pre-operative radiologic signs of AVN was shown in all patients which disappeared completely in 4 patients. Mean limb-length discrepancy decreased from 2.9 cm preoperatively to 0.8 ± 0.57 cm post-operatively. According to Ratliff criteria, 4 patients had good whereas one patient had fair functional outcome. There were no intra-operative or early post-operative complications recorded in our series. One patient had a superficial wound infection that responded to repeated dressings and intravenous antibiotics. On long-term follow-up none of our patients developed postoperative coxa vara, proximal overgrowth of the greater trochanter or signs of chondrolysis. Premature proximal femoral epiphyseal closure was seen in 3 patients, resulting in a leg-length discrepancy. Mild Trendelenburg gait was observed in 1 patient (#4). No reoperations were needed for symptomatic metal removal. Implant failure was not observed in any of the patients until the last follow-up.

DISCUSSION

In this study, we were able to achieve union in all patients both at the osteotomy sites and nonunion sites. There was a significant improvement in the neck-shaft angle and Ratiliff functional grading. Areas of bone resorption were replaced by good density bone signifying excellent bone healing potential of children. We believe that valgus subtrochanteric osteotomy lowers the incidence of implant failure by decreasing the bending moment of the screw-plate fixation. Radiologic signs of avascular necrosis disappeared completely in 4 out of 5 patients presenting with pre-operative avascular necrosis. In the present series, implants used provided secure fixation that external immobilization in form of hip spica was only needed in patients younger than 8 years.

Although rare, paediatric femoral neck fractures are fraught with complications due to combination of high energy trauma, injury to precarious blood supply of femoral head, forceful reduction manoeuvres, non-anatomic reduction and inadequate fixation (1, 2). (1, 3, 12). In developing countries, neglected femoral neck fractures are more commonly reported due to initial mismanagement by traditional bonesetters (13, 14). Low literacy rate, poverty, tendency towards alternative medicine, including traditional bonesetters, as well as lack of access to health facilities leads to delayed presentation. In such cases treatment becomes even more challenging because of femoral neck resorption and/or avascular necrosis of head of femur at the time of initial presentation (2, 15).

Due to the small number of cases and limited exposure of orthopaedic surgeons, the treatment protocols for nonunion of the paediatric femoral neck fractures are not well defined (1). The aims of treatment are to achieve union, restore femoral neck length and neck shaft angle and provide rigid internal fixation (2). Variety of procedures reported in literature include the use of vascularised muscle pedicle, vascularised iliac crest or vascularised fibula to non-vascularised cortical tibial or free fibular strut graft (single or double) (3, 16, 17).

Biomechanical principle behind valgus osteotomy is based on making nonunion site more horizontal, thus converting shearing forces to compressive forces across the fracture site. The osteotomy is relatively easy to perform, cost-effective and provides good stability for the fracture (4). We believe Pauwels' osteotomy has additional advantage of simultaneous correction of coxa vara, restoration of the neck-shaft angle, limb-length

discrepancy, and abductor moment arm (2). Post-operative coxa vara is prevented by the buttressing effect of the distal fragment which improves stability of fixation in both the sagittal and the coronal planes (4).

Closed or open reduction of the fracture site and excision of the fibrous tissue at site of non-union have been long debated in literature (5, 18). Sanghavi et al. did a systematic review of pediatric neck of femur fracture and reported that nonunion site was not opened in majority of cases (3-5). Two-fold advantage of such strategy is that it avoids additional damage to the femoral head blood supply as well as improves the mechanical and biological environment around the fracture nonunion site which eventually converts the fibrous non-union into a solid osseous union (2)(3).

AVN of femoral head is a disastrous complication of neck of the femur fractures with incidence ranging between 17% and 47% (1). Role of valgus osteotomy in the management of AVN has been demonstrated in the series of Togrul et al. (8) and Chladek and Trc (19). Magu et al. stated that the head eventually revascularizes once union is achieved. This prevents collapse and asphericity of femoral head and resultant arthritis (4). In our series, 4 out of 5 patients with pre-operative AVN had complete resolution of AVN at last follow-up. However in patients with persistent AVN of femoral head, further reconstructive surgery of the femoral head may be warranted once union is achieved. Such patients should be closely followed till skeletal maturity to achieve a good outcome and prevent further complications (2).

CONCLUSION AND LIMITATIONS

The limitations of this study include small number of patients and relatively short follow-up. In conclusion, we report that valgus subtrochanteric osteotomy in pediatric femur neck non-unions is cost-effective and technically less demanding procedure and is associated with good clinical and radiological outcomes. It simultaneously provides favourable biomechanical environment for healing of fractures and correction of limb length discrepancy and coxa vara.

UNDER PEER REVIEW

References

1. Eamsobhana P, Keawpornasawan K. Nonunion paediatric femoral neck fracture treatment without open reduction. *Hip international : the journal of clinical and experimental research on hip pathology and therapy*. 2016;26(6):608-11.
2. Sanghavi S, Patwardhan S, Shyam A, Nagda T, Naik P. Nonunion in Pediatric Femoral Neck Fractures. *The Journal of bone and joint surgery American volume*. 2020;102(11):1000-10.
3. Elgeidi A, El-Negery A. Fibular strut graft for nonunited femoral neck fractures in children. *Journal of children's orthopaedics*. 2017;11(1):28-35.
4. Magu NK, Singh R, Sharma AK, Ummat V. Modified Pauwels' intertrochanteric osteotomy in neglected femoral neck fractures in children: a report of 10 cases followed for a minimum of 5 years. *Journal of orthopaedic trauma*. 2007;21(4):237-43.
5. Neto PF, Dos Reis FB, Filho JL, Fernandes HJ, Fujiki EN, Bensahel H, et al. Nonunion of fractures of the femoral neck in children. *Journal of children's orthopaedics*. 2008;2(2):97-103.
6. Sharma A, Tiwari A, Verma T, Maini L. Non-union fracture neck femur in a toddler: Reconstructed by valgus osteotomy - A minimally invasive approach. *Journal of clinical orthopaedics and trauma*. 2016;7(Suppl 1):8-11.
7. Khan AQ, Khan MS, Sherwani MK, Agarwal R. Role of valgus osteotomy and fixation with dynamic hip screw and 120 degrees double angle barrel plate in the management of neglected and ununited femoral neck fracture in young patients. *Journal of orthopaedics and traumatology : official journal of the Italian Society of Orthopaedics and Traumatology*. 2009;10(2):71-8.
8. Togrul E, Bayram H, Gulsen M, Kalaci A, Ozbarlas S. Fractures of the femoral neck in children: long-term follow-up in 62 hip fractures. *Injury*. 2005;36(1):123-30.
9. Shrader MW, Jacofsky DJ, Stans AA, Shaughnessy WJ, Haidukewych GJ. Femoral neck fractures in pediatric patients: 30 years experience at a level 1 trauma center. *Clinical orthopaedics and related research*. 2007;454:169-73.
10. Ratliff AH. Traumatic separation of the upper femoral epiphysis in young children. *The Journal of bone and joint surgery British volume*. 1968;50(4):757-70.

11. Ratliff AH. Fractures of the neck of the femur in children. *The Journal of bone and joint surgery British volume.* 1962;44-b:528-42.
12. Azam MQ, Iraqi A, Sherwani M, Abbas M, Alam A, Sabir AB, et al. Delayed fixation of displaced type II and III pediatric femoral neck fractures. *Indian journal of orthopaedics.* 2009;43(3):253-8.
13. Ju L, Jiang B, Lou Y, Zheng P. Delayed treatment of femoral neck fractures in 58 children: open reduction internal fixation versus closed reduction internal fixation. *Journal of pediatric orthopedics Part B.* 2016;25(5):459-65.
14. Varshney MK, Kumar A, Khan SA, Rastogi S. Functional and radiological outcome after delayed fixation of femoral neck fractures in pediatric patients. *Journal of orthopaedics and traumatology : official journal of the Italian Society of Orthopaedics and Traumatology.* 2009;10(4):211-6.
15. Magu NK, Rohilla R, Singh R, Tater R. Modified Pauwels' intertrochanteric osteotomy in neglected femoral neck fracture. *Clinical orthopaedics and related research.* 2009;467(4):1064-73.
16. Mittal R, Banerjee S. Proximal femoral fractures: Principles of management and review of literature. *Journal of clinical orthopaedics and trauma.* 2012;3(1):15-23.
17. Jaiswal A, Pruthi KK, Goyal RK, Pathak V, Habib M, Tanwar YS, et al. Evaluation of osteosynthesis with dual fibular bone grafting for neglected femoral neck fractures. *Journal of clinical orthopaedics and trauma.* 2013;4(2):58-69.
18. Patterson JT, Tangtiphaibontana J, Pandya NK. Management of Pediatric Femoral Neck Fracture. *The Journal of the American Academy of Orthopaedic Surgeons.* 2018;26(12):411-9.
19. Chládek P, Trc T. [Fractures of the femoral neck in children: complications and their treatment]. *Acta chirurgiae orthopaedicae et traumatologiae Cechoslovaca.* 2002;69(1):31-4.

Table 1: Clinico-demographic profile of patients

S r	Age	Gen	Side	MOI	Delbert	Prev treatment	Time since injury	Ratliff preop AVN	Time to fx union (weeks)	Time to osteotomy union (weeks)	LLD		Ratliff function	Neck shaft angle	
											Pre	Post		pre	Post
1	07	Male	Right	RTA	Type II	K wire and spica cast	6 months	Type iii	22	15	2.5 cm	0.5 cm	Good	100	135
2	11	Female	Left	Fall from height	Type II	Cannulated screws	4 months	Type III	12	17	3 cm	1.0 cm	Good	110	140
3	10	Male	Right	RTA	Type II	No treatment	8 months	Type III	13	12	2.5 cm	0	Good	110	140
4	12	Female	Left	Fall from height	Type II	No treatment	9 months	Type II	27	11	3.5cm	1.5	Fair	105	130
5	09	Female	Left	Fall from height	Type II	No treatment	6 months	type II	16	10	3 cm	1 cm	Good	110	140

Figure Legends

Figure 1

7 year old child with right side Delbet type II neck of femur fracture

A1 and A2: AP and lateral views showing neck of femur fixation with k wires

B: 6 months post-operative x-ray showing neck of femur non union

C1 and C2: Coronal and axial MRI sections shows neck of femur non union and AVN of head of femur

D: Immediate post-operative x ray after valgus sub-trochanteric osteotomy and fixation with a 120 degree blade plate

E1 and E2: 1 year post-operative x-rays

F1 and F2: 2 years post-operative x-rays

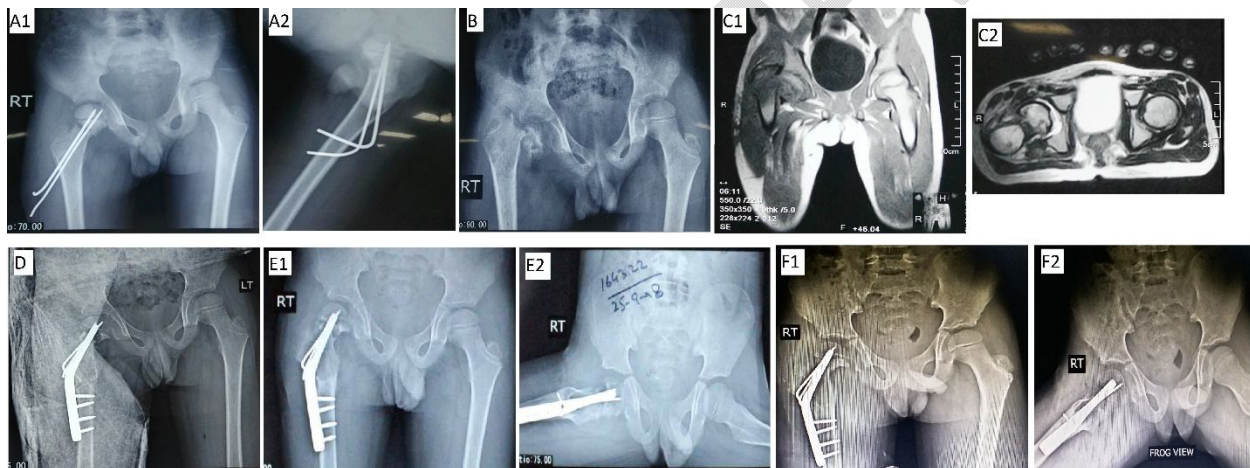


Figure 2

11 year old girl with left side Delbet type II neck of femur fracture

A1 and A2: AP and lateral x-rays showing initial fixation with cannulated screws

B1 and B2: AP and lateral x-rays showing fracture collapse and screw pullout

C1 and C2: Immediate post-operative x ray after valgus sub-trochanteric osteotomy and fixation with a dynamic hip screw

D1 and D2: 1 year post-operative x-rays

E1 and E2: 2 years post-operative x-rays

F1 and F2: Clinical pictures of patient showing her ability to squat and sit cross legged

