

The importance of early intervention for penile fracture in forced flexion - report of two cases at Madinat Zayed hospital

Abstract

Background: A penile fracture is a urological emergency that happens when an erect penis sustains a violent trauma, resulting in a tear in the tunica albuginea of one or both corpora cavernosa.

Case report:

Case 1: A 33-year-old male patient who experienced pain, swelling, and forceful flexion of the penis. The patient reported hearing a cracking sound during masturbation. This case was identified on the basis of clinical presentation and the findings of a physical examination. The emergency surgical repair was performed with an evacuation of the hematoma.

Case 2: A 32-year-old male patient who presented to the emergency department 20 hours after the injury with associated complaints of pain and swelling in the penis and scrotum. This case was identified on the basis of clinical presentation and the findings of a physical examination. The emergency surgical repair was performed with an evacuation of the hematoma. Tunical defect closure was performed with an interrupted 3.0 vicryl suture. Additionally, the patient developed phimosis and a circumcision was performed to remove the tight fibrotic segment of the foreskin, hemostasis was achieved, and closed by 3.0 rapid sutures.

Conclusion: A pre-operative urethrography or flexible cystoscopy should be considered when urethral injury is suspected. Prompt surgical intervention usually leads to satisfactory cosmetic and functional results. Early-stage intervention is required to retain penile function.

Keywords: Penile fracture, Penile trauma, Penile hematoma, Surgery

Introduction

A penile fracture – a urological emergency – occurs when the tunica albuginea of one or both corpora cavernosa ruptures after a violent trauma to the penis when it is in an erect position. It is typically brought on by intense sexual activity when the penis hits the perineum or pubic symphysis. (1) Other causes include masturbation, turning over onto an erect penis, falling out of bed, and violent flexing of the penis to produce detumescence. (2)

Common clinical symptoms of a penile fracture include detumescence after an erection, swelling, damage to the penis, and audible clicking noises. (3) Anomalies in the structure may also affect the tunica albuginea's mechanical characteristics, resulting in weakness of corpora cavernosa and elevating the risk of a traumatic tear to the penis. (3) Management of a penile fracture should not need any other intervention besides surgical exploration because penile fracture can be diagnosed easily through a physical examination. (4) The urgent need for surgery is emphasized in order to prevent erectile dysfunction, which is a common side effect of conservative treatment. (5)

Additionally, due to the low risk of postoperative problems associated with prompt surgical repair, it is recommended that these patients undergo surgery immediately, as opposed to receiving conservative care. (6) However, due to ignorance, poverty, or embarrassment, most people delay obtaining medical attention. Nonetheless, early surgical repair of penile fracture should be preferred due to the favorable long-term outcomes, which include minimal risk of erectile dysfunction (ED) and higher sexual pleasure. (7) The presence of blood at the urethral

meatus may suggest a urethral injury. (8) When physical examination and clinical symptoms are equivocal or a urethral injury is suspected, imaging modalities such as Magnetic Resonance Imaging, Color Doppler and ultrasonography, or angiography and retrograde urethrography are used. (9,10) The majority of penile fracture treatments are surgical. This report discusses two patients whose cases were successfully managed through surgery.

Case Report

Case 1:

A 33-year-old non-diabetic, non-smoking male presented to the emergency department with complaints of swelling, pain, and forced flexion of the penis. The patient reported that he had heard a cracking sound during masturbation. There was no associated significant history. The patient did not report any difficulty passing urine. A physical examination was performed. The findings revealed mild swelling on the left side of the penio-scrotal area, along with tenderness. On examination, both the glans penis and scrotum were found to be normal. There were no marked signs of hematoma or ecchymosis. However, the penis was found to have a deviation towards the right side in a flaccid state. In view of the above-mentioned findings, the patient was diagnosed with a penile fracture. After diagnosis, the patient was admitted to the operation theater for emergency fracture repair. The patient was positioned to laying supine and spinal anesthesia was administered. During this procedure, the surgical field was prepared and a 3 cm transverse left penio-scrotal incision was made directed over the localized small hematoma. Hematoma and clots were removed and, while operating, a ventral transverse tear, measuring

approximately 12 mm on tunica albuginea of left-sided corpus cavernosum, was identified. This tear was repaired by 3.0 vicryle sutures, performed in two layers. Additionally, the hemostasis on the skin was closed by 3.0 rapid sutures and the dressing was done with a crib bandage. The surgery was performed successfully without any complaints.



Figure 1: Patient A, a) Intra-operative early intervention without circumferential incision and degloving the penis. b) Three weeks post op.



Case 2:

A 32-year-old non-diabetic non-smoking patient presented to the emergency department 20

hours after the injury with associated complaints of pain and swelling in the penis and scrotum. The patient did not report any urinary complications. There was no significant past medical history. On physical examination, a big hematoma with suprapubic ecchymosis was observed in the penis and scrotum. On the basis of these findings, a diagnosis of penile fracture was made. The patient was immediately taken to the operating theater. After that, the patient was positioned laying in the supine position. A 14 fr Foley catheter was inserted. Spinal anesthesia was administered and, after preparation of the surgical field, surgery was performed. A circumferential incision proximal to the coronal sulcus was made which enabled complete degloving of the penis. During this procedure, a big hematoma was removed and a transverse tear, approximately 13 mm was identified on the “tunica albuginea of left-sided corpus cavernosum” [Figure 2]. Additionally, a lateral 1 cm transverse tear seen in the left cavernoma was repaired by interrupted 3.0 Vicryl sutures, done in two layers. A tunical defect closure was performed with a 3.0 vicryl suture. Since the patient developed phimosis, a circumcision was done to remove the tight fibrotic segment. The hemostasis on the skin was closed by 3.0 rapid sutures and the dressing was done using a crib bandage. The Foley catheter was withdrawn on the first postoperative day. The patient was released in satisfactory condition on the third postoperative day and was instructed to return for a follow-up in one week and to refrain from sexual activity for six weeks.

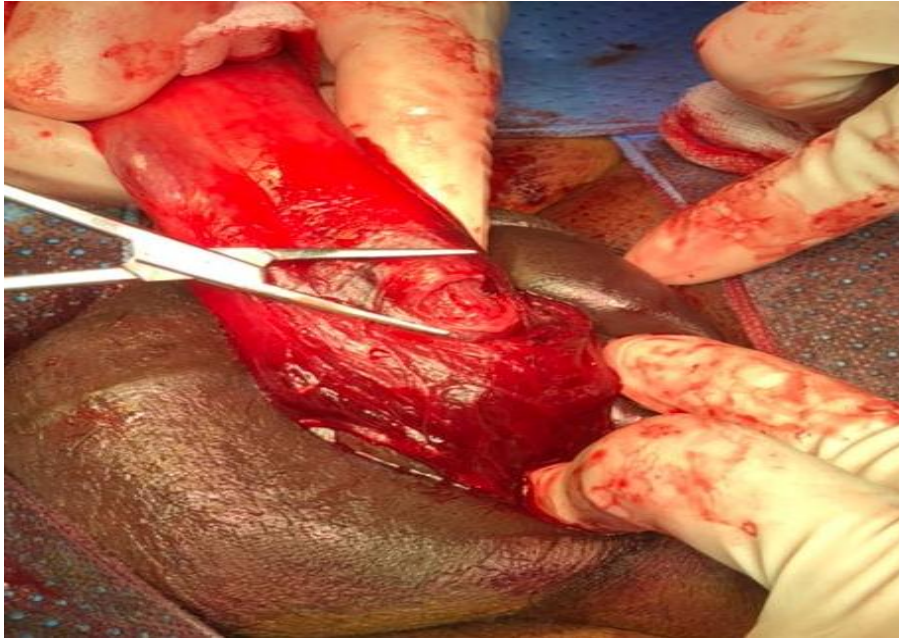


Figure 2: Intra-operative late intervention with circumferential incision and degloving the penis.

Discussion

Although penile fractures are infrequent, they are a urological emergency with potentially fatal physical and psychological effects. (11) The erection transforms the penis from a safe, flaccid organ to a vulnerable one. A penile fracture is a tear in the tunica albuginea caused by penile injury. In most cases, it is concealed or underreported because of societal humiliation. Even if reported to a doctor, the condition often remains undetected or unmanaged. (12)

Studies have reported that the use of excessive force during masturbation or intercourse, tunica albuginea fibrosclerosis, or chronic urethritis are predisposing factors. Causes may vary from region to region based on masturbation behaviors, participation in sexual activities, and sociocultural factors. The most frequently-reported mechanism of trauma is the unnatural bending of the erect penis during masturbation or sexual activity. (13) Our first patient also

presented with a history of masturbation. The current treatment options for penile fractures include conservative treatment and immediate surgery. Conservative treatment options include the application of cold, anti-inflammatory medications, pressure dressings, antibiotics, and the use of erection-inhibiting medicines. (14) However, these treatment options are related to high morbidity. The most worrying outcomes of non-surgical treatment are erectile dysfunction and penile deformity. (15) In addition to these risks, another major complication of conservative treatment is pulsative hematoma which is an extremely uncommon but early consequence of a penile fracture treated conservatively. (16) Immediate surgical repair is advised for improved functional outcomes and to avoid potential problems. Although surgical treatment is seen as advantageous for patients with penile fractures, the timing of the operation is a significant consideration. Early surgical reconstruction is linked with a quicker recovery, a reduction in overall morbidity, reduced side effects or problems, and a decreased likelihood of penile curvature. (17) A new meta-analysis of 12 trials compared the rates of complications between urgent and delayed penile fracture treatment. (18) The authors reported that the rates of erectile dysfunction (ED) and tunical scar formation were nearly identical in both groups, though patients who received a repair quickly had a decreased incidence of penile curvature. Early surgical intervention was linked to significantly fewer problems. (19) In the current investigation, no patients presented with tunical plaque/nodule or ED.

Surgery treatment includes curettage, hemostasis drainage, and repair of the tunica albuginea tear using an absorbable suture. (2) A direct incision precisely over the defect provides optimal exposure with minimal tissue stress and can be performed under local anesthesia as a same-day procedure. (2) Our patients also underwent surgery, had the hematoma excavated and the tear repaired.

Conclusion

A fracture of the penile is a true urological emergency. Diagnosis can be made easily through an understanding of the mode of trauma and clinical characteristics. An immediate surgical examination and repair of tunica albuginea are optimal treatment options. Even in delayed cases, the surgery can be easily performed with little morbidity. Our patients were treated successfully with surgery.

Consent

As per international standard or university standard, patient(s) written consent has been collected and preserved by the author(s).

Ethical Approval:

As per international standard or university standard written ethical approval has been collected and preserved by the author(s).



References

1. Barros, R., Ribeiro, J.G.A., Silva, H.A.Md., Sá, F.Rd., Fosse Júnior, A.M., and Favorito, L.A. Urethral injury in penile fracture: a narrative review. *International Braz j Urol*. 2020;46:152-7.
2. Falcone, M., Garaffa, G, Castiglione, F., and Ralph, D.J.. Current management of penile fracture: an up-to-date systematic review. *Sexual Medicine Reviews*. 2018;6(2):253-60.
3. Gulmi, F.A. Penile Fracture. *Reviews in Urology*. 2018;20(1):41.
4. Kati, B., Akin, Y., Demir, M., Boran, O.F., Gumus, K., and Ciftci, H. Penile fracture and investigation of early surgical repair effects on erectile dysfunction. *Urologia Journal*. 2019;86(4):207-10.
5. Schmid, F.A., Held, U., Eberli, D., Pape H.C., and Halvachizadeh, S. Erectile dysfunction, and penile rehabilitation after pelvic fracture: a systematic review and meta-analysis. *BMJ Open*. 2021;11(5):e045117.
6. Haque, M.F., Paul, A.S., Swain, S., and Goyal, G. Assessment of long-term outcomes with immediate versus delayed surgical repair of penile fractures. *Urological Science*. 2020;31(2):73.
7. Mensah, J., Morton, B., and Kyei, M. Early surgical repair of penile fractures. *Ghana Medical Journal*. 2010;44(3).
8. Hughes, W.M., Natale, C., and Hellstrom, W.J. The management of penile fracture: a review of the literature with special consideration for patients undergoing collagenase clostridium histolyticum injection therapy. *Current Urology Reports*. 2021;22(2):1-7.
9. Barros, R., Hampl, D., Cavalcanti, A.G., Favorito, L.A., and Koifman, L. Lessons learned after 20 years experience with penile fracture. *International Braz j Urol*. 2020;46:409-16.

10. Barros, R., Ribeiro, J.G.A., Silva, H.A.Md., Sá, F.Rd., Fosse Júnior, A.M., and Favorito, L.A. Urethral injury in penile fracture: a narrative review. *International Braz j Urol.* 2020;46:152-7.
11. Shetty, M., Nerli, R., Kamat, S., Sadalge, A., Patil, V.K., and Amarkhed, S. Penile fractures: Results of delayed repair. *Indian Journal of Urology.* 2004;20(2):123.
12. Cozzi, D., Verrone, G.B., Agostini, S., Bartolini, M., D'Amico, G., Pradella, S., et al. Acute penile trauma: imaging features in the emergency setting. *La Radiologia Medica.* 2019;124(12):1270-80.
13. Yilmazel, F.K., Sam, E., Altay, M.S., Cinislioglu, A.E., Sam, E., Delice, O., et al. Surgical results in penile fracture: Our single-center experience. *The American Journal of Emergency Medicine.* 2021;44:184-6.
14. Taşkapu, H.H., Sönmez, M.G., Ecer, G., Uçmak, H., Aydın, A., and Balasar, M. Comparison of early period sexual function parameters between surgical repair and conservative treatment after a penile fracture. *Revista Internacional de Andrología.* 2022.
15. Simms, A., Baradaran, N., Lue, T.F., and Breyer, B.N. Penile Fractures: Evaluation and Management. *Urologic Clinics.* 2021;48(4):557-63.
16. Nale, Đ., and Mičić, S. Pulsative hematoma: a penile fracture complication. *Vojnosanitetski Pregled.* 2007;64(1):58-60.
17. Hodade DP, Chibeleian C, Vartolomei M, Chiujdea A, Martha O, Friedl A, et al. Management of Penile Fractures. *Romanian Journal of Urology.* 2019;18(4):30-3.
18. Amer T, Wilson R, Chlosta P, AlBuheissi S, Qazi H, Fraser M, et al. Penile fracture: a meta-analysis. *Urologia internationalis.* 2016;96(3):315-29.

19. Wong NC, Dason S, Bansal RK, Davies TO, Braga LH. Can it wait? A systematic review of immediate vs. delayed surgical repair of penile fractures. Canadian Urological Association Journal. 2017;11(1-2):53.

UNDER PEER REVIEW