

Diagnostic wandering in a therapeutic emergency: A case study of an AL cardiac amyloidosis mimicking tuberculosis

ABSTRACT

Background: Cardiac amyloidosis corresponds to a buildup of fibrillar proteins in the myocardium. It is characterized by non-specific signs that often lead to a late diagnosis, even though it is an emergency in some cases.

Objective: this case report emphasizes the very long route of care before the diagnosis of cardiac amyloidosis.

Case presentation: A 62-year-old woman with a history of close contact exposure to tuberculosis presented to a peripheral health center with a chronic cough. After several examinations, the diagnosis of pleural tuberculosis was retained. After two months of specific treatment, the patient did not improve, which motivated the request for echocardiography which found signs suggestive of cardiac amyloidosis. The questioning and the clinical examination were repeated. This gave arguments to continue the investigation which led to the final diagnosis of **light chain** (AL) cardiac amyloidosis.

Discussion:

The long route of care before diagnosis of cardiac amyloidosis worsens the prognosis because of the therapeutic delay. The patient often consults several specialists before arriving at the diagnosis. The presence of clinical signs called "red flags" associated with left ventricular hypertrophy should suggest cardiac amyloidosis. Cardiac MRI and biopsy of certain peripheral organs reduced the indication for endocardial biopsy for diagnostic purposes

Conclusion: to improve the prognosis, every clinician must know the red flags of cardiac amyloidosis

Keywords: Cardiac amyloidosis, pleural tuberculosis, multiple myeloma, cardiac MRI.

1. INTRODUCTION

Cardiac amyloidosis is characterized by the buildup of insoluble fibrillar protein chains in the heart muscle's extracellular matrix. In its AL form, it is a diagnostic emergency, but the symptoms are non-specific, which can lead to misdiagnosis or even incorrect treatment. We report a case of an AL cardiac amyloidosis mistaken for pleural tuberculosis.

2. CASE REPORT

A 62-year-old female from low-income family and with history of close contact tuberculosis exposure was seen in a peripheral medical center for chronic cough that had lasted 3 months and was accompanied by shortness of breath, asthenia, and fever. Physical examination revealed bilateral pleural effusion, which was confirmed by chest X-ray (figure 1). There was no Koch's bacillus isolated from the sputum. Due to the strong clinical suspicion, the diagnosis of pleural tuberculosis was nonetheless made, and the patient was started on treatment. After two months, the clinical course was marked by appearance of jugular vein turgidity, hepatomegaly, and lower limbs oedema. The patient was then referred to a pulmonary center, where GeneXpert and histological examination following pleural biopsy revealed no evidence of tuberculosis. As a result, the patient was referred to the cardiology department in order to rule out a cardiac etiology. The electrocardiogram which was performed revealed low voltage QRS in frontal leads and pseudo-infarction pattern in precordial leads (figure 2). Echocardiography showed biventricular hypertrophy and altered left ventricular ejection fraction of 40%. Left ventricular global strain was altered with a base-apex gradient suggesting cardiac amyloidosis.

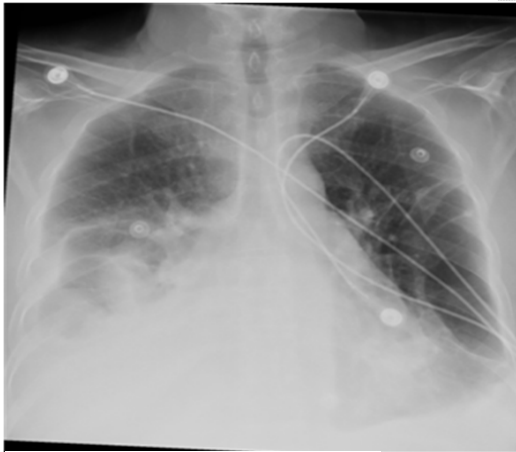

Fig1: Chest X-ray

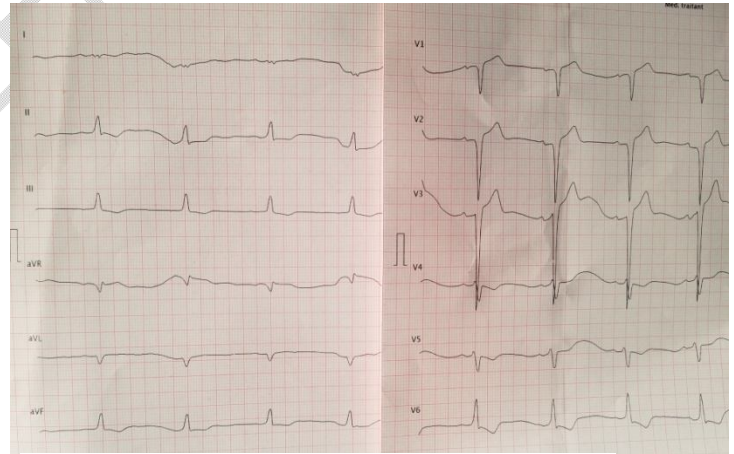


Fig2: electrocardiogram

Physical examination was then repeated to search for any other indicators of cardiac amyloidosis or red flags. In addition to the initial symptoms, we discovered orthostatic hypotension, tingling in hands and dysphonia, which had been developing for three years. Despite multiple visits to the otorhinolaryngology and neurology departments, no clear etiology was identified. These three signs belong to the red flags of amyloidosis and a cardiac MRI was requested. It showed late subendocardial enhancement in favor of cardiac amyloidosis (figure 4). The patient was sent to the department of internal medicine to be

evaluated for gammopathy. The serum protein immunoelectrophoresis and light chain test both revealed a monoclonal IgG Lambda gammopathy, whereas the myelogram revealed 17% plasmacytosis. The rest of the biological work-up revealed hypercalcemia at 90 mg/dl, troponin at 148 pg/ml (normal at 17 pg/ml), and NTproBNP at 6491 pg/ml. AL cardiac amyloidosis complicated multiple myeloma was the ultimate diagnosis. The patient was finally put on treatment but the evolution was fatal.

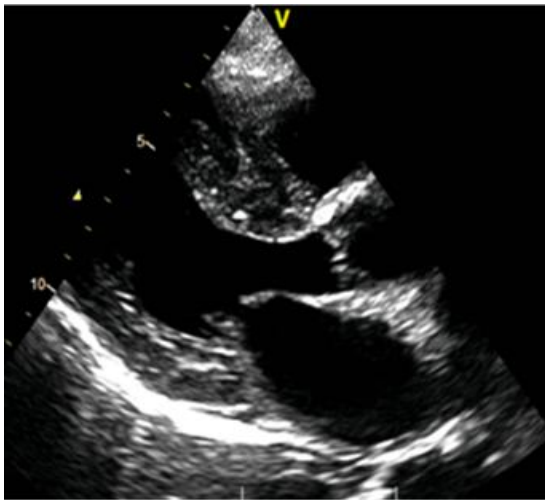


Fig3: Echocardiogram: left ventricle hypertrophy



Fig 4: Left ventricle strain: base-apex gradient

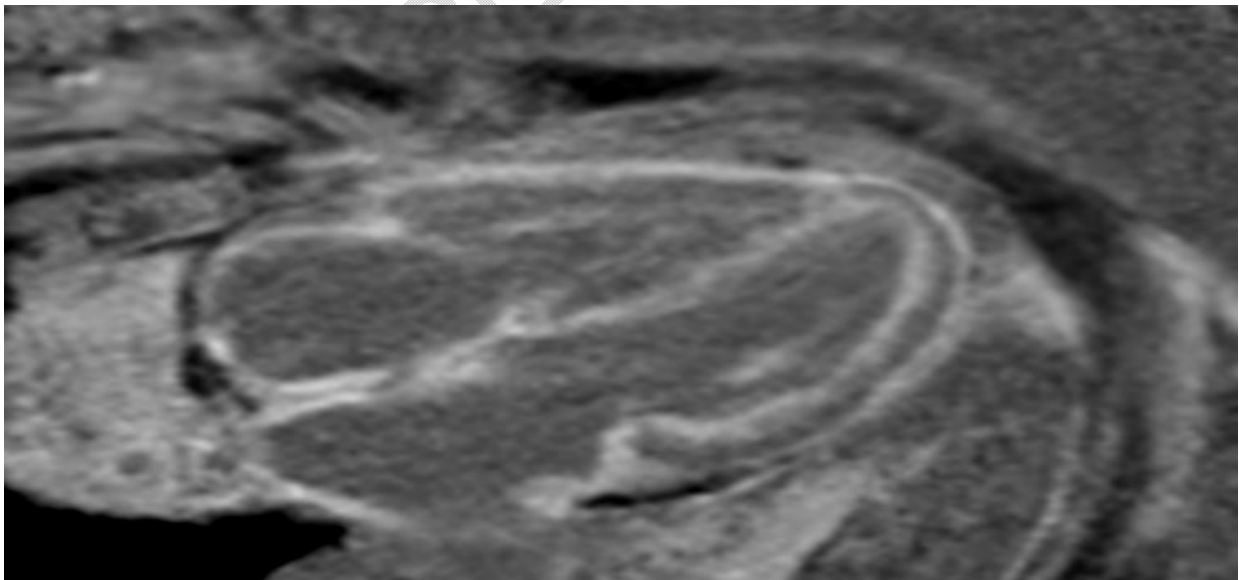


Figure 5: Cardiac MRI, late diffuse subendocardial enhancement

3. DISCUSSION

AL amyloidosis is a relatively rare illness, with a global prevalence of 5.1 to 12.8 cases per million person-years, a male preponderance, and a median age at diagnosis of 64 years [1]. AL cardiac amyloidosis is a therapeutic emergency since the prognosis is pejorative without therapy. Extracardiac involvement usually occurs a year before the diagnosis [2]. A diagnosis at this stage significantly improves the patient's prognosis. In our patient, the duration between the first extracardiac signs or red flags and the diagnosis was three years, which significantly delayed care. Due to the lack of specificity of clinical signs, patients are required to consult several specialists, sometimes resulting in other diagnoses for which they administer potentially deleterious treatments [3]. The strong clinical suspicion, despite the absence of definite histological evidence of tuberculosis, led to the treatment of pleural tuberculosis in our patient case. Echocardiography, performed regarding the worsening of the clinical symptomatology, allowed us to suspect the diagnosis. The triad of biventricular hypertrophy, restrictive mitral Doppler pattern and pericardial effusion is suggestive [4]. Alteration of the global strain with a base-apex gradient is pathognomonic of amyloidosis [5]. At this level of the clinical approach, physicians should not hesitate to repeat the questioning and clinical examination to look for red flags, as illustrated by this clinical case. Cardiac MRI classically shows late subendocardial enhancement, difficulty in adjusting T1 and elongated T1 mapping which is more suggestive of AL amyloidosis. Involvement is most often diffuse, but may be localized, indicating an early stage [6]. The most common cardiac types are transthyretin amyloidosis (ATTR-CM) and AL amyloidosis. Then, the next step is to undertake

a bone scintigraphy to search for cardiac fixation, eventually followed by a biological evaluation of gammopathy, which includes immune-electrophoresis, serum free light chain test, Bence-Jones proteinuria, and maybe an osteo-medullary biopsy. When there is a significant cardiac fixation on scintigraphy and no gammopathy is found, the diagnosis of ATTR-CM is retained. However, if both are negative, another type of cardiac amyloidosis should be considered [7]. In other intermediate scenarios, it is recommended to proceed to histological examination. The presence of a gammopathy is highly associated with AL amyloidosis. Diagnosis is done by biopsy on the salivary gland or subcutaneous and rectal fat. Congo red coloration, when paired with polarized light, causes amyloid proteins to look apple-green on microscopy. Typing can be done by anti-kappa and lambda antibodies [8]. Nonetheless, if the nature of the amyloid deposits cannot be identified, the diagnosis of AL amyloidosis is sometimes made based on a number of arguments, including clinical context compatible with AL amyloidosis and the presence of a monoclonal gammopathy outside of a familial context of hereditary ATTR-CM [9]. The prognosis is assessed according to the cardiac biomarkers like troponin and BNP or NTproBNP level. The higher they are, the worse the prognosis [10,11].

4. CONCLUSION

AL cardiac amyloidosis continues to have a poor prognosis despite recent therapeutic advances. The challenge is to make diagnosis before cardiac involvement which is itself a marker of poor prognosis. This can take a long time between the primary and tertiary care.

CONSENT

As per international standard or university standard, patient (s) written consent has been collected and preserved by the author (s)

ETHICAL APPROVAL

As per international standard or university standard, written ethical approval has been collected and preserved by the author(s).

REFERENCES

1. Baker KR. Light Chain Amyloidosis: Epidemiology, Staging, and Prognostication. *Methodist DeBakey Cardiovasc J.* 2022;18(2):27–35.
2. Hester LL, Gifkins DM, M Bellew K, Vermeulen J, Schechter JM, Strony J, et al. Diagnostic delay and characterization of the clinical prodrome in AL amyloidosis among 1523 US adults diagnosed between 2001 and 2019. *Eur J Haematol.* oct 2021;107(4):428-35.
3. Lousada I, Maurer M, Warner M, Guthrie S, Hsu K, Grogan M. Amyloidosis research consortium cardiac amyloidosis survey: results from patients with al and attr amyloidosis and their caregivers. *J Am Coll Cardiol.* 2018; 71 (11_Supplement):A890–A890.
4. Kyriakou P, Mouselimis D, Tsarouchas A, Rigopoulos A, Bakogiannis C, Noutsias M, et al. Diagnosis of cardiac amyloidosis: a systematic review on the role of imaging and biomarkers. *BMC Cardiovasc Disord.* 2018;18:221.
5. Choukair MO, Halawi A, Nehmeh A, Kazma H. Role of Echocardiography in the Diagnosis of Light Chain Amyloidosis: A Case Report and Review of Literature. *Cureus.* 2020;12(11):e11377.
6. Shah O, Choh N, Shera T, Shera F, Gojwari T, Shaheen F, et al. Magnetic Resonance Imaging in Cardiac Amyloidosis: Unraveling the Stealth Entity. *Int J Angiol Off Publ Int Coll Angiol Inc.* 2022;31(1):40–47.
7. Garcia-Pavia P, Rapezzi C, Adler Y, Arad M, Basso C, Brucato A, et al. Diagnosis and treatment of cardiac amyloidosis: a position statement of the ESC Working Group on Myocardial and Pericardial Diseases. *Eur Heart J.* 2021;42(16):1554–1568.
8. Fotiou D, Dimopoulos MA, Kastritis E. Systemic AL Amyloidosis: Current Approaches to Diagnosis and Management. *HemaSphere.* août 2020;4(4):e454.

9. Jaccard A, Desport E, Mohty D, Bridoux F. Amylose AL. Rev Médecine Interne. 1 févr2015;36(2):89-97.
10. Palladini G, Sachchithanantham S, Milani P, Gillmore J, Foli A, Lachmann H, et al. A European collaborative study of cyclophosphamide, bortezomib, and dexamethasone in upfront treatment of systemic AL amyloidosis. Blood. 30 juill2015;126(5):612-5.
11. Ash S, Shorer E, Ramgobin D, Vo M, Gibbons J, Golamari R, et al. Cardiac amyloidosis-A review of current literature for the practicing physician. Clin Cardiol. 2021;44(3):322–331.

UNDER PEER REVIEW