

Ischemic ventricular septal defect: two rare cases

Abstract:

Introduction: Interventricular septal rupture occurring in the acute phase of a myocardial infarction is a rare complication, its incidence varies between 1 and 2%. We present the observation of two patients with myocardial infarction complicated by apical rupture of the interventricular septum.

Cases:

Case1: we report an 56 years old female with a history of hypertension and diabetes mellitus admitted to our intensive care unit for a ST-Segment–Elevation Acute Coronary Syndrome treated with thrombolysis complicated with heart failure the patient presented a hemodynamic instability requiring the introduction of vasoactive drugs. we performed an echocardiography that showed a solution of continuity of the interventricular septum

Case2: we report is an 88 years old active male smoker admitted to our intensive care unit for an anterior ST segment elevation acute coronary syndrome treated with thrombolysis. On the 2nd day of hospitalization, the patient presented a supra-ventricular tachycardia at 160bpm A cardiac echography was then realized which objectified a solution of continuity in the apical segment of the inter ventricular septum

Conclusion: Ischemic ventricular defect is a rare, serious, and major mechanical complication of myocardial infarction. The best treatment is still surgery despite its high morbidity and mortality rate in the postoperative period

Introduction :

Myocardial rupture after acute myocardial infarction (MI) may involve the left (or right) ventricular free wall, the interventricular septum, and/or the papillary muscles. Interventricular septal rupture occurring in the acute phase of a myocardial infarction is a rare complication, its incidence varies between 1 and 2%. Septal rupture usually occurs within the first week without reperfusion therapy. Patients present clinically Chest pain, shortness of breath, low cardiac output, cardiogenic Shock and the diagnosis is made by Doppler echocardiography. Treatment consists of short-term medical and mechanical support Until the defect can be corrected with surgery or TCC. However, without surgical intervention, ischemic IVCs are responsible for 5% of deaths occurring in the immediate aftermath of a myocardial infarction. We present the observation of two patients with myocardial infarction complicated by apical rupture of the interventricular septum.

Case reports:

Case 1: We report the case of a 56 years old female with a history of hypertension and diabetes mellitus admitted to our intensive care unit for a ST-Segment–Elevation Acute Coronary Syndrome treated with thrombolysis complicated with heart failure. The medical examination revealed a conscious patient with a blood pressure of 150/80 mmHg, respiratory rate of 27 breaths/min, Oxygen saturation of 96%, heart rate of 90 bpm. EKG showed a sinus rhythm of 99bpm, anteroseptal Q waves with a ST elevation. The ultrasensitive troponins were elevated to 6.01 ng/ml (normal < 0.016 ng/ml). The cardiac ultrasound showed a reduced LVEF 35%, a restrictive mitral profile, minimal mitral regurgitation and no right ventricular dysfunction. The treatment consisted of enoxaparin 100U/Kg bid, antiplatelet agents: clopidogrel 75mg once daily, Aspirin 75mg once daily, diuretics 240mg

continuous perfusion, opioids and oxygen nasal the patient's condition improves daily, but after 3 days of hospitalization the patient presented a hemodynamic instability requiring the introduction of vasoactive drugs. We performed an echocardiography that showed a solution of continuity of the interventricular septum (Figure 1). The patient died within hours of cardiogenic shock. Coronary angiography has not been performed.

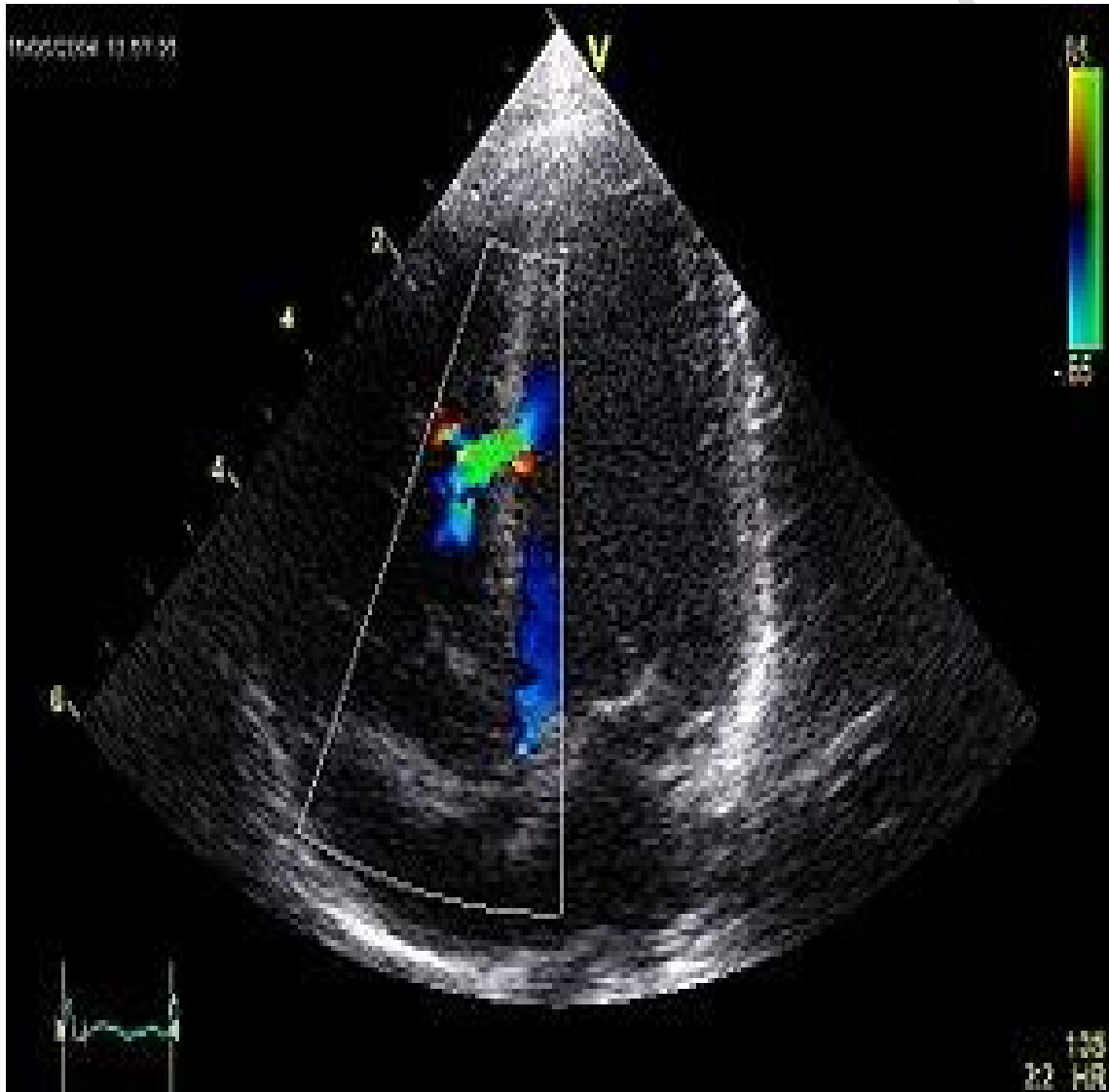


Figure 1 :Apical 4 chamber view showing a rupture of the interventricular septum

Case 2 :The second case we report is an 88 years old active male smoker admitted to our intensive care unit for an anterior ST segment elevation acute coronary syndrome treated with thrombolysis . The medical history revealed a typical angina associated with vomiting, evolving 8 hours before the admission. The medical examination revealed a conscious patient with a blood pressure of 100/80 mmHg, heart rate of 106 bpm. EKG showed a sinus rhythm of 110bpm, anteroseptal Q waves with a ST elevation.). The cardiac ultrasound showed a reduced LVEF 25%, minimal mitral and aortic regurgitation and no right ventricular dysfunction. The ultrasensitive troponins were elevated to 31.8 ng/ml (normal < 0.016 ng/ml). Treatment consisted of antiplatelet enoxaparin, diuretics, statins and oxygen. On the 2nd day of hospitalization, the patient presented a supra-ventricular tachycardia at 160bpm poorly tolerated, refractory to electrical cardioversion complicated by a cardiorespiratory arrest recovered by cardiorespiratory resuscitation measures. A cardiac echography was then realized which objectified a solution of continuity in the apical segment of the inter ventricular septum (figure 2) . The patient then presented with ventricular tachycardia reduced by electrical cardioversion and then a second cardiorespiratory arrest that was not recovered despite cardiorespiratory resuscitation measures. Coronary angiography has not been performed.

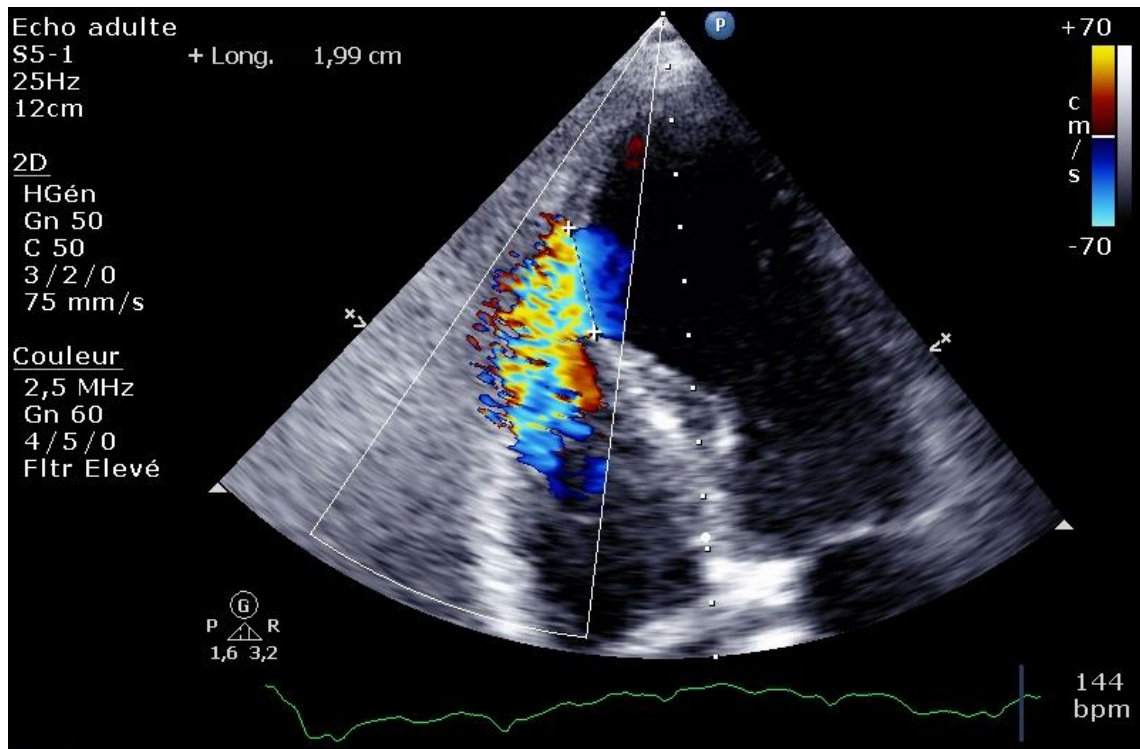


Figure 2: Rupture of the interventricular septum in its apical segment.

Discussion :

Myocardial rupture is a daunting complication of MI and accounts for approximately 15% of deaths in the acute phase of recent MI [1].

Since the advent of thrombolysis and primary angioplasty, Braunwald et al. described risk factors for ischemic myocardial rupture including advanced age, female gender, transmural nature of the infarction, and the left anterior descending artery territory [2]. Our patients had these characteristics. It occurs on average 3 to 10 days after the MI, usually by refractory cardiogenic shock leading to rapid death even before surgical repair, in the majority of cases[3] as in the case of our patients. Septal rupture appears mostly in anterior MI (66% of septal ruptures) as found in our patients. It usually involves the apical portion of anteroseptal infarcted area with transmural necrosis.

Echocardiography performed as soon as the murmur appears or as soon as signs of instability or cardiac insufficiency appear allows a diagnosis of certainty with the demonstration of a defect in 2D mode

and the shunt in color Doppler [4].

Thrombolytic therapy reduces myocardial ischemic volume, but reperfusion can potentially lead to myocardial hemorrhage and dissection in the zone of necrotic myocardium, thereby facilitating the development of rupture within 24 hours after the onset of Acute MI[5][6][7].

The relation of cardiac rupture to timing of thrombolytic administration is controversial. Some studies have shown an increased risk with late therapy (>12 hours after symptom onset),[8] but more recent evidence does not support this finding.[9]

Studies showed that patients who develop ventricular septal defect (VSD) after acute MI are more likely to have total occlusion of the infarct artery. This suggests that the pathophysiology of acute VSD involves sudden, severe ischemia, leading to extensive myocardial necrosis, and that patients who do not reperfuse with thrombolysis are at increased risk of mechanical complications.[10]

It also appeared that patients with inferior infarcts and VSDs tended to have a worse outcome than those with anterior infarcts[11]Edwards and colleagues found in their necropsy study that inferior infarcts were more likely to be associated with complex VSDs (multiple, irregular, and/or variable interventricular connections) located in the inferobasal portion of the septum and therefore were more difficult to approach surgically. Anterior infarcts were more commonly associated with simple, through-and-through defects in the apical septum, which tend to be more easily repaired.[11]

The two main prognostic factors for septal rupture are the degree of global systolic dysfunction secondary to infarction and the extent of the septal defect. The prognosis is still very poor with a 30-day mortality rate of 74% [4]. However, the mortality rates for all patients with VSDs were similar at 30 days and 1 year .[12]This suggests that if the patient survives the initial admission, the long-term prognosis is relatively good.[12]

Post-ischemic rupture of the ventricular septum still represents a major challenge for cardiologists and cardiac surgeons. Operation through the infarcted ventricular zone by patch closure along with intra-aortic balloon counterpulsation support is currently the standard surgical approach.[13] It should be noted that concomitant coronary artery bypass graft (CABG) did not influence early or late survival. [14]

Conclusion :

Ischemic ventricular defect is a rare, serious, and major mechanical complication of myocardial infarction. The best treatment is still surgery despite its high morbidity and mortality rate in the postoperative period.

The diagnosis is mainly echocardiographic. A late diagnosis is a very poor prognostic factor.

References :

- [1]Walts PA, Gillinov AM. Survival after simultaneous left ventricular free wall, papillary muscle, and ventricular septal rupture. *Ann Thorac Surg.* 2004 Nov;78(5):e77-78.
- [2]Braunwald E, Zipes DP, Libby P. Acute Myocardial Infarction. In: Antman EM, Braunwald E, editors. *Heart Disease, a text book of cardiovascular medicine.* 6e éd. Philadelphia: WB Saunders; 2001. pp. 1114-218.
- [3]Hackel DB, Wagner GS. Acute myocardial infarction with papillary muscle rupture. *ClinCardiol.* 1993 Jan;16(1):59-64.
- [4]Cummings RG, Califf R, Jones RN, Reimer KA, Kong YH, Lowe JE. Correlates of survival in patients with post infarction ventricular septal defect. *Ann ThoracSurg.* 1989 Jun;47(6):824-830
- [5]Crenshaw BS, Granger CB, Birnbaum Y, et al. Risk factors, angiographic patterns, and outcomes in patients with ventricular septal defect complicating acute myocardial infarction. GUSTO-I (Global Utilization of Streptokinase and TPA for Occluded Coronary Arteries) Trial Investigators. *Circulation.* 2000; 101: 27-32.

[6]Yip HK, Fang CY, Tsai KT, et al. The potential impact of primary percutaneous coronary intervention on ventricular septal rupture complicating acute myocardial infarction. *Chest*. 2004; 125: 1622-1628.

[7] Poulsen SH, Praestholm M, Munk K, Wierup P, Egeblad H, Nielsen-Kudsk JE. Ventricular septal rupture complicating acute myocardial infarction: clinical characteristics and contemporary outcome. *Ann Thorac Surg*. 2008; 85: 1591-1596.

[8]Dodge HT, Sandler H, Ballew DW, Lord JD. The use of biplane angiocardigraphy for the measurement of left ventricular volume in man. ***Am Heart J***.1960; 60:762–776.

[9]Becker RC, Gore JM, Lambrew C, Weaver WD, Rubinson RM, French WJ, Tiefenbrunn AJ, Bowlby LJ, Rogers WJ, for the National Registry of Myocardial Infarction Participants. A composite view of cardiac rupture in the United States National Registry of Myocardial Infarction. ***J Am Coll Cardiol***.1996; 27:1321–1326.

[10] Cummings RG, Reimer KA, Califf R, Hackel D, Boswick J, Lowe JE. Quantitative analysis of right and left ventricular infarction in the presence of postinfarction ventricular septal defect. ***Circulation***.1988; 77:33–42.

[11] Edwards SB, Edwards WD, Edwards JE. Ventricular septal rupture complicating acute myocardial infarction: identification of simple and complex types in 53 autopsied hearts. ***Am J Cardiol***.1984; 54:1201–1205.

[12]Crenshaw, B. S., Granger, C. B., Birnbaum, Y., Pieper, K. S., Morris, D. C., Kleiman, N. S., ... Topol, E. J. (2000). Risk Factors, Angiographic Patterns, and Outcomes in Patients With Ventricular Septal Defect Complicating Acute Myocardial Infarction. *Circulation*, 101(1), 27–32.

[13]Mantovani V, Mariscalco G, Leva C, Blanzola C, Sala A. Surgical repair of post-infarction ventricular septal defect: 19 years of experience. *Int J Cardiol*. 2006; 108: 202-206.

[14]Alexandre Cinq-Mars, Pierre Voisine, François Dagenais, Risk factors of mortality after surgical correction of ventricular septal defect following myocardial infarction: Retrospective analysis and review of the literature, *International Journal of Cardiology*, Volume 206,2016,Pages 27-36,

Keywords: Coronary artery disease, Myocardial infarction, Ischemic septal defect,