

Poorly Tolerated Ventricular Tachycardia Allowing the Discovery of a Post-infarction Aneurysm (Clinical Case).

ABSTRACT:

Left ventricular pseudoaneurysms are rare. They are usually form from a rupture of the myocardium contained by pericardial adhesions. Unlike true aneurysms, false aneurysms have a narrow neck and lack myocardial elements. They can be constituted spontaneously or acquired.

We report the case of a 60-year-old patient, an active alcoholic and tobacco user, consulted for palpitations evolving for 5 hours associated with NYHA stage II dyspnea. In whom the initial examination found a hemodynamically unstable patient with a BP of 97/65 mmHg mmHg, tachycardia at 160 bpm, a systolic murmur along the left edge of the sternum radiating towards the its tip and base, with crackles at the bases of the lungs. On the ECG, we note a ventricular tachycardia reduced by an external electric shock of 200 joules. The post-reduction ECG showed a regular sinus rhythm with Q waves of infero-basal necrosis. Transthoracic ultrasound revealed a non-symmetrical dilated left ventricle with hypokinesia localized at the inferior, infero-septal and infero-lateral walls with an aneurysm developed at the expense of its infero-basal wall, 30% EF associated with mild mitral regurgitation. Objective biological evaluation of cardiac enzymes was slightly elevated, the rest of the evaluation was without abnormality. The coronarography shows a tight stenosis of the middle and distal circumflex artery, revascularized by the placement of 2 active stents. The patient was put on dual antiplatelet, beta-blocker and ACE inhibitor therapy in addition to amiodarone to maintain sinus rhythm.

Left ventricular aneurysm is a classic complication after myocardial infarction, potentially causing congestive heart failure, thromboembolic event due to parietal rupture, or sometimes ventricular arrhythmia.

KEYWORDS: ventricular tachycardia; myocardial infarction; Aneurysm.

Introduction:

Left ventricular pseudoaneurysms are rare. They are usually form from a rupture of the myocardium contained by pericardial adhesions. Unlike true aneurysms, false aneurysms have a narrow neck and lack myocardial elements. They can occur spontaneously or acquired.

We report a case of a large left ventricular pseudoaneurysm discovered after an episode of Ventricular tachycardia. The most common etiology of such condition is myocardial infarction. However, other rare causes like traumatic, iatrogenic, or infectious type exist.

Case Report:

A 60-year-old patient, smoker consuming 10 packet/year of cigarette and occasional alcoholic, consulted for palpitations evolving for 5 hours associated with NYHA stage III dyspnea. At admission, patient was hemodynamically unstable patient with a BP of 87/55 mmHg, tachycardia at 160 bpm, and a systolic murmur along the left edge of the sternum radiating to the tip and base, with crackles at the bases of the lungs.

The ECG findings showed a (figure 1) ventricular tachycardia, reduced by an external electric shock of 200 joules.

The post-reduction ECG showed a regular sinus rhythm with Q waves of infero-basal necrosis. Transthoracic ultrasound (Figure 2) revealed a dilated LV associated with hypokinesia of the inferior, infero-septal, and inferolateral walls with a ventricular aneurysm developed at the expense of its infero-basal wall, EF at 30% and mild mitral regurgitation.

Biological assessment of cardiac enzymes slightly elevated before external electric shock was delivered, the rest of the assessment was without abnormality.

Coronary angiography (figure 3) showed tight stenosis of the middle and distal circumflex (CX) arteries revascularized by the endovascular implantation of 2 active stents.

The patient was put on oral double antiplatelet therapy, beta blockers and converting enzyme inhibitor in addition to amiodarone to maintain sinus rhythm.

The patient was referred to a cardiac surgery center for the closure of the ventricular aneurysm with a patch type bovine pericardium

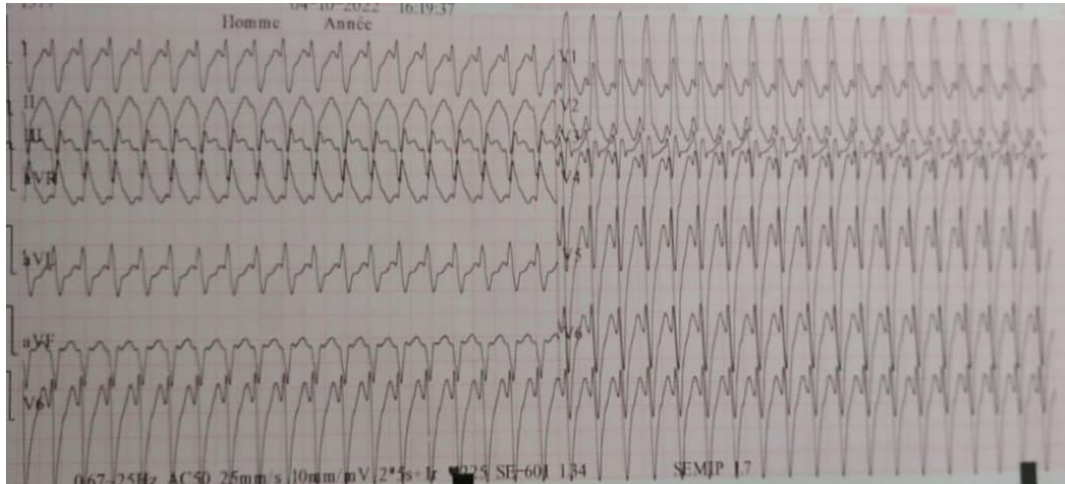


Figure 1: ECG: ventricular tachycardia at 225 bpm with a VT score of 4

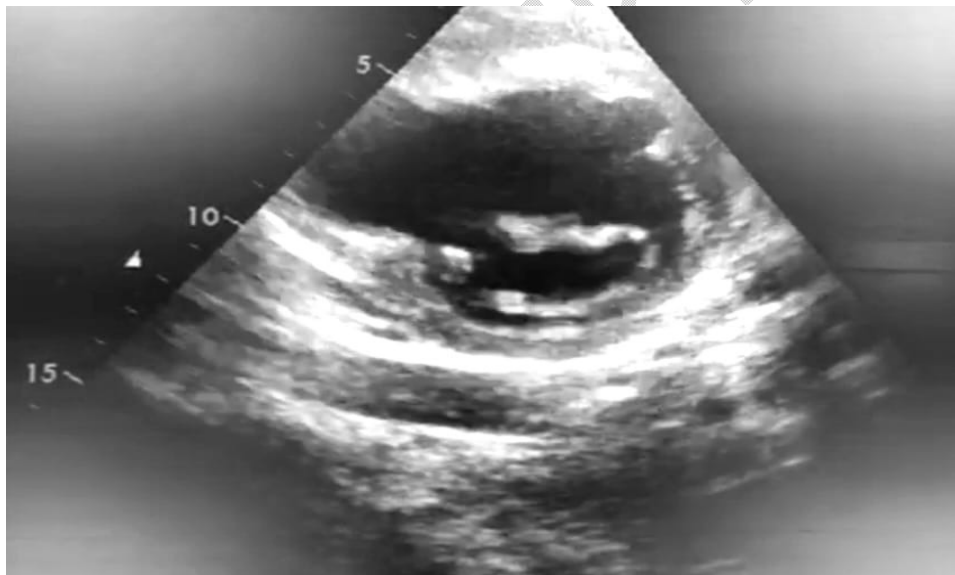


Figure 2: TTE short axis view: showing a ventricular aneurysm at its infero-basal wall.

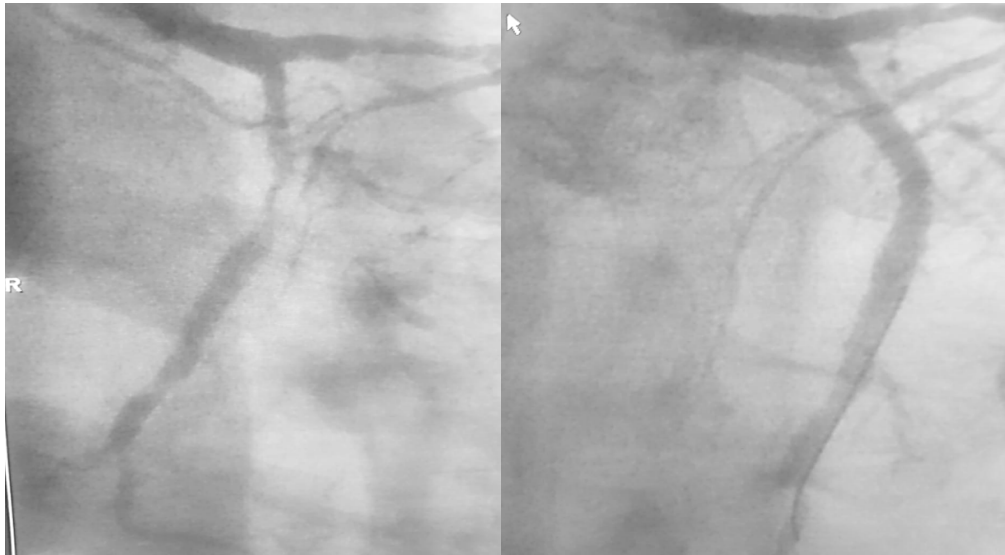


Figure 3: Coronary angiography showing tight stenosis of the middle and distal CX arteries (right hand side of the picture) revascularized by endovascular implantation of 2 active stents (left hand side of the picture)

Discussion:

A left ventricular pseudoaneurysm or “false aneurysm” is a cavity that is formed when a ruptured myocardium is contained by adherent pericardium or scar tissue. Contrary to the true aneurysm whose wall retains all its elements, the pseudoaneurysm contains neither endocardium nor myocardium(1). Its preferential location is located at the level of the posterior or inferior walls, more rarely at the level of the lateral or anterior walls.

Patients often present with symptoms of chest pain, dyspnea, or heart failure. If the ruptured myocardium is not fully contained or if the pseudoaneurysm in turn ruptures, then the patient may experience tamponade, cardiogenic shock, or sudden death. Embolic phenomena or ventricular tachycardia-type arrhythmias as in the case of our patient are rare. In 10% of cases, patients remain completely asymptomatic(2).

Ventricular tachycardia is related to the presence of an intraventricular reentry pathway. A ventricular extrasystole can thus penetrate the reentry circuit causing sustained ventricular tachycardia, this pathway is often secondary to a scar from a myocardial infarction as in the case of our patient

Diagnosis of ventricular pseudoaneurysm is not easy. This rare condition is often overlooked by clinicians even though it can greatly affect the patient's vital prognosis (3).

Indeed, as our case illustrates, the clinical picture is often atypical and the primary cardiac assessment was based on ECG and transthoracic echocardiography which can be misleading by its lack of sensitivity and specificity with respect to such a condition (2).

The main etiology of left ventricular pseudoaneurysms is ventricular ischemia, which weakens the myocardial wall then eventually ruptures. The pseudoaneurysm is then contained by the pericardium. It complicates less than 0.1% of myocardial infarctions and its mortality is 50% in the absence of surgical treatment. It can also be the consequence of cardiac surgery (33%), an invasive procedure (pericardial or pleural drainage) (3%), thoracic trauma (7%), infection (5%) or combined processes. Non-coronary etiologies are more often found in young subjects (4).

In our case, the pseudoaneurysm is a complication that occurred following a myocardial infarction that had not been objectified before, since the patient has never felt anginal chest pain and he consults after having developed a rhythm disorder, a none tolerated VT. The ischemia is retained in front of the ECG findings which showed a sequelae infero-basal myocardial infarction (MI) and coronary angiography findings indicating a complete revascularization of the diseased arteries.

Currently, the review of the literature reveals that angiography, and more precisely ventriculography, allows a definitive diagnosis in 85% of cases with only 2% of false negatives. However, it remains an invasive technique (5).

Transthoracic echocardiography is less invasive, less expensive and a readily available technique. Its weak points lies on operator-dependent and the lack of optimal conditions for realization. It is generally the first choice of tool but is less sensitive in the detection of pseudo aneurysms (6).

Computed tomography with 3D reconstruction represents a reliable imaging technique for diagnosis. However, it sometimes lacks precision in terms of tissue definition. Magnetic resonance, when available and in the absence of contraindications, is of considerable help in the diagnosis. Delayed enhancement after gadolinium perfusion is a specific marker of myocardial fibrosis, it helps to differentiate between true and false aneurysms(7).

The surgical indication remains formal in the event of diagnosis of a false aneurysm because the risk of rupture is greater than in the event of a true aneurysm (8).

Several surgical options exist, the most commonly used consists of closing the defect with a patch of bovine pericardium. The intervention is done by median sternotomy, under extracorporeal circulation. The post-operative follow-up is often favourable(9,10).

Untreated pseudoaneurysms can cause complications such as rupture, tamponade, occurrence of thromboembolic phenomena, and mass syndrome with compression of neighboring structures, infection, arrhythmia or heart failure.

Conclusion:

The left ventricular aneurysm is a classic complication after myocardial infarction, potentially causing congestive heart failure, and thromboembolic event of parietal rupture, or sometimes ventricular arrhythmia.

CONSENT

As per international standard, **parental** written consent has been collected and preserved by the author(s).

COMPETING INTERESTS

Authors have declared that no competing interests exist.

References

1. Martínez MÁ, Pavón M, Hidalgo R. Left Ventricular Aneurysm and Late Ventricular Arrhythmia After Myocardial Contusion. *Rev Esp Cardiol Engl Ed*. 2003;56:745-76.
2. Haine SE, Paelinck BP, Vrints CJ. Post-traumatic focal true left ventricular aneurysm. *Heart*. 2004;90:1009-1009.
3. Guo JR, Zheng LH, Wu LM, Ding LG, Yao Y. Aneurysm-related ischemic ventricular tachycardia: safety and efficacy of catheter ablation. *Medicine (Baltimore)*. 2017;96:e6442.
4. Cardiac Aneurysm with Ventricular Tachycardia and Subsequent Excision of Aneurysm | *Circulation* [Internet]. [cité 27 oct 2022]. Disponible sur: <https://www.ahajournals.org/doi/10.1161/01.CIR.20.2.251>
5. Singh S, Puri A, Narain V, Sahni J. Post-traumatic left ventricular pseudoaneurysm. *Interact Cardiovasc Thorac Surg*. 2012;14:359-61.

6. Keskin M, Çınar T, Hayiroğlu Mİ, Kozan Ö. Resistant Ventricular Tachycardia due to Idiopathic Left Ventricular Aneurysm: Successful Treatment with Surgery. *J Tehran Heart Cent.* janv 2019;14:33-6.
7. Hage F, Hage A, Al-Amadi H, Goela A, Guo LR. Surgical management of patient with left ventricular aneurysm and ventricular tachycardia. *SAGE Open Med Case Rep.*2021;9:2050313X211065881.
8. Sattar Y, Alraies MC. Ventricular Aneurysm [Internet]. *StatPearls [Internet]. StatPearls Publishing;* 2021 [cité 27 oct 2022]. Disponible sur: <https://www.ncbi.nlm.nih.gov/books/NBK555955/>
9. Zhang X, Liu X. Ventricular tachycardia and heart failure in a patient of mid-ventricular obstructive hypertrophic cardiomyopathy with apical aneurysm: A case report. *Exp Ther Med.* 2019;18:2238-42.
10. Masson E. Ventricular tachycardia revealing a left ventricular aneurysm [Internet]. *EM-Consulte.* [cité 27 oct 2022]. Disponible sur: <https://www.em-consulte.com/article/232901/ventricular-tachycardia-revealing-a-left-ventricule>