

# CASE REPORT ON PARADUODENAL HERNIA: UNCOMMON CAUSE OF A COMMON SURGICAL PROBLEM

## Abstract

Objectives :

Paraduodenal hernia is the most common type of internal hernia. Patients generally present to the emergency with a short history of abdominal pain, associated with episodes of nausea and vomiting. Ischemia of the herniated bowel loop may set in as a result of closed loop obstruction,

Subjects and methods :

A 32 years old male patient who presented with complaints of pain abdomen, breathlessness and multiple episodes of vomiting for a day.

Results :

He underwent emergency exploratory laparotomy with excision of the hernial sac, bowel resection with duodeno-ileal anastomosis and was discharged on post op day 5 on a liquid diet.

Conclusion :

An early diagnosis with appropriate imaging techniques, X-ray or CT scan of the abdomen is essential to reduce the associated morbidity. Early surgical intervention is the deciding factor in the associated mortality in these patients. The surgery should be done with the intent of reduction of the contents with or without excision of the hernia wall/sac and simple closure of the defect with non-absorbable interrupted sutures, staying away from the vessels that form the walls of the hernia.

**Keywords: Right, Paraduodenal hernia, Internal Hernia, Small bowel ischemia.**

## Introduction

Internal hernia is the protrusion of viscus through an opening in the peritoneal or mesenteric folds, accounting for 0.6 to 5.8 % of all cases of acute intestinal obstruction.<sup>[1]</sup>

There are two theories pertaining to its development:

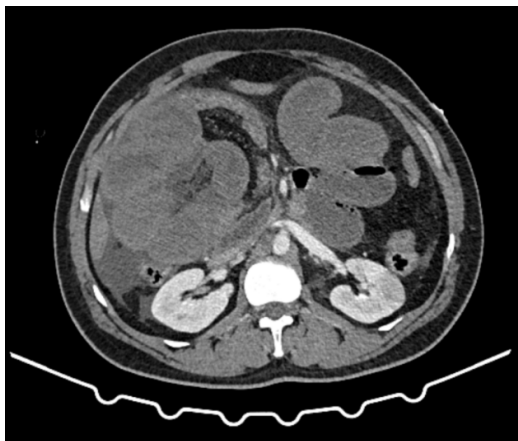
- a. Moynihan's theory: It is the more accepted theory behind the development of such defects, wherein he attributed it to physiological adhesions, arising as the bowel returns to the abdomen during development and fusion of the common dorsal mesentery with the posterior abdominal wall, leading to the development of fusion folds and fossae.
- b. Andrew's theory: Attributed it to the developmental fusion defects of peritoneum, which incarcerated the small bowel beneath the developing colon.<sup>[2]</sup>

Internal hernias may present early in life, with recurrent sub-acute obstructive symptoms like, recurrent pain abdomen, episodes of vomiting or intermittent cramping as and when the gut loops herniate and get relieved as they reduce spontaneously or late in life, when the herniated gut loops are unable to reduce spontaneously presenting with symptoms of acute intestinal obstruction.

Paraduodenal hernias also known as mesocolic hernias, account for 53% of all internal hernias, of which left is more common than right. They have a male preponderance with a ratio of 3:1. It requires a high index of suspicion to identify such a defect in patients with recurring subacute intestinal obstruction or post-prandial abdominal discomfort, which may improve with body position. A pre-operative diagnosis is not always possible in these cases. [3,4]

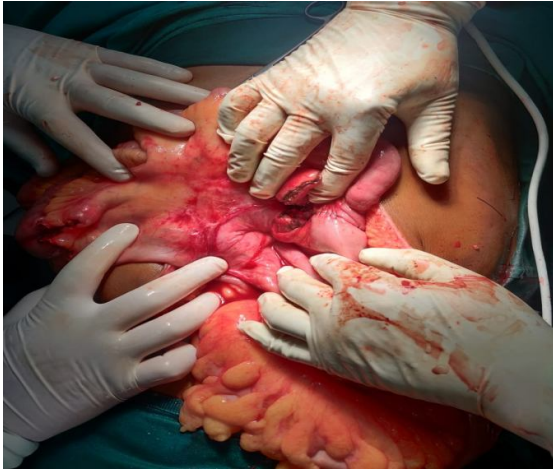## Case presentation

A 32 years old male, presented to our emergency department with pain abdomen, multiple episodes of vomiting and breathlessness for a day, without any past history of similar complaints. On examination, he was tachycardic(120 bpm), tachypnoeic(26 per minute) and in shock (unrecordable BP), had a tense abdomen, with diffuse tenderness and guarding. Patient was evaluated using ultrasound abdomen, showing, small bowel loops dilated upto 4.5 cm with moderate ascites, chest and abdominal x-rays showed, multiple air fluid levels and contrast enhanced CT scan of the abdomen showed, a peritoneal sac herniating through the right paraduodenal fossa with the small bowel loops as content. He was taken for exploratory laparotomy under the cover of inotropes, I.V. fluids and antibiotics. Intra-operatively, small bowel loops were seen herniating through the defect, with ischemia of the jejunum and ileum, ischemic segment resected with a duodeno-ileal anastomosis. The patient was discharged on post-op day 5 on a liquid diet and is doing well on a 2-month follow-up.

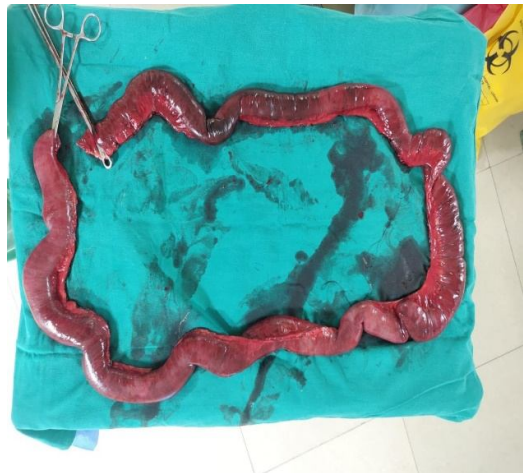

**Figure 1** CT scan of the patient showing a right paraduodenal hernia with a well-formed peritoneal sac (arrow) with the non-enhancing and dilated small bowel loops as content.

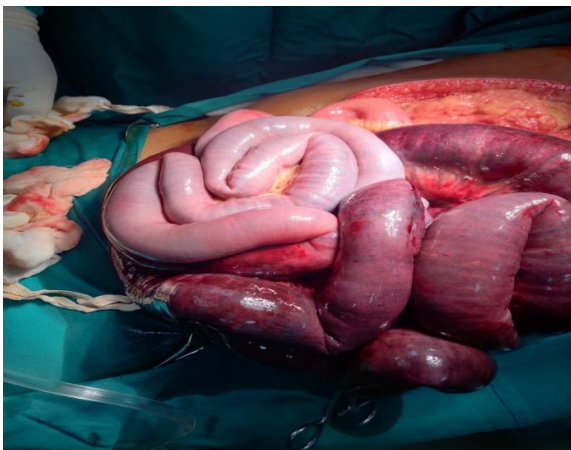**Figure 1** The peritoneal cavity with the bowel loops seen herniating through the fossa of waldeyer.



*Figure 3 Zone of vascular transition seen at proximal jejunum*



*Figure 4. Long segment Small Bowel resection*



## **Discussion**

“Internal hernia is the protrusion of the viscus through an intra-abdominal aperture without traversing fascial planes, majority occurring between the 4<sup>th</sup> and 5<sup>th</sup> decades of life, with a mortality of 31 to 50 %, which is significantly higher in patients with another concomitant abdominal disease”. [5] Plain abdominal radiography films of these patients may reveal a distended, fluid filled stomach or dilated small bowel loops in an ovoid mass lateral to the midline- “the classical empty abdominal sign”. [3,4,6]

CECT scan of the abdomen is the gold standard imaging modality for diagnosing paraduodenal hernia, with a sensitivity of 94% and accuracy of 90-95%. [7] It can help avoid a fatal complication which may occur by means of a percutaneous biopsy, especially in patients with a lean build wherein the hernia may resemble an intra-peritoneal mass. [3] “It shows clustering of small bowel in the left upper quadrant with mass effect on the posterior stomach and transverse colon, and inferomedial displacement of the duodenojejunal junction in case of a left hernia, or in the right upper quadrant with displacement of the descending duodenum superiorly and the transverse and ascending mesocolon anteriorly, where the jejunal arterial branches may course superior and posterior to the SMA”. [1,8]

The acquired internal hernias are most commonly seen following rearrangement of the intra-abdominal structures following surgeries like, bowel resection and anastomosis, hepaticojejunostomy or most notably after Roux-en-Y gastric bypass. Congenital hernia has a delayed presentation, with mortality mostly arising from the septic complications arising from bowel ischemia. [1]

“Left paraduodenal hernia occurs into the Landzert fossa, which is typically obliterated during the 5th to 10th weeks of gestation as the left colonic mesentery, inferior mesenteric vein (IMV), and ascending left colic artery fuse with the retroperitoneum while the small bowel is simultaneously undergoing its 270-degree counter clockwise rotation around the superior mesenteric artery (SMA). These patients present with a history of negative workups for postprandial abdominal discomfort. They carry a 50 % lifetime risk of becoming obstructed or strangulated”. [3,7] “A right paraduodenal hernia occurs due to abnormality in the second stage of embryonic midgut rotation into the Waldeyer fossa, which is typically obliterated as the SMA and right colon mesentery fuse with the retroperitoneum after passing over the third portion of the duodenum during the third stage of intestinal rotation”. [1,7-10] Another form is the middle mesocolic hernia, an even rarer entity, where the bowel loops herniate through the fossa mesocolica within the transverse mesocolon. [5]

Nearly ¾ of the patients diagnosed with a paraduodenal hernia undergo surgery in the emergent setting. Early surgical intervention is advised with reduction of the contents with or without excision of the hernia sac and closure of the defect with non-absorbable interrupted sutures, staying away from the vessels that form the walls of the hernia. An incidental diagnosis of a paraduodenal hernia, made on diagnostic laparoscopy with suspicion for another cause of acute abdomen, should not be ignored or deferred for repair at a later date. As this may increase the chances of the hernia becoming obstructed. It has been observed that laparoscopic repair has better outcome when compared to open repair, in terms of length of hospital stay, post-operative pain, earlier return to work. [4] Considering the chronic, intermittent history of these hernias, there are usually dense interbowel adhesions between the bowel loops, which may require adhesiolysis or bowel resection.

## Conclusion

In conclusion, paraduodenal hernia is an uncommon but significant cause of intestinal obstruction which requires early surgical intervention, with preference give to minimally invasive methods and if diagnosed late can be a fatal problem.

## Funding

- The authors did not receive support from any organization for the submitted work.
- No funding was received to assist with the preparation of this manuscript.
- No funding was received for conducting this study.
- No funds, grants, or other support was received

**Consent:** written informed consent was obtained from the patient.

## Ethical Approval:

As per international standard or university standard written ethical approval has been collected and preserved by the author(s).

## Conflicts of Interest

- The authors have no relevant financial or non-financial interests to disclose.
- The authors have no conflicts of interest to declare that are relevant to the content of this article.
- All authors certify that they have no affiliations with or involvement in any organization or entity with any financial interest or non-financial interest in the subject matter or materials discussed in this manuscript.
- The authors have no financial or proprietary interests in any material discussed in this article.

## References

1. Shackelford, R. and Zuidema, G., 2019. Surgery Of The Alimentary Tract. 8th ed. pp.858-863.
2. Mehra R, Pujahari AK. Right paraduodenal hernia: report of two cases and review of literature. Gastroenterology report. 2016 May 1;4(2):168-71.
3. Hassani KI, Aggouri Y, Toughrai I, Mazaz K. Left paraduodenal hernia: a rare cause of acute abdomen. The Pan African Medical Journal. 2014;17.
4. John M, Michael H, Matthew S, Anthony U, David D, Pablo G, Christopher E. Identification and repair of left-sided paraduodenal hernia using both laparoscopic and robotic techniques. Case Reports in Surgery. 2020 Feb 5;2020.
5. Schizas D, Apostolou K, Krivan S, Kanavidis P, Katsaros I, Vailas M, Koutelidakis I, Chatzimavroudis G, Pikoulis E. Paraduodenal hernias: a systematic review of the literature. Hernia. 2019 Dec;23(6):1187-97.
6. Kuzinkovas V, Haghighi K, Singhal R, Andrews NJ. Paraduodenal hernia: a rare cause of abdominal pain. Canadian Journal of Surgery. 2008 Dec;51(6):E127.
7. Bollampally AR, Dhanapal B, Mohammed FH. Right Paraduodenal Hernia: A Rare Cause of Small Bowel Strangulation. Cureus. 2020 Nov 30;12(11).

8. Joseph AM, Huynh D, Chaipis P. Right Paraduodenal Hernia. *Federal Practitioner*. 2017 Aug;34(8):33.
9. Shadhu K, Ramlagun D, Ping X. Para-duodenal hernia: a report of five cases and review of literature. *BMC surgery*. 2018 Dec;18(1):1-7.
10. Dayananda L, Sreekumar KP, Moorthy S, Prabhu NK. Para duodenal hernias-a pictorial essay. *Indian Journal of Radiology and Imaging*. 2006 Oct 1;16(4):469.