

# RECCURENT TEMPOROMANDIBULAR JOINT DISLOCATION: MANAGEMENT BY DAUTERY PROCEDURE – REPORT OF A CASE

## ABSTRACT

Temporomandibular joint (TMJ) dislocation is considered as any involuntary excessive movement of the mandible to the extent that the condyle gets locked in front of articular eminence resulting in inability to close the mouth. Literature review shows that numerous management options are available to treat TMJ dislocation ranging from conservative to open surgical and arthroscopic interventions. Even though advanced methods like arthroplastic eminoplasty are practised, Dautrey's procedure still remains as one of the most accepted modalities. In this case report a case of recurrent TMJ dislocation treated by Dautrey's procedure is presented.

Key words: Dautrey's, TMJ, dislocation, management

## INTRODUCTION

The functional position of TMJ is within the glenoid fossa which is a ginglymo diarthroidal joint. Articular eminence limits the forward movement of TMJ. TMJ dislocation occurs when the condylar head of the jaw moves forward, out of its forementioned anatomical position. Capsule is the pivotal structure which limits the movement of TMJ. Lateral ligaments support the capsule in this function. Iatrogenic, traumatic, systemic, anatomic or pathologic factors can alter this functional position and cause TMJ dislocation. Incidence of mandibular dislocation is only 3%, and recurrent dislocation is even more uncommon, which is a very distressing condition<sup>1</sup>. TMJ dislocation is characterized by difficulty to close the mouth, drooling of saliva and intense stretching of the ligaments and muscles, provoking intense local orofacial pain<sup>2</sup>. It can be either acute or chronic (recurrent). By contrast, recurrent TMJ dislocation has a much more complicated etiology and a much greater impact on overall quality of life. The surgical methods which have been used in literature either facilitate the unhindered forward and backward movement of condyle around articular eminence or obstruct the condylar movement ahead of the articular eminence<sup>3</sup>. In this case report we discuss a case of recurrent TMJ dislocation treated by Dautrey's procedure is discussed.

## CASE REPORT

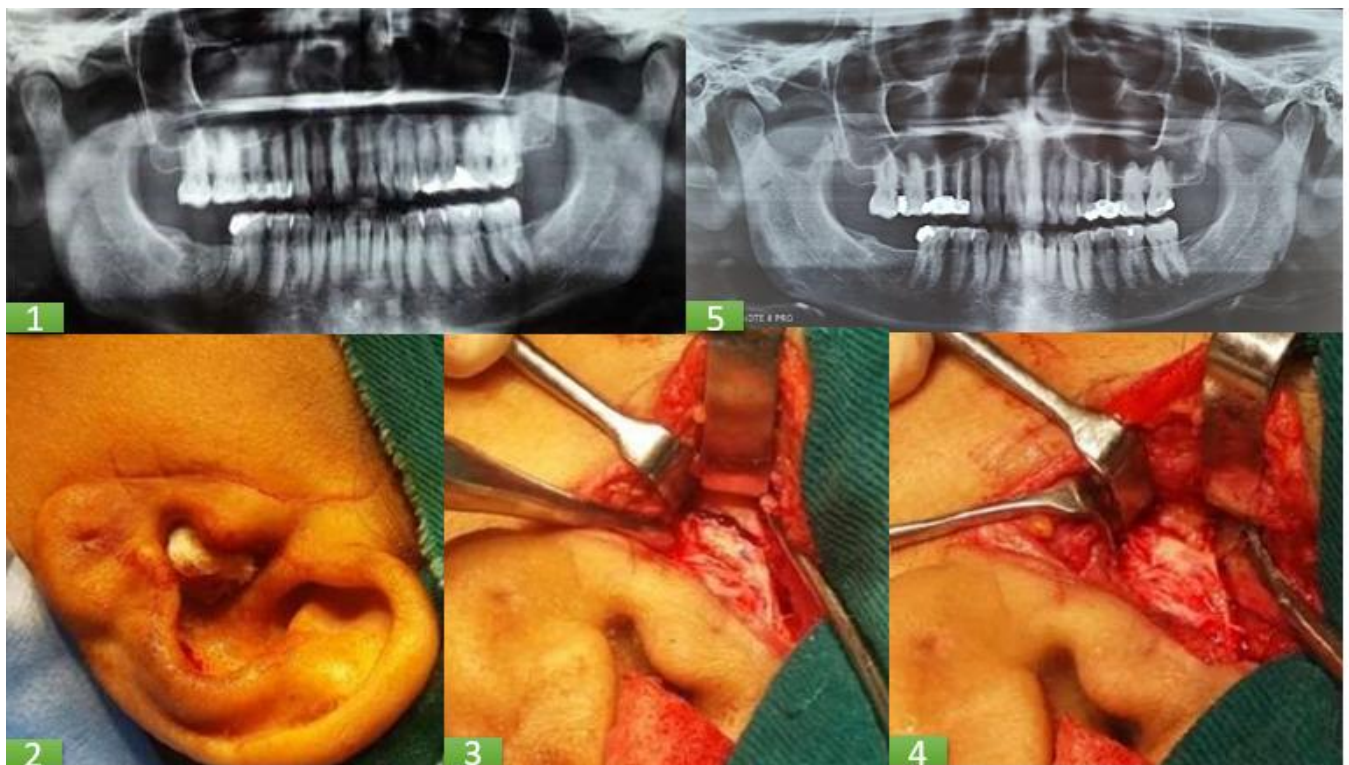
A 43 year old female patient reported to our OPD with chief complaint of repeated TMJ dislocation of 4 years duration. The patient gave a history of numerous manual reduction in the previous occasions. With each successive dislocation, further episodes occurred more frequently. Medical, dental, family and personal history were non-contributory. On general examination all of other systems appeared normal. On local examination she showed tenderness of the TMJ bilaterally, pain while opening the mouth,

restricted mouth opening ( 2 finger breadth) , clicking sound on the right and left TMJ.OPG and CT scan were taken and it showed the evidence of TMJ dislocation (Fig.1)

Dautery procedure was planned under general anaesthesia .

### **SURGICAL PROCEDURE**

Under general anaesthesia Pre auricular incision was given on the right side. The dissection was continued until the articular eminence with TMJ was fully exposed. The zygomatic arch was given an oblique cut using osteotome in a downward and forward direction. The arch was sprung first laterally very slowly and then downwards by controlled pressure with a nasal septal osteotome to prevent its complete fracture.This created a mechanical obstruction limiting the mandibular movements(Fig 2 to 4).The procedure was repeated on the opposite side.Mouth opening was found to be limited upon forceful opening after surgery.Post-operative intermaxillary fixation (IMF) was placed for one week.Patient was instructed not to open the mouth,IMF was changed to elastics for three weeks post-operatively.A post-operative OPG was taken after two days (Fig5).The patient is on frequent follow up for the last 4 years with no evidence of dislocation



**Fig 1. PRE-OP OPG WITH MOUTH CLOSED**

**Fig 2. INTRA-OP-INCISION MARKED ON LEFT SIDE**

**Fig 3. OBLIQUE OSTEOTOMY OF LEFT ZYGOMA ARCH**

**Fig 4. CREATION OF A MECHANICAL OBSTACLE**

## FIG 5. POST OP OPG

### DISCUSSION

#### Etiopathogenesis

Occlusal stability, joint stability and orthopedic stability holds the TMJ in the functional position. Iatrogenic, traumatic, systemic, anatomic or pathologic factors can alter this stable position. Arthritic changes in the condyle like flattening or narrowing, decrease in the height of the articular eminence, morphological changes of the glenoid fossa are the most common pathologic reason for TMJ dislocation<sup>4,5</sup>. Losing the elasticity of articular disc and ligaments especially lateral ligaments which can occur due to iatrogenic causes ( lengthy oral procedures, endotracheal intubation) and trauma also leads to TMJ dislocation<sup>6,7,8,9,10</sup>. Age changes and alteration in the dentition also play definite role in dislocation<sup>11</sup>. Patients with Syndromic diseases like Ehlers-Danlos Syndrome, orofacial dystonia, and the Marfan syndrome may also develop recurrent TMJ dislocation<sup>12,13</sup>. Certain antipsychotic medications also precipitate this condition.

#### Classification

Based on location of dislocation it can be anterior, medial, lateral or posterior<sup>14,15</sup>. Anterior dislocation is the most common one where as posterior one is very rare. It can be partial (subluxation) or complete (luxation) based on extent. Based on duration it can be acute, chronic protracted or chronic recurrent. Both unilateral and bilateral cases are reported<sup>5,16,17</sup>. Based on radiological features it is grouped in to 3 by Akinbami<sup>16</sup>:

Type I - the head of the condyle is directly below the tip of the eminence

Type II - the head of the condyle is in front of the tip of the eminence

Type III - the head of the condyle is high-up in front of the base of the eminence.

#### Clinical features

TMJ dislocation is characterized by difficulty to close the mouth, drooling of saliva and intense stretching of the ligaments and muscles, provoking intense local orofacial pain<sup>1</sup>.

#### Management

Management of TMJ dislocation depends mainly on the type of dislocation.

##### 1 ) Acute

This condition is often painful and is managed by manual reduction. Hippocrates stated that pressing the mandible downward, then backward, and finally upward direction helps in reducing the dislocation. Lewis explained that the clinician should stand in front of patient or at 11 o' clock position. Then, the

thumb should be pressed down on the occlusal surface of the lower molar teeth. The chin should be elevated with the fingers concomitantly and the entire mandible should be pushed posteriorly<sup>17</sup>. Usually spasm of lateral pterygoid may complicate the management as the spastic muscles induce severe pain and hence reduction should always be performed by giving auriculotemporal nerve block or local infiltration in the joint space or under moderate sedation<sup>19</sup>. According to certain authors instead of placing thumb in the occlusal surface it can be changed to the anterior border of the ramus<sup>20</sup>. Awang reported that, inducing a gag reflex by irritating the soft palate creates a reflex neuromuscular action can help in manual reduction<sup>21</sup>.

## 2) Chronic dislocation

It can be chronic recurrent dislocation or subluxation and long standing chronic dislocation.

### Conservative management (for Subluxation)

Injecting sclerosing agents like alcohol, sodium tetradecyl sulfate, sodium psylliate, morrhuate sodium, and platelet-rich plasma into the joint space are some of the well-known technique of conservative management<sup>22</sup>. Jacobi hermanns E et al stated that(1981) Injecting autologous blood restrict mandibular movements by inducing fibrosis in the upper joint space and the pericapsular tissues<sup>23</sup>. About 2 mL of blood in the upper joint space and 1m L in the pericapsular structures can be injected twice a week for 3 weeks<sup>24</sup>. Restriction of the mandibular movement with a head bandage for a period of 3-4 weeks further aids in enhancing fibrosis<sup>25</sup>. Injection of botulinum toxin A (BTX-A) in the lateral pterygoid muscle causes temporary weakening of the skeletal muscle by blocking the Ca<sup>2+</sup>-mediated release of acetylcholine from the nerve endings of the neuromuscular junction and aids in preventing TMJ dislocation. Repeated administration is required after 2 weeks for promising results<sup>26</sup>.

### Long standing chronic dislocation

When the conservative management fails to achieve promising results surgical options are necessary. The surgical procedures can be categorized under 2 main headings :1) Procedures that enhance the path of condylar movement ;and 2) Those that inhibit the path of condylar movement<sup>27</sup>.

#### 1) Procedures that enhance the path of condylar movement

Condylotomy, condylectomy , eminectomy, eminoplasty are the other procedures which enhance the path for condylar movement. Arthroplastic eminoplasty involves safely scarring the articular eminence without markedly altering the bony anatomy to allow the condyle to move freely back into its normal position and prevent dislocation.The technique employs a specially designed diamond rasp to minimize bone reduction, and has the advantage of avoiding down-fracturing of the eminence. In studies, eminoplasty has been shown to produce clinical outcomes as effective as those obtained with the use of conventional open eminectomy<sup>28</sup>. Myotomy with resection of the insertion of the lateral pterygoid muscle limits the mandibular translation and allows only rotational movement of the condyle. This procedure had been described by Bowman in 1949.eTemporalis myotomy can be performed instead of lateral pterygoid which was described by Laskin <sup>29</sup>.

## 2) Those that inhibit the path of condylar movement

Capsulorrhaphy is a procedure of shortening the capsule by removing a section and suturing it to make it tight. This limits the condylar movement. LeClerc and Girard proposed a vertical osteotomy of the zygomatic arch which is performed in front of the joint and the proximal segment lowered to obstruct the condylar path. Gosserez and Dautrey advocated a downward and forward osteotomy on the zygomatic arch and depressing it in front of the condylar head to serve as an obstacle to abnormal forward translation<sup>30</sup>. Dautrey's procedure is a very well accepted procedure and reports only about one percent of failures.

## CONCLUSION

A case of recurrent dislocation of temporomandibular joint is presented. Etiopathogenesis of TMJ dislocation and various management options are discussed. Dautrey procedure was performed to successfully manage the case and the patient was under regular follow up for the last four years.

## REFERENCES

1. Merrill, Ralph G. Mandibular dislocation in surgery of the temporomandibular joint. 2nd ed. Keith, DA, editor. Blackwell Scientific Publications; 1992. p. 154-179.
2. Da Costa Ribeiro, R., dos Santos, B. J., Provenzano, N., & de Freitas, P. H. L. (2014). Dautrey's procedure: an alternative for the treatment of recurrent mandibular dislocation in patients with pneumatization of the articular eminence. *International Journal of Oral and Maxillofacial Surgery*, 43(4), 465–469.
3. Bhandari SK, Issar Y, Sambyal SS, Kumar AN. Management of temporomandibular joint recurrent dislocation using Dautrey's procedure: report and review. *Int J Otorhinolaryngol Head Neck Surg* 2019;5:1748-52
4. Güven O. Inappropriate treatments in temporomandibular joint chronic recurrent dislocation: A literature review presenting three particular cases. *J Craniofac Surg*. 2005;16:449–52.
5. Vasconcelos BC, Porto GG, Neto JP, Vasconcelos CF. Treatment of chronic mandibular dislocations by eminectomy: Follow-up of 10 cases and literature review. *Med Oral Patol Oral Cir Bucal*. 2009;14:e593–6.
6. Bhandari S, Swain M, Dewoolkar LV. Temporomandibular joint dislocation after laryngeal mask airway insertion. *The Internet J of Anaesth*. 2008;16:1–4.
7. Lipp M, Von Domarus H, Daublender M. Temporomandibular joint dysfunction after endotracheal intubation. *Anaesthetisa*. 1987;36:442–5.
8. Rastogi Nk, Vakharia N, Hung OR. Perioperative anterior dislocation of the temporomandibular joint. *Anesth Analg*. 1997;84:924–6.
9. Rosemore J, Nikoomanesh P, Lacy BE. Bilateral temporomandibular joint dislocation after PEG tube placement. *Gastrointest Endosc*. 2004;59:146–7.

10. Kepron W. Bilateral dislocations of the temporomandibular joint complicating fiberoptic bronchoscopy. *Chest*. 1986;90:465.
11. Medra AM, Mahrous AM. Glenotemporal osteotomy and bone grafting in the management of chronic recurrent dislocation and hypermobility of the temporomandibular joint. *Br J Oral Maxillofac Surg*. 2008;46:119–22.
12. Bauss O, Sadat-Khonsari R, Fenske C, Engelke W, Schwestka-Polly R. Temporomandibular joint dysfunction in Marfan syndrome. *Oral Surg Oral Med Oral Pathol Oral Radiol Endod*. 2004;97:592–8.
13. Thexton A. A case of Ehlers-Danlos syndrome presenting with recurrent dislocation of the temporomandibular joint. *Br J Oral Surg*. 1965;3:190–3.
14. Hoard MA, Tadge JP, Gampper TJ, Edlich RF. Traumatic chronic TMJ dislocation: Report of an unusual case and discussion of management. *J Craniomaxillofac Trauma*. 1998;4:44–7.
15. Harstall R, Gratz KW, Zwahlen RA. Mandibular condyle dislocation into the middle cranial fossa: A case report and review of literature. *J Trauma*. 2005;59:1495–503.
16. Landes CA, Lipphardt R. Prospective evaluation of a pragmatic treatment rationale: Open reduction and internal fixation of displaced and dislocated condyle and condylar head fractures and closed reduction of non-displaced, non-dislocated fractures. Part I: Condyle and sub condylar fractures. *Int J Oral Maxillofac Surg*. 2005;34:859–70.
17. Caminiti MF, Weinberg S. Chronic mandibular dislocation: The role of non-surgical and surgical treatment. *J Can Dent Assoc*. 1998;64:484–91.
18. Akinbami BO. Evaluation of the mechanism and principles of management of temporomandibular joint dislocation. Systematic review of literature and a proposed new classification of temporomandibular joint dislocation. *Head Face Med*. 2011;7:10.
19. StakesbyLewis JE. A simple technique for reduction of long-standing dislocation of the mandible. *Br J Oral Surg*. 1981;19:52–6.
20. Howe GL. 3rd ed. Wright: Bristol; 1985. *Minor Oral Surgery*; pp. 393–5.
21. Awang MN. A new approach to the reduction of acute dislocation of the temporomandibular joint: A report of three cases. *Br J Oral Maxillofac Surg*. 1987;25:244–9.
22. Brachmann F. Eigenblutinjektionen beirezidivierenden, nichtfixierten Kiefergelenkluxationen. *Zahnarztl*. 1964;15:97.
23. Gulses A, Bayar GR, Aydintug YS, Sencimen M, Erdogan E, Agaoglu R. Histological evaluation of the changes in temporomandibular joint capsule and retrodiscal ligament following autologous blood injection. *J Craniomaxillofac Surg*. 2013;41:316–20.
24. Jacobi-Hermanns E, Tetsch P. Pericapsular autologous blood injection as therapy for habitual temporomandibular joint luxation. *Dtsch Zahnarztl Z*. 1981;36:187–90.
25. Schulz S. Evaluation of periarticular autotransfusion for therapy of recurrent dislocations of the temporomandibular joint. *Dtsch Stomatol*. 1973;23:94–8.
26. Martínez-Pérez D, García Ruiz-Espiga P. Recurrent temporomandibular joint dislocation treated with botulinum toxin: Report of 3 cases. *J Oral Maxillofac Surg*. 2004;62:244–6.

27. Gadre KS, Kaul D, Ramanojam S, Shah S. Dautrey's procedure in treatment of recurrent dislocation of the mandible. *Journal of oral and maxillofacial surgery*. 2010 Aug 1;68(8):2021-4.
28. Sato, et al. *Oral Surg Oral Med Oral Pathol Oral Radiol Endod* 2003;95:390-395
29. Laskin DM. Myotomy for the management of recurrent and protracted mandibular dislocations. In *Transactions of the International Conference on Oral Surgery* 1973 Jan 1 (Vol. 4, pp. 264-268).
30. Baptist J, Baliga M. Dautrey's Procedure Revisited in Management of Recurrent Mandibular Dislocation. *J Contemp Dent Pract* 2017;18(1):78-79.