

## Case study

# SPONTANEOUS PNEUMOMEDIASTINUM AN ELUSIVE CONDITION FOR SURGEONS

## ABSTRACT

Pneumomediastinum is defined as the presence of free air in the mediastinum. It may appear sinister to some surgeons and any medical practitioner because it can be fatal if the underlying cause and complications are not addressed. Other possible causes must be investigated and identified, as secondary pneumomediastinum can have disastrous consequences if not treated. On the other hand, spontaneous pneumomediastinum is usually harmless and is treated conservatively most of the time. We present a case of spontaneous pneumomediastinum in a 15-year-old teenager who was admitted for bronchial asthma exacerbation and presented with shortness of breath, chest tightness, and wheezing.

## INTRODUCTION

Pneumomediastinum, also known as mediastinal emphysema, is the presence of free air in the mediastinum. It is further classified into two types: spontaneous pneumomediastinum (SPM), which has no evident main cause, and secondary pneumomediastinum (SPM), which has a particular causative pathologic event, such as trauma, intrathoracic infections, or aerodigestive tract violation. [1]. SPM is a benign, self-limiting illness that mostly affects young guys. [2] Its prevalence varied from 1:7000 to 1:45000 hospital admissions and was more common in men in their second to fourth decades of life. [2,3].

Macklin et al. described pathophysiology in 1939. A rapid rise in intra-alveolar pressure may result in alveolar rupture with air dissection down the interstitial sheaths into the mediastinum, resulting in pneumomediastinum, or it can reach the lung periphery, resulting in subpleural bullae (ruptured bullae may also cause pneumothorax). [6]

Potential causes include pre-existing conditions that favour or facilitate pneumomediastinum, such as asthma, lung diseases, tobacco, inhaled drug use, corticosteroid and irritant inhalation, and events closely linked to the development of the condition, such as emesis, cough, asthma exacerbation, defecation, physical exercise, and so on[2,3].

The medical profession regards pneumomediastinum as a warning indication with potentially fatal consequences. However, after secondary reasons such as esophageal perforation, spasm, or reflux are ruled out, SPM should be explored, and therapy with a low recurrence rate is expected. [1] Spontaneous pneumomediastinum generally resolves on its own after a few days of therapy that includes identifying the underlying cause (if feasible), rest, analgesics, and clinical monitoring. [4]

This case report describes the relationship between bronchial asthma and spontaneous pneumomediastinum in a 15-year-old girl. The purpose of this case report is to educate surgeons about the characteristics of spontaneous pneumomediastinum, its probable repercussions, and asthma exacerbation as a cause of this syndrome.

## **CASE REPORT**

A 15-year-old adolescent with underlying bronchial asthma reported to the emergency room with substernal chest discomfort, shortness of breath, and a slight productive cough. For three days, his symptoms increased, culminating in wheezing the night before his presentation. He denied any recent trauma and a history of foreign body aspiration or drug addiction. Prior to this incident, he was in his customary excellent health. His last bronchial asthma episode was more than two years ago, and he is now just on PRN MDI salbutamol. His asthma is well managed, according to NAEPP guidelines.

On entry, he was tachypneic, and oxygenation was improved using an **ETD(DESCRIBE WITH WORDS)** venturi mask. Crackles may be heard throughout both lungs. After frequent nebulization, he was able to wean off oxygen support in the ward. He was afebrile, with stable vital signs and no hemodynamic assistance. The results of the laboratory tests and arterial blood tests were ordinary. Pneumomediastinum was seen on a chest scan (Figure 1). A thoracic HRCT scan corroborated similar findings, as well as the presence of little mediastinal fluid with air trapping in the bilateral upper lobe lungs (Figure 2). There was no indication of tracheal or bronchial damage on CT. The **OGDS(DESCRIBE WITH WORDS)** test showed negative for esophageal damage.

For one week, he was bedridden in the ward, with oxygen supplementation and strict monitoring. A one-week course of antibiotics was also administered, along with daily nebulization. His clinical symptoms improved day by day, and by the seventh hospital day, he had no more respiratory difficulties and was released home. His following chest x-ray indicated remission of pneumomediastinum and he remained asymptomatic.

## **DISCUSSION**

SPM was generated by the rupture of the distal alveoli as a consequence of increased intraalveolar pressure, and it extended from the lung parenchyma tissue to the mediastinum through the peribronchovascular route owing to the pressure differential of the air from this rip. [6] Spontaneous alveolar rupture occurs when there is a rise in alveolar pressure, such as coughing, vomiting, straining, or performing the valsalva manoeuvre. [5,6] More than 95% of instances of pneumomediastinum are caused by alveolar rupture, which is more common than esophageal or tracheobronchial disruptions. [7]

According to a retrospective study conducted by Patricia et al, the majority of the 18 patients with SPM (44.4%) were current smokers, 27.8% had a history of bronchial asthma, 22.2% had a history of bronchial hyperactivity (without bronchial asthma), and 11.1% had

interstitial lung disease. In terms of precipitating factors, 50% of the cases of SPM were related to bouts of cough.[2]

In a systematic review of 27 SPM studies (including 600 patients), at least one predisposing factor was identified in 22% of the cases, with bronchial asthma being the most common, followed by interstitial lung disease, COPD, bronchiectasis, bullae, thoracic neoplasm, cystic disease, and respiratory tract infection. [9] SPM has traditionally been attributed to asthma exacerbations. [5] A chronic inflammatory condition seems to limit airway lumen by increasing airway pressure. SPM may emerge at the first asthma exacerbation or later as a complication of asthma in children [Versteegh and Broeders, 1991; Bullaro and Bartoletti, 2007]. The acute exercise of asthma due to respiratory infections was thought to be the triggering cause in this instance.

When pneumomediastinum is clinically suspected, the first step in diagnosis is a posteroanterior and lateral chest radiograph. The Macklin effect has been identified on chest CT scan by seeing air dissection through perivascular and peribronchial sheaths in 89-100% of instances with spontaneous pneumomediastinum, however CT scan confirmation is not required. [7] A CT of the chest is the next diagnostic step when the underlying mechanism, which is the key to therapy, is unknown. [8] Digestive tract involvement must be ruled out since it is the most serious consequence. [3] Endoscopy should be performed if there is a history of esophageal damage or clinical signs of it, such as the typical Mackler triad of vomiting, chest discomfort, and subcutaneous emphysema. Delays in recognising esophageal damage, such as in Boerhaave's syndrome, may have disastrous implications with significant morbidity and mortality, and is lethal in the absence of treatment. If tracheal damage or rupture is suspected, fiberoptic bronchoscopy and a thoracic CT should be done. In our situation, the patient had an endoscopy to rule out esophageal damage, which came out negative.

Antibiotics were provided in some instances, although their job is mainly to treat an underlying chest infection or if there are symptoms of mediastinitis, and occasionally to prevent it. [3] In our situation, antibiotics were initiated to address underlying chest infections, using a one-week antibiotic treatment. Recurrence is normally extremely uncommon, and when it does occur, it is usually due to continued exposure to trigger factors, such as drug misuse or uncontrolled asthma. [3] In general, spontaneous pneumomediastinum is self-limiting and resolves in a few days, although the patient should be watched for the complication.

## **CONCLUSION**

Spontaneous pneumomediastinum is an uncommon condition that typically has a benign history and is treated conservatively. However, surgeons must rule out subsequent pneumomediastinum, which may be lethal if undetected or untreated. SPM patients should still be checked for complications. A simple chest x-ray is generally enough to detect this

illness. Nonetheless, if a chest radiograph is ambiguous, a thoracic CT with endoscopy and bronchoscopy is a solid technique for ruling out subsequent pneumomediastinum.

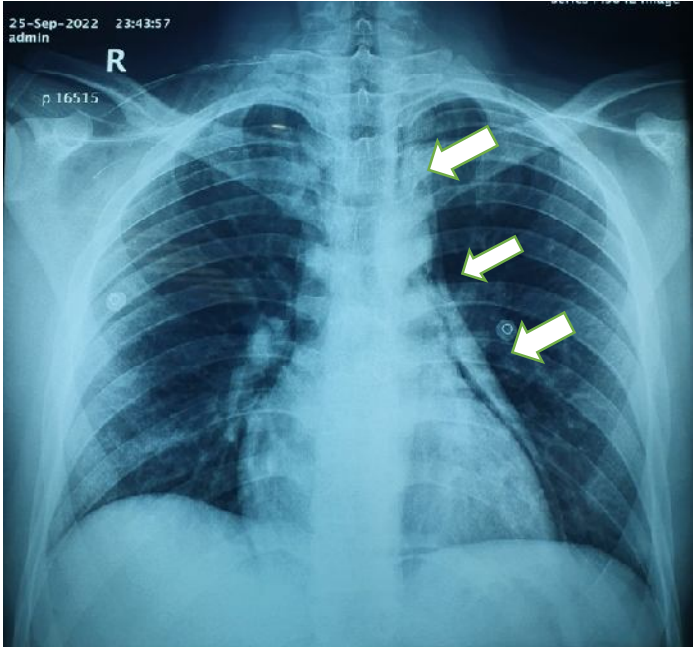


Figure 1: Chest xray showed pneumomediastinum and pneumopericardium (arrow)

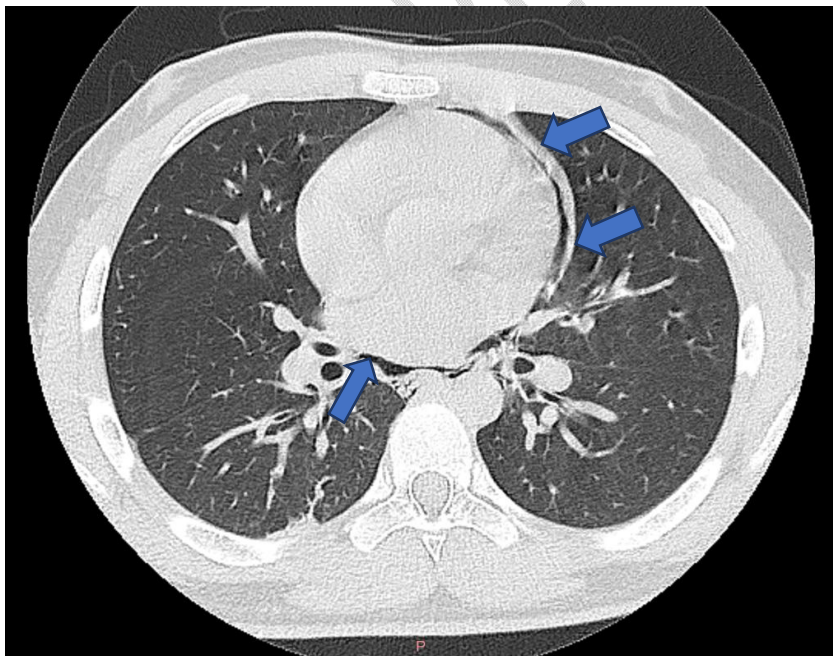


Figure 2: HRCT Thorax revealing pneumomediastinum

## References

- [1] Caceres M, Ali Sz, Braud R, Weiman D, Garrett He Jr. Spontaneous Pneumomediastinum: A Comparative Study And Review Of The Literature. *Ann Thorac Surg.* 2008 Sep;86(3):962-6. Doi: 10.1016/J.Athoracsur.2008.04.067. Pmid: 18721592.
- [2] Mondello B, Pavia R, Ruggeri P, Barone M, Barresi P, Monaco M. Spontaneous Pneumomediastinum: Experience In 18 Adult Patients. *Lung.* 2007 Jan-Feb;185(1):9-14. Doi: 10.1007/S00408-006-0002-7. Epub 2007 Feb 15. Pmid: 17310299.
- [3] José Meireles, Sara Neves, Alexandra Castro, Margarida França, Spontaneous Pneumomediastinum Revisited, *Respiratory Medicine Cme*, Volume 4, Issue 4, 2011, Pages 181-183, Issn 1755-0017
- [4] Cicak B, Verona E, Mihatov-Stefanović I, Vrsalović R. Spontaneous Pneumomediastinum In A Healthy Adolescent. *Acta Clin Croat.* 2009 Sep;48(4):461-7. Pmid: 20405645.
- [5] Tortajada-Girbés, M., Moreno-Prat, M., Ainsa-Laguna, D., & Mas, S. (2016). *Spontaneous Pneumomediastinum And Subcutaneous Emphysema As A Complication Of Asthma In Children: Case Report And Literature Review. Therapeutic Advances In Respiratory Disease, 10(5), 402–409.* Doi:10.1177/1753465816657478
- [6] Macklin Cc. Transport Of Air Along Sheaths Of Pulmonic Blood Vessels From Alveoli To Mediastinum: Clinical Implications. *Arch Intern Med (Chic).* 1939;64(5):913–926. Doi:10.1001/Archinte.1939.00190050019003
- [7] Chassagnon G, Favelle O, Derogis V, CottierJp. Spontaneous Pneumomediastinum Due To The Macklin Effect: Less Is More. *Intern Emerg Med.* 2015 Sep;10(6):759-61. Doi: 10.1007/S11739-015-1229-1. Epub 2015 Mar 25. Pmid: 25804499.
- [8] Russell DW, Watts JR Jr, Powers TA. Searching for the Source of the Leak: PIE and the Macklin Effect. *Ann Am Thorac Soc.* 2018 Nov;15(11):1354-1356. doi: 10.1513/AnnalsATS.201803-200CC. PMID: 30382777; PMCID: PMC6322014.
- [9] Dajer-Fadel WL, Arguero-Sanchez R, Ibarra-Perez C, Navarro-Reynoso FP. Systematic review of spontaneous pneumomediastinum: a survey of 22 years data. *Asian CardiovascThorac Ann.* 2014 Oct; 22(8): 997-1002.