

Role of laparoscopic loop sigmoid colostomy in a case of Fournier's gangrene with parietal wall abscess and complex perineopelvic fistula causing pelvic sepsis

ABSTRACT

Background

Fournier's gangrene is a rapidly progressive necrotizing fasciitis of scrotum and perineal region. The cornerstone of treatment is early detection, aggressive surgical debridement along with complete drainage of abscess and also optimal medical management.

Methods

This patient with Fournier's gangrene who underwent emergency surgical debridement and abscess drainage, followed by **serial debridements** in our institution had an unusual presentation. Because of constant fecal contamination of the wound along with development of multiple fistulous tract communicating to anterior abdominal wall and pelvis, there was ascending infection leading to pelvic sepsis and parietal wall abscess. Hence MR Fistulogram and Pelvis was recommended. The patient was successfully managed by Laparoscopic loop sigmoid for control of sepsis and faster recovery. In this patient, Laparoscopic mobilization and exteriorization of the sigmoid loop through widening the left utility port incision was found to be simple and easily reproducible technique in creating loop sigmoid colostomy. The operative time for our case was 65 minutes, making it feasible even for the surgeon without extensive laparoscopy experience.

Results

Postoperatively patient had a faster recovery, wound infection settled and secondary suturing of the wound was done. Patient was discharged for later colostomy reversal.

Conclusion

In our experience we found that patient with Fournier gangrene and complex perineal wound causing pelvic sepsis can be managed with laparoscopic fecal diversion for sepsis control and faster wound recovery

Keywords: Fournier's Gangrene; Complex Perineal Wound; Perineopelvic Fistula; Pelvic Abscess; Laparoscopic Loop Sigmoid Colostomy

1. INTRODUCTION

Fournier's gangrene is rare life-threatening soft tissue infection the scrotum and perineal region. Rarely Fournier's gangrene directly invade into the pelvis from the more superficial fascial levels along interfascial planes, however if it does it is even more difficult to manage(1). We present a case of Fournier's gangrene with perineopelvic fistula causing pelvic sepsis, which was successively treated in our department.

2. CASE REPORT

A 66 year old male patient with k/c/o uncontrolled DM presented with complaints of scrotal swelling with discoloration scrotal skin and pain since 2 days. On evaluation the patient's vitals were stable local examination revealed 15x10cm scrotal swelling, scrotal skin was edematous with areas of scrotal skin necrosis and foul smelling discharge was present. Hence patient was diagnosed to have Fournier's gangrene and was taken for emergency incision and drainage/debridement under spinal anesthesia. Intraoperative pus was drained, thorough debridement was done. Both the testes were found to be uninvolved and healthy. However, there was significant loss of scrotal skin and both the testes were exposed[Figure: 1]. Pus was sent for culture and sensitivity.

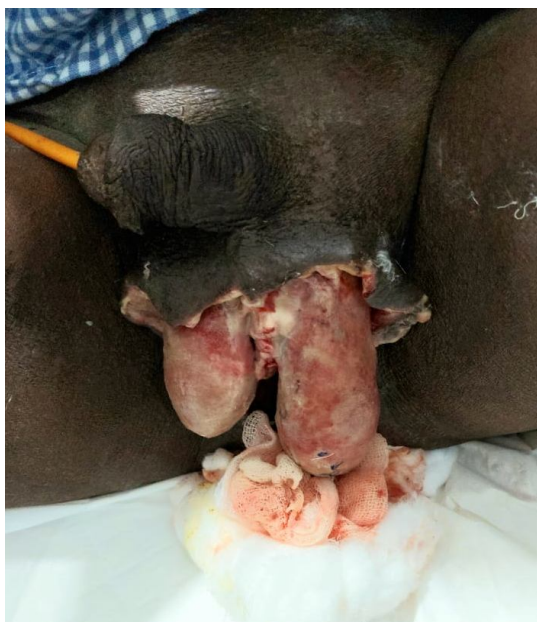

Figure 1: Post debridement status of the patient, exposed testes with significant scrotal skin loss

Patient's general condition improved. Lab parameters were on improving trend (wbc counts 13000, LFT/RFT WNL). However there was persistent pus discharge form the wound. We continued serial debridement/dressing under local anesthesia for 4 days. But there was no significant improvement, on POD 5 we found that left testis was enlarged and gangrenous with significant pus discharge from the inguinal region. Hence patient was taken up for inguinal exploration with left orchiectomy. Intraoperative there was frank pus in the inguinal canal which was extending into the subrectus plane and the pelvic cavity. Spermatic cord was also found to be sloughed out and gangrenous. Left orchiectomy and thorough drainage of the abscess was done. Corrugated drain as kept inguinal wound was closed [Figure-2]

Post operatively there was persistent pus discharge with fecal staining in the inguinal wound hence patient was taken up for re-exploration. Inguinal sutures was removed pus was drained. There was communication between the dissected superficial perineal wound and anterior abdominal wall through the ischiorectalfossa behind the pubic bone was noted. Hence patient was planned for MRI pelvis and fistulogram. MRI showed there is linear fistulous tract noted in right inner gluteal region with external opening at 9'0 clock position and extending superiorly along perianal region, anteriorly with extension of tract into pelvic cavity along left periurethral and periprostatic region which is extending along the left iliac region to left inguinal region at post operative site.

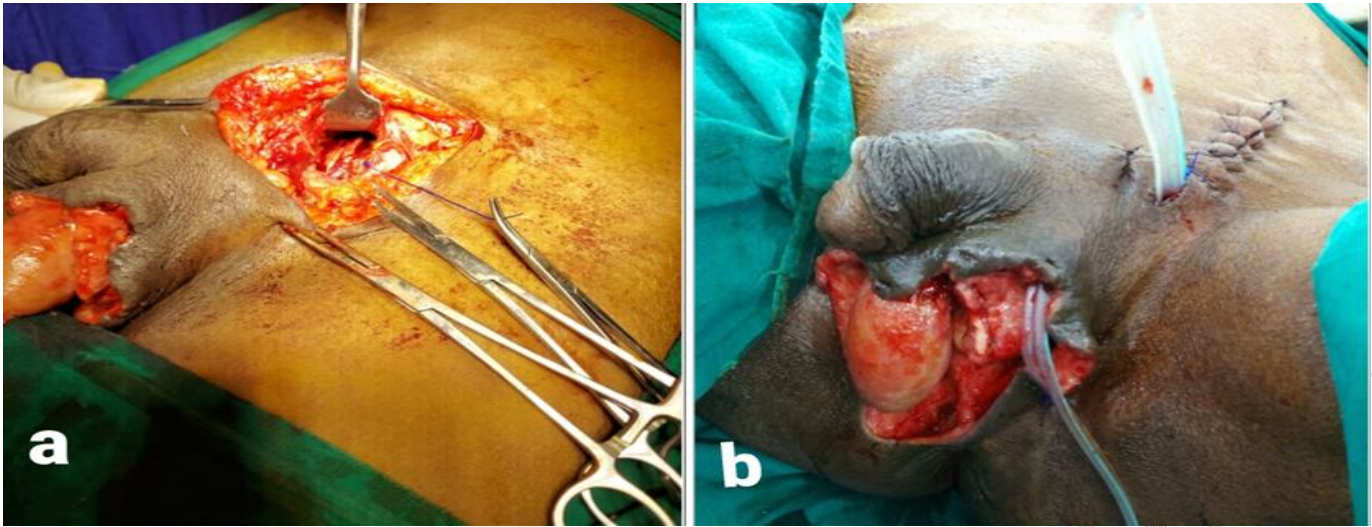


Figure 2: a] Intraoperative picture showing the abscess extending into the sub rectus plane of the anterior abdominal wall. b] Post orchiectomy status, abscess drainage and wound was closed with corrugated drain in situ

In view of complex perineal wound with fistulous tract extending into the pelvis and parietal wall patient was planned for fecal diversion for control of pelvic sepsis. Hence patient was taken up for Laparoscopic sigmoid loop colostomy [Figure:3]. Post operatively pus discharge settled, inguinal wound secondary suturing done and Right testes was covered with residual scrotal skin itself. Patient was discharged for follow up [Figure:4]

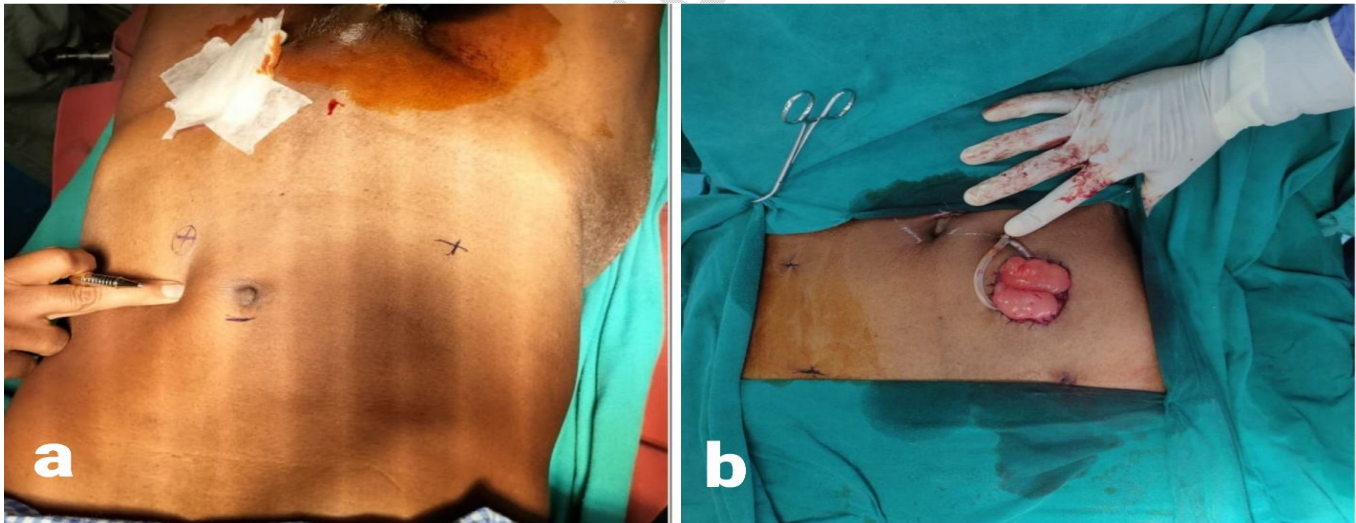


Figure 3: a] Pre procedure Laparoscopic port site marking for sigmoid loop colostomy. b] Post laparoscopic loop sigmoid colostomy status

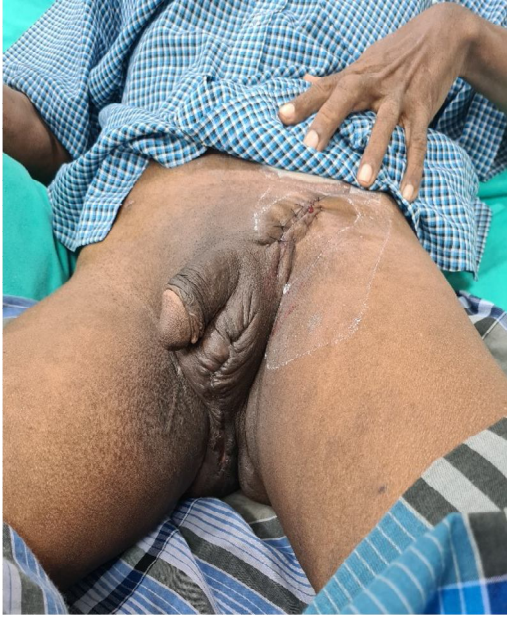

Figure 4: Post-secondary suturing and healed scrotal and inguinal wound

3. DISCUSSION

In this patient due to constant fecal contamination of the wound along with persistence of multiple fistulous tract even after complete debridement and abscess drainage, there was ascending infection leading to pelvic sepsis and parietal wall abscess. Testes and spermatic cords are generally not affected by this disease, because they are supplied by the testicular artery. However, this patient underwent left orchiectomy because of severe infection in the peritesticular tissues and spermatic cord leading to gangrenous left testes. Some studies also reported similar findings(2). Hence high clinical suspicion and early detection of fistulous communication, extent of infectious process and path of spread by CT/MRI is recommended(3). And this subset of patients should be managed with TPN or colostomy for preventing fecal contamination of the wound and faster recovery. Chennamsetty et al. recommended that anal sphincter involvement, fecal incontinence and continued fecal contamination of wound margins be viewed as indications for colostomy (4). However in our experience in patients with Fournier's gangrene TPN was proved to be ineffective in patient's with complex perineal wound and multiple ano-rectal fistulous tract. Since TPN also had a risk of reducing immunological competence we performed a colostomy. Early fecal diversion in addition to adequate antibiotic therapy resulted in fast recovery from sepsis and an improved overall outcome(5,6). In this patient, Laparoscopic mobilization of the large bowel, demonstration of proximal and distal loop, exteriorization of the bowel loop through widening the left utility port incision was found to be simple and easily reproducible technique in creating loop sigmoid colostomy. Previous evidence reported the usefulness of Laparoscopic sigmoid colostomy in various patients requiring fecal diversion(7). The operative time for our case was 65 minutes, making it feasible even for the surgeon without extensive laparoscopy experience, and was comparable to that reported in another study(8).

4. CONCLUSION

In our experience we found that patient with Fournier gangrene and complex perineal wound with multiple fistulous tract extending into the pelvic cavity and parietal wall causing sepsis can be managed with laparoscopic fecal diversion for sepsis control and faster wound recovery. Because Fournier's gangrene is vulnerable to fecal contamination, we recommend performing colostomy during initial debridement if there is any doubt regarding possible fecal contamination. Which can be accomplished safely by laparoscopic technique.

CONSENT

Patients signed informed consent regarding publishing their data and photographs.

ETHICAL APPROVAL

No ethical approval is required in accordance with the ethical standards of our institution.

REFERENCES

1. Jayatunga A, Caplan S, Paes T. Survival after retroperitoneal necrotizing fasciitis. *British J Surg.* 1993; 80(8):981-981. <https://doi.org/10.1002/bjs.1800800813>.
2. Yanar H, Taviloglu K, Ertekin C, et al. Fournier's gangrene: risk factors and strategies for management. *World J Surg.* 2006;30(9):1750-54.

3. Avery L, Scheinfeld MH. Imaging of penile and scrotal emergencies. *RadioGraphics*. 2013; 33:721. <https://doi.org/10.1148/rg.333125158>.
4. Chennamsetty A, Khourdaji I, Burks F, Killinger KA. Contemporary diagnosis and management of Fournier's gangrene. *Therapeutic Advances in Urology*. 2015;7(4):203–15.
5. A. Akcan, E. Sozuer, H. Akyildiz, N. Yilmaz, C. Kucuk, E. Ok. Necessity of preventive colostomy for Fournier's gangrene of anorectal region *Turkish J Trauma Emerg Surg*, 2009;15(4):342-46
6. Pini Prato A, Castagnola E, Micalizzi C, Dufour C, Avanzini S, Pio L, et al. Early diverting colostomy for perianal sepsis in children with acute leukemia. *Journal of Pediatric Surgery*. 2012;47(10):23–7.
7. Haque P, Singh N, Upadhyay S, Chaudhry N. Laparoscopic versus open sigmoid loop colostomy: A comparative study from a cohort of 62 patients requiring temporary faecal diversion at a tertiary care center in North India. *Nigerian J Surg*. 2019; 25(2):139.-45. Doi: 10.4103/njs.NJS_13_19.
8. Trejo-Ávila ME, Valenzuela-Salazar C, Betancourt-Ferreyra J, Fernández-Enríquez E, Romero-Loera S, Moreno-Portillo M. Laparoscopic versus open surgery for abdominal trauma: a case-matched study. *J Laparoendosc Adv Surg Tech*. 2017; 27:383–7. Doi: 10.1089/lap.2016.0535.