

# Role of laparoscopic loop sigmoid colostomy in a case of Fournier's gangrene with parietal wall abscess and complex perineopelvic fistula causing pelvic sepsis

## ABSTRACT

### *Background*

Fournier's gangrene is a rapidly progressive necrotizing fasciitis of scrotum and perineal region. The cornerstone of treatment is early detection, aggressive surgical debridement along with complete drainage of abscess and also optimal medical management.

### *Methods*

This patient with Fournier's gangrene who underwent emergency surgical debridement and abscess drainage, followed by serial debridement's in our institution had an unusual presentation. Because of constant fecal contamination of the wound along with development of multiple fistulous tract communicating to anterior abdominal wall and pelvis, there was ascending infection leading to pelvic sepsis and parietal wall abscess. Hence MR Fistulogram and Pelvis was recommended. The patient was successfully managed by Laparoscopic loop sigmoid for control of sepsis and faster recovery. In this patient, Laparoscopic mobilization and exteriorization of the sigmoid loop through widening the left utility port incision was found to be simple and easily reproducible technique in creating loop sigmoid colostomy. The operative time for our case was 65 minutes, making it feasible even for the surgeon without extensive laparoscopy experience.

### *Results*

Postoperatively patient had a faster recovery, wound infection settled and secondary suturing of the wound was done. Patient was discharged for later colostomy reversal.

### *Conclusion*

In our experience we found that patient with Fournier gangrene and complex perineal wound causing pelvic sepsis can be managed with laparoscopic fecal diversion for sepsis control and faster wound recovery

*Keywords: Fournier's Gangrene; Complex Perineal Wound; Perineopelvic Fistula; Pelvic Abscess; Laparoscopic Loop Sigmoid Colostomy*

## 1. INTRODUCTION

Fournier's gangrene is rare life-threatening soft tissue infection the scrotum and perineal region. Rarely Fournier's gangrene directly invade into the pelvis from the more superficial fascial levels along interfascial planes, however if it does it is even more difficult to manage[1] We present a case of Fournier's gangrene with perineopelvic fistula causing pelvic sepsis, which was successively treated in our department.

## 2. CASE REPORT

A 66 year old male patient with k/c/o uncontrolled DM presented with complaints of scrotal swelling with discoloration scrotal skin and pain since 2 days. On evaluation patients vitals were stable local examination revealed 15x10cm scrotal swelling, scrotal skin was edematous with areas of scrotal skin necrosis and foul smelling discharge was present. Hence patient was diagnosed to have Fournier's gangrene and was taken for emergency incision and drainage/debridement under spinal anesthesia. Intraoperatively pus was drained, thorough debridement was done. Both testis was found to be uninvolved and healthy. However there was significant loss of scrotal skin and both testis was exposed [Figure: 1]. Pus was sent for culture and sensitivity.

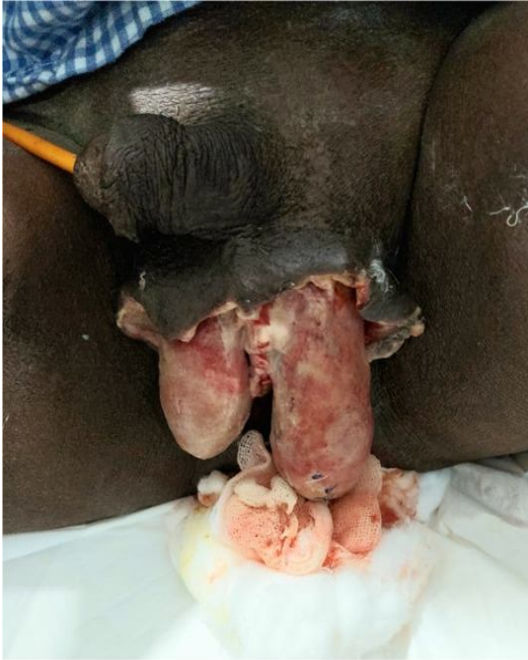

Figure 1: Post debridement status of the patient, exposed testes with significant scrotal skin loss

Patient's general condition improved. Lab parameters was on improving trend (wbc counts 13000, LFT/RFT WNL). However there was persistent pus discharge form the wound. We continued serial debridement/dressing under local anesthesia for 4 days. But there was no significant improvement, on POD 5 we found that left testis was enlarged and gangrenous with significant pus discharge from the inguinal region. Hence patient was taken up for inguinal exploration with left orchidectomy. Intraoperatively there was frank pus in the inguinal canal which was extending into the subrectus plane and the pelvic cavity. Spermatic cord was also found to be sloughed out and gangrenous. Left orchidectomy and thorough drainage of the abscess was done. Corrugated drain as kept inguinal wound was closed [Figure-2]

Post operatively there was persistent pus discharge with fecal staining in the inguinal wound hence patient was taken up for re-exploration. Inguinal sutures was removed pus was drained. There was communication between the dissected superficial perineal wound and anterior abdominal wall through the ischioirectalfossa behind the pubic bone was noted. Hence patient was planned for MRI pelvis and fistulogram. MRI showed There is linear fistulous tract noted in right inner gluteal region with external opening at 9'0 clock position and extending superiorly along perianal region, anteriorly with extension of tract into pelvic cavity along left periurethral and periprostatic region which is extending along the left iliac region to left inguinal region at post operative site.

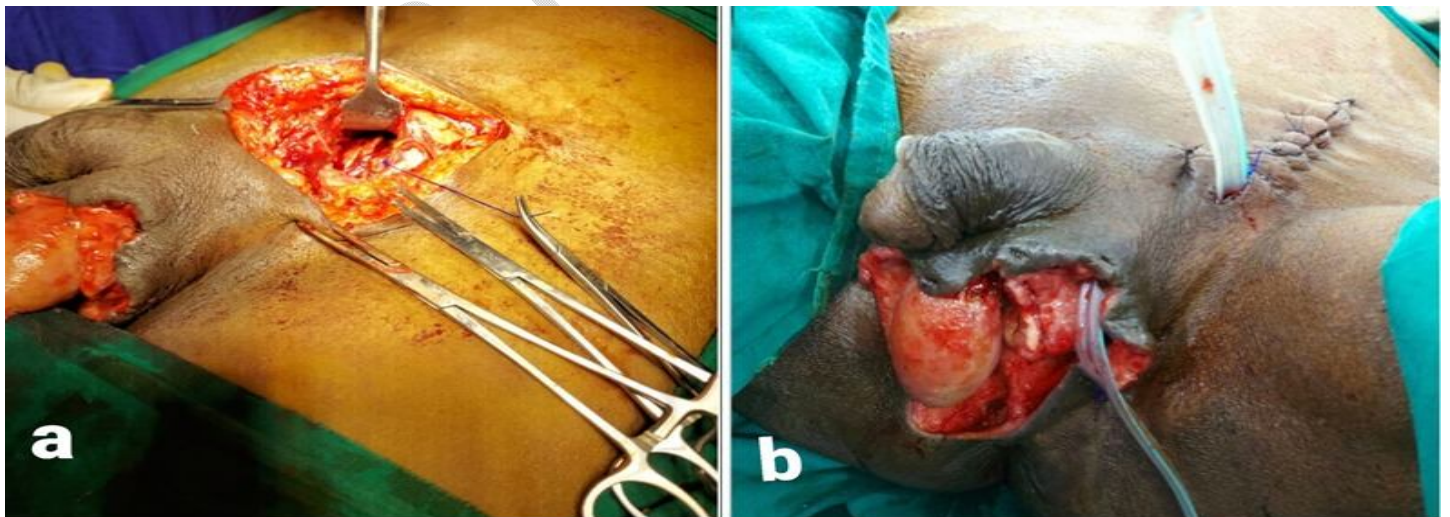


Figure 2: a] Intraoperative picture showing the abscess extending in to the sub rectus plane of the anterior abdominal wall  
b] Post orchietomy status, abscess drainage and wound was closed with corrugated drain in situ

In view of complex perineal wound with fistulous tract extending into the pelvis and parietal wall patient was planned for fecal diversion for control of pelvic sepsis. Hence patient was taken up for Laparoscopic sigmoid loop colostomy[Figure:3]. Post operatively pus discharge settled, inguinal wound secondary suturing done and Right testes was covered with residual scrotal skin itself. Patient was discharged for follow up [Figure:4]

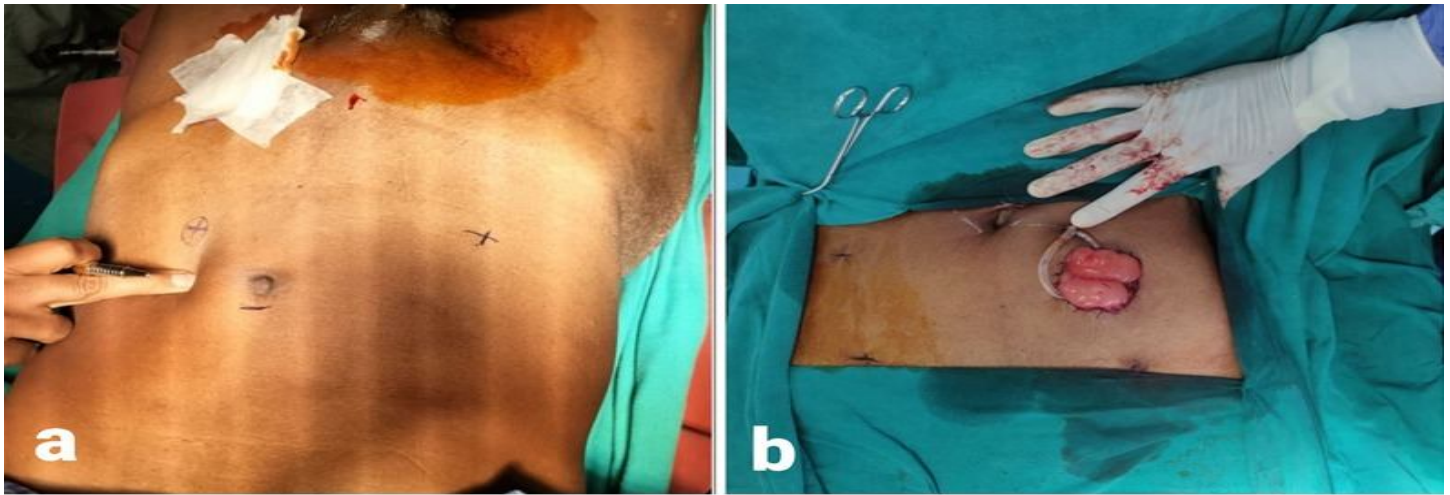


Figure 3: a] Pre procedure Laparoscopic port site marking for sigmoid loop colostomy. b] Post laparoscopic loop sigmoid colostomy status



Figure 4: Post secondary suturing and healed scrotal and inguinal wound

### 3. DISCUSSION

**In our experience** in this patient due to constant fecal contamination of the wound along with persistence of multiple fistulous tract even after complete debridement and abscess drainage, there was ascending infection leading to pelvic sepsis and parietal wall abscess. Hence high clinical suspicion and early detection of fistulous communication, extent of infectious process and path of spread by CT/MRI is recommended[2]. And these subset of patients should be managed with early fecal diversion for control of sepsis and faster recovery. In this patient, Laparoscopic mobilization of the large bowel, demonstration of proximal and distal loop, exteriorization of the bowel loop through widening the left utility port incision was found to be simple and easily reproducible technique in creating loop sigmoid colostomy. Previous evidence reported the usefulness of Laparoscopic sigmoid colostomy in various patients requiring fecal diversion[3]. The operative time for our case was 65 minutes, making it feasible even for the surgeon without extensive laparoscopy experience, and was comparable to that reported in another study[4].

### 4. CONCLUSION

**In our experience** we found that patient with Fournier gangrene and complex perineal wound with multiple fistulous tract extending into the pelvic cavity and parietal wall causing sepsis can be managed with laparoscopic fecal diversion for sepsis control and faster wound recovery.

## CONSENT

Patients signed informed consent regarding publishing their data and photographs.

## ETHICAL APPROVAL

No ethical approval is required in accordance with the ethical standards of our institution.

## REFERENCES

1. Jayatunga A, Caplan S, Paes T. Survival after retroperitoneal necrotizing fasciitis. *British Journal of Surgery*. 1993;80(8):981-981.
2. Avery L, Scheinfeld MH (2013) Imaging of penile and scrotal emergencies. *RadioGraphics* 33:721–740
3. Haque P, Singh N, Upadhyay S, Chaudhry N. Laparoscopic versus open sigmoid loop colostomy: A comparative study from a cohort of 62 patients requiring temporary faecal diversion at a tertiary care center in North India. *Nigerian Journal of Surgery*. 2019;25(2):139.
4. Trejo-Ávila ME, Valenzuela-Salazar C, Betancourt-Ferreya J, Fernández-Enríquez E, Romero-Loera S, Moreno-Portillo M. Laparoscopic versus open surgery for abdominal trauma: a case-matched study. *J Laparoendosc Adv Surg Tech A* 2017;27:383–7.