

Double Appendix: A Rare Case Entity

ABSTRACT

Introduction: Duplication of the vermiform appendix is a rare congenital abnormality and the majority of cases are diagnosed incidentally.

Presentation of the Case: A forty year old male was admitted to the emergency department complaining of abdominal pain, nausea, and anorexia. The physical examination confirmed the presence of pain at Mc Burney's point. Laboratory findings showed raised White blood counts. Abdominal ultrasound revealed non compressible appendix with peri appendiceal fluid collection and probe tenderness. Intraoperatively double appendix was found. One appendix was grossly normal and other was inflamed. Both appendices were surgically removed to prevent complications in later life of the patient.

Discussion: Although the finding of appendiceal duplication is an uncommon congenital abnormality, misdiagnosis and mismanagement of this situation may yield poor clinical outcomes and serious medical consequences.

Conclusion: Anatomical variations should be considered as a precursor of future pathological processes.

Keywords: Appendix; acute abdomen; double appendix.

1. INTRODUCTION

"Duplication of vermiform appendix is a rare congenital anomaly originally observed and described by Picoli in 1892. Double appendix emerged as a difficult entity to diagnose. With an incidence varying from 0.004% to 0.009% [1,2] double appendix has become a neglected and commonly missed diagnosis, often with life threatening consequences. Double appendix are usually asymptomatic". "Symptoms are usually the result of obstruction and inflammation. Most of the cases of vermiform appendix duplication in adults published in literature were incidentally diagnosed during an autopsy or laparotomy for a different cause. On the other hand, double appendix in children, requires additional and more meticulous work-up as it often represents a manifestation of more complex developmental intestinal, genitourinary or vertebral abnormalities" [1,2]. "The clinical presentation can vary according to the location of the appendices" [3].

"Duplication of the vermiform appendix is rare, with a reported incidence of 0.004%. About 100 appendiceal anomalies have been reported in the literature. Most anomalies of the appendix have been observed in adults and most were noticed incidentally during surgery not primarily involving the appendix" [1]. Picoli (1892) reported "the first

case of appendix duplex in a female patient who had associated anomalies of duplication of the entire large bowel, two uteri with two vaginae, ectopia vesicae and exomphalos" [2]. "Double appendix are usually asymptomatic, the majority of them are diagnosed at surgery or on post-mortem examination, some of them can be picked up preoperatively on barium enema. Symptoms are usually the result of obstruction and inflammation. The clinical presentation can vary according to the location of the appendices" [3]. "Duplication of the vermiform appendix is rare, with a reported incidence of 0.004%. About 100 appendiceal anomalies have been reported in the literature. Most anomalies of the appendix have been observed in adults and most were noticed incidentally during surgery not primarily involving the appendix" [1]. Picoli (1892) reported "the first case of appendix duplex in a female patient who had associated anomalies of duplication of the entire large bowel, two uteri with two vaginae, ectopia vesicae and exomphalos" [2]. "Double appendix are usually asymptomatic, the majority of them are diagnosed at surgery or on post-mortem examination, some of them can be picked up preoperatively on barium enema. Symptoms are usually the result of obstruction and inflammation. The clinical presentation can vary according to the location of the appendices" [3].

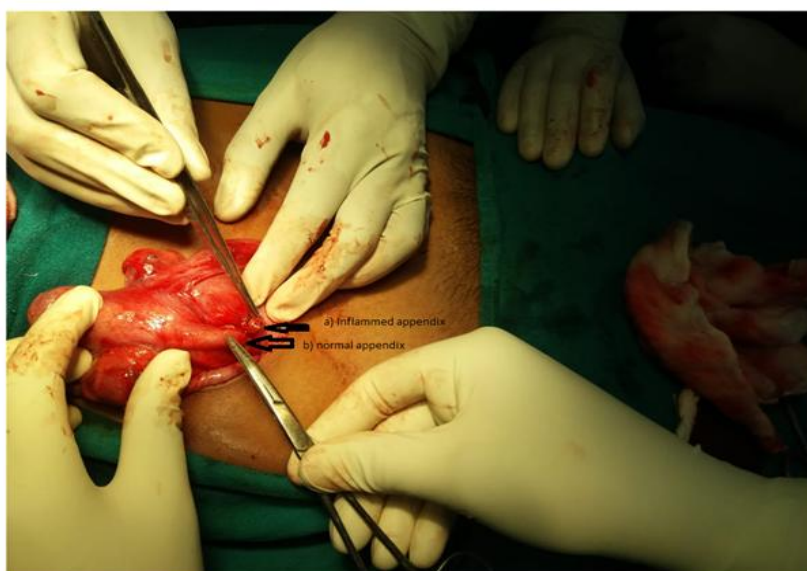2. CASE PRESENTATION

A forty year old male patient presented to the emergency department with the chief complaint of pain abdomen, nausea and anorexia for 1 day. Pain started around umbilicus and later shifted to right lower quadrant accompanied by nausea and anorexia. On physical examination of patient, tenderness at Mc Burney's point was present. Rebound tenderness was positive at Mc Burney's point. Laboratory studies showed leucocytosis with White blood counts 13000/cumm, Hb 12gm% . Renal and liver function tests were within normal limits. Ultrasound abdomen showed blind ended tubular structure with diameter of 8 mm in right iliac fossa. The tubular structure was non compressible with periappendiceal fluid collection and positive probe tenderness. Diagnosis of acute appendicitis was made and patient was shifted to operation theatre for appendicectomy. Grid iron incision was made at Mc Burney's point. After lysis of adhesions and cecum release

normal cecal appendix in its usual position was identified. Further bowel inspection revealed no meckel's diverticulum. So cecal mobilization was done and another tubular structure originating from taenia coli was identified which appeared to be appendix and was inflamed (cave wall bridge type B2). Both the tubular structures were surgically removed. Incision closed in layers. Patient discharged on fourth post operative day in good condition. Histopathology revealed both tubular structures as appendices.

3. DISCUSSION

"The first case of double cecal appendix was reported in 1892. Since then less than 100 cases have been reported world wide" [4]. "Duplication is rare and may be associated with other congenital abnormalities" [5]. First classification of cecal appendix was developed in 1936 by Cave [6] modified in 1962 by Wallbridge [7]. "Since then authors made several changes to it and modified classification by Cave-Wallbridge



**Fig. 1. Intraoperative finding of double appendix
a) Inflamed appendix; b) Normal appendix**




Fig. 2. Morphology of double appendix after being detached from body

was formed which is now most widely used. Cave-Wallbridge categorizes double cecal appendix into three types: A, B and C. Type A is characterized by the presence of two cecal appendices with a common origin in a single caecum. In type B, two appendices emerge from different cecal origins from a single caecum. This type is also subdivided into B1 and B2. In subtype B1, the two appendices emerge from a single caecum, one from each side of the ileocecal valve, symmetrically. On the other hand, in subtype B2, one of the appendices is in its usual position and the second one is located alongside the taenia coli. Finally, type C is characterized by the existence of two caecum, each with a cecal appendix. On routine investigations preoperative diagnosis of double appendix may be missed. Theoretically; computed tomography has been reported to identify duplication of the appendix, especially in cases where both appendices are significantly inflamed” [8]. “Possibility of double appendix should be kept in mind in unwell patient with clinical features suggestive of acute appendicitis, but with a macroscopically normal appendix at the time of surgery. Cecum should be carefully inspected to exclude duplicate appendix. Duplicate normal appearing appendix should be resected to avoid future diagnostic confusion” [9]. “Missing a duplicate appendix during surgery may have serious life threatening complications for the patient in the future including sepsis, acute appendicitis, colonic perforation, obstruction, bleeding, pain, failure to thrive, abdominal mass” [10-13] due to difficult diagnosis because of history of previous appendectomy and may pose medicolegal problems for the surgeon as well.

4. CONCLUSION

Although rare but appendix duplication should be kept in mind in patients with normal appearing appendix during surgery. Intestinal, genitourinary or bone anatomic variations should be investigated in face of duplicated appendix. Thorough examination of caecum for duplicated appendix should be carried out during surgery for acute appendicitis in case of normal appearing appendix to rule out missed appendix which can lead to serious outcomes for both patients and surgeon.

CONSENT

As per international standard or university standard, Participants' written consent has been collected and preserved by the author(s).

ETHICAL APPROVAL

As per international standard or university standard written ethical approval has been collected and preserved by the author(s).

COMPETING INTERESTS

Authors have declared that no competing interests exist.

REFERENCES

1. Collins DC. A study of 50,000 specimens of the human vermiform appendix. *Surg Gynecol Obstet.* 1955;101(4):437-45.
2. Kjossev KT, Losanoff JE. Duplicated vermiform appendix. *Brit J Surg.* 1996; 83:1259.

3. Kothari AA, Yagnik KR, Hathila VP. Duplication of vermiform appendix. *J Postgraduate Med.* 2004;50(4):285-6.
 4. Griffiths EA, Jagadeesan J, Fasih T, Mercer-Jones M. Bifid vermiform appendix: A case report. *Curr Surg.* 2006;63:176-8.
 5. Bluett MK, Halter SA, Salhany KE, O'Leary JP. Duplication of the appendix mimicking adenocarcinoma of the colon. *Arch Surg.* 1987;122(7):817-20.
 6. Cave AJ. Appendix vermiform is duplex. *J Anat.* 1936;70:283-292.
 7. Wallbridge PH. Double appendix. *Br J Surg.* 1962;50:346-347.
 8. Chew DK, Borromeo JR, Gabriel YA, Holgersen LO. Duplication of the vermiform appendix. *J Pediatr Surg.* 2000; 35(4):617-8.
 9. Nageswaran H, Khan U, Hill F, Maw A. Appendiceal duplication: A comprehensive review of published cases and clinical recommendations: *World J Surg.* 2018;42:574-81.
 10. Bali R, Wani M, Mir S, Thakur S, Bhat R. Appendiceal duplication with simultaneous acute appendicitis and appendicular perforation causing small bowel obstruction. *J Surg Case Rep.* 2011; 2011(2):3.
 11. Dhar PP, Mohanty U. A rare case report of infant ileal atresia with double appendix. *Int J Surg Case Rep.* 2020;74:226-9.
 12. Raja AA, Vasanthakumaran T. A rare case of duplicated appendix presenting as perforated appendicitis. *J Surg Case Rep.* 2020;2020(7):rjaa133.
 13. Macpherson RI. Gastrointestinal tract duplications: Clinical, pathologic, etiologic, and radiologic considerations. *Radiographics.* 1993;13(5):1063-80.
-