

Case report

**Posterior perineal hernia and its repair by
combined laparoscopic-perineal approach:
clinical case report.**

ABSTRACT

Aims: To discuss a rare type of perineal hernia and its successful approach by combining laparoscopic and transperineal approaches.

Presentation of case: 45 years old multiparous woman presented with a gluteal swelling, progressing in size and associated with ulceration of swelling. Patient had undergone abdominal hysterectomy and ovarian cystectomy in the past. Clinical examination showed a large perineal hernia and its contents were delineated by computed tomography. Patient was offered surgical repair. Owing to large size of the sac and dense bowel adhesions inside the sac, laparoscopic reduction was complemented by perineal mobilization of the contents. Better visualization provided by laparoscopy facilitated pelvic mesh fixation with ease.

Discussion: Perineal hernias are rare and various approaches have been described for repair of perineal hernias including open transabdominal, transperineal or combined abdominoperineal repairs. We present a case report of posterior perineal hernia in a female patient who presented with a mass in the gluteal region. Surgical repair with synthetic mesh was performed using a combination of laparoscopic and transperineal approaches. Thus, combined approach can be beneficial to tackle large perineal hernia as described in this case report.

Conclusion: Symptomatic perineal hernias require surgery and synthetic mesh repair using combined approach (laparoscopic and perineal) allows successful repair.

Keywords: posterior perineal hernia, surgical repair, mesh repair, laparoscopic approach

1. INTRODUCTION

Perineal hernia is the protrusion into the perineum of intraperitoneal or extraperitoneal contents through a congenital or acquired defect of the pelvic diaphragm. Perineal hernias may occur anteriorly or posteriorly to the superficial transverse perineal muscles. Repair can be accomplished through transabdominal, perineal, or combined abdominoperineal approaches. The defect in the muscles of the pelvic diaphragm may be closed either with direct suturing or by using autogenous tissues or synthetic mesh. [1]

We present a case report demonstrating the benefits of combined approach using a nonabsorbable mesh to repair the defect.

2. PRESENTATION OF CASE

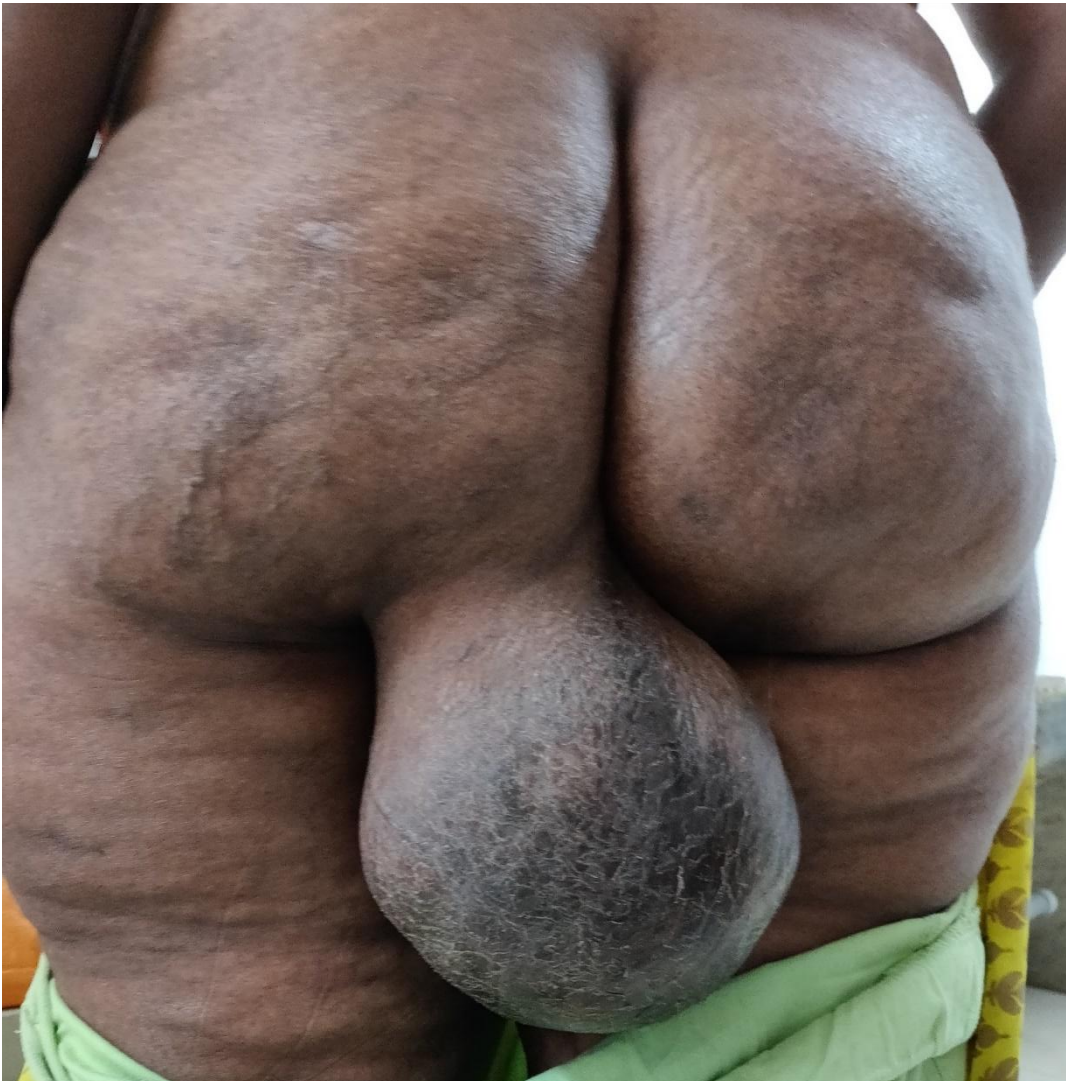2.1 Patient information

45 years old multiparous woman presented with complaints of a perineal swelling for 4 years which progressed in size and made walking uncomfortable. Patient noted skin ulceration over the swelling a week ago. Patient gave history of multiple abdominal surgeries in the past including total abdominal hysterectomy (2007), laparotomy for left ovarian cyst removal (2011), incisional hernia repair (2013) and left gluteal abscess drainage (2013). No known comorbidities.

2.2 Clinical findings

On examination, there was a swelling of size 15x10cms in the left gluteal region emerging between the anus and left ischial tuberosity with positive cough impulse. Superficial skin ulceration was noted over the swelling. It was partly reducible. Another swelling of size 3x3cms over the anterior abdomen along the midline scar in the hypogastric region, fully reducible. BMI = 28.9

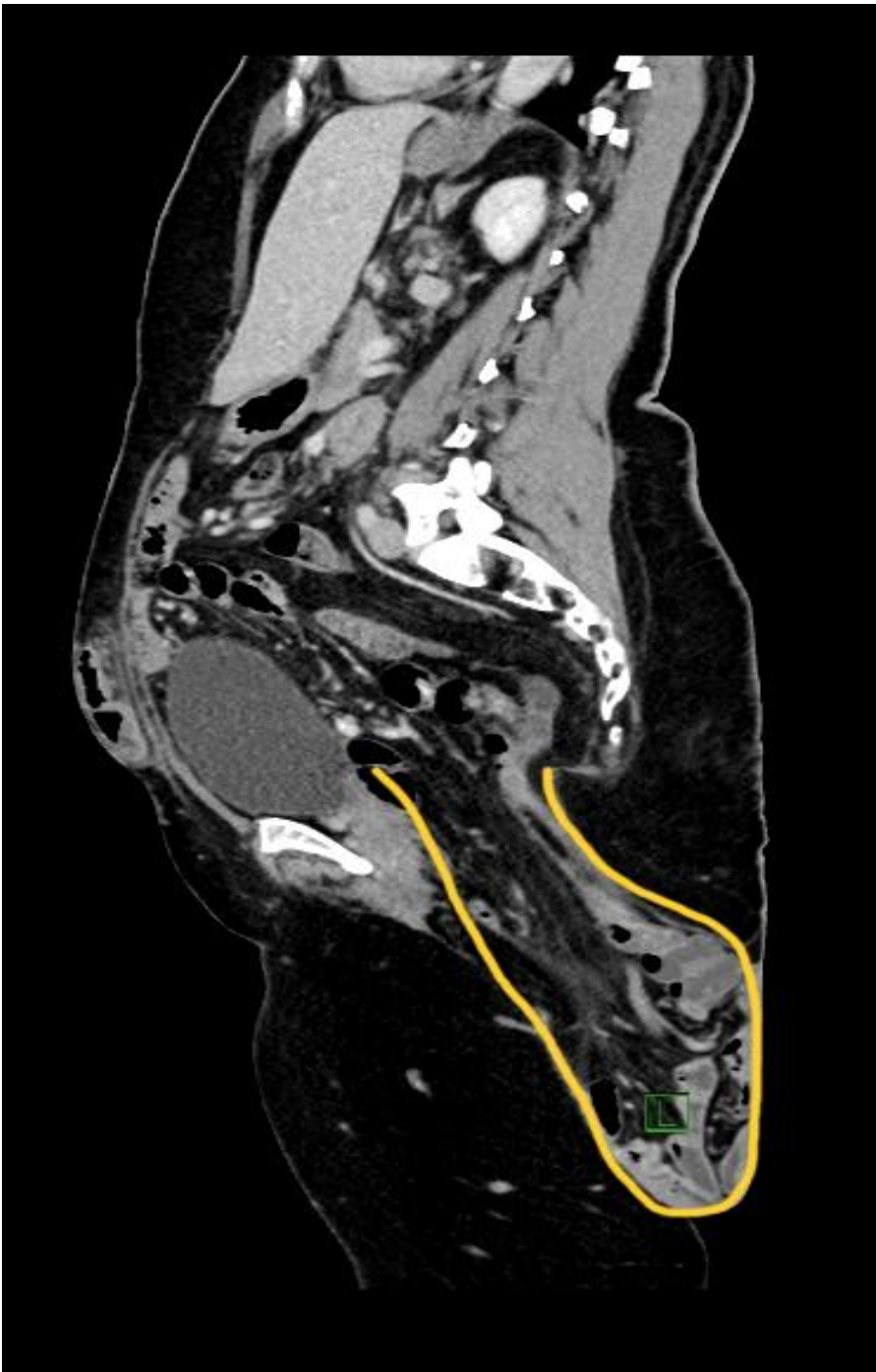Image 1: Preoperative image (patient is standing)



2.3 Diagnostic assessment

Her baseline blood work was within normal range. CT abdomen Imaging revealed defect measuring 5.4x4cms in the left side of the pelvic floor in the posterior perineum with herniation of the mesentery, small bowel loops along with the mesenteric vessels through the left ischio-rectal fossa to the exterior. There was no evidence of bowel obstruction on the imaging. Also, ventral hernia in the hypogastric region with a defect 5.4 x 5cms containing bowel loops was evident.

Image 2: Computed tomography of pelvis taken preoperatively. (Sagittal view with yellow line highlighting the hernia sac)

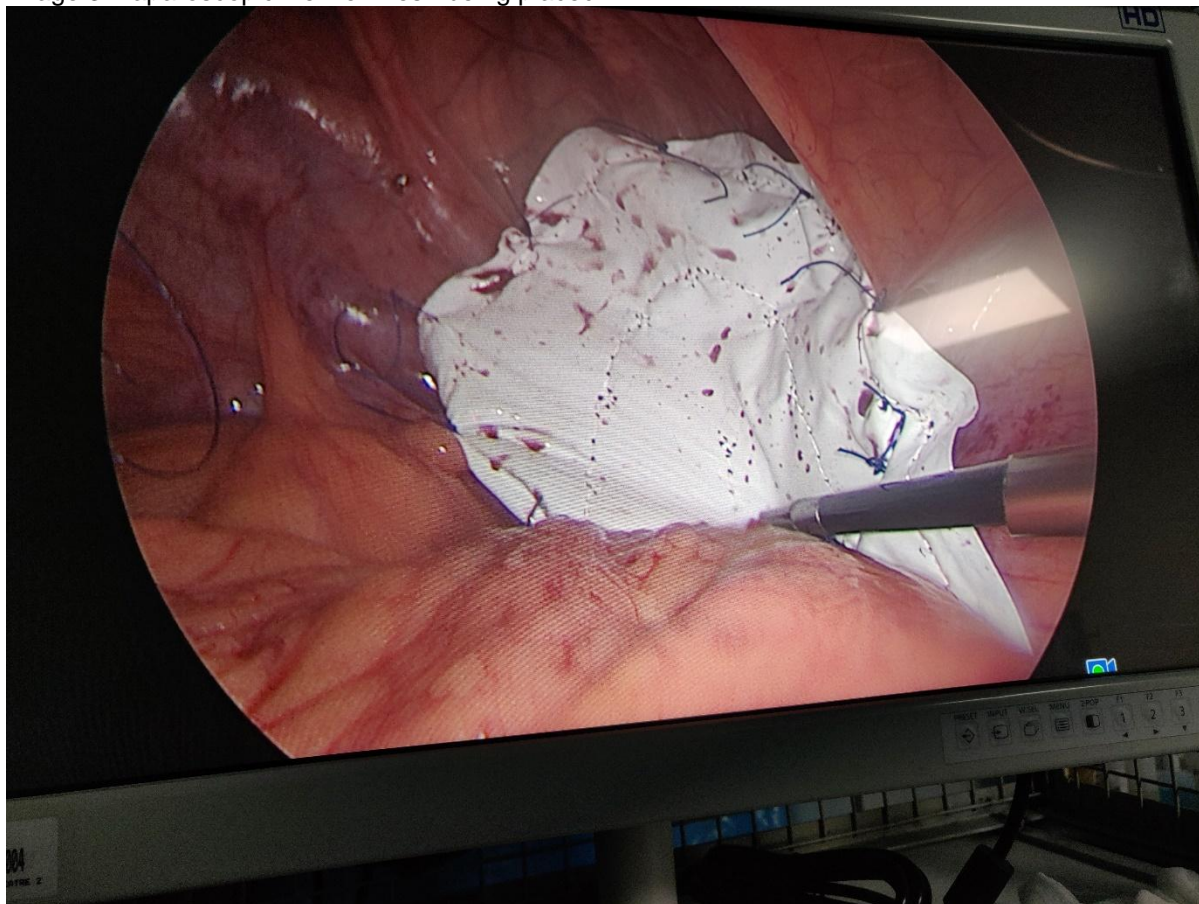


2.4 Surgical intervention

After preoperative evaluation, patient was planned for laparoscopic repair of the posterior perineal hernia. Prophylactic antibiotics and low molecular weight heparin were administered perioperatively. Patient placed under Lloyd Davis position. Pneumoperitoneum was created by inserting Veress needle at Palmer's point. 10 mm camera port was placed in the right lumbar region. 5 mm working ports were placed in the right iliac, right and left hypochondriac region. Hernial defect was noted in the left pelvic floor of size about 5x5cms containing small bowel loops with its mesentery, caecum and appendix. Due to dense adhesions of bowel loops to the sac and large size of hernial sac, laparoscopic reduction was challenging. Hence, sac was opened from perineal side. Bowel loops were released from the sac and contents were reduced. Redundant sac was excised and perineal wound closure was done. Perineal defect was covered with dual composite

mesh 15cms diameter and anchored with 2-0 prolene sutures over pelvic brim placed laparoscopically. Ventral hernia repair was performed simultaneously. Surgery lasted for three hours. She tolerated diet by postoperative day (POD) 2, opened bowel and was discharged on POD 6.

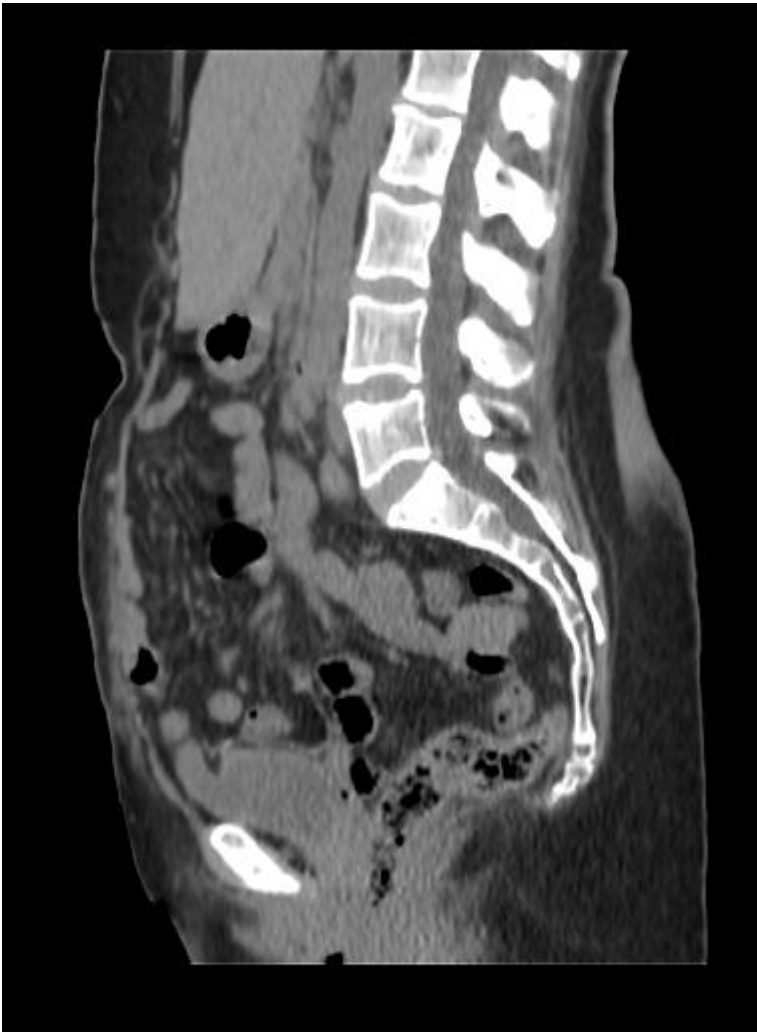Image 3: Laparoscopic view of mesh being placed



2.5 Follow-up and Outcome

Patient presented on POD 7 with abdominal distension, 3 episodes of non-bilious vomiting, constipation and not passing flatus. Clinically, soft non-tender distended abdomen with sluggish bowel sounds was noted. X-ray abdomen showed dilated small bowel loops suggestive of sub-acute intestinal obstruction. Patient was managed with naso-gastric decompression, iv fluids and analgesics. The episode settled with conservative management and patient was discharged. 3-month follow-up CT scan showed resolution of hernia completely and no recurrence. One year follow-up showed no evidence of hernia recurrence.

Image 4: Computed tomography of pelvis taken postoperatively (Sagittal view – no recurrence 3 months postoperatively)



3. DISCUSSION

Primarily acquired perineal hernias are caused by factors associated with increased intra-abdominal pressure. They are more common in females as a result of the broader female pelvis and the attenuation of the pelvic floor during pregnancy and childbirth. Secondly acquired perineal hernias are incisional hernias associated with extensive pelvic operations such as abdominoperineal resection of the anorectum and pelvic exenteration. Pain in the perineal area, intestinal obstruction, topical skin erosion, and difficulty with urination necessitate the surgical repair of a perineal hernia. [1]

Surgical repair involves mobilisation and reduction of the contents of the hernial sac with closure of the defect. Laparoscopy has the advantage of quicker recovery time, faster recovery of bowel function, and decreased immunological stress while offering the same advantages as open abdominal surgery and allows better exposure for dissection of the contents of the hernia sac, hernial boundaries and pelvic contours and provides good access for mesh positioning on solid structures, such as the sacrum and pelvic floor. [2] Successful laparoscopic perineal hernia repair as well as successful repair by a combined laparoscopic mesh repair approach and plastic resection of the cutaneous perineal wound have been reported. [3,4]

Owing to large size of the sac and dense bowel adhesions inside the sac, laparoscopic reduction was more challenging and infeasible in this case. Mobilization of contents as well as adhesiolysis was achieved by approaching the sac from perineal side. Better visualization provided by laparoscopy facilitated pelvic mesh fixation with ease. Thus, combined approach was beneficial to tackle this large perineal hernia with adhesions.

4. CONCLUSION

In conclusion, symptomatic perineal hernias require surgery and synthetic mesh repair using combined approach (laparoscopic and perineal) allows successful repair.

CONSENT

All authors declare that 'written informed consent was obtained from the patient for publication of this case report and accompanying images. A copy of the written consent is available for review by the Editorial office/Chief Editor/Editorial Board members of this journal.

REFERENCES

1. Stamatiou D, Skandalakis JE, Skandalakis LJ, Mirilas P. Perineal hernia: surgical anatomy, embryology, and technique of repair. *Am Surg*. 2010 May;76(5):474-9. PMID: 20506875
2. Honjo K, Sakamoto K, Motegi S, Tsukamoto R, Munakata S, Sugimoto K, et al. Case report of perineal hernia after laparoscopic abdominoperineal resection. *Asian J Endosc Surg*. 2018;11(2):173–6.
3. Gómez Portilla A, Cendoya I, Uzquiza E, Martín E, Martínez de Lecea C, Gómez C, Romero EE. Giant perineal hernia: laparoscopic mesh repair complemented by a perineal cutaneous approach. *Hernia*. 2010 Apr;14(2):199-201. doi: 10.1007/s10029-009-0519-9. Epub 2009 Jun 3. PMID: 19495919.
4. Dulucq JL, Wintringer P, Mahajna A. Laparoscopic repair of postoperative perineal hernia. *Surg Endosc*. 2006 Mar;20(3):414-8. doi: 10.1007/s00464-005-0193-7. Epub 2006 Jan 25. PMID: 16437278.