

Case study

The Commonness of Rarity

ABSTRACT

Malaria is the most frequent tropical disease in developing nations. Among the four types of malaria, *P. falciparum* malaria is the most severe, as it affects multiple systems. Acute Respiratory Distress Syndromes (ARDS) is the most severe respiratory complication commonly associated with *P. falciparum* but very rarely with *P. vivax*. Here, we present an interesting case report pertaining to young patient (Male/25 years/no co-morbidities) presented with severe breathlessness, diagnosed as ARDS post *P. vivax* malaria complicated by secondary bacterial infection achieving complete recovery with the combined holistic approach of early mechanical ventilation support, prone positioning, antibiotic titration, physiotherapy and good nutrition. This case reinstates the importance of early recognition of ARDS, clinical suspicion for secondary infection and implication of prone position ventilation and other recruitment manoeuvres (RM).

KEYWORDS: *Malaria; ARDS; P.vivax; Recruitment manoeuvres.*

INTRODUCTION

Malaria is one of the most frequent parasitic illnesses occurring in developing nations. Pulmonary involvement in malaria has been established for over 20 decades, but the understanding of its pathophysiology and therapy is very less. Pulmonary edema is the most devastating event of the lung's involvement. The basic underpinning mechanism is the enhanced alveolar capillary permeability resulting in the loss of intravascular fluid into the lungs. Among all the species of malaria, falciparum has the potential to induce serious illness that affects nearly all organs of the body within a few days after presentation. Malaria-related severe lung involvement (ARDS) is occasionally associated with vivax malaria, which is one of the most devastating respiratory complications associated with high mortality rates. The estimated incidence of ARDS in case of *P. falciparum* is 5% to 25% while in cases of *P. vivax* are very scattered, less than 1% [1]. We here present a case of a young male patient with sudden onset of ARDS as a complication of vivax malaria requiring the lung-protective mechanical ventilation, prone positioning and other medical management support thereby recovering completely.

CASE PRESENTATION

A 25 years old young male patient (normotensive, non-diabetic) had complained of severe breathing difficulty, hypoxia and was on BIPAP support at another local hospital. He has been suffering from fever with chills since the last 2-3 days. Upon undergoing diagnostic tests, he tested positive for *P. Vivax* and was started on Inj. Falcigo but the deterioration continues. Patient was then brought to the Emergency Department of KD Hospital with BIPAP support, hypoxia and hypotension. On primary investigation in the emergency department, the patient was tachypneic, had tachycardia and hypotension. ABG showed type II respiratory failure with decreased air entry in bilateral lung fields along with presence of crackles indicating possibility of pulmonary edema along with possibility of inflammation or infection of small bronchi, bronchioles, and alveoli. Due to unstable hemodynamics, a chest x-ray was advised which confirmed the auscultative findings. Lung scan also showed 'B/C' profile with shred sign/lung hepatization. Blood samples were drawn for basic work-up and blood cultures. Inotropic support was started and the patient was shifted to Intensive care unit (ICU).

In ICU, patient continued to be tachypneic, had worsening hypoxia and hence was intubated with prior consent. Patient was sedated, paralyzed and continuously monitored. A cross reference to Pulmonologist was given in view of ARDS. Blood Culture and sensitivity - aerobic & MYCO - F test came out negative. The Patient continued to stay hypoxic with 100% FiO₂ support. Along with frequent Recruitment maneuvers (RMs) done bedside, patient was made prone & provided Ventilation for 15-18 hours per day. This process was further repeated for 2-3 days. Patient started showing signs of gradual improvement. Tracheostomy was performed in view of need of prolonged mechanical ventilation and resolving signs of ARDS confirmed by clinical and radiological improvements for the patient.

As the clinical recovery was slow and suspecting an underline sepsis/co-infection, tracheal secretions were sent for culture which showed Acinetobacter Baumannii complex resistant to Fosfomycin and Levofloxacin. Accordingly, the antibiotic support was changed and further care was taken for prevention of secondary infections.

By taking a holistic approach of Physiotherapy, Mobilization with ventilator, good nutrition, DVT Pump (for prevention of DVT), titration of antibiotics and other supportive care, the patient showed complete sign of recovery and was shifted to ward for further observation and management. Tracheostomy was decannalised 2-3 prior to day of discharge in the ward. During ward stay, the patient was closely monitored for any signs of instability. Patient was discharged in hemodynamically stable condition after 21 days of stay in hospital.

RADIOLOGICAL INVESTIGATION:

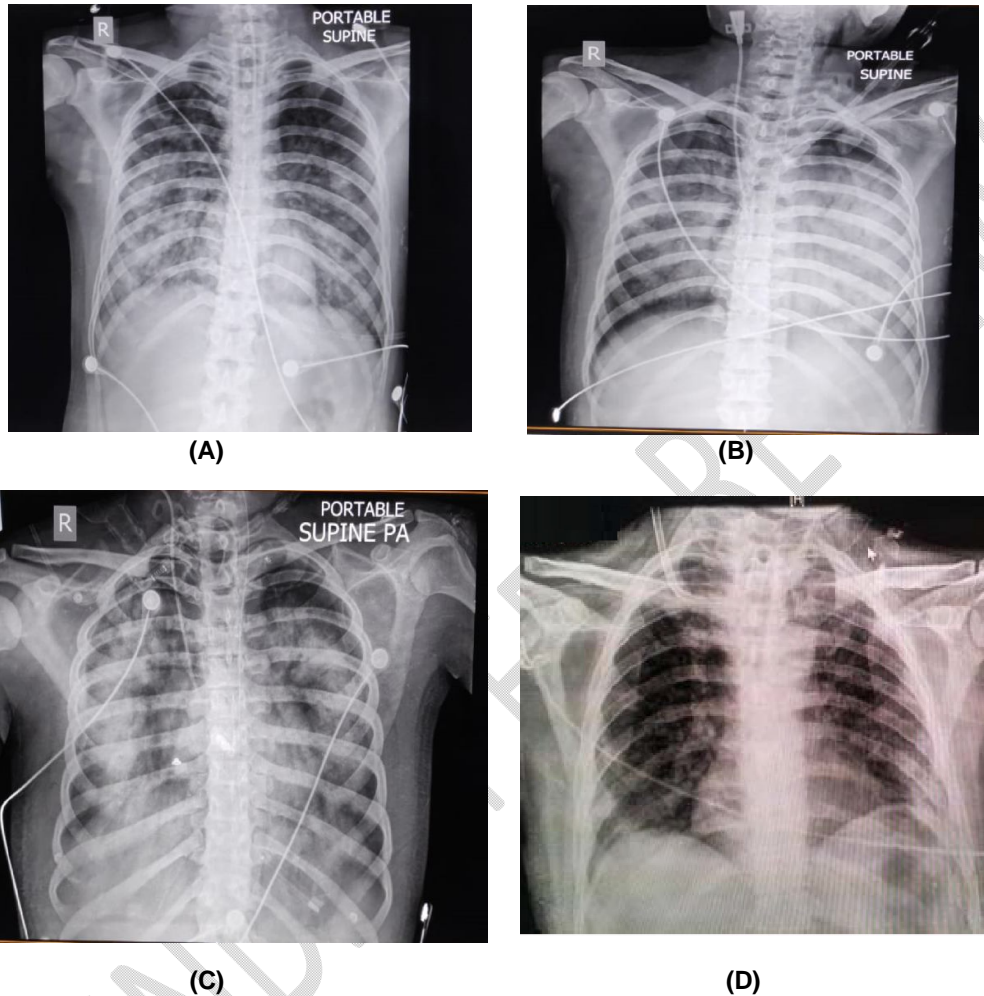


Figure A-D: Shows serial Chest X-ray done on Admission (A) During the course of treatment (B) and (C) Bilateral increased homogenous opacities in line with clinical picture of ARDS followed by (D) which shows significant improvement post tracheostomy decannulation at the time of discharge.

Written informed consent was obtained from the patient to publish his case in the journal.

DISCUSSION

Human malaria, the parasitic disease, is caused by four plasmodium species, *Plasmodium falciparum*, *P. vivax*, *P. ovale*, and *P. malariae* which is spread by the female *Anopheles* mosquito. A benign febrile acute disease caused by *Plasmodium vivax* is usually seen in countries of Asia and South America [2]. Manifestations of malaria vary from asymptomatic infection to acute febrile syndrome, severe malaria, and lethal cases. Clinical evolution is influenced by parasite and host variables, as well as social and geographic factors [4]. *P. vivax* (benign tertian malaria) may no longer be a paradigm for uncomplicated malaria. In benign tertian malaria, there have been isolated

instances of shock with ARDS⁴, pulmonary edema⁵, ARDS⁶, and bronchiolitis obliterans [4-7]. This defines malaria as another cause of ALI and ARDS. In a case series of three cases report by **Supriya Sarkar et al.** two middle aged men and one juvenile boy affected with **vivax malaria had a complication of ARDS [8]. The initial case was associated with stultification of renal and liver function. ARDS was emerged following the therapy with antimalarial drugs in two cases, whereas in the third case ARDS occurred prior to the initiation of chloroquine therapy. The diagnosis** of ARDS was corroborated after ruling out the cardiac disease using echocardiography. ARDS developed rapidly in all cases within an hour of the onset of respiratory distress, necessitating intubation. Recovery was rapid and complete in all three cases. In all the cases, early introduction of mechanical ventilation with high PEEP was proved to be life-saving. Similar flow of symptoms was noted in our case apart from renal and liver dysfunction. RFT and LFT with protein was normal throughout the period of stay in hospital. Optimal management of malaria-induced ARDS includes early recognition and diagnosis followed by high peep - low tidal volume prone ventilation as seen in our management. Researchers also suggest that an accumulation of pulmonary monocytes occurs leading to an intravascular inflammatory response, which contributes to pulmonary manifestations in malaria [9]. The patient typically have breathlessness which swiftly onrushes to the respiratory failure which is observed either at the time of disease occurrence or after the clinical recovery. A case of ARDS in 58-year-old female patient with P. Vivax reported by **Malik A et al.** **showed importance early detection and administration of particular antimalarial therapy, together with assisted ventilation, can salvage lives [10]. This clinical presentation was observed in our case and** there is a requirement of mechanical ventilation within a few hours after the onset of respiratory symptoms. During the initial 2-3 days of ventilation, the patient was paralysed, and recruitment was endeavoured for refractory hypoxemia. In 2013, the French multicentric RCT PROSEVA Study Group showed in patients with severe ARDS, early application of prolonged prone-positioning sessions significantly decreased 28- day and 90-day mortality [11].

The ARDS may also be related to a coincidental bacterial sepsis that may not be clinically obvious. Hence, after collecting relevant microbiologic specimens, doctors should use a low threshold for initiating broad spectrum antibiotic therapy in such patients. In our case, after initial improvement shown due to prone ventilation and recruitment, further recovery was dampened by the underlying secondary **bacterial infection which was proven by positive tracheal secretions. The change in antibiotic as per sensitivity report along with combined holistic approach of physiotherapy and good nutrition helped achieve significant clinical improvement in patients and ensured a quick and complete recovery without any** further complication.

CONCLUSION

Patients with severe ARDS due to vivax malaria can be safely managed with early prone position ventilation. Early institution of mechanical ventilation with high PEEP coupled with prone positioning, RMs, physiotherapy, early mobilization and good nutrition can lead to faster recovery of the patient. Early recognition, clinical **suspicion for secondary infection and antibiotic titration are also key factors for better patient management.**

CONSENT

"All authors declare that 'written informed consent was obtained from the patient (or other approved parties) for publication of this case report and accompanying images. A copy of the written consent is available for review by the Editorial office/Chief Editor/Editorial Board members of this journal."

ETHICAL APPROVAL (WHERE EVER APPLICABLE)

"All authors hereby declare that all experiments have been examined and approved by the appropriate ethics committee and have therefore been performed in accordance with the ethical standards laid down in the 1964 Declaration of Helsinki."

REFERENCES

1. Mazhar F, Haider N. Respiratory Manifestation of Malaria: An Update. *Int J Med Res Health Sci.* 2016;5(5):59-65.
2. Lomar AV, Vidal JE, Lomar FP, Barbas CV, de Matos GJ, Boulous M. Acute respiratory distress syndrome due to vivax malaria: case report and literature review. *Braz J Infect Dis.* 2005;9(5):425-30.
3. Miller LH, Baruch DI, Marsh K, Doumbo OK. The pathogenic basis of malaria. *Nature.* 2002; 415:673–9.
4. Kumar S, Melzer M, Dodds P, Watson J, Ord RP. Vivax malaria complicated by shock and ARDS. *Scand J Infect Dis.* 2007; 39:255–6.
5. Torres JR, Perez H, Postigo MM, Silva JR. Acute non-cardiogenic lung injury in benign tertian malaria. *Lancet.* 1997; 350:31–2.
6. Taniot MA, Kogelman L, McGovern B, Hassoun P. Acute respiratory distress syndrome complicating Plasmodium vivax malaria. *Crit Care Med.* 2001; 29:665–7.
7. Yale S, Adlakha A, Sebo TJ, Ryu JH. Bronchiolitis obliterans organizing pneumonia caused by Plasmodium vivax malaria. *Chest.* 1993; 104:1294–6.
8. Sarkar S, Saha K, Das CS. Three cases of ARDS: An emerging complication of Plasmodium vivax malaria. *Lung India.* 2010; 27(3):154-7.
9. Mukherjee T, Lavania AK. Acute Respiratory Distress Syndrome due to Vivax Malaria. *Med J Armed Forces India.* 2008;64(4):365-6.
10. Malik A, Yadav P, Sajjan K, Gurbani C. Acute respiratory distress syndrome in a case of Plasmodium vivax malaria. *Int J Community Med Public Health.* [Online].2021; 8 (3): 1515-1517.
11. Guérin C, Reignier J, Richard JC, Beuret P, Gacouin A, Boulain T, et al. Prone positioning in severe acute respiratory distress syndrome. *N Engl J Med.* 2013;368(23):2159-2168.

UNDER PEER REVIEW