

Therapeutics Effect of Costus Root Extract against Copper Oxide Nanoparticles Induced Liver and Kidney Toxicity in Rat

ABSTRACT

Aims: Copper oxide nanoparticles (CuO NPs), which have potential hazards for organisms and the environment in a number of applications, have emerged as a prominent class of nanomaterials.

Study design: This study aimed to investigate the effect of copper oxide nanoparticles in rat liver and kidney tissues.

Methodology: A total of 20 adult male rats were assigned randomly to 2 groups [1st, control; 2nd, CuO NPs (100 mg/kg body weight/day) intraperitoneally for 4 weeks].

Results: Current results revealed, significant increases in serum ALT, AST, urea, creatinine, potassium ions and liver and kidney tissue damage after CuO NPs administration when compared to control group. Conversely, statistical significant decreases were detected in serum albumin, total proteins, calcium and sodium ions levels in CuO NPs group as compared to control group.

Conclusion: We can conclude that; CuO NPs-induced toxicity and injury in rat liver and kidney.

Keywords: Copper oxide nanoparticles; liver; Kidney; Toxicity; Rats.

1. INTRODUCTION

Nanoparticles (NPs) are generally defined as particulate matter with at least one dimension that is less than 100 nm. This definition puts them in a similar size domain as that of ultrafine particles (air borne particulates) and places them as a sub-set of colloidal particles [1]. Due to unique properties of NPs such as small size (1-100 nm in diameter) and the greater surface area to volume ratio as well as different electronic, magnetic, optical and mechanical properties and also particle shape, these particles hold great interests in the various fields [2,3]. NPs may do not have toxic effects and used in treatment of many diseases and it has antimicrobial and antibacterial activities [4,5], however; the greater surface area to volume ratio of some NPs causes their higher chemical reactivity and results in increased production of reactive oxygen species [6,7]. Metal and metal oxide nanoparticles have been hypothesized to promote cytotoxicity and apoptosis via generation of reactive oxygen species, activation of intracellular signaling pathways, DNA damage and autophagic cell death [8-10].

Copper (Cu) is an essential trace element and has important role in many metabolic and chemical processes in cells and tissues [11,12]. Copper oxide nanoparticles (CuO NPs) have developed as a significant class of nanomaterials with potential dangers to organisms and the environment in a variety of applications as industrial, chemical, electronic and medical applications [13,14]. In a range of applications, CuO NPs have emerged as an important class of nanomaterials that may be harmful to living things and the environment human exposure to these nanoparticles has risen as a result of their diverse applications [15-17]. Oxidative stress and reactive oxygen species (ROS) production are considered the main mechanism by which copper oxide nanoparticles (CuO NPs) induce toxicity [18]. The goal of this study was to determine the effect of copper nanoparticle on liver and kidney in male rats.

2. MATERIAL AND METHODS

2.1 Preparation of CuO NPs

CuO NPs was purchased from NanoFab Technology, Cairo, Egypt with particle size about 25 ± 5 nm and a 99.9% trace metal basis.

2.2 Animals, Ethical Considerations and Experimental Design

A total of 20 male albino rats (*Rattus norvegicus*) weighing 175 ± 15 g, that were delivered from National Research Center in Giza, Egypt. The study design was endorsed by the Institutional Ethical Committee for Animal Care and Use (code: IACUC-SCI-TU-0242). Before the trial began, rats were kept at our Faculty's animal house for a week. They were kept in conventional circumstances with a standard rodent feed, unlimited access to water, a standard temperature of 25°C, 12-hour light/dark cycles, and a minimum relative humidity of 40%. Rats were allocated equally to 2 groups; Group 1- Control group: rats didn't receive any treatment, Group 2- CuO NPs group: included animals that were intraperitoneally injected with CuO Nps (400 mg/Kg body weight/ day) for 4 weeks [19].

2.3 Blood and serum samples

Finally, at the end of the study period, rats were anesthetized by sodium pentobarbital then sacrificed. Blood samples have been collected aseptically by venipuncture into a dry clean and sterile tube without anticoagulant substances and allow it to clot. Blood samples permitted to stand for 30 min at 4 ° C for clotting and then centrifuged for 10 minutes at 3000 rpm. The collected serum was kept at -18° C until it was analyzed to determine a blood parameter.

Animals were dissected just after decapitation; liver and kidney were quickly removed and cleaned with a saline solution (0.9%), then fixed with neutral buffered formalin solution (10%) for histopathological examinations.

2.4 Assessment of serum liver function tests

Alanine transaminase (ALT) and aspartate transaminase (AST) in sera were estimated according to assay designated by Reitman and Frankel [20]. Albumin and total proteins levels sera were estimated accordance to assay designated by Doumas et al. [21] and El-Aarag et al. [22] respectively.

2.5 Assessment of serum Kidney function and electrolytes tests

Creatinine and urea in sera were estimated according to assay designated by Patton and Crouch [23]. Potassium, calcium, sodium, and chloride ions levels in sera were estimated using marketable kits of Indian Sensa-core electrolyte according to the method planned by Tousson et al. [24].

2.6 Histopathological examination

Fixed liver and kidney samples were processed for paraffin sectioning, stained with hematoxylin and eosin (H&E) for histopathological examination according to Tousson [25].

2.7 Statistical Analyses

Data were expressed as means values + SE and statistical analysis was performed using one-way analysis of variance (ANOVA) to assess significant differences among treatment groups. The criterion for statistical significance was set at $p < 0.01$. Analysis was performed using (Graphpad prism, Graphpad software, Inc, La Jolla, CA, USA).

3. RESULTS

3.1 Changes in liver functions

Table (1) and Figure (1) showed that; a significant elevation in the levels of serum ALT, AST and a significant depletion in the level of albumin and total proteins in CuO NPs as compared control.

3.2 Changes in kidney functions and electrolytes

Table (2) and Figure (2) showed that; CuO NPs induced a significant increase in the level of urea, creatinine, and potassium ions while a significant decrease in the level of sodium and calcium ions as compared control group.

Table 1: Changes in serum liver functions tests in control and CuO NPs groups.

	Control	CuO NPs
GPT (U/L)	41.1 [#] ± 2.25	79.4* ± 5.86
GOT (U/L)	131.0 [#] ± 7.60	185.5* ± 9.04
Albumin (g/dl)	3.92 [#] ± 0.22	2.77* ± 0.18
T. protein (g/dl)	6.047 [#] ± 0.39	5.282* ± 0.30

Data are expressed as mean ± SE of 10 observations. Significant difference from the control group at *p < 0.01. Significant difference from the CuO NPs group at #p < 0.01.

Table 2: Changes in kidney functions & electrolytes levels in control and CuO NPs groups.

	Control	CuO NPs
Creatinine (mg/dl)	0.38 [#] ± 0.027	0.96* ± 0.040
Urea (mg/dl)	33.46 [#] ± 1.16	62.2* ± 3.88
Phosphorus	4.35 [#] ± 0.27	6.01* ± 0.49
Na+(mEq/L)	135.9 [#] ± 9.6	130.8* ± 10.5
K+(mEq/L)	4.77 [#] ± 0.31	3.50* ± 0.40
Ca++(mEq/L)	1.195 [#] ± 0.018	0.944* ± 0.016

Data are expressed as mean ± SE of 10 observations. Significant difference from the control group at *p < 0.01. Significant difference from the CuO NPs group at #p < 0.01.

3.3 Histopathological effects of CuO NPs on the liver

Liver sections in control group indicated typical hepatocyte organisation, including polygonal cells with large oval nuclei, eosinophilic cytoplasm, and a few spaced-apart hepatic sinusoids distributed between the hepatic cords with fine Kupffer cell arrangement (Figure 1A). Contrarily, liver sections in rat treated with CuO NPs showed many of histopathological changes as marked cytoplasmic vacuolization in hepatocytes, inflammatory cells and congestion in the central veins (Figure 1B).

3.4 Histopathological effects of CuO NPs on the kidney

Kidney sections in the control group revealed normal histological structures of the glomeruli and tubules in the cortical and medullary portions (Figure 1C). In contrast, kidney section in treated rats with CuO NPs revealed many of histopathological changes as marked atrophy of tubular cells and glomeruli and marked inflammatory cellular infiltration (Figure 1D).

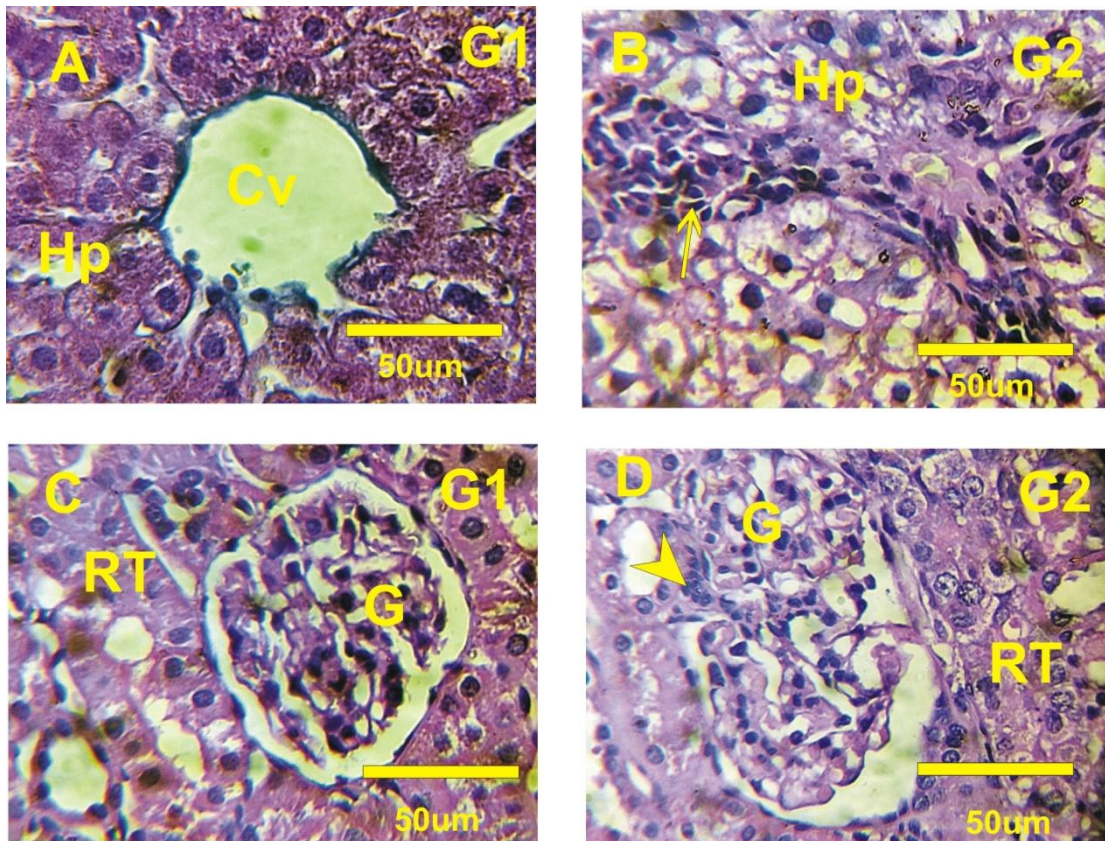


Figure 1: Liver and kidney sections in control and CuO NPs groups stained with H & E. **A:** Normal structure of liver section revealed hepatocytes (Hp) and normal central veins **B:** liver section in CuO NPs revealed marked cytoplasmic vacuolization of hepatocytes with marked inflammatory cells. **C:** Kidney sections in the control group revealed normal histological structures of the glomeruli and tubules in the cortical and medullary portions. **D:** Kidney section in treated rats with CuO NPs revealed marked atrophy of tubular cells and glomeruli and marked inflammatory cellular infiltration.

4. DISCUSSION

Exposure to CuO NPs can result in significant adverse health effects in multiple organ systems [11-13]. CuO NPs originates from various industrial and/or household sources, and enters the body through food and fluid intakes, as well as by inhalation [17,14]. In line with this, the goal of this work was to investigate renal and hepatic toxicity of copper oxide nanoparticles (CuO NPs) in male rats.

According to our findings, CuO NPs cause an increase in AST and ALT levels as well as a depletion of total proteins and albumin. These findings point to hepatic toxicity and dysfunction, and the rise in liver enzymes may be caused by free radicals generated by the copper oxide nanoparticles. Additionally, changes in protein synthesis and/or metabolism may be to blame for the drop in protein levels. These results concurred with those of Yari et al. [26], El-Magd [27], Abdelazeim et al. [28] who reported that; CuO NPs induce marked liver damage. These results concurred with those of **Yaqub et al. [29]; Elkhateeb et al. [30]** who reported that; CuO-NPs induced renal toxicity in rats and changes in liver functions.

According to our findings; CuO NPs induced marked liver injury as marked cytoplasmic vacuolization of hepatocytes with marked inflammatory cells. According to our results; CuO NPs induce increase in the level of urea, creatinine, and potassium ions while a significant decrease in the level of sodium and calcium ions as compared control group. These results mean that CuO NPs induced nephrotoxicity. These results concurred with those of **Chibber and Shanker [31]** who reported that; CuO-NPs induced renal toxicity and changes in blood parameters in mice. These results

concurrent with those of **Elkhateeb et al. [30]** who reported that; CuO-NPs induced renal toxicity in rats. Current results revealed that CuO NPs induced severe atrophy of tubular cells and glomeruli, notable necrotic tubular cells, and marked inflammatory cellular infiltration. Current findings support **Yaqub et al. [29]** who studies the evaluation of CuO-NPs acute toxicity on the changes in kidney structures in mice.

5. CONCLUSION

Copper oxide nanoparticles (CuO NPs) induced renal and liver toxicity and damage in tissues in rats

6. REFERENCE

1. Christian P., Von der Kammer F., Baalousha M. and Hofmann T. (2008): Nanoparticles: structure, properties, preparation and behaviour in environmental media. *Ecotoxicology*, 17(5): 326-343.
2. Alotaibi B, El-Masry TA, Tousson E, Alarfaj SJ, Saleh A (2020) Therapeutic effect of rocket seeds (*Eruca sativa* L.) against hydroxyapatite nanoparticles injection induced cardiac toxicity in rats. *Pak J Pharm Sci* 33: 1839-1845.
3. Altwaijry, N., El-Masry, T. A., Alotaibi, B., Tousson, E., & Saleh, A. (2020). Therapeutic effects of rocket seeds (*Eruca sativa* L.) against testicular toxicity and oxidative stress caused by silver nanoparticles injection in rats. *Environmental toxicology*, 35(9), 952-960.
4. Alotaibi, B., Tousson, E., El-Masry, T. A., Altwaijry, N., & Saleh, A. (2021). Ehrlich ascites carcinoma as model for studying the cardiac protective effects of curcumin nanoparticles against cardiac damage in female mice. *Environmental toxicology*, 36(1), 105-113.
5. Mahgoob, A. A. E., Tousson, E., Abd Eldaim, M. A., Ullah, S., Al-Sehemi, A. G., Algarni, H., & El Sayed, I. E. T. (2022). Ameliorative role of chitosan nanoparticles against silver nanoparticle-induced reproductive toxicity in male albino rats. *Environmental Science and Pollution Research*, 1-10.
6. Fahmy, B., & Cormier, S. A. (2009). Copper oxide nanoparticles induce oxidative stress and cytotoxicity in airway epithelial cells. *Toxicology in Vitro*, 23(7), 1365-1371.
7. Altwaijry, N., El-Masry, T. A., Alotaibi, B. S., Tousson, E., Alodhayani, A. A., El-Morshedy, K., ... & Saleh, A. (2021). Potential therapeutic effects of avenanthramide-C against lung toxicity caused by silver nanoparticles injection in rats. *Pakistan Journal of Pharmaceutical Sciences*, 34.
8. Singh, S. P., Mishra, A., Shyanti, R. K., Singh, R. P., & Acharya, A. (2021). Silver nanoparticles synthesized using *Carica papaya* leaf extract (AgNPs-PLE) causes cell cycle arrest and apoptosis in human prostate (DU145) cancer cells. *Biological Trace Element Research*, 199(4), 1316-1331.
9. Izzularab, B. M., Tousson, E., Abdo, N. I., & Beltagy, D. M. (2022). Curative Consequences of Rocket Seeds (*Eruca Sativa*) Extract against Lead Nanoparticles Induced Renal Dysfunction in Rats. *Biomedical and Pharmacology Journal*, 15(1), 147-156.
10. Tousson, E., Alashmouni, S., El-Atrash, A., & El-Gharbawy, D. M. (2022). The potential curative role of *Avena sativa* extract against oxidative stress, DNA damage and apoptosis induced by acute hepatotoxicity of silver nanoparticles in rats. *Environmental Toxicology*, 37(10), 2412-2418.
11. Applerot, G., Lellouche, J., Lipovsky, A., Nitzan, Y., Lubart, R., Gedanken, A., & Banin, E. (2012). Understanding the antibacterial mechanism of CuO nanoparticles: revealing the route of induced oxidative stress. *Small*, 8(21), 3326-3337.
12. Fu, X. (2015). Oxidative stress induced by CuO nanoparticles (CuO NPs) to human hepatocarcinoma (HepG2) cells. *Journal of Cancer Therapy*, 6(10), 889.

13. Tang, Y., He, R., Zhao, J., Nie, G., Xu, L., & Xing, B. (2016). Oxidative stress-induced toxicity of CuO nanoparticles and related toxicogenomic responses in *Arabidopsis thaliana*. *Environmental pollution*, 212, 605-614.
14. Roy, D., Adhikari, S., Adhikari, A., Ghosh, S., Azahar, I., Basuli, D., & Hossain, Z. (2022). Impact of CuO nanoparticles on maize: Comparison with CuO bulk particles with special reference to oxidative stress damages and antioxidant defense status. *Chemosphere*, 287, 131911.
15. Karlsson, H. L., Gustafsson, J., Cronholm, P., & Möller, L. (2009). Size-dependent toxicity of metal oxide particles—a comparison between nano- and micrometer size. *Toxicology letters*, 188(2), 112-118.
16. Wang, S., Huang, X., He, Y., Huang, H., Wu, Y., Hou, L., ... & Huang, B. (2012). Synthesis, growth mechanism and thermal stability of copper nanoparticles encapsulated by multi-layer graphene. *Carbon*, 50(6), 2119-2125.
17. Dai, Y., Wang, Z., Zhao, J., Xu, L., Xu, L., Yu, X., ... & Xing, B. (2018). Interaction of CuO nanoparticles with plant cells: internalization, oxidative stress, electron transport chain disruption, and toxicogenomic responses. *Environmental Science: Nano*, 5(10), 2269-2281.
18. Borowska, S., & Brzóska, M. M. (2015). Metals in cosmetics: implications for human health. *Journal of applied toxicology*, 35(6), 551-572.
19. Tousson, E., & El-Gharbawy, D. M. (2022). Impact of *Saussurea lappa* root extract against copper oxide nanoparticles induced oxidative stress and toxicity in rat cardiac tissues. *Environmental Toxicology*.
20. Reitman, S., & Frankel, S. (1957). A colorimetric method for the determination of serum glutamic oxalacetic and glutamic pyruvic transaminases. *American journal of clinical pathology*, 28(1), 56-63.
21. Dumas, B. T., Watson, W. A., & Biggs, H. G. (1971). Albumin standards and the measurement of serum albumin with bromocresol green. *Clinica chimica acta*, 31(1), 87-96.
22. El-Aarag B, Attia A, Zahran M, Younes A, Tousson E (2021) New phthalimide analog ameliorates CCl4 induced hepatic injury in mice via reducing ROS formation, inflammation, and apoptosis. *Saudi J Biological Sciences* 28: 6384-6395.
23. Patton, C. J., & Crouch, S. R. (1977). Spectrophotometric and kinetics investigation of the Berthelot reaction for the determination of ammonia. *Analytical chemistry*, 49(3), 464-469.
24. Tousson, E., El-Atrsh, A., Mansour, M., & Abdallah, A. (2019). Modulatory effects of *Saussurea lappa* root aqueous extract against ethephon-induced kidney toxicity in male rats. *Environmental Toxicology*, 34(12), 1277-1284.
25. Tousson, E. (2016). Histopathological alterations after a growth promoter boldenone injection in rabbits. *Toxicology and industrial health*, 32(2), 299-305.
26. Mohammadyari, A., Razavipour, S. T., Mohammadbeigi, M., Negahdary, M., & Ajdary, M. (2014). Explore in-vivo toxicity assessment of copper oxide nanoparticle in Wistar rats. *J Biol Today's world*, 3, 124-28.
27. El-Magd, M. A. (2018). Effect of naringenin and hesperidin in amelioration of copper oxide nanoparticles toxicity in rat liver. *AJMS*, 1(1), 14-18.
28. Abdelazeim, S. A., Shehata, N. I., Aly, H. F., & Shams, S. G. E. (2020). Amelioration of oxidative stress-mediated apoptosis in copper oxide nanoparticles-induced liver injury in rats by potent antioxidants. *Scientific Reports*, 10(1), 1-14.
29. Yaqub, A., Anjum, K. M., Munir, A., Mukhtar, H., & Khan, W. A. (2018). Evaluation of acute toxicity and effects of sub-acute concentrations of copper oxide nanoparticles (CuO-NPs) on hematology, selected enzymes and histopathology of liver and kidney in *Mus musculus*. *Indian Journal of Animal Research*, 52(1), 92-98.

30. Elkhateeb, S. A., Ibrahim, T. R., El-Shal, A. S., & Abdel Hamid, O. I. (2020). Ameliorative role of curcumin on copper oxide nanoparticles-mediated renal toxicity in rats: An investigation of molecular mechanisms. *Journal of Biochemical and Molecular Toxicology*, 34(12), e22593.

31. Chibber, S., & Shanker, R. (2017). Can CuO nanoparticles lead to epigenetic regulation of antioxidant enzyme system?. *Journal of Applied Toxicology*, 37(1), 84-91.

DATA AVAILABILITY

All data used in this study are included in this published article.

UNDER PEER REVIEW