

What is marked in **yellow** is the part of the article that is suggested to be corrected.

What is marked in **green** is the explanation of what must be corrected

What is marked in **blue** is the explanation of how should be corrected

Persistent Intraocular Residue with the Use of Dexycu® in Cataract Extraction: A Case Series

ABSTRACT

Purpose:

To report 8 cases of persistent intraocular residue with the use of Dexycu® extended-release dexamethasone in cataract surgery and to describe a procedure to remove the residue from the lens implant. See what is suggested in the introduction related to the objective

Observations and Presentation:

Between 2020-2021, persistent residue was noted in 8 eyes of 7 patients who received Dexycu® implants after cataract surgery. The residue was identified an average of 1.63 months after surgery (range 0.20-4.23). A subsequent procedure removed the residue from the intraocular lens; the average time to the follow-up procedure after surgery was 4.71 months (range 1.90-11.20).

Conclusions and Importance:

This is the first published report of persistent intraocular residue associated with the use of Dexycu®. We also describe the procedure we used to remove the residue in patients with significant visual symptoms. this is wrong

Keywords: Cataract Surgery; Dexycu; Residue Polish; Tano Diamond Brush

1. INTRODUCTION

Almost 28 million cataract surgeries are performed worldwide each year [1]. Efforts to improve the patient experience and surgical outcomes by targeting postoperative inflammation have yielded several methods that do not require use of postoperative eye drops. Dexycu® (Icon Bioscience Inc., Newark, CA) is a novel posterior chamber dexamethasone drug delivery suspension that has been shown to effectively control postoperative inflammation in patients for up to 21 days after cataract surgery [2]. A single vial of Dexycu® suspension is equivalent to 51.7 mg of dexamethasone suspended in a Verisome® acetyl triethyl citrate spherule (Eyepoint Pharmaceuticals, Inc. Watertown, MA) [2].

Dexycu® was approved by the FDA in 2018. Possible adverse reactions listed by the FDA include increased intraocular pressure, corneal edema, and iritis [3]. Since the approval of Dexycu®, other complications have been reported such as iris atrophy [4]. However, intraocular lens (IOL) residue associated with the use of Dexycu® has not, to our knowledge, been previously described. We present a case series of persistent IOL residue associated with the use of Dexycu® to prevent postoperative inflammation in 8 eyes of 7 patients, as well as a technique for polishing the lens when this complication arises.

As an objective it is incorrect, there cannot be two verbs, if that is the case, a general objective and other specific ones must be made, which give me an outlet for that general objective. it is at it happens with thesis work. Taken into account the title of this article, a suggested objective would be: to present a series of 8 cases of patients operated on...with residues of...and specifically... list as many as you want, provided that correspond with the type of the article you want to publish

2. METHODOLOGY

This section of the article is very important because several aspects are going to be explained that must be made very clear so that all readers are able to understand, whether or not they are from the medical community. Example: type of the article, place, realization period, description of the variables analyzed in the study, inclusion-exclusion of patients, methodology followed in the treatment, how the results obtained are expressed and how they were processed..please rewrite.

Approval to retrospectively review patient charts was obtained from the University of Utah IRB (#00146975). All patients consented to the publication of their case details and patient images were taken and shared with documented permission in their charts. Patient characteristics are summarized in Table 1.

Table 1: Patient / Surgery Characteristics

Patient ID	Gender	Eye	Age	Procedure Type	Time to Recognition (months)	Time to Polishing (months)	IOL Type
1	F	OD	61	Routine Cataract	1.63	2.93	B&L MX60E
2	M	OS	65	Combination (Hydrus®)	4.23		B&L MX60UT
3	M	OS	76	Combination (Goniotomy)	0.20	5.27	B&L MX60E
4	F	OD	79	Routine Cataract	3.90	4.37	B&L MX60UET
5	M	OD	53	Complex Cataract	0.20		B&L MX60E
	M	OS	53	Complex	0.77	1.90	B&L

				Cataract			MX60E
6	F	OS	66	Routine Cataract	0.80	2.57	B&L MX60E
7	F	OD	69	Combination (ABiC™+ Hydrus®)	1.27	11.20	B&L MX60E

These results are expressed in a section called results and not in the method and in this case it would be presentation of the cases.

In addition, each case must be well documented, that is, the 8 cases, and that includes a description of each case separately, making a detailed presentation of each patient, including age, sex, medical history, diagnosis, treatment and everything detailed. The table shown does not correspond to an article like this, here what is done is to present the series of cases, if you want to study other variables, then check the suggestion made in the objective

During 2020-2021, Dexycu was billed 1,076 times in conjunction with cataract surgery at the Moran Eye Center. Of these patients, postoperative persistent residue was noted in 8 eyes of 7 patients. The median age of patients with residue was 66 years (range 53-79). Regarding surgery type, 3 eyes underwent routine phacoemulsification with IOL placement, 3 underwent combination procedures (e.g. ABiC™+Phaco+IOL), and 2 underwent complex phacoemulsification with IOL placement (e.g. complicated by synechialysis).

Patients received a 0.3 mL injection of lidocaine with epinephrine. The phacoemulsification was performed with 500 mL of Omidria® phenylephrine/ketorolac infusion (Omeros Corp., Seattle, WA). After lens removal, 0.1 mL of intracameral moxifloxacin was administered. The viscoelastic used in all 8 cases was DisCoVisc® (Alcon, Geneva, Switzerland). Six eyes received monofocal MX60E lenses (Bausch + Lomb, Bridgewater, NJ) and 2 eyes received toric lenses, the MX60UT125 and MX60UET350 (Bausch + Lomb, Bridgewater, NJ). A Dexycu® pellet was placed posterior to the iris in all patients per manufacturer specifications.

The average time from surgery to the discovery of the residue was 1.63 months (range 0.20-4.23). Of the 8 eyes with residue, 6 underwent the polishing procedure. The average time between the initial surgery and the polishing procedure was 4.71 months (range 1.90-11.20). Figures 1 and 2 provide pictures of the residue as it appeared under slit-lamp examination.

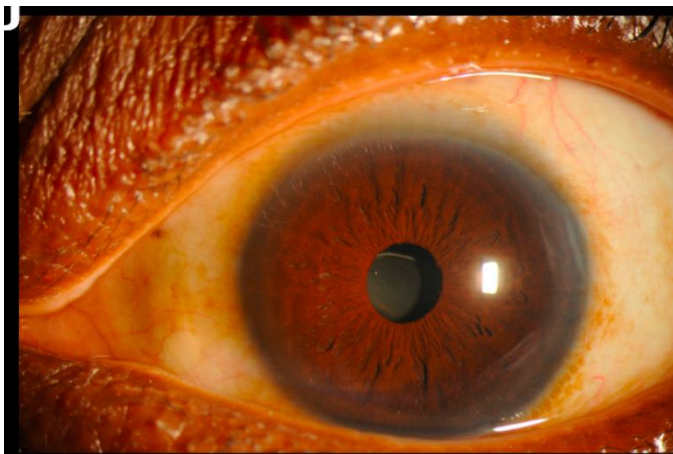


Figure 1. Patient ocular residue photo 1 from which patient???

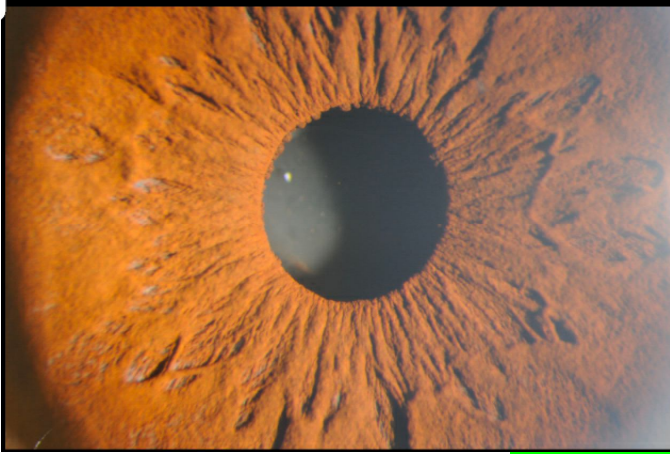


Figure 2. Patient ocular residue photo 2 **from which patient???**

2.1 Description of IOL Polishing Procedure

Two paracentesis incisions were made with a 1 mm diamond blade. Lidocaine was injected into the anterior chamber followed by DisCoVisc® (Alcon Inc., Geneva, Switzerland). The 23g Tano diamond brush (Synergetics Inc., O'Fallon, MO, US) was used to polish the residue from the anterior surface of the intraocular lens. Once the residue was removed, bimanual irrigation/aspiration was used to remove viscoelastic from the anterior chamber. Moxifloxacin was injected into the anterior chamber and surgical wound integrity was confirmed. Topical betadine, brimonidine, and antibiotic drops were placed on the corneal surface at the conclusion of the procedure. The video for this procedure can be provided as supplementary material.

3. **RESULT** AND DISCUSSION

THIS TYPE OF ARTICLE DOES NOT SHOW RESULTS, IT ONLY PRESENTS THE SERIES OF CASES

THE MOST RELEVANT ASPECTS ARE DISCUSSED IN HIS SERIES OF CASES AND IN CORRESPONDENCE WITH THE OBJECTIVES

The finding of persistent intraocular lens residue associated with the use of Dexycu® has not, to our knowledge, been previously published prior to this case series.

Adhesion of foreign material to artificial intraocular lenses is a well-known phenomenon, with calcifications and silicone oil being identified as common culprits in various case studies [5-12]. An experimental study by Kageyama and Yaguchi showed that silicone oil was most likely to interact with silicone IOLs and least likely to interact with hydrophobic acrylic lenses [9]. In the aqueous milieu of the posterior chamber, the hydrophobic Verisome® spherule of Dexycu® could promote the precipitation of residue on a hydrophobic IOL. In this case series, the depositions observed involved the acrylic hydrophobic lenses B&L MX60 and its toric varieties.

Further studies will be required to elucidate if there is a molecular interaction between the MX60 hydrophobic lenses and Dexycu®. It is important to note that of the 8 surgeries, 5 surgeries involved additional procedures or ocular comorbidities. Further inquiry is necessary to determine whether there may be a relationship between the presence of residue and the type of surgery or pre-existing pathology.

This case series also describes utilizing a Tano diamond brush to delicately polish the IOL without compromising the optical quality of the lens. The risks of an additional procedure must be evaluated in the context of benefit to the individual patient. In our cohort, two of the eyes did not undergo polishing because the risks of the additional procedure exceeded the potential benefit to the patient.

4. CONCLUSION

This case series documents the first reported cases of persistent IOL residue with the use of Dexycu® in 8 eyes of 7 patients. Although all the patients who experienced this complication had MX60 lenses and its toric varieties, the relationship between the composition of the Dexycu® suspension and these lenses remains unclear. We also described a procedure to remove this residue without damage to the IOL. This is not a conclusion, what could emerge from here, in relation to new elaborated objectives, would be, if the suggested technique worked or not and that would be another article.

REFERENCES

I suggest to update the bibliography

1. Lindstrom RL. Future of Cataract Surgery Seems Promising. *Ocular Surgery News*. Thorofar, NJ: Healio Ophthalmology; 2021.
2. Donnenfeld E, Holland E. Dexamethasone Intracameral Drug-Delivery Suspension for Inflammation Associated with Cataract Surgery: A Randomized, Placebo-Controlled, Phase III Trial. *Ophthalmology*. Jun 2018;125(6):799-806. doi:10.1016/j.ophtha.2017.12.029
3. Harris JD. *Clinical Review: Dexycu*. 2017:1-56. Reference ID: 4194949. https://www.accessdata.fda.gov/drugsatfda_docs/label/2018/208912s000lbl.pdf
4. Bergman Z, Thompson R, Malouf A, Swamy R. Iris Atrophy After Administration of Intracameral Dexycu in Routine Cataract Surgery: A Case Series. *Eye Contact Lens*. Dec 16 2021;doi:10.1097/ICL.0000000000000873
5. Apple DJ, Isaacs RT, Kent DG, et al. Silicone oil adhesion to intraocular lenses: an experimental study comparing various biomaterials. *Journal of cataract and refractive surgery*. May 1997;23(4):536-44. doi:10.1016/s0886-3350(97)80210-6
6. Horgan SE, Cooling RJ. Irreversible silicone oil adhesion. *Ophthalmology*. Jun 1997;104(6):898-900. doi:10.1016/s0161-6420(97)38951-9
7. Hu CL, Peng KL. Removal of silicone oil droplets adhering to the posterior surface of an intraocular lens (IOL). *Int Med Case Rep J*. 2018;11:157-159. doi:10.2147/IMCRJ.S167722
8. Kageyama T, Yaguchi S. Removing silicone oil droplets from the posterior surface of silicone intraocular lenses. *Journal of cataract and refractive surgery*. Jul 2000;26(7):957-9. doi:10.1016/s0886-3350(00)00306-0
9. Oner FH, Saatci OA, Sarioglu S, Durak I, Kaynak S, Cabuk M. Interaction of intraocular lenses with various concentrations of silicone oil: an experimental study. *Ophthalmologica*. Mar-Apr 2003;217(2):124-8. doi:10.1159/000068561
10. Sakimoto S, Tsukamoto Y, Saito Y. Removal of silicone oil droplet adhering to a silicone intraocular lens using 25-gauge instrumentation. *Journal of cataract and refractive surgery*. Feb 2009;35(2):383-5. doi:10.1016/j.jcrs.2008.07.041
11. Zeana D, Schrage N, Kirchoff B, Wenzel M. Silicone oil removal from a silicone intraocular lens with perfluorohexyloctane. *Journal of cataract and refractive surgery*. Feb 2000;26(2):301-2. doi:10.1016/s0886-3350(99)00350-8
12. Rahimi M, Azimi A, Hosseinzadeh M. Intraocular Lens Calcification: Clinico-pathological Report of Two Cases and Literature Review. *J Ophthalmic Vis Res*. Apr-Jun 2018;13(2):195-199. doi:10.4103/jovr.jovr_36_16