

## **Developing of a Healing Formulation Able to Prevent Scar Hypertrophy**

**Abstract**

Derangement of the processes regulating wound healing leads to leads of esthetical and functional problems, and its prevention still represents an unmet therapeutic need. Several compounds are endowed with the ability to redirect the healing process, and prevent excessive fibroblast proliferation, scar hypertrophy as well as keloids. In the present study, we evaluated the healing and anti-inflammatory effects of topical applications of a multicomponent healing formulation (MHF) containing bromelain, onion extracts, glycyrrhizin, snail mucus as well as vitamin E and A in a mouse model of scar hypertrophy. Daily topical application of the MHF had no effect on the healing rate. Still, the MHF significantly reduced the wound inflammatory response as evidenced by reduced expression of pro-inflammatory cytokine IL1 $\beta$ , IL6 and TNF $\alpha$  in the granulation tissue of mice exposed to MHF compared to control animals. In keeping with this, histological analysis of the scars showed that those from MHF-challenged mice were less hyperplastic, with reduced abnormal collagen deposition and, overall, appeared more hydrated and with higher conservation of tissue organization. The present study, on the one hand indicates that the MHF may be harnessed to prevent evolution of the healing process toward scar hypertrophy or keloids in patients, and on the other that a multicomponent strategy is a rational approach to developing topical remedies to prevent abnormal wound healing.

**Keywords:** Scar hypertrophy, Wound healing, Inflammation, Glycyrrhizin, Bromelain, Snail mucus.

## **Introduction**

There is large consensus that the pleiotypic and dynamic process involved in cutaneous wound healing can be grouped into three different but in part overlapped phases such as a first inflammatory response, a second process characterized by new tissue deposition, and a final event of tissue remodeling (1). Different pathophysiological events and genetic predisposition can turn these processes normally leading to normal asymptomatic scars into healing dynamics evolving into cosmetically unacceptable scars. Of note, in addition to derangement of scar morphology, these abnormal scars often represent a critical clinical problem given that are associated with local discomfort, itch, pain, and, according to the site, functional impairment (2).

Given the relevance of the clinical implications of abnormal cutaneous wound healing, a great deal of effort has been focused at identifying therapeutic interventions for scar treatment. Among them, therapeutic strategies such as cryotherapy, surgical excision, radio- or laser therapy as well as steroid injection are currently adopted (1,3). Unfortunately, these treatments require several therapeutic sessions and show low compliance. There is large consensus, therefore, that prevention of derangement of the healing processes is of the utmost importance to reduce the risk of abnormal scar evolution into hypertrophic scars and keloids (4).

In this light, different preventatives are routinely used in topical scar treatment. Among them, onion extracts are endowed with anti-inflammatory and bacteriostatic properties, as well as with the ability to counteract collagen deposition and excessive fibroblast proliferation. Clinical evidence shows that such extracts counteract surgical scar hypertrophy and improve its texture and overall morphology (5-7). Bromelain is a crude extract from pineapple containing several proteases and additional flavonoids used for different human disorders including treatment of edema and inflammation. Several lines of evidence demonstrate a beneficial effect of bromelain in preventing abnormal healing of skin lesions. Although the exact mechanisms of action have not clearly identified, it has been postulated that the protease content of the extract allows enzymatic debridement, angiogenic control

as well as prevention of excessive inflammatory response and ensuing anomalous collagen deposition (8-11). Sterile inflammation a key event accompanying every process of tissue repair. Even though it is central in danger signaling during wound healing by promoting immune cell recruitment and activation, excessive and/or prolonged signaling can prompt chronicization of inflammation with ensuing derangement of scar formation. Among the different players involved in danger signaling, the high mobility group Box-1 (HMGB1) protein represents a key executioner of sterile inflammation and its targeting through different means provides protection in several models of excessive immune activation (12-13). In keeping with this, Glycyrrhizin, a key triterpene in the extract of *Glycyrrhiza glabra* able to bind and inactivate HMGB1, counteracts sterile inflammation and prevents abnormal wound healing by regulating, in addition to immune cells, extracellular matrix deposition, angiogenesis and fibroblast proliferation (14-18). Recently, the use of pharmaceutical preparations from snail mucus for different skin disorders received great momentum (19). As far as wound healing is concerned, several lines of evidence demonstrate that snail mucus assists scar repair thanks to its high content in mucopolysaccharides that form a sort of barrier to dehydration and microbial contamination (20). In addition to these physicochemical properties, topical application of snail mucus during wound healing regulates fibroblast proliferation and migration, immune cell activation also protecting from oxidative stress (21). The latter has been repeatedly identified as a causative factor of hypertrophic scars and keloids (22-23). This is in keeping with both the cytotoxic potential of oxygen radicals, as well as with their proinflammatory properties. The pathogenetic role of oxygen radical in hypertrophic scars is further confirmed by the ability of vitamin E to improve wound healing after surgery and improve survival of skin flap (24-25). In this regard, even the topical administration of vitamin A, a key regulator of cell differentiation and proliferation, provides protection from hypertrophic scar formation thanks to its potent cell differentiation signaling that counteracts excessive fibroblast and vessel proliferation (26-29).

Of note, in spite of evidence of the ability of several agents of counteracting derangement of the skin healing process, there is lack of information on the effects of formulations containing multiple molecules endowed with scar-regulating properties. Remarkably, synergism among the different mechanisms of action of the above-mentioned compounds might significantly boost the overall ability to prevent scar evolution towards hypertrophy or keloid. Hence, in the present study we evaluated the effects of a formulation containing onion extracts, bromelain, glycyrrhizic acid, snail mucus as well as vitamins E and A, on several parameters of the skin healing process in mice.

Studies involving animals must have been approved by the authors' Institutional Animal Care and Use Committee (IACUC) or equivalent ethics committee and must follow internationally recognized guidelines such as the [ARRIVE guidelines](#). Please address the following aspects in your Statement of Ethics.

## **Materials and Methods**

### **Animals and drug administration**

All animal manipulations were internally approved by the director of the animal facility (CESAL) and performed according to the European Community guidelines for animal care (DL 116/92, application of the European Communities Council Directive 86/609/EEC). Adult male C57B16 mice 20-25 g (Charles River, Milan, Italy) were maintained 5 per cage in a climate-controlled room at  $23\pm 2^{\circ}\text{C}$  on a 12-hour light/dark cycles with free access to food and water. The day of surgery, a 3x3 mm dorsal skin flap was excised in mice after depilation and anesthesia with isoflurane. Subsequently, the skin wound was allowed to heal by second intention. A group of 10 animals was treated with the multicomponent healing formulation (MTF), applied topically 3 times a day during daylight hours, whereas the control group received no treatment.

### **Evaluation of the temporal kinetics of wound repair**

The speed of wound repair was evaluated in animals treated with the MTF compared with controls. For every mouse, the wound area was evaluated daily by computer-aided area measurement acquiring

a picture of the wound followed by software analysis. Data are reported as the mean $\pm$ SEM of the areas of the wounds in the two groups of animals.

### **Real Time-PCR**

Expression levels of inflammatory cytokines (IL1 $\beta$ , IL6 and TNF $\alpha$ ) were assessed by quantitative real time (RT)-PCR 4 days after skin excision. Mice (n=5 per group) were euthanized and a skin fragment of the wound border was excised and frozen at -80 °C. Later on, skin fragments were thawed in Trizol Reagent (Life Technologies) and RNA extracted according to the manufacturer's instruction. One  $\mu$ g of RNA was retrotranscribed using iScript (Bio-Rad Milan Italy). PCR amplification was carried out by means of SsoAdvanced<sup>TM</sup> Universal SYBR<sup>®</sup> Green Supermix (Bio-Rad, USA) according to manual instruction using the RotorGene 3000 Instrument (Qiagen Germany). Ribosomal 18s rRNA was used as the normalizer. Quantitative PCR was performed using the following procedure: 98°C for 1 min, 40 cycles of 98°C for 5 sec, 60°C for 15 sec. The program was set to reveal the melting curve of each amplicon from 60°C to 95°C with a read every 0.5°C. The following primers were used: TNF $\alpha$ : forward 5'-GGCATGCGGCCTCCAGGCAG-3' and reverse 5'-AGAGCCCTCAGCCTCCTGTTCT-3'; IL1 $\beta$ : forward 5'-TGGACCTTCCAGGATGAGGACA-3', reverse 5'-GTTCATCTCGGAGCCTGTAGTG-3'; IL6 forward 5'-TACCACTTCACAAGTCGGAGGC-3' and reverse 5'-CTGCAAGTGCATCATCGTTGTTC-3', 18S forward 5'-GGACCAGAGCGAAAGCATTGCC-3', reverse 5'-TCAATCTCGGGTGGCTGAACGC-3'.

### **Histological evaluation of the scar**

The effect of the MTF on tissue organization of the wound was evaluated in mice 6 days after skin incision by means of histological investigation. Specifically, the picosirius red technique for the staining of collagen fibers and consecutive counterstaining with hematoxylin-eosin was evaluated.

Briefly, mice were euthanized with isoflurane overdose and the scar excised and fixed in 4% formalin/PBS. Two days later, they were ethanol-dehydrated, diaphanized with xylene for one day. Later on they were paraffin embedded and cut in 5  $\mu$ m thick slices, mounted on slips. Collagen fiber staining and hematoxylin/eosin counterstaining was performed as previously described (30).

## **Data analysis**

All numerical data are expressed as mean  $\pm$  SEM. The Shapiro-Wilk analysis was first conducted for the analysis of normality. For gene expression analysis, data were evaluated by means of ANOVA plus Tukey's post hoc test. p values lower than 0.05 were considered statistically significant.

## **Results**

### **Effects of the MTF on kinetics of skin wound repair**

We first analyzed whether the daily application of the formulation altered the temporal kinetics of wound healing. The dorsal wound was allowed to heal by second intention, a protocol typically leading to scar hypertrophy because of the continuous tearing of the dorsal skin and wound margins during spontaneous mouse motor activity. As shown in Fig. 1A, the area of the cutaneous lesion progressively diminished reaching an almost complete recovery within 6 days in control mice. Of note, an identical temporal evolution of wound healing occurred in mice receiving the topical application of the healing formulation.

### **Effects of the MTF on cytokine expression in the wounded skin**

In light of the key pathogenetic role of inflammation in the process leading to scar hypertrophy (31), and also considering the anti-inflammatory potential of several components of the healing formulation, we then investigated whether the latter alters the inflammatory response during skin healing. To this end, we focused on the expression levels of proinflammatory cytokines as markers

of the extent of the inflammatory response within the granulation tissue of the wound. As shown in Fig. 1B, we found that transcript levels of IL1 $\beta$ , IL6 and TNF $\alpha$  significantly increased in the granulation tissue of the wound healing by second intention at day 4 after skin incision. Of note, such an increase was significantly reduced in the wounds of mice treated with the healing formulation. It is also worth noting, however, that the treatment did not revert cytokine expression levels to those of uninjured skin (Fig. 1B).

### **Effects of the MTF on histological organization of the scar**

The ability of the healing formulation to affect the extent of the inflammatory process within the granulation tissue of the skin wound was an index of its bioactivity. To further investigate the impact of the healing formulation on the process leading to scar hypertrophy, we also histologically analyzed the wound at the end of healing (day 6). As expected, the scar of control mice appeared hypertrophic, with widespread disruption of tissue architecture, in keeping with the skin healing process by second intention. The cytoarchitecture of the epidermal layer also appeared disrupted and irregular because of numerous, underlying hyperplastic dermal processes. Of note, scars are invaded by processes of collagen fibers that begin to be deposited from the periphery of the scar (Fig. 2A and B). Concentric formations of collagen deposits can be seen within the dermal layer, reminiscent of the hyaline collagen structures typical of scar hypertrophy and keloids. In keeping with this, higher magnifications (40X) demonstrated that collagen deposition reaches the layer of the epidermis (Fig. 2C). Remarkably, scar tissue organization appeared significantly different in mice challenged with the daily treatment with the healing formulation. Specifically, within the scar we found an overall reduction of the hyperplastic elements present in scars of untreated mice. As far as the arrangements of the epidermal layer is concerned, at variance with the scars of control mice, we found that in mice receiving the healing formulation it appeared much more preserved and showed no structural disruption caused by dermal hyperplasia. In addition, both the intensity and the extent of collagen

fiber deposition at the edges of the scar were lowered by the treatment with the healing formulation (Fig. 2D and E). It is also interesting to note that, in line with the moisturizing-emollient properties of the product, the dermal layer appeared more hydrated. At higher magnification (40X), a lack of collagen deposition is noted in the regions below the epidermis (Fig. 2F). It is also worth noting that histologic preparations of scars from mice exposed to the healing formulation also demonstrated a presence of amorphous material containing tissue debris lining the scar surface. In first hypothesis, this might be interpreted as the deposition of mucopolysaccharides contained in snail mucus.

## **Discussion**

The present study for the first time demonstrates that a formulation containing multiple agents endowed with cytoprotective and anti-inflammatory properties provides significant protection from scar hypertrophy. In particular, we report that daily treatment of mice with the healing formulation reduces the expression of proinflammatory cytokines IL1 $\beta$ , IL6 and TNF $\alpha$  within the granulation tissue during wound healing. Of note, these acute phase cytokines have a central role in maintaining immune activation of myeloid cells such as macrophages and granulocytes, as well as in the activation of fibroblast proliferation and collagen deposition (31-32). The anti-inflammatory effects of the formulation is well in keeping with the ability of bromelain to counteract the inflammatory response (11), as well as with the key role of glycyrrhizin, a HMBG1-scavenging agent, in dampening danger signaling originating from tissue damage during wound formation and healing (12). The additional cytoprotective properties due to both vitamin E and the snail mucus can further assist the healing process and reduce the inflammatory component. In this regard, it is worth noting that the snail mucus may have also reduced inflammation by providing a sort of barrier to external agents including pathogens somehow shielding the granulation tissue from external noxae that delay healing by second intention. Indeed, such a mechanical barrier, mainly ascribed to accumulation of the mucopolysaccharide and proteoglycan components of the snail mucus upon repetitive topical application, is well in keeping with the presence

of amorphous material lining the scars of mice treated with the healing formulation (see Fig. 2D and E). This finding on the one hand corroborates the hypothesis of the barrier-forming ability of the snail mucus, and on the other clearly indicates the strength of such a barrier that is so firmly attached to the scar surface to be able to resist to initial paraformaldehyde scar fixation and the following steps of the histological staining procedure. It is also worth mentioning that the mucopolysaccharide barrier originating from the snail mucus may have also warranted dehydration of the scar, a key properties that have contributed to prevention of hypertrophy. This is in keeping with the preservation of the morphology of the epidermidis as well as with the lack of collagen deposition beneath the epidermidis itself. An additional key role in preventing abnormal/excessive collagen deposition and scar hypertrophy could be also ascribed to Vitamin A present in the healing formulation. Indeed, several lines of evidence indicate that retinoic acid is able to improve the healing process by regulating miofibroblast activation, matrix deposition and scar distensibility. In keeping with this, retinoic acid counteracts both hypertrophic and atrophic acne scars also promoting TGF $\beta$  signaling (26), the latter being a key event involved in resolution of inflammation. In this this light, the ability of the onion extract to regulate extracellular matrix apposition through metalloproteinase-1 can further contribute to prevent scar hypertrophy (5). Of note, in spite of the ability of the healing formulation to affect scar histology as well as the extent of the inflammatory response, we did not find evidence for an impact on the healing rate (see Fig 1A). In this regard, we reason that this finding might be well interpreted considering that the different components of the formulation do not have the ability to promote cell proliferation. Actually, some of them, such as vitamin A, potently trigger cell differentiation (33-34), an event that *per se* counteracts proliferation. Even scavenging HMGB1 with glycyrrhizin prevents the angiogenic properties of the allarmin, an effect that is at odds with an acceleration of the healing process. Possibly, therefore, the ability of the formulation to counteract signaling involved in vessel and fibroblast proliferation underlies, at least in part, its overall preventing effect on scar hypertrophy. Remarkably, evidence for a lack of

changes in the healing rate way also be interpreted as evidence of the good safety index of the formulation.

## **Conclusions**

As a whole, the present study suggests that the concomitant effects of the several compounds present in the healing formulation concur to prevent derangement of the healing process by second intention towards hypertrophy, allowing reconstitution of a skin structure that more closely reproduces the histological parameters of the healthy skin. Likely, indeed, the various bioactive properties of the agents present in the healing formulation can give birth to a therapeutic synergism leading to a mutual enhancement of the properties of the single components.

## References

1. Reinke JM, Sorg H (2012) Wound repair and regeneration. *Eur. Surg. Res.* 49
2. Kim SW (2021) Management of keloid scars: noninvasive and invasive treatments. *Arch Plast Surg* 48:149–157.
3. Chen MA, Davidson TM (2005) Scar management: Prevention and treatment strategies. *Curr. Opin. Otolaryngol. Head Neck Surg.* 13.
4. Sidgwick GP, McGeorge D, Bayat A (2015) A comprehensive evidence-based review on the role of topicals and dressings in the management of skin scarring. *Arch. Dermatol. Res.* 307.
5. Cho JW, Cho SY, Lee SR, Lee KS (2010) Onion extract and quercetin induce matrix metalloproteinase-1 in vitro and in vivo. *Int J Mol Med* 25.
6. Pińska M, Zebrowska ME, Półocka-Olech L, et al (2014) Effect of enoxaparin and onion extract on human skin fibroblast cell line—Therapeutic implications for the treatment of keloids. *Pharm Biol* 52.
7. Conti V, Corbi G, Iannaccone T, et al (2020) Effectiveness and Tolerability of a Patch Containing Onion Extract and Allantoin for Cesarean Section Scars. *Front Pharmacol* 11.
8. Mataro I, Delli Santi G, Palombo P, et al (2017) Spontaneous healing and scar control following enzymatic debridement of deep second-degree burns. *Ann Burns Fire Disasters* 30:
9. Sahbaz A, Aynioglu O, Isik H, et al (2015) Bromelain: A natural proteolytic for intra-abdominal adhesion prevention. *Int J Surg* 14.
10. Pavan R, Jain S, Shraddha, Kumar A (2012) Properties and Therapeutic Application of Bromelain: A Review. *Biotechnol Res Int* 2012.
11. Fitzhugh DJ, Shan S, Dewhirst MW, Hale LP (2008) Bromelain treatment decreases neutrophil migration to sites of inflammation. *Clin Immunol* 128.
12. Tsung A, Tohme S, Billiar TR (2014) High-mobility group box-1 in sterile inflammation. *J. Intern. Med.* 276.
13. Sims GP, Rowe DC, Rietdijk ST, et al (2010) HMGB1 and RAGE in inflammation and cancer. *Annu. Rev. Immunol.* 28.
14. Stronati L, Palone F, Negroni A, et al (2019) Dipotassium glycyrrhizate improves intestinal mucosal healing by modulating extracellular matrix remodeling genes and restoring epithelial barrier functions. *Front Immunol* 10.
15. Jeon YR, Roh H, Jung JH, et al (2019) Antifibrotic effects of high-mobility group box 1 protein inhibitor (glycyrrhizin) on keloid fibroblasts and keloid spheroids through reduction of autophagy and induction of apoptosis. *Int J Mol Sci* 20.
16. Kotian SR, Bhat KMR, Padma D, Pai KSR (2019) Influence of traditional medicines on the

- activity of keratinocytes in wound healing: An in-vitro study. *Anat Cell Biol* 52.
17. Kim J, Park JC, Lee MH, et al (2018) High-mobility group box 1 mediates fibroblast activity via RAGE-MAPK and NF- $\kappa$ B signaling in keloid scar formation. *Int J Mol Sci* 19.
  18. Hung CF, Hsiao CY, Hsieh WH, et al (2017) 18 $\beta$ -glycyrrhetic acid derivative promotes proliferation, migration and aquaporin-3 expression in human dermal fibroblasts. *PLoS One* 12.
  19. Bonnemain B (2005) Helix and drugs: Snails for western health care from antiquity to the present. *Evidence-based Complement. Altern. Med.* 2
  20. Gentili V, Bortolotti D, Benedusi M, et al (2020) HelixComplex snail mucus as a potential technology against O<sub>3</sub> induced skin damage. *PLoS One* 15.
  21. Trapella C, Rizzo R, Gallo S, et al (2018) HelixComplex snail mucus exhibits pro-survival, proliferative and pro-migration effects on mammalian fibroblasts. *Sci Rep* 8.
  22. Hokynková A, Babula P, Pokorná A, et al (2019) Oxidative stress in wound healing – current knowledge. *Ces a Slov Neurol a Neurochir* 82.
  23. Zhao M, Zhou J, Chen YH, et al (2018) Folic acid promotes wound healing in diabetic mice by suppression of oxidative stress. *J Nutr Sci Vitaminol (Tokyo)* 64.
  24. David Chang CW, Russell Ries W (2001) Nonoperative techniques for scar management and revision. *Facial Plast Surg* 17.
  25. Tanaydin V, Conings J, Malyar M, et al (2016) The role of topical Vitamin E in scar management: A systematic review. *Aesthetic Surg. J.* 36
  26. Shao Y, He T, Fisher GJ, et al (2017) Molecular basis of retinol anti-ageing properties in naturally aged human skin in vivo. *Int J Cosmet Sci* 39.
  27. Chandrashekar B, Ashwini K, Vasanth V, Navale S (2015) Retinoic acid and glycolic acid combination in the treatment of acne scars. *Indian Dermatol Online J* 6.
  28. Lateef H, Abatan OI, Aslam MN, et al (2005) Topical pretreatment of diabetic rats with all-trans retinoic acid improves healing of subsequently induced abrasion wounds. *Diabetes* 54.
  29. Dematte MF, Gemperli R, Salles AG, et al (2011) Mechanical evaluation of the resistance and elastance of post-burn scars after topical treatment with tretinoin. *Clinics* 66.
  30. Lattouf R, Younes R, Lutomski D, et al (2014) Picosirius Red Staining: A Useful Tool to Appraise Collagen Networks in Normal and Pathological Tissues. *J Histochem Cytochem* 62.
  31. Ogawa R (2017) Keloid and hypertrophic scars are the result of chronic inflammation in the reticular dermis. *Int. J. Mol. Sci.* 18
  32. Wong VW, Gurtner GC, Longaker MT (2013) Wound healing: A paradigm for regeneration. In: *Mayo Clinic Proceedings*

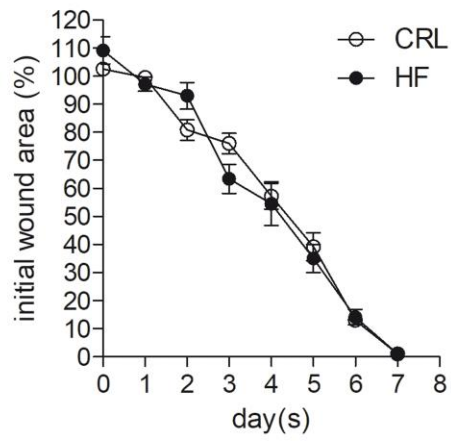
33. Polcz ME, Barbul A (2019) The Role of Vitamin A in Wound Healing. *Nutr. Clin. Pract.* 34
34. Szymański Ł, Skopek R, Palusińska M, et al (2020) Retinoic Acid and Its Derivatives in Skin. *Cells* 9

### Figure legends

**Figure 1. Effects of the healing formulation on the healing rate and cytokine expression of a dorsal skin wound in mice.** (A) Time course of the healing rate of a dorsal skin wound in mice left untreated (CRL) or daily treated with a topical application of the healing formulation (HF). (B) Transcript levels of proinflammatory cytokine IL1 $\beta$ , IL6 and TNF $\alpha$  within healthy dorsal skin (HS) or the granulation tissue of dorsal skin wounds (day 4 after skin incision) of mice untreated (CRL) or daily exposed to topical application of the multicomponent healing formulation (MHF). Each point/column represents the mean  $\pm$  SEM of 10 mice per group. \* $p < 0.05$ , \*\* $p < 0.01$  vs CRL, # $p < 0.05$  vs MHF. ANOVA plus Tukey's post hoc test.

**Figure 2. Effects of the MHF on scar histological organization.** The histological organization of representative scars of control and MHF-treated mice at day 7 is shown. In control mice (A-C) note the irregularities of the epidermal layer, the underlying hyperplastic dermal processes as well as the widespread deposit of collagen fibers (red) in keeping with healing by second intention. In (C), higher magnification (40X) of the inset in (B) shows that collagen deposition reach the layer of the epidermis in the scar of control mice. In MHF-treated animals (D-F), the scar shows a more preserved epidermal layer, reduced dermal hyperplasia, higher hydration and reduced extent of collagen fiber deposition. In (F), higher magnifications (40X) of the inset in (E), shows lack of collagen deposition in the regions below the epidermis. Note the presence of amorphous material containing tissue debris lining the scar surface of MHF-treated mice. Bar = 60  $\mu$ m.

A



B

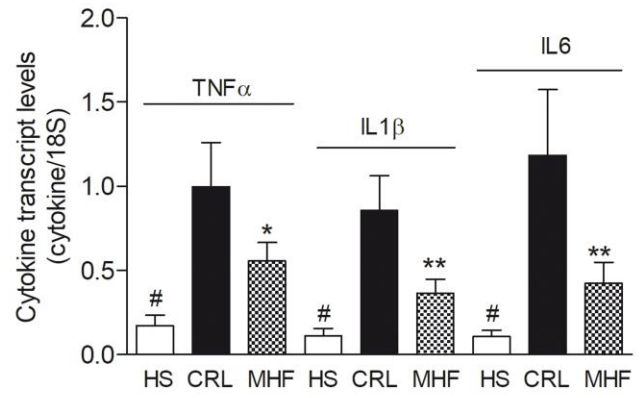


Figure 1

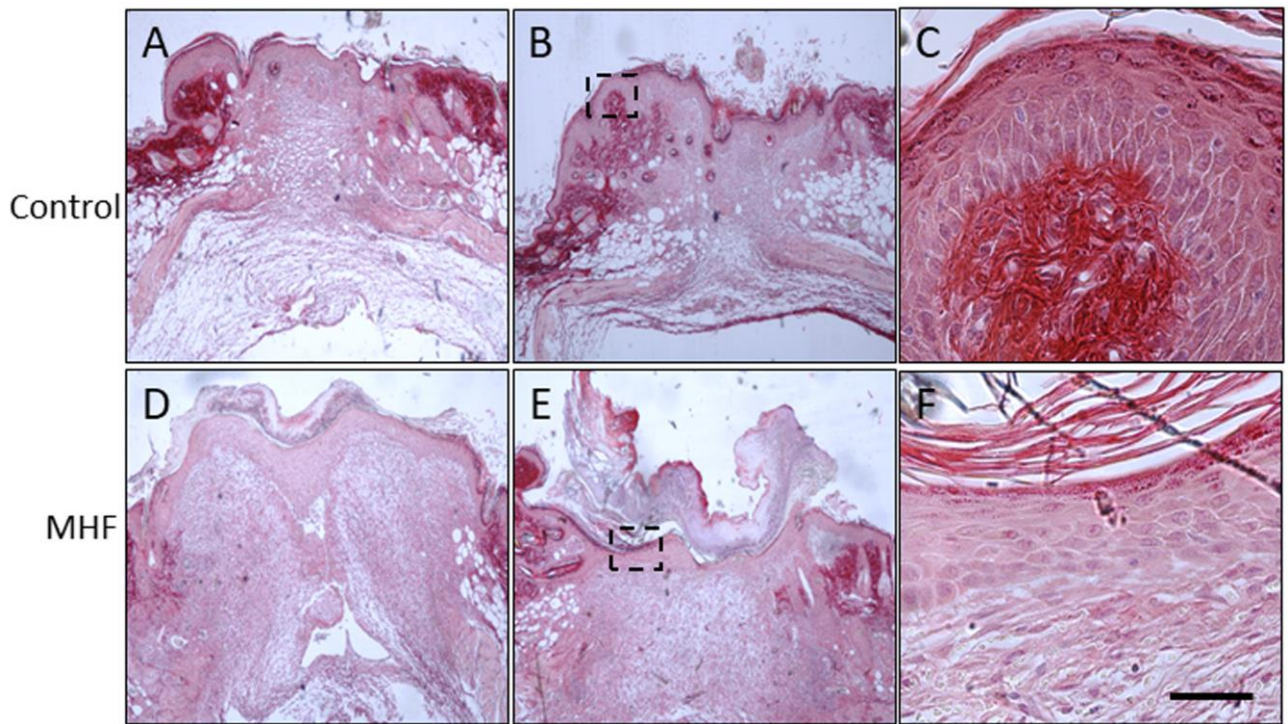


Figure 2