

Original Research Article

Assessment Of The Effect Of *Cocos nucifera* (Coconut) Milk On Testosterone Level And Testes Of Male Albino Rats

Comment [L1]: Scientist name after species

ABSTRACT

Aims:This study was designed to investigate the effect of consumption of aqueous and methanol extracts of *Cocos nucifera* (coconut) milk on the testosterone levels and testes of male albino wistar rats.

Study design:A 15-day experimental study.

Place and Duration of Study:Animal House and Department of Medical Laboratory Science, College of Medicine, University of Nigeria, Enugu Campus, between May 2019-November 2019

Methodology:Twenty five adult male albino rats were divided into five groups (I-V) of five rats each. Rats in group I received only water and standard feed throughout the experiment and served as control. Groups II and III received 163mg/kg and 326mg/kg of methanol extract of coconut milk (MECM) respectively, while group IV and V received 110mg/kg and 220mg/kg of aqueous extract of coconut milk (AECM) for two weeks. Upon completion of extract administration, the blood samples of the rats were obtained for estimation of serum testosterone. The animals were sacrificed and the testes excised, weighed and fixed in 10% formal saline for 48hours prior to paraffin embedding for histological processing. Testes sections were processed and stained using the Haematoxylin and Eosin (H&E) technique for light microscopical examination.

Results:There was no significant difference in the relative testicular weight between the "control" and "treatment" groups following oral administration of MECM and AECM to rats. Similarly, there was no discernible variation in the testosterone levels between the "control" and "test" groups. Testicular histology showed normal seminiferous tubule with mild germinal epithelial sloughing, hence no increased spermatogenesis was observed in the experimental group.

Conclusion:extracts of *cocos nucifera* milk had no significant short term effects on the testicular weight and the testosterone level of male Albino rats. In addition, extracts of *cocos nucifera* milk at these doses may cause mild morphological alterations in the testes of rats.

Comment [L2]: Why methanol extract was chosen and would it doesn't cause any effect on stomach

Comment [L3]: On what aspects the concentration was taken as dose for animal study?

Comment [L4]: Same comment as mentioned for methanol extract.

Comment [L5]: First letter in caps

Comment [L6]: Alterations is either acute or severe

Keywords: *Cocos nucifera*, Testes, relative testicular weight, testosterone level, seminiferous tubule

1. INTRODUCTION

Coconut (*Cocos nucifera*) is one of the world's most beneficial trees, supplying nourishment for millions of people, particularly in the tropical and subtropical regions, and is often referred to as the "tree of life" because of its various uses [1].

Coconut milk is a milky-white, opaque liquid made from the grated pulp of ripe coconuts. Coconut milk's opacity and rich flavor are attributable to its high oil content, which is mostly saturated fat, half of which is lauric acid [2]. It also contains nutrient-rich contents e.g. carbohydrates such as sugar and dietary fibers; minerals such as magnesium, calcium, iron, manganese, phosphorus, potassium, sodium and zinc, as well as vitamins B1, B3, B5, B6, B9 and C [3].

The male factor is responsible for 20 to 70% of all occurrences of infertility [4]. Vitamin C, one of the antioxidants found in coconut milk, aids male fertility by improving sperm motility and count while also lowering the fraction of malformed sperm cells [5]. Low testosterone levels, which is the male sex hormone may be responsible for infertility in men, however, previous study has shown that some natural products such as citrus fruits, garlic, turmeric, fenugreek, ginseng and coconut milk supports healthy hormone production and helps to boost male reproductivity by increasing testosterone levels and sperm counts[6]. Male infertility is becoming more common over the world, which is of public concern due to its

Comment [L7]: Punctuations is not followed properly .

social and economic consequences [7]. As a result, men's fertility has been stimulated using commonly available and affordable natural products with minimal or no negative effects. This could be a viable alternative to pharmacological methods of fertility stimulation, which have a number of drawbacks and are not widely available [8]. This rise in male infertility and the paucity of scientific reports as at the period of the study, on the sub-acute effects of aqueous and methanol extracts of coconut milk on the testosterone level and testes of men, necessitated this research which investigated the possible effects of coconut milk as an adjuvant on the reproductive system as it relates to testosterone level and testes using adult male albino rats.

Comment [L8]: Include the significance of testosterone benefits and why the study was designed?

2. MATERIAL AND METHODS

2.1 Collection of plant material (Coconut)

Ten (10) mature fresh coconut fruits were obtained from Nsukka, in Nsukka Local Government Area of Enugu State, South East Nigeria. The coconut was kept in a cool dry place.

2.2 Preparation of Coconut milk Extract

A clean, sterilized knife was used to split open the mature, fresh coconut heads and for the removal of the white coconut flesh from the shell. The coconut flesh was further divided into more smaller pieces; it was washed and blended with an electric blender without adding water. The blending was done thrice for 5minutes each, the grinded coconut was weighed, using a standard weighing balance. The weight obtained was 400g. The blended coconut was divided into two (2) parts of 200g each.

A wooden stirrer was used to homogenize 200g of the finely ground coconut fruit with 200ml of water to create the aqueous extract. In order to sift the homogenate, a fresh muslin cloth was used., until all the coconut milk was fully extracted and the filtrate obtained was stored in the refrigerator at 2-8°C until when needed.

Comment [L9]: Should be in caps

For the methanol extract, 200ml of (80%) methanol was added to 200g of the grinded coconut fruit for 72hours. Throughout the extraction procedure, the mixture was continually stirred. The combination was filtered with Whatmann filter paper after 72 hours, and the filtrate was then left to evaporate. The obtained residue was kept in a refrigerator until it was needed. Both extracts' extractive values were calculated.

2.3 Animal housing and management

Twenty five adult male Wistar rats weighing 120-180g obtained from the Animal house, College of medicine University of Nigeria Teaching Hospital. The rats were weighed and divided into five (5) groups; I, II, III, IV and V of five (5) rats per group according to their body weights. They were housed in Anatomy Department, College of Medicine University of Nigeria Enugu Campus under standard conditions of temperature (27±2 °C) and a 12hours light, 12hours dark cycle. The rats were housed in groups in metallic cages and given access to clean water and standard commercial rat feed (Guinea feed®, Enugu, Nigeria). Acclimatization lasted for two (2) weeks after which the study was commenced. All the animals were handled in accordance to Institutional regulations approved for the care and use of animals for scientific research by University of Nigeria.

2.4 Experimental design and conduct

The rats were divided into five groups, which comprised of group I-V. Group I, was the control group and received water and standard commercial feed only throughout the duration of the experiment, while groups II-V served as the test group and received graded doses of methanol and aqueous extracts of coconut milk twice daily via oropharyngeal route using an oral gavage for 14 days as follows; group II and III received 163mg/kg and 326mg/kg body weight of methanol extract of coconut milk respectively. Group IV and V received 110mg/kg and 220mg/kg body weight of aqueous extract of coconut milk respectively.

Comment [L10]: Why group VI was not designed and why standard drug to induce testosterone level was not given. Hence the medicinal drug can be compared with std drug.

Comment [L11]: Toxicity studies to fix doses for the study shld have been done or refered from ROL.

2.5 Testosterone Estimation

At the end of two weeks, on the fifteenth day, the blood samples of the rats were collected into plain tubes by a retro-orbital puncture of the median canthus for the estimation of the levels of testosterone using Standard Accu Bind ELISA Microwells with testosterone code system product code: 3725-300, by monobind Inc. Lake Forest. CA 92630, USA. It uses the principle of competitive Enzyme immunoassay.

Comment [L12]: Mention the time for blood collection as it would support the hypothesis of the study.

Comment [L13]: Apart from testosterone estimation why other parameters like are not carried out as it would support the study.

2.6 Relative organ weight determination

Under chloroform anesthesia, the rats were sacrificed, and the testes were excised. Necropsy was performed to check for any lesions or signs of abnormalities. Each rat's testes was blotted with filter paper and weighed on a balance. The relative organ weight [ROW] of each testis was calculated using this formula:

$$\text{ROW} = \frac{\text{Absolute Organ weight(g)}}{\text{X}} \times \frac{100}{\text{Weight of rat}}$$

2.7 Tissue processing and microscopy

Under chloroform anesthesia, the rats were sacrificed, the testes were removed, weighed, and fixed in 10 percent formal saline for 48 hours prior to histological processing utilizing the paraffin embedding technique with a light microscope. Sections measuring 3-5 microns were prepared and stained using the Haematoxylin and Eosin (H & E) staining method as described [9]. An Olympus TM binocular microscope with an integrated illumination system was used to examine the sections.

2.8 Statistical analysis

Data was analyzed using Statistical Package for Social Sciences (SPSS) software (SPSS, Chicago, IL; version 23.0). All data were expressed as the mean value \pm SEM. The level of significance was determined by the student's t-test. While the effect on the 'test' groups were determined by one way analysis of variance (ANOVA) and Tukey's multiple comparison, $P < 0.05$ was considered significant.

3. RESULTS AND DISCUSSION

Over the years, infertility has increased in both males and females. However, the rise in male infertility has been a subject of worldwide worry. Smoking, drinking alcoholic drinks, and using prohibited substances, as well as stress, poor diet, and lack of exercise, have all been linked to this [10]. In addition, testicular damage, vas deferens blockage, varicocele, inadequate vitamin intake, and increased testicular heat have all been linked to male infertility [11].

In experimental studies, testicular size is the best main evaluation for spermatogenesis [12], and the weight of male reproductive organs is often a useful reproductive risk assessment, because in the testicular mass, tubules and germinal components make up about 98 percent of the mass. In spite of the many uses of coconut milk, the results of this investigation showed that the mean relative organ weights (ROW) of the testes of the treated rats did not significantly change when compared with the controls ($P = .83$) as shown in (Table 1). However, an increase in mean relative weights of the testes was observed in all the treated rats that received both aqueous and methanol extracts of coconut milk compared with the control rats but the increase was not significant. A previous study documented that the small amounts of medium chain triglycerides (MCTs) found in coconut milk are unlikely to have any significant effects on body weight or metabolism [13]. This finding agrees with a study conducted by [11], which documented that there was no significant increase in the mean relative weight of testes of rats when treated with low, medium and high dose of coconut milk extract.

Table 1: Effect of *Cocos nucifera* milk on relative weight of testes of treated rats

	Groups					ANOVA	
	I	II	III	IV	V	F ratio	P value
Relative weight of testes	0.60 \pm 0.07	0.62 \pm 0.04	0.62 \pm 0.04	0.62 \pm 0.11	0.71 \pm 0.07	0.372	0.826

Results are expressed as mean \pm standard error of mean (SEM).

Table 2 reveals the results of the serum testosterone levels from the MECM and AECM treatment group in comparison with the controls. In comparison to the control, all treated groups showed reduced mean serum testosterone values. This rise in male infertility has resulted in a demand for natural solutions that are readily available and affordable, has moderate or no side effects, and can be used as a substitute for pharmacological techniques of fertility stimulation, which may have some negative effects and are not readily available [14]. According to certain studies, rats given coconut oil and coconut oil diets had higher testosterone levels [15,16,17].

This is in contrast to the findings of this study, which showed that all treated rats had lower mean serum testosterone levels than the control ($p > 0.05$); this could be attributed to the stress the rats experienced during the handling and treatment period. Increased oxidative stress was found to damage supporting Sertoli cells and the testosterone-secreting Leydig cells, as well as affect the hypothalamic-pituitary-gonadal (HPG) axis [18,19]. Cortisol, a stress hormone, has been proven to act directly on cells in the testes, inhibiting testosterone production and release, resulting in low testosterone levels [20,21].

The histology findings revealed that control rats showed normal representation of testicular microanatomical structure (Fig. 1i), whereas, the testes of the treated rats that received oral administration of methanol and aqueous extracts of coconut milk showed mild morphological alterations compared to the control. Rats in group II (Fig. 1ii) and V (Fig. 1v) that received 163mg/kg and 220mg/kg body weight of methanol and aqueous coconut milk extracts respectively, showed mild tubular degeneration with sloughing of the germinal epithelium which may be due to an inflammatory process [11]. The observed mild vacuolated germinal epithelia in some of the seminiferous tubules of rats in group III (Fig. 1iii) that received 326mg/kg body weight of methanol extract of coconut milk may be due germ cell degeneration [22]. Sertoli cell vacuolation is a common early feature of morphologic injury to Sertoli cell that can be found in studies of 28 days or less [23], prior to any germ cell degeneration. These vacuoles may contain fluid or lipid, and they may represent endoplasmic

Comment [L14]: Mention the short form like MECM & AECM in the experimental design

Comment [L15]: Is it raised or reduced

Comment [L16]: Check whether the second sentence and this 3rd one are similar

Comment [L17]: Cortisol estimation can be carried out.

Comment [L18]: Degeneration is because of methanol or dosage concentration.

reticulum or intercellular space dilation. In healthy mouse testicular tissues, seminiferous epithelia exhibited vacuolar changes, previous toxicological studies have also reported similar pathological changes in testicular tissues [24,25].

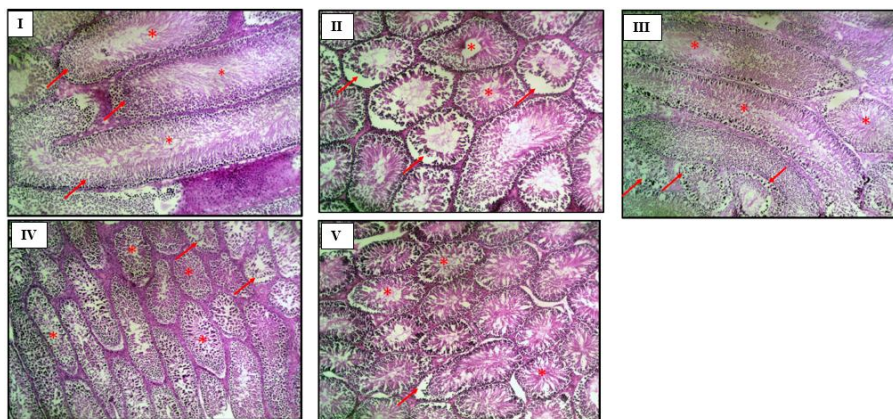


Figure 1; I-V: Photomicrographs of testes sections of animals in Groups I – V. The seminiferous tubules (arrows) of animals in Groups I and IV appear normal with the germinal epithelia intact and the flagella of mature spermatids seen in the lumen (*); those in Groups II and V appear to have degenerated tubules with sloughed germinal epithelia (arrows); those in Group III have vacuolated germinal epithelia in some of the seminiferous tubules (arrows).

4. CONCLUSION

Short term administration of both aqueous and methanolic extracts of coconut milk had no significant effect on the weight of testes and the level of testosterone, and may cause mild morphological alterations in the testes of rats at these doses.

REFERENCES

- 1 Adelan, AO. and Alamu, TA. Effect of coconut (Cocos nucifera) flakes substitution on some quality parameters of wheat bread. *African J of Food, Agric, Nutr Dev.* 2021; 21(7):18349-18367
<https://doi.org/10.18697/ajfand.102.20170>
- 2 Patil U, and Benjakul S. Coconut milk and coconut oil: their manufacture associated with protein functionality. *J of Food Sci.* 2018; 83(8):2019-2027.
<https://doi.org/10.1111/1750-3841.14223>
- 3 Karunasiri AN, Gunawardane M, Senanayake CM, Jayathilaka N, Seneviratne KN. Antioxidant and nutritional properties of domestic and commercial coconut milk preparations. *Int J of food sci.* 2020; (2020):1-9
<https://doi.org/10.1155/2020/3489605>
- 4 Ramgir SS, Gopalakrishnan AV, Roopan SM. Herbal Traditional Remedies for Male Infertility. *Phytopharmaceuticals: Potential Therapeutic Applications.* 2021; 3:173-189.
<https://doi.org/10.1002/9781119682059.ch9>
- 5 Alyaqoubi S, Abdullah A, Samudi M, Abdullah N, Addai ZR, and Musa KH, "Study of antioxidant activity and physicochemical properties of coconut milk (Pati santan) in Malaysia," *J Chem Pharm Res.* 2015; 7(4) 967-973
<https://doi.org/10.19026/ajfst.7.1301>
- 6 Alamgir AN. Vitamins, nutraceuticals, food additives, enzymes, anesthetic aids, and cosmetics. In *Therapeutic*

Comment [L19]: Pictures are not clear

Comment [L20]: Group I and III photos magnification is not in similarity to other groups.

Comment [L21]: Is it because of short term or of drug dosage confirm through literature.

Comment [L22]: Explain more and clearly

Use of Medicinal Plants and their Extracts. 2018; 2: 407-534. Springer, Cham.

https://doi.org/10.1007/978-3-319-92387-1_5

7 Anyakudo MM, Balogun AJ, Adeniyi MO. Beneficial effects of honey-based diet on glycemic control and reproductive potential in diabetic rats. *World*. 2015; 3(2): 41-46.

8 Liu PY, Handelsman DJ. The present and future state of hormonal treatment for male infertility. *Human reproduction update*. 2003; 19(1): 9-23.

<https://doi.org/10.1093/humupd/dmg002>

9 Baker, FJ., Silverton, RE., Palhster, CJ., Homby, A., Luxton, RW. and Griffin, R.L. *Introduction to Medical Laboratory Technology*. 1998; Reed Education and Professional Publishing. 7th (ed). P.230.

10 Yao DF, Mills JN. Male infertility: lifestyle factors and holistic, complementary, and alternative therapies. *Asian journal of Andrology*. 2016; 18(3): 410.

<https://doi.org/10.4103/1008-682X.175779>

11 Fischer Victor, A, Christabel Francis, Fischer, Christie E. Micro architecture of the Testes following administration of Coconut Oil (*Cocos nucifera* L.) on Adult Albino Wistar Rats *IOSR J Pharm Biol Sci*. 2019; 14(4):1-9

12 Raji, Y., Ifabunmi, SO., Akinsomisoye, OS., Morakinyo, AO., Oloyo, AK. Gonadal responses to antipsychotic drugs: Chlorpromazine and thioridazine reversibly suppress testicular functions in albino rats. *Int J Pharmacol*. 2015; 1: 287-292.

<https://doi.org/10.3923/ijp.2005.287.292>

13 Cardoso, DA., Moreira, AS., de Oliveira GM., Raggio Luiz, R. & Rosa, GA coconut extra virgin oil-rich diet increases HDC cholesterol and waist circumference and body mass in coronary artery diseases patient. *Journal of Nutritional Hospital*. 2015; 32(5): 2144-2155.

14 Johnkennedy, N., Ndubueze, EH., Augustine, I., Chioma, D., & Okey, EC. Coconut Water Consumption and Its Effect on Sex Hormone Concentrations. *Journal of Krishna Institute of Medical Sciences (JKIMSU)*. 2014; 3(2). 11-18.

15 Dosumu, OO., Duru, FO., Osinubi, A.A., Oremosu, AA., Noronha, CC. Influence of virgin coconut oil (VCNO) on oxidative stress, serum testosterone and gonadotropic hormones (FSH, LH) in chronic ethanol ingestion.

Agriculture and Biology Journal of North America. 2010;1(6): 1126-1132. doi:10.5251/abjna.2010.1.6.1126.1132

<https://doi.org/10.5251/abjna.2010.1.6.1126.1132>

16 Hurtado de Catalfo, GE., De Alaniz, MS., Marra, CA. Dietary lipids modify redox homeostasis and steroidogenic status in rat testis. *Nutrition*. 2008; 24(7-8): 717-726.

<https://doi.org/10.1016/j.nut.2008.03.008>

17 Hurtado de Catalfo GE., De Alaniz, MS., Marra, CA. Influence of commercial dietary oils on lipid composition and Testosterone production in interstitial cells isolated from rat testis. *Lipids*. 2009; 44(4): 34-357.

<https://doi.org/10.1007/s11745-008-3277-z>

18 Maneesh, M., Dutta, S., Chakrabarti, A., Vasudevan, DM. Alcohol abuse-duration dependent decrease in plasma TT and antioxidants in males. *Indian J PhysiolPharmacol*. 2006; 50(3): 291-296.

19 Rehman R, Amjad S, Tariq H, Zahid N, Akhter M, Ashraf M. Oxidative stress and male infertility: a cross sectional study. *JPMA. J Pak Med Assoc*. 2020;70(3):461.

<https://doi.org/10.5455/JPMA.12992>

20 Venkat, K. K., Arora, M. M., Singh, P., Desai, M., Khatkhatay, I. Effect of alcohol consumption on bone mineral density and hormonal parameters in physically active male soldiers. *Bone*. 2009; 45(3): 449-454.
<https://doi.org/10.1016/j.bone.2009.05.005>

21 Roychoudhury S, Chakraborty S, Choudhury AP, Das A, Jha NK, Slama P, Nath M, Massanyi P, Ruokolainen J, Kesari KK. Environmental factors-induced oxidative stress: Hormonal and molecular pathway disruptions in hypogonadism and erectile dysfunction. *Antioxidants*. 2021;10(6):837.
<https://doi.org/10.3390/antiox10060837>

22 Creasy D, Bube A, De Rijk E, Kandori H, Kuwahara M, Masson R, Nolte T, Reams R, Regan K, Rehm S, Rogerson P, Whitney K. (2012). Proliferative and nonproliferative lesions of the rat and mouse male reproductive system. *ToxicoPathol* 40:40S-121S.
<https://doi.org/10.1177/0192623312454337>

23 Hentrich A, Wolter M, Szardening-Kirchner C, et al: Reduced numbers of Sertoli, germ, and spermatogonial stem cells in impaired spermatogenesis. *Mod Pathol* 2011; 24: 1380-1389.
<https://doi.org/10.1038/modpathol.2011.97>

Comment [L23]: References shld be as mentioned in author's guidelines

24 Singh SK and Chakravarty S: Antispermatogenic and antifertility effects of 20,25-diazacholesterol dihydrochloride in mice. *ReprodToxicol* 2003;17: 37-44.
[https://doi.org/10.1016/S0890-6238\(02\)00075-8](https://doi.org/10.1016/S0890-6238(02)00075-8)

25 Mahmoud YI: Effect of extract of Hibiscus on the ultrastructure of the testis in adult mice. *Acta Histochem* 2012; 114: 342-348,
<https://doi.org/10.1016/j.acthis.2011.07.002>