

# **DIAGNOSTIC CHALLENGES IN OSTEORADIONECROSIS OF THE JAW**

## **Abstract**

Osteoradionecrosis of the jaws (ORNJ) is a severe radiotherapy (RT) complication that occurs in 2% to 22% of individuals with head and neck cancers (HNC) who are treated with RT or concurrent chemo-RT. The accurate diagnosis of ORNJ is crucial for appropriate and prompt management. On the other hand, various ORNJ stages can resemble osteomyelitis, medication-related osteonecrosis of the jaw (MRONJ), and tumor recurrences. This challenging situation is primarily due to the clinical and radiologic similarities between ORNJ and these non-RT-related conditions. Image analysis techniques such as panoramic imaging (PI), computed tomography (CT), magnetic resonance imaging (MRI), bone scintigraphy, positron emission tomography (PET), and single photon emission CT (SPECT) might help to avoid diagnostic obstacles. Despite the fact that the general characteristics of ORNJ have been reported in the literature, there is no clear consensus on its definitive diagnosis. Therefore, the current review aims to address ORNJ and its clinical and radiological aspects, as well as provide evidence to inform on the approaches to be used in removing the complexity in diagnosis, with a specific focus on radiological and nuclear medicine techniques.

**Keywords:** Radiotherapy, toxicity, osteoradionecrosis, jaw, diagnostic challenges.

## Introduction

Head and neck cancers (HNCs) are rising globally, accounting for approximately 900,000 cases per year and ranking seventh among the most prevailing cancers (1,2). Laryngeal and hypopharyngeal, nasal cavity and paranasal sinuses, nasopharyngeal, oral and oropharyngeal, and salivary gland cancers constitute 4% of all cancers in the United States and Europe (3,4). Reports from Asia have shown that HNCs are responsible for roughly 5% of all cancer fatalities on this continent (5). In parallel to the advancements in radiation delivery and planning systems, radiotherapy (RT) has established itself as an efficient but less toxic (than past) therapeutic option in the treatment of HNCs, with almost 75% of these patients receiving curative, adjuvant, or palliative RT (6). Nonetheless, this successful therapeutic procedure may result in osteoradionecrosis of the jaw (ORNJ), a detrimental complication of RT (7). Furthermore, despite the fact that newer, more advanced RT techniques such as intensity-modulated RT (IMRT), three-dimensional conformal RT (3D-CRT), and intensity-modulated proton therapy (IMPT) reduced the risk of ORNJ due to their improved tissue sparing properties, ORNJ may still occur in a significant portion of HNC patients depending on the high radiation doses received by the nearby or involved mandible (8).

Although many researchers have defined ORNJ, it was originally documented clinically by Regaud in 1922 and stipulated as one of the most serious problems in radiation oncology practice (9). Eiving only introduced the term "radiation osteitis" to describe this condition in 1926 (10). In the 1970s, Meyer characterized ORNJ as a triad of radiation, trauma, and infection, but made no reference to septic destruction of avascular tissue (11). On the other hand, Guttenberg emphasized the significance of microorganisms in the pathogenesis of ORNJ and referred to the condition as septic ORNJ (12). Marx introduced the "three H" principle in the years that followed, and it was acknowledged as being crucial to the pathophysiology of ORNJ (13). Accordingly, the definition of ORNJ stated that it

developed as a result of cellular and metabolic changes in radiation-induced hypoxic-hypovascular-hypocellular tissues, together with associated tissue loss and non-healing wounds. Epstein used the term of "RT-induced osteonecrosis" for ulceration or necrosis of mucous membranes exposed to necrotic bone for more than three months (14). In the years that followed, Delanian and Lefaix described the fibroatrophic processes involved in the pathogenesis of ORNJ (15), and Lyons and Ghazali (16), and Bras et al. proposed the theory of fibrosis linked to vascular changes (17). Although there is no explicit consensus, the current widely acknowledged ORNJ definition describes it as a late RT complication characterized by a necrotic process occurring in the jawbone, persisting for 3-6 months or longer in the irradiated site without tumor recurrence, non-healing, pain, denuded bone, purulent drainage, and mucosal and/or cutaneous fistula (13,18, 19).

According to many studies, the frequency of ORNJ in HNCs ranges from 2% to 22%. (14,20-24), which is significantly more prevalent in the mandible than in the other bones in this location (23-27). The fundamental explanation for this discovery is that the mandible has one-sixth the vascular supply of the centripetal blood supply of the maxilla (25-27). The additional, although less important, factor might be that the jaw is more frequently encompassed in the radiation portal and receives larger RT doses than the maxilla (28). Because of its critical location, such a gradual and frequently permanent RT problem has serious ramifications for the affected patients' functioning. The ORNJ has been found to influence patients' vital functions like swallowing, speech, and mastication via triggering discomfort, deformity, limited mouth opening, mucosal fistula development, and pathological fractures (29-32). ORNJ may cause anemia, inflammatory infections, leukocytosis, hyperproteinemia, and hypercoagulation, rendering oncologic treatment more difficult in HNC patients (32). Furthermore, ORNJ has a severe impact on the quality of life (QoL) of long-term HNC survivors (33), and the emergence of trismus and numbness following ORNJ

therapy worsens QoL measures even more. Also, dietary restrictions, eating in public, speech intelligibility, halitosis, and an inability to communicate can all result in much lower QoL. (34-36).

For all the aforementioned reasons, an early and accurate ORNJ diagnosis is critically important for the best patient care in HNC. The conclusive exclusion of local tumor recurrence, particularly in a suspected case of ORNJ, is one of the primary diagnostic mysteries, in addition to the problems in the proper diagnosis of ORNJ (37). Furthermore, radiological evidence of ORNJ may be inconspicuous in both the very advanced and early phases of disease. As a result of the difficulty in correctly identifying the ORNJ itself and its extent, clinicians may face a perplexing image of the situation, which will act as the principal determinant of the therapy required by the disease state. Therefore, addressing the existing complexities in ORNJ diagnosis is crucial for customizing traditional therapy techniques and developing cutting-edge management strategies (19). The present review is intended to focus primarily on the diagnostic challenges of ORNJ, which may serve usefully in the choice and timely onset of fitting preventive and therapeutic maneuvers in the radiation oncology and dentistry clinics.

## **Risk Factors for ORNJ Development**

Recognition of the ORNJ risk factors may lower the risk of ORNJ through the timely application of preventive measures and improve its prognosis via the prompt initiation of necessary interventions in HNC patients receiving RT or concurrent chemoradiotherapy (CCRT). The most salient risk factors for the development of ORNJ were notably linked to RT dosage and method as well as pre-RT and post-RT tooth extractions in the existing literature (7, 8, 38). The investigation by Chrcanovic and colleagues identified additional risk factors for the occurrence of ORNJ, including pre-RT bone surgery, the size, location, and stage of the tumor, its proximity to the bone, poor oral hygiene, alcohol use, smoking, the absence of

hyperbaric oxygen therapy (HBO), and improper handling of radiation shields (39). Additionally, it has been reported that using bisphosphonates in conjunction with chemotherapy and antiangiogenic agents may further increase this risk (40, 41).

### **Factors related to radiation dose and technique**

The consensus is that as the maximal dose of RT to the mandible increases, so does the likelihood of ORNJ formation (27, 42-44). ORNJ development has been associated with maximal RT doses higher than 60-75 Gy in several studies (43, 45, 46). Therefore, it was advised to minimize the mandibular volumes that get high doses and to reduce potentially dangerous hot spots in the jaw in order to prevent the emergence of ORNJ (46, 47). Modern IMRT technology enables more acceptable dosage reductions, better preservation of healthy tissues, and a reduced occurrence of ORNJ (48). Tsai et al. discovered that 3D-CRT patients had a higher incidence of ORNJ than IMRT patients (6.3% vs. 13%,  $P = 0.07$ ) (49). Moon et al. postulated that employing IMRT would reduce toxicity in the mandible and verified this hypothesis by finding a significantly reduced incidence of ORNJ in IMRT patients compared to 3D-CRT (19% vs. 4.0%,  $P = 0.01$ ) (50). Proton therapy is an advanced form of RT, in which the prescribed dose is transferred along a Bragg peak. IMPT is a more sophisticated form of proton therapy in which the tumor is targeted using various shaping techniques and beam modulation while the harm to surrounding normal tissues is minimized (8). Zhang et al. (51) revealed that the lower mandibular doses delivered by IMPT compared to normal IMRT reduced the ORNJ risk in oropharyngeal cancer patients from 7.7% to 2.0% ( $P < 0.05$ ).

### **Factors related to dental risk**

Providing oral care before RT or CCRT for HNC patients could be considered the initial step in minimizing complications in the oral cavity and related structures (7, 28). This viewpoint is reinforced by the fact that RT induces osteoblast and cementoblast loss with microvascular damage. Additionally, bacterial toxins in tooth plaque contribute to this condition,

including caries and periodontal diseases (52, 53). The two major risk factors for ORNJ are dental decay and periodontal disease, both of which can harm teeth and require extractions in the irradiated area (54-56). Furthermore, RT may cause dental caries, prompting tooth extractions, as well as changes in oral flora and impaired salivary gland activities (57, 58).

Tooth extraction in HNC patients is a risk factor for ORNJ (8), with mandibular teeth enduring radiation doses of more than 60 Gy being the most significant risk (59). An increased need for extractions during the riskier post-RT periods may result from failing to perform prophylactic tooth extractions before the RT (60). Even though a strong link between ORNJ risk and post-RT tooth extractions has been well documented in the literature, other researchers found that pre-RT traumatic tooth extractions also carried a significantly elevated risk of ORNJ (25, 61). Therefore, it is advised to perform any extraction as soon as is practical before RT, using atraumatic or minimally traumatic procedures, and to use prophylactic peri- and post-interventional antibiotics to reduce the risk of ORNJ associated with tooth extractions (59, 62, 63).

### **Classification of ORNJ**

The lack of a standardized staging approach is one of the difficulties in making an accurate diagnosis, although several researchers have proposed various ORNJ staging methods (13, 29, 64–68). In HNCs undergoing RT, Coffin classified the ORNJ into minor and major forms in 1983 (64). The minor form is composed of microscopic sequestrum that could not be radiographically shown but were clinically evident. The major ORNJ form was established when a pathologic fracture was identified clinically and radiologically due to necrosis. As depicted in Table 1, Marx proposed a three-stage protocol for ORNJ based on how patients responded to treatment with HBO and surgery in the same year. Stage 1 of the procedure responds to HBO therapy, while Stages 2 and 3 call for sequestrectomy and HBO therapy. With an extraoral fistula, a pathological fracture, and extension to nearby anatomical areas,

stage 3 is deficient and catastrophic (13). Morton and Simpson classified ORNJ into minor, moderate, and major categories in 1986 based on the requirement for surgery, the degree of sequestration, and the length of the recovery period (65). In 1987, Epstein created the ORNJ three-phase system for assessing disease severity, clinical symptoms, and the presence of pathological fractures (Table 1)(66). Ten years later, Clayman divided ORNJ into two types: Type 1, which can be treated conservatively, and Type 2, or "radiation osteomyelitis," which cannot be treated conservatively (67). In the years afterwards, Schwartz and Kagan have reinterpreted the degree of bone involvement (68). And finally, Notani et al. have described a staging ORNJ associated with the alveolar bone and canal (29): Stage I: ORNJ confined to dentoalveolar bone, Stage II: ORNJ limited to dentoalveolar bone or mandible above the inferior dental canal, or both, and Stage III: ORNJ involving the mandible below the inferior alveolar canal, or pathological fracture, or skin fistula (Table 1).

## **Diagnostic methods**

Although the diagnosis of ORNJ is mostly based on mucous membrane ulcers with clinically visible exposure of necrotic bone, radiographic investigations disclose critical features in overcoming diagnostic obstacles. It should be emphasized that radiological findings alone may not be sufficient to diagnose ORNJ in circumstances when tissue changes are not evident in the relevant location. To overcome the difficulties in diagnosis, both clinic and radiologic evidence should be evaluated simultaneously (8, 39). As a result, in order to establish a definitive diagnosis of ORNJ, the RT process and the patient's dental history and exams, panoramic radiographs and computed tomography (CT) scans, as well as other sophisticated imaging modalities, a biopsy of the lesion, and the disease stage should all be considered. Furthermore, the occurrence of primary or secondary malignancies should be ruled out (69-71).

## **Clinical evaluation**

Pain, one of the clinically debilitating signs of ORNJ, may pose a diagnostic problem (19,39,72), since it may be present in some instances but not in others (73). Furthermore, due to sensory nerve fiber loss, pain may be absent in late-stage ORNJ. As a result of various neurological disorders associated to ORNJ, dysesthesia and anesthesia should be explored during clinical evaluation. Patients frequently complain of halitosis and dysgeusia. A thorough intraoral examination may aid with the diagnosis, since the uneven surface and sharpened-edge bone in the gingiva suggest ORNJ. In such circumstances, surrounding soft tissue destruction can also be seen. In the diagnosis of advanced ORNJ, local or systemic infections and trismus may accompany the clinical picture in which pathological fracture, intraoral or extraoral fistulas are evident (74-76).

The clinical similarities between ORNJ and MRONJ pose a significant diagnostic challenge (72). Both ailments have a low incidence (2-22% for ORNJ vs. 0.001-7% for MRONJ), are usually confined to the mandible, and share many clinical features, such as presence of pain, exposed bone, and intraoral or orocutaneous fistula (14, 20-22, 77, 78). Furthermore, no pathognomonic histologic characteristic has been established to distinguish MRONJ from ORNJ (72). Nonetheless, the following considerations may help resolving this ambiguity in diagnosis (72,77,78):

- Patients with MRONJ are usually older than those with ORNJ.
- MRONJ occurs more frequently in the maxilla than ORNJ.
- ORNJ has a higher rate of pathological fractures than MRONJ.
- The existence of primary or recurrent tumor should be ruled out histologically

for the accurate diagnosis of ORNJ.

A careful and detailed medical history is the most useful tool in differential diagnosis, owing to the fact that MRONJ is associated with antiresorptive or antiangiogenic medication therapy and ORNJ with RT or CCRT.

## **Radiological evaluation**

For the diagnosis and assessment of ORN, the imaging modalities of choice are commonly panoramic imaging (PI), cone-beam computed tomography (CBCT), and computed tomography (CT) (8). Magnetic resonance imaging (MRI), bone scintigraphy, single photon emission computed tomography (SPECT), and positron emission tomography (PET) are among recommended imaging methods (19,39)(Table 2).

The first important problem in diagnosing ORNJ radiologically is that the disease may not manifest in the early stages (19). Furthermore, radiological findings may not indicate the full severity of the disease (9,79). The ORNJ region may appear normal at first, or it may develop into isolated or extensive osteolytic sites, sequestration, and pathological fractures (19). The precise alteration that may be seen in the early phase, however, is an increase in radiodensity and the mixed radiopaque/radiolucent lesion areas, indicating bone destruction. An early change seen in the outer cortical plate of the mandible is a sharply bounded bone resorption. Jaw fractures can be seen, when the bone's normal structure is substantially compromised. Particularly in the posterior mandible, which has typically less vascularization than the maxilla, early changes of ORNJ can be recognized. There may be spots of atypical bone resorption and sclerosis with vague non-cortical margins (73).

Radiolucent post-extraction sockets can be followed for more than a year in the images examined (9,19). Another difficulty is that bone loss and sclerosis found in ORNJ may be mistaken as periodontal disease. The final radiological examination of ORNJ is dependent on the identification of the sequestrum, in addition to the patient's past medical history. The sequestrum is defined as isolated cortical bone pieces and is most typically found in the mandible. Because the imaging findings of ORNJ are similar to those of osteomyelitis, a CBCT or CT scan is advised to locate the sequestrum. Pathological fracture alone does not

provide an unequivocal diagnosis. In such circumstances, it will be useful to employ additional imaging modalities (73).

### ***Panoramic Imaging (PI)***

PI, which is often employed in regular dental checkups, is widely acknowledged as the first step in imaging procedures used to diagnose ORNJ (8, 19). Intraoral and extraoral radiographs are used to support PI, providing for two-dimensional (2D) examination of both jaws (19,80). The presence of a sequestrum, radiolucency without discernible sclerotic boundaries encircling a region of necrotic bone, or a radiodense area in low-density tissue are all signs of ORNJ in the PI (Figure 1)(14,37). The sequestrum, which represents the necrotic bone fragment, is radiopaque. However, it may be distinguished in PI by pronounced alterations in the mineral composition of bone (>30-50%) created in later stages of ORNJ (14, 81-83). Enlargements of the periodontal ligament space along the apex of the teeth exposed to mandibular doses more than 45 Gy are seen in particular. This may, on the other hand, be related with numerous periodontal disorders and does not confirm the presence of an ORNJ (73,80). Furthermore, whereas PI can reveal pathological fractures, identifying the sequestrum is required to establish the diagnosis of ORNJ (73).

Because of their radiological similarities, osteomyelitis and MRONJ are included in the differential diagnosis of ORNJ. Gaêta-Araujo et al. examined the radiological characteristics of osteomyelitis, ORNJ, and MRONJ, all of which are osteonecrotic lesions, and concluded that while PI had a predictive value of 74%, it may be insufficient in separating the diseases. Only permitting 2D assessments, intrinsic magnification and distortion of the images in PI, and a lack of formalized follow-up all contribute to flaws in evaluating the characteristics and phases of the ORNJ (84).

### ***Cone beam computed tomography (CBCT)***

Dental CBCT is a type of x-ray machine that is utilized when standard dental or face x-rays are insufficient. Using this technique, physicians can get 3D images of teeth, soft tissues, nerve pathways, and bone all in one scan. In comparison to conventional CT, CBCT delivers volumetric imaging of the bone structures of the craniofacial area at lower doses and costs. Although CBCT imaging may not ensure ample soft tissue contrast, it does provide precise information regarding the morphological aspects and extent of lesions. It can be used to determine the amount of osteomyelitis in the differential diagnosis of cysts, tumors, and ORNJ (73). The use of CBCT in the investigation of ORNJ allows for the assessment of lytic changes, cortical bone resorption, and surrounding structures (8). Sclerotic areas, pathological fractures, and sequestrum are all shown by CBCT, which is critical for an accurate diagnosis (Figure 2). CBCT can distinguish osteomyelitis from ORNJ and MRONJ, and the predictive value between these three lesions has been shown to be 90%. When characterizing necrotic regions, CBCT provides better detail than PI. Furthermore, CBCT examination may aid in differential diagnosis by detecting greater periosteal bone growth in MRONJ than in ORNJ, and cortical bone resorption rather than osteomyelitis in ORNJ (84). The use of CBCT assists in identifying necrosis from other suspected cases of osteolysis (78). In essence, given all of these important properties, CBCT provides reliable results in the detection of bone disorders (84).

### ***Computed tomography (CT)***

Cortical discontinuity, osteolysis, changes in trabecular structure, thickening of soft tissues, pathological fractures, and bone sequestrum are among the CT findings of ORNJ (19, 39). One of the distinguishing characteristics of the disease on a CT scan in the latter stages of ORNJ is loss of bone trabeculae in cancellous bone with bicortical involvement. On CT scans, the lesion appears as gas bubbles that might represent an infectious process that is pathognomonic for

osteomyelitis (37, 85). To rule out the likelihood of a tumor recurrence or second primary cancer, any development in the soft tissue nearby should be an indication of primary or second cancers (37). When bone sclerosis and permeating trabeculation are seen on a CT scan, ORNJ can be distinguished from these conditions (86). Cortical defects that are localized far from the underlying tumor enhance ORNJ diagnosis (87).

ORNJ-related cortical discontinuities may be seen on the buccal or lingual side of the jaw, as well as on both sides. The presence of discontinuities in both lingual and corresponding buccal cortex is widely recognized as an indication of a jaw fracture (88). Due to the 3D character of CT compared to PI, bone alterations in the anterior-posterior direction and involvement of the buccal or lingual cortex are more obvious. Additionally, PI is unable to distinguish between lingual and buccal bone deterioration, which can easily be detected by CT (87, 89). A fusiform swelling clarifies soft tissue thickening around the pathological fracture. In the absence of a pathological fracture, the lesion is restricted to bone degradation (88). Mandibular bone destruction in the absence of soft tissue involvement simplifies ORNJ diagnosis (90). Because advanced ORNJ frequently includes soft tissue swelling, the differential diagnosis with tumor recurrence is complicated. However, it may be helpful to know that a malignant squamous cell carcinoma commonly causes damage in the alveolar process or through the lingual cortex to aid in the diagnosis (88). ORNJ also differs from tumor recurrence in that recurrences usually occur during the first two years of treatment, while there is a longer interval between the therapy and ORNJ formation, with a median ORNJ development interlude following RT or CCRT of nearly three years (91).

### ***Magnetic resonance imaging (MRI)***

MRI is a non-invasive technique to identify interior structures, distinguish between soft and hard tissues, and examine various bodily functions. The basic idea underlying MRI is to produce high-quality cross-sectional images of the body by using non-ionizing radio

frequency electromagnetic radiation in the presence of regulated magnetic fields. MRI has better tissue contrast and higher spatial resolution than other imaging techniques (92). With aberrant, homogenous, low marrow signal intensity on T1-weighted images and increased signal intensity on T2-weighted images, MRI reveals altered bone marrow in the ORNJ site (91, 92). Because the masticatory muscles nearby the lesion have thickened, MRI has the benefit of detecting ORNJ earlier than CT. But, it is challenging to make a diagnosis, since the muscle thickening might signify a tumor recurrence as well. Consequently, the utilization of CT imaging may aid in overcoming this difficulty (88). Cortical damage, an aberrant bone marrow signal, and a modest to moderately uneven contrast enhancement is all visible on gadolinium-enhanced MRI scans of the ORNJ (93, 94). MRI with dynamic contrast is additionally useful because it can demonstrate quantitative differences in vascular leakage at ORNJ locations (95).

***Bone scintigraphy, Single photon emission computed tomography (SPECT), and Positron emission tomography (PET)***

Bone scintigraphy is utilized to pinpoint the location and severity of the illness since it has a sensitivity of up to 100% in the diagnosis of ORNJ (92). Early-stage ORNJ can be detected via bone scintigraphy employing <sup>99m</sup>Tc-marked diphosphonates (<sup>99m</sup>Tc-MDP), and depending on altered phosphate metabolisms, it may signify osteoblastic activity and healthy blood flow (96). However, this imaging technique has limited spatial resolution and soft tissue over-projection, whereas SPECT removes these drawbacks (92). Three-phase bone scintigraphy, according to Lapa et al., demonstrated an enhanced homogenous bone metabolism caused by inflammatory processes in instances with ORNJ, and late phase SPECT was adequate for ORNJ diagnosis (97). Inflammatory soft tissue or tumor recurrence are shown by PET/CT. PET/CT shows both hypermetabolic bone marrow and increased glucose metabolism. However, localized changes in clearance rate, vascular perfusion, permeability,

and chemical bonding have an impact on both PET/CT and SPECT pictures (98). Additionally, when osteomyelitis is present, it may be difficult to discern between soft tissue and bone involvement. For a conclusive diagnosis of tumor recurrence, an incisional biopsy is advised for indiscernible cases (99). However, to prevent the development of a fistula track, the biopsy method must be as minimally invasive as possible.

## **Discussion**

ORNJ is a dreaded consequence of RT or CCRT affecting the mandibular bone, but there is no broadly acknowledged consensus in the literature on a definition of the disorder. Furthermore, the lack of a consistent classification makes comparing clinical findings and outcomes across research problematic. The diagnosis of ORNJ is also difficult since there is no broad agreement on its specific diagnostic criteria. Therefore, due to the lack of a specific staging system and clinical risk factors that correspond to ORNJ diagnostic criteria, as well as the inability to create a general radiographic diagnosis guideline using the data at hand, the literature presented here displays that diagnosing ORNJ presents glaring difficulties. These challenges were demonstrated by the findings of a review of 12 published articles that attempted to define ORNJ. In this study, Wong et al. found that the only characteristic that all of the papers had in common was clinical exposure to the non-vital bone(100).

There is disagreement in the literature regarding the clear connection between the timing of tooth extractions (before vs. after RT) and ORNJ risk (8). There were no dental interventions in 82% of the ORNJ cases reported in Owosho and colleagues' study (43). Nevertheless, Nabil et al. indicated that after 2–5 years of RT, the risk of ORNJ increased by 23% due to tooth extractions. In this particular respect, it should be noted that failing to extract suspect teeth prior to RT will result in many more tooth extractions and an increased risk of ORNJ (59). It is strongly recommended to use IMRT rather than 2D-RT or 3D-CRT and to keep RT doses as low as possible to prevent ORNJ genesis in HNC patients (8, 50).

Zhang et al. stressed that mandibular doses were even lower with IMPT than with IMRT when treating oropharyngeal cancers (51). This conclusion is supported by the ability of dose confinements in IMPT to protect nearby healthy tissues. Therefore, where it is practicable, IMPT may be favored as the RT technique of preference for such patients. In addition to the modern RT techniques, fluoride solutions and artificial saliva preparations may prevent xerostomia, tooth decay, and tooth extraction, which represent significant risk factors for ORNJ development (7, 28).

Although the clinically observed exposure of necrotic bone in the previously irradiated area and ulceration of the mucous membrane form the basis of the recognized fundamental description of ORNJ in the literature, examples of ORNJ with radiologically necrotic but intact mucosa have been documented (13, 18, 43, 66, 101). Owosho et al. included ORNJ patients with only radiological evidence of necrosis in their staging method, suggesting that this illness might be neglected if just the crucial clinical diagnosis is used, and that radiological findings have a significant influence on both diagnosis and staging (66). Miyamoto et al. examined the diagnostic component of ORNJ by combining clinical symptoms with imaging modalities CT, MRI, PET/CT, bone scintigraphy, and SPECT in a cohort of 57 locations in 54 patients with a history of RT and suspected ORN. In this investigation, diagnostic imaging examinations showed long-term RT-related bone marrow degeneration on MRI and sclerotic alterations in 82% of the bone marrow on CT. The efficacy of these techniques in diagnosis was proven in the same study, with PET/CT revealing involvement surrounding the symptomatic bone and SPECT identifying the ORNJ lesion uptake (99).

In addition to bone sclerosis caused by RT-induced damage, the ORNJ genesis process also includes hypovascularization, hypoxia, and fibrosis that are brought on by abnormal bone marrow changes (7, 44, 86, 99). Additionally, one of the symptoms of ORNJ, trismus, may be

brought on by inflammation and fibrosis in the nearby masticatory muscles (102). Thus, by displaying abnormalities in bone and soft tissue and supporting the clinical scenario, the combined use of CT and MRI in the diagnosis of ORNJ may serve as the most reliable radiological tool to overcome the diagnostic obstacle (99). RT can lessen or even halt periosteal reactions in patients with ORNJ (99, 103, 104), whereas periosteal reactions frequently last a long time in MRONJ patients (103, 104). As a result, CT evaluation of the periosteal responses in RT locales may help to clarify the ORNJ and MRONJ enigmas, which have similar clinical manifestations. Advanced ORNJ-related neurological symptoms may be a precursor to primary or secondary malignancies, as well as MRONJ. Biopsies guided by PET and SPECT imaging are recommended for a definitive diagnosis in such cases (99).

The emergence of a necrotic bone, such as ORNJ in osteomyelitis, is another source of consternation. However, in ORNJ, the periosteum is permanent and there is no reactive bone, whereas in osteomyelitis, both the periosteum and the reactive bone are viable. The therapeutic radiation energy received by the initial ORNJ site in the bone is expected to cause far more severe symptoms and tissue destruction than chronic osteomyelitis (105). Although CBCT examination of lesion details is advised, MRI will be the appropriate imaging modality to assess soft tissues in the case of ORNJ due to the lack of radiation exposure in MRI examinations (37, 106).

## **Conclusion**

Finally, to reliably identify ORNJ in HNC patients, selecting the most suitable imaging modalities in accordance with their clinical characteristics may help to accurately demonstrate the lesion and its bony or soft tissue extensions. Robust, multi-institutional, and prospective data examining all facets of ORNJ are needed to resolve the complex diagnostic enigma. A comprehensive diagnosis of ORNJ and its severity appears to benefit from collaboration

between clinical findings, CT/MRI, and biopsy, according to the evidence in the literature that is currently accessible.

## **REFERENCES**

1. Global Cancer Observatory. International Agency for Research on Cancer. World Health Organization. Available at: <https://gco.iarc.fr/> (Accessed on August14, 2022).
2. Bray F, Ferlay J, Soerjomataram I, Siegel RL, Torre LA, Jemal A. Global cancer statistics 2018: GLOBOCAN estimates of incidence and mortality worldwide for 36 cancers in 185 countries [published correction appears in *CA Cancer J Clin.* 2020;70(4):313.
3. American Society of Clinical Oncology (ASCO). Cancer.Net ® ASCO: Knowledge Conquers Cancer. Available at: <https://www.cancer.net/cancer-types/head-and-neck-cancer/statistics>.
4. Gatta G, Botta L, Sánchez MJ, et al. Prognoses and improvement for head and neck cancers diagnosed in Europe in early 2000s: The EURO CARE-5 population-based study. *Eur J Cancer.* 2015;51(15):2130-2143.
5. Keam B, Machiels JP, Kim HR, et al. Pan-Asian adaptation of the EHNS-ESMO-ESTRO Clinical Practice Guidelines for the diagnosis, treatment and follow-up of patients with squamous cell carcinoma of the head and neck. *ESMO Open.* 2021;6(6):100309.
6. Ratko TA, Douglas GW, de Souza JA, Belinson SE, Aronson N. Radiotherapy Treatments for Head and Neck Cancer Update. Rockville (MD): Agency for Healthcare Research and Quality (US); December 2014.
7. Yilmaz B, Somay E, Kucuk A, Pehlivan B, Selek U, Topkan E. persistent inflammation as a cause of severe late complications in chemoradiotherapy-treated head and neck cancer patients. *New Horizons in Medicine and Medical Research* 2022; 12; 16-31.

8. Frankart AJ, Frankart MJ, Cervenka B, Tang AL, Krishnan DG, Takiar V. Osteoradionecrosis: Exposing the evidence not the bone. *Int J Radiat Oncol Biol Phys*. 2021;109(5):1206-1218.
9. Regaud C. Sur la necrose des OSattients par un processus cancreux et traiters par les radiations. *Compt Rend Sot de Biol*. 1922; 25: 427-429 (in French).
10. Eiving J. Radiation osteitis. *Acta Radiol*. 1926;6(1-6):399-412.
11. Meyer I. Infectious diseases of the jaws. *J Oral Surg*. 1970;28(1):17-26.
12. Guttenberg SA. Osteoradionecrosis of the jaw. *Am J Surg*. 1974;127(3):326-332.
13. Marx RE. Osteoradionecrosis: a new concept of its pathophysiology. *J Oral Maxillofac Surg*. 1983;41(5):283-288.
14. Epstein JB, Rea G, Wong FL, Spinelli J, Stevenson-Moore P. Osteonecrosis: study of the relationship of dental extractions in patients receiving radiotherapy. *Head Neck Surg*. 1987;10(1):48-54.
15. Delanian S, Lefaix JL. The radiation-induced fibroatrophic process: therapeutic perspective via the antioxidant pathway. *Radiother Oncol*. 2004;73(2):119-131.
16. Lyons A, Ghazali N. Osteoradionecrosis of the jaws: current understanding of its pathophysiology and treatment. *Br J Oral Maxillofac Surg*. 2008;46(8):653-660.
17. Bras J, de Jonge HK, van Merkesteyn JP. Osteoradionecrosis of the mandible: pathogenesis. *Am J Otolaryngol*. 1990;11(4):244-250.
18. Støre G, Boysen M. Mandibular osteoradionecrosis: clinical behavior and diagnostic aspects. *Clin Otolaryngol Allied Sci*. 2000;25(5):378-384.
19. Chronopoulos A, Zarra T, Ehrenfeld M, Otto S. Osteoradionecrosis of the jaws: definition, epidemiology, staging and clinical and radiological findings. A concise review. *Int Dent J*. 2018;68(1):22-30.

20. Cheng VS, Wang CC. Osteoradionecrosis of the mandible resulting from external megavoltage radiation therapy. *Radiology*. 1974;112(3):685-689.
21. Rankow RM, Weissman B. Osteoradionecrosis of the mandible. *Ann OtolRhinolLaryngol*. 1971;80(4):603-611.
22. Morrish RB Jr, Chan E, Silverman S Jr, Meyer J, Fu KK, Greenspan D. Osteonecrosis in patients irradiated for head and neck carcinoma. *Cancer*. 1981;47(8):1980-1983.
23. Beaumont S, Bhatia N, McDowell L, et al. Timing of dental extractions in patients undergoing radiotherapy and the incidence of osteoradionecrosis: a systematic review and meta-analysis. *Br J Oral Maxillofac Surg*. 2021;59(5):511-523.
24. Lajolo C, Gioco G, Rupe C, et al. Tooth extraction before radiotherapy is a risk factor for developing osteoradionecrosis of the jaws: A systematic review. *Oral Dis*. 2021;27(7):1595-1605.
25. Beech N, Porceddu S, Batstone MD. Preradiotherapy dental extractions and health-related quality of life. *Oral Surg Oral Med Oral Pathol Oral Radiol*. 2016;122(6):672-679.
26. Wahl MJ. Osteoradionecrosis prevention myths. *Int J Radiat Oncol Biol Phys*. 2006;64(3):661-669.
27. Beumer J, Harrison R, Sanders B, Kurrasch M. Osteoradionecrosis: predisposing factors and outcomes of therapy. *Head Neck Surg*. 1984;6(4):819-827.
28. Jawad H, Hodson NA, Nixon PJ. A review of dental treatment of head and neck cancer patients, before, during and after radiotherapy: part 2. *Br Dent J*. 2015;218(2):69-74.
29. Notani K, Yamazaki Y, Kitada H, et al. Management of mandibular osteoradionecrosis corresponding to the severity of osteoradionecrosis and the method of radiotherapy. *Head Neck*. 2003;25(3):181-186.
30. Jacobson AS, Zevallos J, Smith M, et al. Quality of life after management of advanced osteoradionecrosis of the mandible. *Int J Oral Maxillofac Surg*. 2013;42(9):1121-1128.

31. Rogers SN, D'Souza JJ, Lowe D, Kanatas A. Longitudinal evaluation of health-related quality of life after osteoradionecrosis of the mandible. *Br J Oral Maxillofac Surg.* 2015;53(9):854-857.
32. Jin T, Zhou M, Li S, Wang Y, Huang Z. Preoperative status and treatment of osteoradionecrosis of the jaw: a retrospective study of 252 cases. *Br J Oral Maxillofac Surg.* 2020;58(10):e276-e282.
33. Chieng CY, Davies A, Aziz A, Lowe D, Rogers SN. Health related quality of life and patient concerns in patients with osteoradionecrosis. *Br J Oral Maxillofac Surg.* 2021;59(9):1061-1066.
34. Danielsson D, Munck-Wikland E, Hagel E, Halle M. Quality of life after microvascular mandibular reconstruction for osteoradionecrosis-A prospective study. *Head Neck.* 2019;41(7):2225-2230.
35. de Graeff A, de Leeuw RJ, Ros WJ, et al. A prospective study on quality of life of laryngeal cancer patients treated with radiotherapy. *Head Neck.* 1999;21(4):291-296.
36. List MA, Siston A, Haraf D, et al. Quality of life and performance in advanced head and neck cancer patients on concomitant chemoradiotherapy: a prospective examination. *J Clin Oncol.* 1999;17(3):1020-1028.
37. Deshpande SS, Thakur MH, Dholam K, Mahajan A, Arya S, Juvekar S. Osteoradionecrosis of the mandible: through a radiologist's eyes. *Clin Radiol.* 2015;70(2):197-205.
38. Balermpas P, van Timmeren JE, Knierim DJ, Guckenberger M, Ciernik IF. Dental extraction, intensity-modulated radiotherapy of head and neck cancer, and osteoradionecrosis: A systematic review and meta-analysis. *StrahlentherOnkol.* 2022;198(3):219-228.

39. Chrcanovic BR, Reher P, Sousa AA, Harris M. Osteoradionecrosis of the jaws--a current overview--part 1: Physiopathology and risk and predisposing factors. *Oral Maxillofac Surg.* 2010;14(1):3-16.
40. Ruggiero SL, Dodson TB, Fantasia J, et al. American Association of Oral and Maxillofacial Surgeons position paper on medication-related osteonecrosis of the jaw--2014 update. *J Oral Maxillofac Surg.* 2014;72(10):1938-1956.
41. Wan JT, Sheeley DM, Somerman MJ, Lee JS. Mitigating osteonecrosis of the jaw (ONJ) through preventive dental care and understanding of risk factors. *Bone Res.* 2020;8:14.
42. Marx RE, Johnson RP. Studies in the radiobiology of osteoradionecrosis and their clinical significance. *Oral Surg Oral Med Oral Pathol.* 1987;64(4):379-390.
43. Owosho AA, Tsai CJ, Lee RS, et al. The prevalence and risk factors associated with osteoradionecrosis of the jaw in oral and oropharyngeal cancer patients treated with intensity-modulated radiation therapy (IMRT): The Memorial Sloan Kettering Cancer Center experience. *Oral Oncol.* 2017;64:44-51.
44. Chang DT, Sandow PR, Morris CG, et al. Do pre-irradiation dental extractions reduce the risk of osteoradionecrosis of the mandible? *Head Neck.* 2007;29(6):528-536.
45. Chen JA, Wang CC, Wong YK, et al. Osteoradionecrosis of mandible bone in patients with oral cancer--associated factors and treatment outcomes. *Head Neck.* 2016;38(5):762-768.
46. Ben-David MA, Diamante M, Radawski JD, et al. Lack of osteoradionecrosis of the mandible after intensity-modulated radiotherapy for head and neck cancer: likely contributions of both dental care and improved dose distributions. *Int J Radiat Oncol Biol Phys.* 2007;68(2):396-402.

47. Studer G, Studer SP, Zwahlen RA, et al. Osteoradionecrosis of the mandible: minimized risk profile following intensity-modulated radiation therapy (IMRT). *StrahlentherOnkol.* 2006;182(5):283-288.
48. Ahmed M, Hansen VN, Harrington KJ, Nutting CM. Reducing the risk of xerostomia and mandibular osteoradionecrosis: the potential benefits of intensity modulated radiotherapy in advanced oral cavity carcinoma. *Med Dosim.* 2009;34(3):217-224.
49. Tsai CJ, Hofstede TM, Sturgis EM, et al. Osteoradionecrosis and radiation dose to the mandible in patients with oropharyngeal cancer. *Int J Radiat Oncol Biol Phys.* 2013;85(2):415-420.
50. Moon DH, Moon SH, Wang K, et al. Incidence of, and risk factors for, mandibular osteoradionecrosis in patients with oral cavity and oropharynx cancers. *Oral Oncol.* 2017;72:98-103.
51. Zhang W, Zhang X, Yang P, et al. Intensity-modulated proton therapy and osteoradionecrosis in oropharyngeal cancer. *Radiother Oncol.* 2017;123(3):401-405.
52. Rohrer MD, Kim Y, Fayos JV. The effect of cobalt-60 irradiation on monkey mandibles. *Oral Surg Oral Med Oral Pathol.* 1979;48(5):424-440.
53. Galler C, Epstein JB, Guze KA, Buckles D, Stevenson-Moore P. The development of osteoradionecrosis from sites of periodontal disease activity: report of 3 cases. *J Periodontol.* 1992;63(4):310-316.
54. Oh HK, Chambers MS, Garden AS, Wong PF, Martin JW. Risk of osteoradionecrosis after extraction of impacted third molars in irradiated head and neck cancer patients. *J Oral Maxillofac Surg.* 2004;62(2):139-144.
55. Wang X, Hu C, Eisbruch A. Organ-sparing radiation therapy for head and neck cancer. *Nat Rev Clin Oncol.* 2011;8(11):639-648.

56. Garden AS, Morrison WH, Wong PF, et al. Disease-control rates following intensity-modulated radiation therapy for small primary oropharyngeal carcinoma. *Int J Radiat Oncol Biol Phys.* 2007;67(2):438-444.
57. Lieshout HF, Bots CP. The effect of radiotherapy on dental hard tissue--a systematic review. *Clin Oral Investig.* 2014;18(1):17-24.
58. Brennan MT, Spijkervet FK, Elting LS. Systematic reviews and guidelines for oral complications of cancer therapies: current challenges and future opportunities. *Support Care Cancer.* 2010;18(8):977-978.
59. Nabil S, Samman N. Incidence and prevention of osteoradionecrosis after dental extraction in irradiated patients: a systematic review. *Int J Oral Maxillofac Surg.* 2011;40(3):229-243.
60. Wang TH, Liu CJ, Chao TF, Chen TJ, Hu YW. Risk factors for and the role of dental extractions in osteoradionecrosis of the jaws: A national-based cohort study. *Head Neck.* 2017;39(7):1313-1321.
61. Beech NM, Porceddu S, Batstone MD. Radiotherapy-associated dental extractions and osteoradionecrosis. *Head Neck.* 2017;39(1):128-132.
62. Jawad H, Hodson NA, Nixon PJ. A review of dental treatment of head and neck cancer patients, before, during and after radiotherapy: part 1. *Br Dent J.* 2015;218(2):65-68.
63. Fayle SA, Duggal MS, Williams SA. Oral problems and the dentist's role in the management of paediatric oncology patients. *Dent Update.* 1992;19(4):152-159.
64. Coffin F. The incidence and management of osteoradionecrosis of the jaws following head and neck radiotherapy. *Br J Radiol.* 1983;56(671):851-857.
65. Morton ME, Simpson W. The management of osteoradionecrosis of the jaws. *Br J Oral Maxillofac Surg.* 1986;24(5):332-341.

66. Epstein JB, Wong FL, Stevenson-Moore P. Osteoradionecrosis: clinical experience and a proposal for classification. *J Oral Maxillofac Surg.* 1987;45(2):104-110.
67. Clayman L. Clinical controversies in oral and maxillofacial surgery: Part two. Management of dental extractions in irradiated jaws: a protocol without hyperbaric oxygen therapy. *J Oral Maxillofac Surg.* 1997;55(3):275-281.
68. Schwartz HC, Kagan AR. Osteoradionecrosis of the mandible: scientific basis for clinical staging. *Am J Clin Oncol.* 2002;25(2):168-171.
69. Raggio BS, Winters R. Modern management of osteoradionecrosis. *Curr Opin Otolaryngol Head Neck Surg.* 2018;26(4):254-259.
70. van de Meent MM, Pichardo SEC, Rodrigues MF, Verbist BM, van Merkesteyn JPR. Radiographic characteristics of chronic diffuse sclerosing osteomyelitis/tendoperiostitis of the mandible: A comparison with chronic suppurative osteomyelitis and osteoradionecrosis. *J Craniomaxillofac Surg.* 2018;46(9):1631-1636.
71. Liu Z, Cao Y, Ma C, Sun J, Zhang C, He Y. Nomogram model to predict postoperative relapse after mandibular osteoradionecrosis surgery. *J Craniomaxillofac Surg.* 2018;46(11):1960-1967.
72. Kün-Darbois JD, Fauvel F. Medication-related osteonecrosis and osteoradionecrosis of the jaws: Update and current management. *Morphologie.* 2021;105(349):170-187.
73. White, Stuart C, Michael J. Pharoah. White and Pharoah's Oral Radiology: Principles and Interpretation. Elsevier Health Sciences, 2018. pp. 1068-1123.
74. Jacobson AS, Buchbinder D, Hu K, Urken ML. Paradigm shifts in the management of osteoradionecrosis of the mandible. *Oral Oncol.* 2010;46(11):795-801.
75. Mücke T, Konen M, Wagenpfeil S, Kesting MR, Wolff KD, Hölzle F. Low-dose preoperative chemoradiation therapy compared with surgery alone with or without

postoperative radiotherapy in patients with head and neck carcinoma. *Ann Surg Oncol.* 2011;18(10):2739-2747.

76. Mücke T, Koschinski J, Wagenpfeil S, et al. Functional outcome after different oncological interventions in head and neck cancer patients. *J Cancer Res Clin Oncol.* 2012;138(3):371-376.
77. Akashi M, Wanifuchi S, Iwata E, et al. Differences between osteoradionecrosis and medication-related osteonecrosis of the jaw. *Oral Maxillofac Surg.* 2018;22(1):59-63.
78. Grisar K, Schol M, Schoenaers J, et al. Osteoradionecrosis and medication-related osteonecrosis of the jaw: similarities and differences. *Int J Oral Maxillofac Surg.* 2016;45(12):1592-1599.
79. Epstein JB, Wong FL, Dickens A, Szasz I, Lepawsky M. Bone and gallium scans in postradiotherapy osteonecrosis of the jaw. *Head Neck.* 1992;14(4):288-292.
80. Mallya SM, Tetradis S. Imaging of Radiation- and Medication-Related Osteonecrosis. *Radiol Clin North Am.* 2018;56(1):77-89.
81. Dore F, Filippi L, Biasotto M, Chiandussi S, Cavalli F, Di Lenarda R. Bone scintigraphy and SPECT/CT of bisphosphonate-induced osteonecrosis of the jaw. *J Nucl Med.* 2009;50(1):30-35.
82. Van Assche N, Jacobs R, Coucke W, van Steenberghe D, Quirynen M. Radiographic detection of artificial intra-bony defects in the edentulous area. *Clin Oral Implants Res.* 2009;20(3):273-279.
83. Koth VS, Figueiredo MA, Salum FG, Cherubini K. Bisphosphonate-related osteonecrosis of the jaw: from the sine qua non condition of bone exposure to a non-exposed BRONJ entity. *DentomaxillofacRadiol.* 2016;45(7):20160049.

84. Gaêta-Araujo H, Vanderhaeghen O, Vasconcelos KF, et al. Osteomyelitis, osteoradionecrosis, or medication-related osteonecrosis of the jaws? Can CBCT enhance radiographic diagnosis?. *Oral Dis.* 2021;27(2):312-319.
85. Merine D, Fishman EK, Magid D. CT detection of sacral osteomyelitis associated with pelvic abscesses. *J Comput Assist Tomogr.* 1988;12(1):118-121.
86. Alhilali L, Reynolds AR, Fakhran S. Osteoradionecrosis after radiation therapy for head and neck cancer: differentiation from recurrent disease with CT and PET/CT imaging. *AJNR Am J Neuroradiol.* 2014;35(7):1405-1411.
87. Hermans R, Fossion E, Ioannides C, Van den Bogaert W, Ghekiere J, Baert AL. CT findings in osteoradionecrosis of the mandible. *Skeletal Radiol.* 1996;25(1):31-36.
88. Hermans R. Imaging of mandibular osteoradionecrosis. *Neuroimaging Clin N Am.* 2003;13(3):597-604.
89. Store G, Larheim TA. Mandibular osteoradionecrosis: a comparison of computed tomography with panoramic radiography. *DentomaxillofacRadiol.* 1999;28(5):295-300.
90. Dalinka MK, Mazzeo VP Jr. Complications of radiation therapy. *Crit Rev Diagn Imaging.* 1985;23(3):235-267.
91. Chong J, Hinckley LK, Ginsberg LE. Masticator space abnormalities associated with mandibular osteoradionecrosis: MR and CT findings in five patients. *AJNR Am J Neuroradiol.* 2000;21(1):175-178.
92. Bachmann G, Rössler R, Klett R, Rau WS, Bauer R. The role of magnetic resonance imaging and scintigraphy in the diagnosis of pathologic changes of the mandible after radiation therapy. *Int J Oral Maxillofac Surg.* 1996;25(3):189-195.
93. Storey MR, Garden AS, Morrison WH, Eicher SA, Schechter NR, Ang KK. Postoperative radiotherapy for malignant tumors of the submandibular gland. *Int J Radiat Oncol Biol Phys.* 2001;51(4):952-958.

94. Yoshioka H, Nakano T, Kandatsu S, Koga M, Itai Y, Tsujii H. MR imaging of radiation osteitis in the sacroiliac joints. *MagnReson Imaging*. 2000;18(2):125-128.
95. Joint Head and Neck Radiation Therapy-MRI Development Cooperative, Mohamed ASR, He R, et al. Quantitative dynamic contrast-enhanced MRI identifies radiation-induced vascular damage in patients with advanced osteoradionecrosis: Results of a prospective study. *Int J Radiat Oncol Biol Phys*. 2020;108(5):1319-1328.
96. Alexander JM. Radionuclide bone scanning in the diagnosis of lesions of the maxillofacial region. *J Oral Surg*. 1976;34(3):249-256.
97. Lapa C, Linz C, Bluemel C, et al. Three-phase bone scintigraphy for imaging osteoradionecrosis of the jaw. *Clin Nucl Med*. 2014;39(1):21-25.
98. Kaneda T, Minami M, Ozawa K, et al. Magnetic resonance imaging of osteomyelitis in the mandible. Comparative study with other radiologic modalities. *Oral Surg Oral Med Oral Pathol Oral RadiolEndod*. 1995;79(5):634-640.
99. Miyamoto I, Tanaka R, Kogi S, et al. Clinical Diagnostic Imaging Study of Osteoradionecrosis of the Jaw: A Retrospective Study. *J Clin Med*. 2021;10(20):4704.
100. Wong JK, Wood RE, McLean M. Conservative management of osteoradionecrosis. *Oral Surg Oral Med Oral Pathol Oral RadiolEndod*. 1997;84(1):16-21.
101. Owosho AA, Kadempour A, Yom SK, et al. Radiographic osteoradionecrosis of the jaw with intact mucosa: Proposal of clinical guidelines for early identification of this condition. *Oral Oncol*. 2015;51(12):e93-e96.
102. Somay E, Yilmaz B, Topkan E, Kucuk A, Pehlivan B, Selek U. Radiation-induced trismus: A concise review of pathogenesis, prevention and management. *Current Practice in Medical Science*. 2022; 8: 1-20.
103. Ogura I, Sasaki Y, Sue M, Oda T, Kameta A, Hayama K. Tc-99m hydroxymethylene diphosphonate scintigraphy, computed tomography, and magnetic resonance imaging of

osteonecrosis in the mandible: Osteoradionecrosis versus medication-related osteonecrosis of the jaw. *Imaging Sci Dent.* 2019;49(1):53-58.

- 104.** Obinata K, Shirai S, Ito H, et al. Image findings of bisphosphonate related osteonecrosis of jaws comparing with osteoradionecrosis. *DentomaxillofacRadiol.* 2017;46(5):20160281.
- 105.** Marx RE, Tursun R. Suppurative osteomyelitis, bisphosphonate induced osteonecrosis, osteoradionecrosis: a blinded histopathologic comparison and its implications for the mechanism of each disease. *Int J Oral Maxillofac Surg.* 2012;41(3):283-289.
- 106.** Watanabe H, Honda E, Tetsumura A, Kurabayashi T. A comparative study for spatial resolution and subjective image characteristics of a multi-slice CT and a cone-beam CT for dental use. *Eur J Radiol.* 2011;77(3):397-402.

## **Figure Legends**

**Figure 1.** Panoramic radiography of the left mandibular posterior region shows the sequestrum of osteoradionecrosis (red arrows).

**Figure 2.** In the axial cone beam computed tomography section of the left mandibular posterior region, the sequestrum of osteoradionecrosis is observed (red arrows).

## Tables

**Table 1.** The most commonly used classifications of osteoradionecrosis

<b>Researcher(s)</b>	<b>Year</b>	<b>Principle of classification</b>	<b>Characteristic of classification</b>
Marx (12)	1983	Response to management with HBO therapy and surgery	I: Responds to HBO therapy II: Requires HBO therapy and sequestrectomy III: Requires HBO therapy and advances surgical resection, also presented with pathological fracture, cutaneous fistula, and radiologically profound resorbed site.
Epstein et al. (63)	1987	*Clinical presentation and level of disease	I: Recovering II: Non-progressive, chronic disease III: Progressive, active disease
Notani et al. (25)	2003	The association of the disease with the alveolar bone and canal	I: Circumscribed to superficial alveolar bone II: Circumscribed to alveolar bone and above the level of the mandibular canal, involving the mandibular cortex and medullary bone III: Involving the mandible below the inferior alveolar canal, or pathological fracture, or skin fistula

\* Divided into secondary groups to indicate the absence or presence of pathological fracture.

*Abbreviation:* Hyperbaric oxygen; HBO.

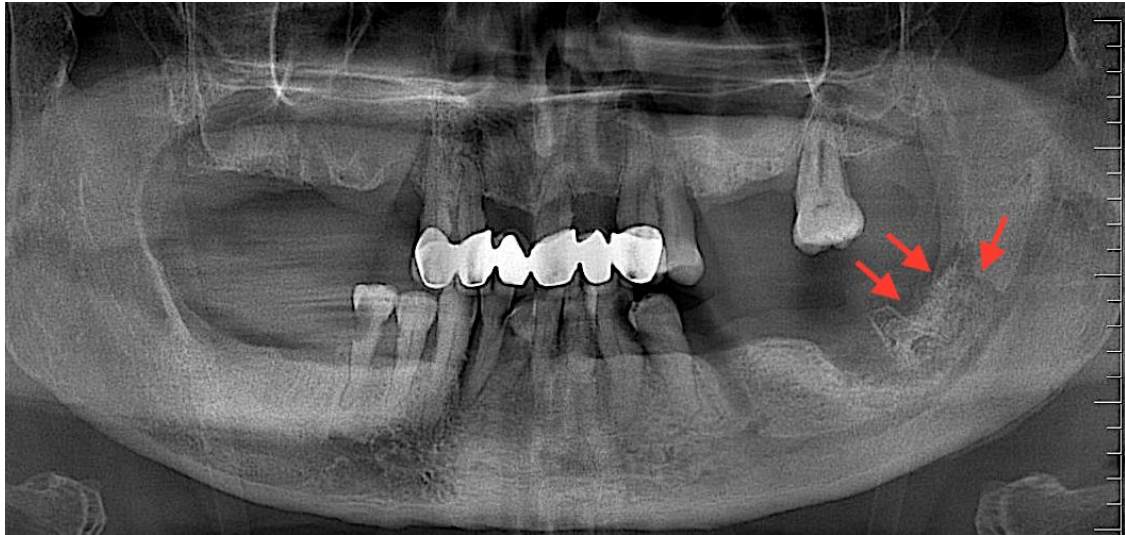
**Table 2.** Radiological findings of osteoradionecrosis in different imaging techniques

<b>Imaging technique</b>	<b>Point of reference</b>	<b>Radiological findings</b>
PI(13,70)	Bone alterations	Sclerotic boundaries Sequestrum Pathological fracture
CBCT (34,75,78)	Bone alterations	Lytic changes Cortical bone resorption Sclerotic areas Pathological fracture Sequestrum
CT(15,36,80,82)	Bone alterations	Cortical discontinuity Osteolysis Changes in trabecular structure Lingual and buccal bone deterioration Pathological fractures Sequestrum Bone sclerosis
MRI(82, 85, 86)	Bone marrow alterations	Aberrant, homogenous, low marrow signal intensity on T1-weighted images Increased signal intensity on T2-weighted images
	Muscular differences	Masticatory muscles thickening
Bone scintigraphy, SPECT(90, 91)	The efficiency of bone metabolic	Altered phosphate metabolisms Enhanced homogenous bone metabolism
PET(92)	Bone marrow and glucose metabolism activity	Hypermetabolic bone marrow Increased glucose metabolism Inflammatory soft tissue or tumor recurrence

*Abbreviations:* PI, Panoramic imaging; CBCT, cone beam computed tomography; CT, computed tomography; MRI, magnetic resonance imaging; PET, positron emission tomography; SPECT, single-photon emission CT.

**Figures**

**Figure 1**



**Figure 2**

