

## Case study

### A RARE CASE REPORT OF OSTEORADIONECROSIS MANDIBLE AFTER IRRADIATION FOR BREAST CANCER

Comment [A1]: Radionecrosis of mandible

#### ABSTRACT

Management of irradiated patients with cancer in the head and neck region is a challenging scenario. Radiotherapy promotes cellular and vascular insufficiency that results in a low response rate in the healing. Consequently, surgical procedures in irradiated tissues present high rates of complication. Osteoradionecrosis (ORN) is the most severe sequelae caused by radiotherapy. ORN can occur due to multiple reasons, of which periodontal disease, traumatic injury induced by ill-fitting dentures and trauma after surgery or tooth extraction are the most common. The management of this side effect is difficult and can result in bone or soft tissue loss, affecting the quality of life since majority of patients with ORN have various comorbidities associated. In this article we present a case report of osteoradionecrosis secondary to irradiation for breast cancer which is not frequently reported in literature.

Key words: Osteoradionecrosis, radiation, breast, mandible

#### INTRODUCTION

Radiotherapy is one of the important treatment modality in the management of malignant disease of the head and neck. Radiotherapy destroys all the cells with a high turnover rate. [1]. Even though bone is radio-resistant compared with other tissues, radiotherapy will seriously compromise in its blood supply and reparative ability. Osteoradionecrosis (ORN) is one of the most severe complications of radiation therapy [2]. Marx (1983) defined ORN as an area greater than 1 cm of exposed bone in a field of irradiation that failed to show any evidence of healing for at least 6 months [3]. Since majority of patients with ORN have various comorbidities associated, it is difficult to treat and often leads to poor outcome and deformity. ORN can occur due to various reasons, of which periodontal disease, traumatic injury induced by ill-fitting dentures and trauma after surgery or tooth extraction are the most common [2]. ORN is seen to be dependent on the technique of the RT used, in particular—the radiation dose to the bone. A total dosage of approximately 6500 to 7000 uGy or greater, particularly to the floor of the mouth and mandible significantly show elevated incidence of ORN of the mandible [3]. Dose rates in excess of 0.55 uGy/hour have also been seen to elevate the risk of ORN. ORN of mandible secondary to breast irradiation is not frequently reported in literature since site of irradiation in breast cancer is chest wall which is distant from mandible and this makes our case report unique.

Comment [A2]: Full form

Comment [A3]: Case history misses on vital information as to whether the patient has undergone previous radiotherapy for dental involvement.

Comment [A4]: No history of pernicious habits have been illustrated in the case history

Comment [A5]: Previous studies do not support this theory.

All studies report that no cases of ORN have been reported in cases receiving radiotherapy less than 6000cGy that too directly at the tooth site, leave radiation at other sites.

#### CASE REPORT

A 73 year old lady reported to our department with complaints of pain and swelling in the lower right back tooth region since three months duration. She was diabetic, dislipidemic and hypertensive. Patient also gave a history of breast cancer two year back (T2N2M1). For this she underwent left radical mastectomy and adjuvant chest wall RT with 5000 cGy in 25 fractions. This was followed by adjuvant

chemotherapy with 8 cycles of 5-fluorourasil, epirubicin, and cyclophosphamide after surgery. Dental extraction of 47 was done 3 months after the radiation therapy. Since then she gives a history of continuous pus discharge from the extraction socket (Fig.1). She first consulted a local dental clinic and was given antibiotic course for one week. The symptoms subsided after antibiotic therapy. However the symptoms had aggravated again.

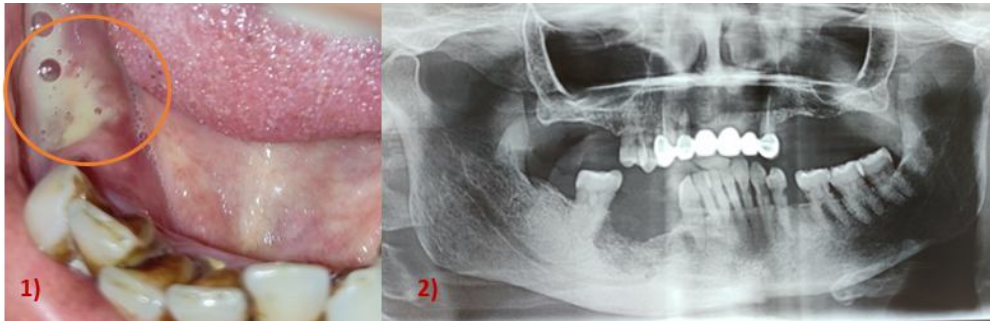


Fig: 1 – Pus discharge from extraction socket, Fig: 2 - OPG One year extraction

On examination, a non-healing extraction site was seen in relation to 47 with pus discharging from the extraction socket with obliteration of buccal vestibule and erythematous swollen area from 45 to 48. Paresthesia in relation to lateral one third of right lower lip was also noted. The site was non tender on palpation.

### Investigations

The pus was sent for culture and sensitivity, which revealed presence of aerobic streptococcus viridian's species (alpha haemolytic). Routine blood examinations revealed a slight elevation in creatinine level. CRP was also elevated slightly. An OPG (Fig. 2) was taken which showed moderate bone loss in relation to extraction site. CT mandible revealed ill-defined oblong area of mixed sclerosis and intramedullary lucency involving the body of mandible on right side with cortical defects and sequestrum.

### Management:

Initially a conservative management was planned and patient was given ampicillin 500mg, 6 hourly for 7 days, pentoxifyllin 400mg three times daily, and tocopherol 1000 IU daily therapy for 6 months. But even after long term medical management, symptoms didn't subside. Hence surgical management under GA was planned. Prior to surgery, the site was irrigated daily with saline-betadine solution in 1:1 ratio, Tab Pentoxifylline 400mg TID and Cap Evion 600mg BD was given for one week. Daily irrigation reduced the pus discharge. After substantial decrease in pus discharge, surgery was performed under GA. Following intraoral debridement, sequestrectomy and saucerization, a small pediatric nasogastric feeding tube 6 to 10 inches long in length was placed against the bony bed and secured in the vestibule with 4-0 silk sutures (Fig 3, 4, 5). Local drug delivery with gentamycin was given through the infant nasogastric tube for one week. Along with that Inj Accuzone plus 1.5g IV BD, pentoxifylline and evion was administered.

**Comment [A6]:** No surgical procedures are suggested post radiotherapy for a period atleast 6 to 12 months due to increased risk of .

**Comment [A7]:** Any draining sinus or lymphadenopathy ?

Why lymphnode examination was not conducted ?

**Comment [A8]:** Name and dosage of the drug

**Comment [A9]:** After what duration ?

**Comment [A10]:** Why biopsy was not performed for a definite diagnosis kindly explain

Even mri

**Comment [A11]:** Full form

**Comment [A12]:** Full form

**Comment [A13]:** Full form

**Comment [A14]:** Pictorial representation of ct kindly attach

**Comment [A15]:** Full form

**Comment [A16]:** Where is patients consent for the surgery mentioned ?

**Comment [A17]:** Why was no type of bone graft given to the patient ?

The patient was discharged after one week. At that time the surgical site has healed completely and the patient is in periodic follow up since then.

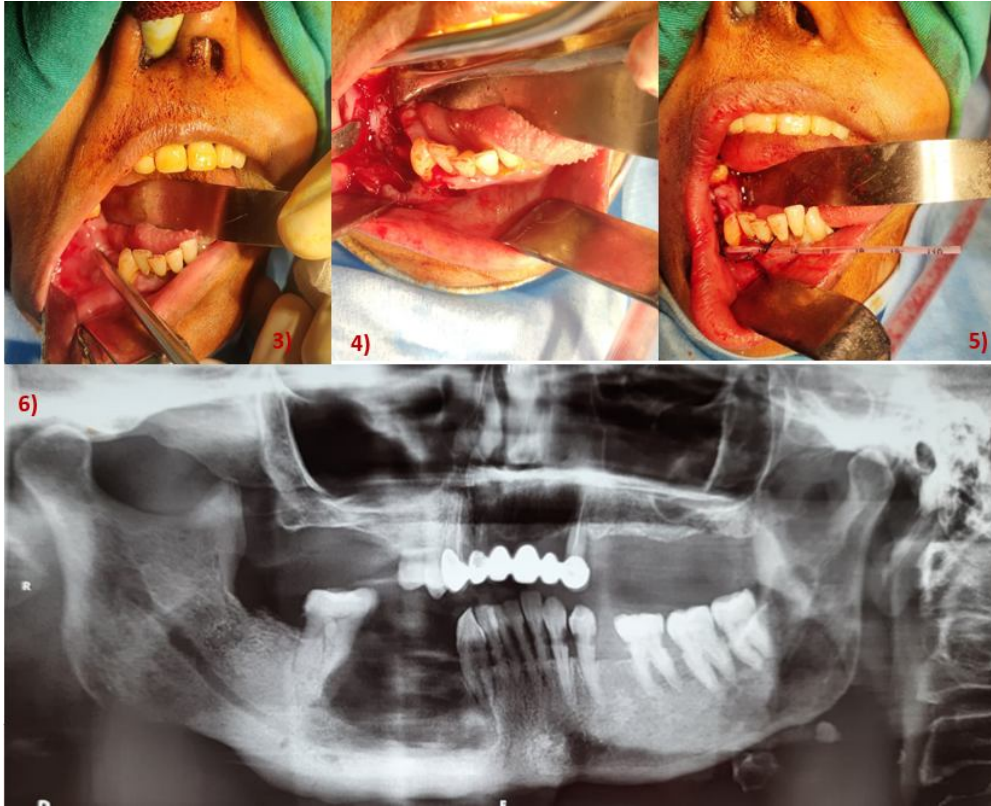

Fig: 3 – Site at the time of surgery, Fig: 4 – After sequestrectomy

Fig: 5 – After suturing, Fig: 6 – Post op OPG

**Comment [A18]:** Has the patient been given any prosthesis?

How did the treatment help the geriatric patient in normal mastication post surgery ?

**Comment [A19]:** Reason for exposing the patient to another radiation in the form of opg after surgery ?

## DISCUSSION

Malignant diseases of maxillofacial region are treated by (i) radiation therapy, (ii) surgery, (iii) chemotherapy, and (iv) combination therapy. Radiation often has serious effects on hard and soft tissues. Because of its inorganic composition, bone absorbs more energy than soft tissue and is more susceptible to radiation induced injuries. The effects of radiation on bone depend on the following four factors, viz: 1. Quality of radiation 2. Quantity of radiation 3. The location and extent of lesion 4. Condition of teeth and periodontium.

The late and major complication of therapeutic radiotherapy for head and neck cancer is osteoradionecrosis. Osteoradionecrosis was considered an infection initiated by injury to irradiated

bone before 20<sup>th</sup> century. Marx [4, 5] has shown that it is a chronic, non-healing wound caused by hypoxia, hypocellularity and hypovascularity of irradiated tissue. Before 1960's only ortho voltage irradiation was the available treatment modality which was highly deleterious to bone and the incidence of ORN was about to be 37% [6]. But shift from orthovoltage to megavoltage, targeted irradiation, collimation, dose fractionation etc. reduced the incidence to 2 to 5 percent [7]. Initially ORN was thought to be a triad of radiation, trauma and infection. Marx et al. [8] have shown that microorganisms are merely contaminants and trauma is only one of several factors involved in the disease.

Irradiation in chest wall for breast cancer usually do not cause ORN mandible. But if a supraclavicular field of irradiation is done in such cases, this may cause ORN of mandible as the irradiated field is in proximity with mandible.

Incidence:

ORN is common in mandible among facial bones which account about 2-3% [9, 10]. The second common bone involved in ORN is temporal bone.

Classification:

The following are the most accepted classification system of ORN.

**Comment [A20]:** How does the author intend to correlate a lesion in the mandible as orn without biopsy result and how does the author come to a correlation of breast cancer identified two years back and RT to a site away from the lesion ??

No correlation is found

**Comment [A21]:** Any evidence of this case receiving irradiation supraclavicularly ??? if so kindly submitt

**Comment [A22]:** In the complete manuscript the author does not describe what stage does this belong to and evidence for confirming it as orn

Table:  
of

Stage	Description	Symptoms	Treatment
I Ia Ib	Resolved, healed No pathologic fracture	None	Follow-up, prevention of recurrence
	Pathologic fracture		Reconstructed
II	Chronic, persistent non- progressive	None, or controlled	Local wound care Antiseptics/antibiotics, analgesics, hyperbaric oxygen (if indicated)
III	Active, progressive	Progressive	Local wound care Antiseptics/antibiotics, analgesics, hyperbaric oxygen (if indicated)

1. List

different symptoms and treatment by Epstein et al - 1987 [11]

Table: 2 List of different symptoms and treatment by Marx - 1983 [3]

Stage	Description	Symptoms	Treatment
I Ia Ib	<b>Resolved, healed</b> No pathologic fracture	None	Follow-up, prevention of recurrence
	Pathologic fracture		Reconstructed
II	Chronic, persistent non-progressive	None, or controlled	Local wound care Antiseptics/antibiotics, analgesics, hyperbaric oxygen (if indicated)
III	Active, progressive	Progressive	Local wound care Antiseptics/antibiotics, analgesics, hyperbaric oxygen (if indicated)

Pathophysiology:

Marx has described the three H principle in the development of ORN.

- (i) Hypocellularity,
- (ii) Hypovascularity of the irradiated tissues and
- (iii) Hypoxia.

But now the fibroatrophic theory (2014)[15] is gaining much importance which states that fibroblast populations undergo total cellular depletion and reduced ability to produce and secrete collagen into the surrounding tissue in response to radiation exposure. The sequence in the development of ORN is given below:

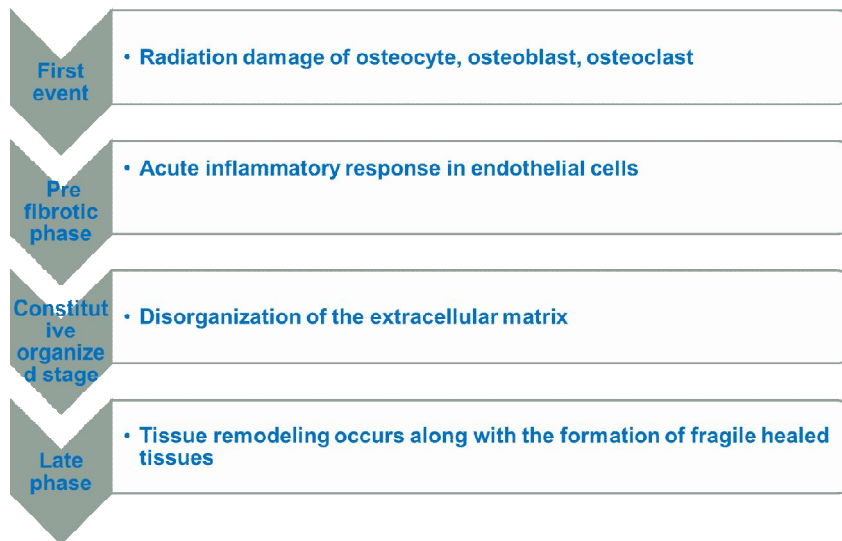


Image 1: Flow chart describing the fibroatrophic theory

Clinical features:

Severe deep boring pain with evidence of exposed bone are the chief presenting features. There may be associated trismus, fetid breath, pyrexia, soft tissue abscesses and persistently draining sinuses. Exposed bone is frequently associated with intraoral/extraoral fistulae. The exposed bone often has rough surface that abrades adjacent soft tissue and causes further discomfort.

Radiographic Features:

Very little radiographic change occurs in the early stages of the disease. The characteristic changes seen in osteomyelitis of non-irradiated bone (sequestra and involucra) occur late or not at all in irradiated bone because of severely compromised blood supply. Initial blood flow assays with nuclear isotope

**Comment [A23]:** Has the author examined the area where the radiation therapy was performed to find any soft tissue or hard tissue changes?

If there are no deleterious changes at the site where the RT was given how does the author hypothesize the correlation of breast cancer RT with mandibular bone changes?

**Comment [A24]:** Any fibroatrophic changes at the site of RT?

**Comment [A25]:** Does the patient give any history of RT exposed bone in the chest area giving pain?

**Comment [A26]:** What stage does the author define for the said patient? and justify the need of surgery if it was in the early phase

technetium-99 methylene diphosphate scanning can be of some benefit in assessing regional perfusion of the afflicted areas.

#### Management:

There is no universally accepted treatment for ORN. The management of ORN remains controversial, both radical and conservative treatments have been reported. Conservative treatment include systemic antibiotics, selective rinsing with topical antiseptics, and selective removal of small sequestra, curettage and local debridement. Radical treatment is indicated, where ORN is refractory to conservative treatment. HBO therapy was once one of the mainstays of treatment. But now it's not included as a definitive treatment modality and is used only as an adjunct [12, 13]. Circumscribed debridement can be performed in small necrotic areas, whereas large necrotic areas should be surgically removed [14]. All these procedures should be done as atraumatically as possible. Also the periosteum covering the intact bone should be preserved. Bone resection is performed, if there is persistent pain, infection or pathological fracture. It is preferably done intraorally, to avoid possibility of orocutaneous fistula in radiation-compromised skin. Studies have shown that combined use of pentoxifylline-tocopherol therapy has been effective in the management of septic ORN of the mandible. Because there is currently no standard medical treatment, this approach constitutes a useful alternative to existing therapies in treating ORN. The combinations of these two drugs act synergistically and are readily available, well tolerated and inexpensive [15]. Recently the use of PENTOCLO therapy is widely accepted which emphasizes on the combination of pentoxifylline- tocopherol-clodronate regimen [16]. However the use of clodronate is debatable as it may precipitate chemonecrosis/BRON J [17, 18, 19, 20].

#### Prevention:

Pre irradiation dental care of the teeth in direct beam of radiation should be performed. Non-restorable and periodontally compromised teeth should be extracted. Radiation therapy is delayed by 10 to 14 days to allow initial healing. Restoration of teeth, topical fluoride application and periodontal therapy should be completed before irradiation. If extraction is unavoidable after irradiation, the number should be limited to a minimum of one or two per appointment. Also extraction should be done atraumatically and without raising extensive flaps. It is mandatory to do extractions under antibiotic prophylaxis. Prophylactic use of pentoxifylline and tocopherol in such patients shows excellent results [21]. Time interval of extraction after irradiation has an important role in precipitation of ORN. As the time period increases chance of developing ORN also increases [21].

#### SUMMARY AND CONCLUSION

This case report highlights the need of proper precautions that should be taken before extractions and other surgical procedures in mandible for who had undergone chest wall irradiation. ORN of mandible secondary to chest wall irradiation is not common. However, if there is a history of supraclavicular field of irradiation, the possibility of development of ORN of mandible is very high.

#### REFERENCES

1. Nabil S, Samman N. Incidence and prevention of osteoradionecrosis after dental extraction in irradiated patients: a systematic review. Int J Oral Maxillofac Surg. 2011 Mar;40(3):229-43.
2. Beumer J, Harrison R, Sanders B, Kurrasch M. Osteoradionecrosis: predisposing factors and outcomes of therapy. Head Neck Surg 1984; 6: 819– 827.

**Comment [A27]:** Was this test suggested to the patient? if so kindly mention the institutes that provide this test

**Comment [A28]:** In the complete manuscript no where the author mentions the place/ institution at which this patient has reported

And most importantly the month and year this case was reported

When was the patient detected of breast cancer?  
What stage was the cancer defined?  
When was the surgery performed for breast cancer?  
When did the extraction take place?  
How many months patient took the medication?  
Did the extraction take place between the RT or after it was completed ?  
What family does the dugs belong ?

Does the author wants to correlate breast cancer as a result of long standing tooth infection or does the author want to relate radiotherapy on the chest with om in the mandible or does the author want to conclude that chemotherapy caused atrophic changes ? the scope of the manuscript seems to deviate and hypothesize an unclear correlation

Or microscopic finding is established as a factor for orn ?

**Comment [A29]:** So does the author want to say the treatment that was followed as controversial ??

**Comment [A30]:** Full form please

**Comment [A31]:** Was this adjunct used in the said case ? if not why ?

**Comment [A32]:** Any pathological fracture I the said case ?

**Comment [A33]:** Kindly elaborate the proper precautions with references

**Comment [A34]:** Kindly provide statistical data and reference how many post breast cancer RT cases turn out to be ORN within a period of 2 years in

3. Marx RE. Osteoradionecrosis: a new concept of its pathophysiology. *J Oral Maxillofac Surg.* 1983;41(5):283-8.
4. Marx RE. Chronic osteomyelitis of jaws, *Oral Maxillofac Surg Clin North Am.* 1991;3:367.
5. Marx RE. A new concept in the treatment of osteoradionecrosis. *J Oral Maxillofac Surg.* 1983;41(6):351-7.
6. Mark A Engleman, Gayle Woloschak, William Small Jr. Radiation-induced skeletal injury. In: William Small Jr, Gayle W (Eds). *Radiation Toxicity: A practical Guide, Volume 128.* US: Springer. 2006.pp.155-69.
7. Lauren O'Malley, et al. Improvement of radiological penumbra using intermediate energy photons (IEP) for stereotactic radiosurgery. *Phys Med Biol.* 2006;51:2537-48.
8. Marx RE, Carlson ER, Smith BR, et al. isolation of actinomyces species and Eikenella corrodens from patients with chronic diffuse sclerosing osteomyelitis. *JOMS.* 1994;52:2
9. Clayman L. Clinical controversies in oral and maxillofacial surgery: Part II. Management of dental extractions in irradiated jaws: a protocol without hyperbaric oxygen therapy. *J Oral Maxillofac Surg.* 1997;55:275-8.
10. Bras J, de Jonge HK, van Merkesteyn JP. Osteoradionecrosis of the mandible: pathogenesis. *Am J Otolaryngol.* 1990;11(4):244-50.
11. Epstein JB, Wong FL, Stevenson-Moore P: Osteoradionecrosis clinical experience and a proposal for classification. *J Oral Maxillofac Surg* 1987, 45:104–110.
12. Annane D, Depondt J, Aubert P, Villart M, Gehanno P, Gajdos P, et al. Hyperbaric oxygen therapy for radionecrosis of the jaw: a randomized, placebo-controlled, double-blind trial from the ORN96 study group. *J Clin Oncol.* 2004;22(24):4893–900.
13. Sultan A, Hanna GJ, Margalit DN, Chau N, Goguen LA, Marty FM, et al. The use of hyperbaric oxygen for the prevention and Management of Osteoradionecrosis of the jaw: a Dana-Farber/Brigham and Women's Cancer center multidisciplinary guideline. *Oncologist.* 2017;22(3):343–50.
14. Pitak-Arnnop P, Sader R, Dhanuthai K, Masaratana P, Bertolus C, Chaine A, et al. Management of osteoradionecrosis of the jaws: an analysis of evidence. *Eur J Surg Oncol.* 2008;34(10):1123–34.
15. Delanian S, Lefaix JL: The radiation-induced fibroatrophic process: therapeutic perspective via the antioxidant pathway. *Radiother Oncol* 2014, 73:119–131.
16. Medical treatment of osteoradionecrosis of the mandible by PENTOCLO: Preliminary results : Robard M, Y.Louis,D.Blanchard E,.Babin: *European Annals of Otorhinolaryngology, Head and Neck Diseases*,Volume 131, Issue 6 , December 2014, Pages 333-33.
17. Hagelauer N, Ziebart T, Pabst AM, Walter C. Bisphosphonates inhibit cell functions of HUVECs, fibroblasts and osteogenic cells via inhibition of protein geranylgeranylation. *Clin Oral Investig.* 2015;19(5):1079–91.
18. Ruggiero SL, Dodson TB, Fantasia J, Goodday R, Aghaloo T, Mehrotra B, et al. American association of oral and maxillofacial surgeons position paper on medication-related osteonecrosis of the jaw--2014 update. *J Oral Maxillofac Surg.* 2014;72(10):1938–56.
19. Rugani P, Walter C, Kirnbauer B, Acham S, Begus-Nahrman Y, Jakse N. Prevalence of medication-related osteonecrosis of the jaw in patients with breast cancer, prostate cancer, and multiple myeloma. *Dent J (Basel).* 2016;4(4):32.

20. Pabst AM, Ziebart T, Ackermann M, Konerding MA, Walter C. Bisphosphonates' antiangiogenic potency in the development of bisphosphonate-associated osteonecrosis of the jaws: influence on microvessel sprouting in an in vivo 3D Matrigel assay. *Clin Oral Investig*. 2014;18(3):1015–22.
21. Aggarwal K, Goutam m, Singh M, Kharat N, Singh V, Vyas S, et al. Prophylactic use of pentoxifylline and tocopherol in patients undergoing dental extractions following radiotherapy for head and neck cancer. *Niger J Surg* 2017;23:130-3.