*Original Research Article*

# Role of Magnetic Resonance Imaging in Evaluation of Ankle Impingement Syndrome


## Abstract

**Background:** Ankle impingement is the painful mechanical restriction of complete ankle range of motion caused by an osseous or soft-tissue deformity. Ankle impingement syndromes are prevalent and significant post-traumatic sources of morbidity in professional and amateur sports. The aim of this research is to evaluate the role of Magnetic Resonance Imaging (MRI) in diagnosis of ankle impingement syndromes.

**Methods:** This prospective study was performed on 40 consecutive patients aged from 20 to 55 years old, with clinical diagnosis of ankle impingement, 21 (52.5%) of them were males and 19 (47.5%) were females. All patients were subjected to full history taking [personal history, history of present illness (onset, course and duration; pain, swelling, limitation of movement, and other symptoms)], clinical Examination was carried out by the colleagues in the Orthopaedic department and MRI examination where all patients were examined with closed superconductive 1.5 T magnet (GE SIGNA Explorer), using the extremity coils.

**Results:** 26 out of the 28 cases with clinically suspected posterior impingement were correctly diagnosed by MRI (sensitivity of 92.86%, specificity of 100% and accuracy of 92.86%) and other two cases showed synovial effusion. 3 out of the 4 cases with clinically suspected anterolateral impingement were correctly diagnosed by MRI (sensitivity of 75%, specificity of 100% and accuracy of 75%) and other case showed sinus tarsi. All the 4 cases with clinically suspected anterior, anterolateral impingement were correctly diagnosed by MRI (sensitivity of 100%, specificity of 100% and accuracy of 100%). Totally, MRI sensitivity in diagnosis impingement was 92.5%, specificity was 100% and accuracy was 92.5%).

**Conclusions:** MRI exhibits excellent overall sensitivity, specificity, and accuracy in the diagnosis of ankle impingement. MRI displays rather definite anatomic and pathologic details, with outstanding outlining of both bony and soft tissue structures. Moreover, it assists in the exclusion of other mimic similar conditions.



**Keywords:** Magnetic Resonance Imaging, Diagnosis, Ankle Impingement Syndrome.


## Introduction:

Ankle impingement is the painful mechanical restriction of complete ankle range of motion caused by an osseous or soft-tissue deformity [1, 2].

Ankle impingement syndromes are prevalent and significant post-traumatic sources of morbidity in professional and amateur sports [3].

Bone impingement, soft tissue impingement, and entrapment neuropathy are the morphological and clinical classifications of ankle impingement, depending on which joint piece impinges on the others [4].

Impingement syndromes in the ankle involve a vast range of disease with diverse causes, anatomic characteristics, and manifestations; despite the fact that no formal categorization exists, these syndromes are often described by the anatomic region affected. Specific anterior, anteromedial, anterolateral, posterior, posterolateral, posteromedial and syndesmotic impingements have been explained [5] .

In general, anterior ankle impingement indicates the trapping of tissues at the anterior edge of the tibiotalar joint during terminal dorsiflexion. Multiple osseous and soft tissue anatomic anomalies have been identified as etiological factors [6].

During terminal plantar flexion, compression of tissues posterior to the tibiotalar and talocalcaneal articulations causes posterior ankle impingement.

Similarly, this may be produced by a various osseous and soft tissue etiologies alone or in combination [6].

The clinical diagnosis of ankle impingement is supported by radiographs and sophisticated imaging techniques [CT, magnetic resonance imaging (MRI) and Ultrasound] [3].

MRI is the most effective imaging modality for identifying osseous and soft tissue anomalies in these disorders and excluding other possible causes of persistent ankle pain [7].

Despite conventional radiography being usually the first imaging technique utilized to assess any potential bony abnormalities, soft-tissue affection usually escapes and it has disadvantages of improper assessment of cartilaginous, ligamentous, and tendinous lesions [8].

Due to its improved soft tissue contrast and capacity to scan in several planes, MRI is especially suitable for evaluating the complicated bone and soft tissue anatomy of the foot and ankle. In addition, new quick scan methods increase efficiency and enable the performance of dynamic research. In recent years, the MR arthrography technology has advanced dramatically, resulting in a greater prevalence of its application [7].

This research objects to evaluate the role of MRI in diagnosis of ankle impingement syndromes.

## Patients and Methods:

This prospective study was performed on 40 consecutive patients aged from 20 to 55 years old, with clinical diagnosis of ankle impingement, 21 (52.5%) of them were males and 19 (47.5%) were females, who were referred to Radiodiagnosis and Imaging Department in the period between December 2019 to May 2021.

Patients with clinical diagnosis of ankle impingement and both genders were included with no age or gender predilection.

Patients known to have contraindications MRI e.g., an implanted magnetic device, cochlear implantation, metallic foreign body in the eye, an aneurysm clip or pacemakers were excluded from the research.

All patients underwent full history taking [personal history, history of present illness (onset, course and duration; pain, swelling, limitation of movement, and other symptoms)], clinical Examination was carried out by the colleagues in the Orthopedic department and MRI examination where all patients were examined with closed superconductive 1.5 T magnet (GE SIGNA Explorer), using the extremity coils.

**Patient preparation:** Patients were asked to remove all metal objects, a chaperone was provided for claustrophobic patients (e.g., relative or staff) as far as possible, earplugs or headphones were offered, procedure was explained to the patient and patients were instructed to keep still.

**Patient positioning:** Patients were positioned in supine with feet pointed towards the magnet (feet first supine), ankle was positioned in the foot and ankle coil at 90° angle, foot was tightened securely by cushions to avoid movement, For added comfort, a cushion was put beneath the patient's head, and the laser beam localizer was positioned over the ankle joint.

**Localizer:** An initial three-plane localizer was used to localize and design the sequences. Typically, localizers are shorter than 25 seconds. T1 weighted low resolution scans.

**Image analysis:** All images were loaded to a workstation (General Electrical). Evaluation of the ankle and imaging interpretation were conducted. Reports were written for every case after examining the MRI sequences. Images were evaluated for the presence of any impingement cause, abnormal marrow signal, cortical lining disruption, ligaments and tendons integrity joint effusion and capsular abnormality.

**Outcome measures:** The primary outcome measures were the prevalence and the MRI findings of each impingement

type. The secondary outcome was the comparison between the clinical diagnosis and the MRI findings of the included cases with evaluation of MRI sensitivity and specificity for diagnosis of ankle impingement.

**Statistical analysis**

Using Statistical Package for the Social Sciences (SPSS) version 22.0, data were tabulated and entered into a computer. Calculations were made for the mean, standard deviation, and frequency and proportion of non-numerical variables. Comparing clinical and MRI diagnosis, the sensitivity, specificity, positive predictive value, negative predictive value, and accuracy of MRI were determined.

## Results:

Table 1 shows distribution of studied cases according to patient's demographic data, side of complaint, patient's clinical manifestations, site of impingement in ankle and patient's MRI findings

**Table 1: Distribution of studied cases according to patient's demographic data, side of complaint, patient's clinical manifestations, site of impingement in ankle and patient's MRI findings**

| | | **Study participants (n=40)** | **Sex** | |
|---|---|---|---|---|
| | | **N (%)** | **Male** | **Female** |
| **Age (years)** | **20-< 30** | 13 (32.5%) | 7 | 6 |
| | **30-< 40** | 9 (22.5%) | 5 | 4 |
| | **40-< 50** | 13 (32.5%) | 8 | 5 |
| | **≥50** | 5 (12.5%) | 1 | 4 |
| | **Total** | 40 (100%) | 21(52.5%) | 19 (47.5%) |
| | **Range** | 20-55 | | |
| | **Mean ± S. D** | 37.15±11.070 | | |
| **Affected Side** | **Left** | 24 (60%) | | |
| | **Right** | 16 (40%) | | |
| | **Total** | 40 (100%) | | |
| **Clinical manifestations** | **Pain** | 40 (100%) | | |
| | **Limitation of movement** | 40 (100%) | | |
| | **Swelling** | 11 (27.5%) | | |
| | **Clicking** | 9 (22.5%) | | |
| **Site of ankle impingement** | **Posterior ankle impingement** | 28 (70%) | | |
| | **Anterolateral ankle impingement** | 4 (10%) | | |
| | **Anterior ankle impingement** | 4 (10%) | | |
| | **Combined anterior and posterior ankle impingement** | 4 (10%) | | |
| | **Total** | 40 (100%) | | |
| **MRI findings** | **Stieda process** | 16 (40%) | | |

| | | |
|---|---|---|
| | **Fractured Stieda process** | 7 (17.5%) |
| | **Os trigonum** | 7 (17.5%) |
| | **Thickened posterior talofibular ligament (PTFL)** | 3 (7.5%) |
| | **Flexor hallucislongus (FHL) tenosynovitis** | 19 (47.5%) |
| | **Thickened intermalleolar ligament** | 2 (5%) |
| | **Anterior tibio-talar spur** | 6 (15%) |
| | **anterior tibio-fibularthickening** | 1 (2.5%) |
| | **Os fibulare** | 1 (2.5%) |
| | **Anterolateral gutter granulation tissue** | 1 (2.5%) |
| | **Synovial thickening** | 7 (17.5%) |
| | **Soft tissue edema** | 16 (40%) |
| | **Bone cystic changes** | 15 (35%) |
| | **Bone marrow edema** | 33 (82.5%) |
| | **Joint effusion** | 34 (85%) |

Data are presented as mean ± SD or frequency (%).

Table 2 shows demographic data, clinical presentation and MRI data of cases with posterior impingement

**Table 2: Demographic data, clinical presentation and MRI data of cases with posterior impingement**

| | | **Posterior impingement (n=28)** |
|---|---|---|
| | | **N (%)** |
| **Age (years)** | **20- <30** | 9 (32.1%) |
| | **30 - < 40** | 6 (21.4%) |
| | **40 - < 50** | 10 (35.7%) |
| | **≥50** | 3 (10.8%) |
| **Sex** | **Males** | 17 (60.7%) |
| | **Females** | 11 (39.3%) |
| **Side** | **Left** | 16 (57.2%) |
| | **Right** | 12 (42.8%) |
| **Clinical presentation** | **Pain** | 28 (100%) |
| | **Limitation of movement** | 28 (100%) |
| | **Swelling** | 6 (21.4%) |
| | **Clicking** | 4 (14.3%) |
| **MRI findings** | **Stieda process** | 12 (42.9%) |
| | **Fractured Stieda process** | 7 (25%) |
| | **Os trigonum** | 7 (25%) |
| | **Thickened PTFL** | 3 (10.7%) |
| | **FHL tenosynovitis** | 17 (60.7%) |
| | **Thickened intermalleolar ligament** | 2 (7.1%) |
| | **Synovial thickening** | 3 (10.7%) |
| | **Soft tissue edema** | 10 (35.7%) |
| | **Bone cystic changes** | 10 (35.78%) |
| | **Bone marrow edema** | 21 (75%) |
| | **Joint effusion** | 22 (78.6%) |

Data are presented as frequency (%).

Table 3 shows Demographic data, clinical presentation and MRI data of cases with antero-lateral impingement

**Table 3: Demographic data, clinical presentation and MRI data of cases with antero-lateral impingement**

| | | Anterolateral impingement (n=4) |
|---|---|---|
| | | N (%) |
| Age (years) | 20-<30 | 1 (25%) |
| | 30-< 40 | 2 (50%) |
| | 40- < 50 | 0 (0%) |
| | ≥ 50 | 1 (25%) |
| Sex | Males | 2 (50%) |
| | Females | 2 (50%) |
| Side | Left | 2 (50%) |
| | Right | 2 (50%) |
| Clinical presentation | Pain | 4 (100%) |
| | Limitation of movement | 4 (100%) |
| | Swelling | 2 (50%) |
| | Clicking | 1 (25%) |
| MRI findings | Thickened intact anterior tibiofibular ligament | 2 (50%) |
| | Os fibulare | 1 (25%) |
| | Anterolateral gutter granulation tissue | 1 (25%) |
| | Synovial thickening | 2 (50%) |
| | Soft tissue edema | 2 (50%) |
| | Bone cystic changes | 1 (25%) |
| | Bone marrow edema | 4 (100%) |
| | Joint effusion | 4 (100%) |

Data are presented as frequency (%).

Table 4 shows demographic data, clinical presentation and MRI findings of cases with anterior impingement

**Table 4: Demographic data, clinical presentation and MRI findings of cases with anterior impingement**

| | | Anterior impingement (n=4) |
|---|---|---|
| | | N (%) |
| Age (years) | 20-<30 | 1 (25%) |
| | 30 - < 40 | 1 (25%) |
| | 40 - <50 | 1 (25%) |
| | ≥ 50 | 1 (25%) |
| Sex | Males | 1 (25%) |
| | Females | 3 (75%) |
| Side | Left | 3 (75%) |
| | Right | 1 (25%) |
| Clinical presentation | Pain | 4 (100%) |
| | Limitation of movement | 4 (100%) |
| | Swelling | 2 (50%) |
| | Clicking | 2 (50%) |
| MRI findings | Anterior tibio-talar spur | 3 (75%) |
| | Synovial thickening | 1 (25%) |
| | Soft tissue edema | 2 (50%) |
| | Bone cystic changes | 2 (50%) |
| | Bone marrow edema | 4 (100%) |
| | Joint effusion | 4 (100%) |

Data are presented as frequency (%).

Table 5 shows demographic data, clinical presentation and MRI findings of cases with combined posterior and anterior impingement

**Table 5: Demographic data, clinical presentation and MRI findings of cases with combined posterior and anterior impingement**

| | | Combined posterior and anterior impingement (n=4) |
|---|---|---|
| | | N (%) |
| Age (years) | 20-< 30 | 2 (50%) |
| | 30 - < 40 | 0 (0%) |
| | 40 - <50 | 2 (50%) |
| | ≥ 50 | 0 (0%) |
| Sex | Males | 1 (25%) |
| | Females | 3 (75%) |
| Side | Left | 3 (75%) |
| | Right | 1 (25%) |
| Clinical presentation | Pain | 4 (100%) |
| | Limitation of movement | 4 (100%) |
| | Swelling | 1 (25%) |
| | Clicking | 2 (50%) |
| MRI findings | Stieda process | 4 (100%) |
| | FHL tenosynovitis | 2 (50%) |
| | Anterior tibio-talar spur | 3 (75%) |
| | Loose bodies | 1 (25%) |
| | Synovial thickening | 1 (25%) |
| | Soft tissue edema | 2 (50%) |
| | Bone cystic changes | 2 (50%) |
| | Bone marrow edema | 4 (100%) |
| | Joint effusion | 4 (100%) |

Data are presented as frequency (%).

Regarding posterior impingement, 26 out of the 28 cases were correctly diagnosed by MRI (sensitivity of 92.86%, specificity of 100% and accuracy of 92.86%). All cases of anterior and combined impingement were correctly diagnosed (sensitivity, specificity and accuracy of 100%), while for anteriolateral impingement, MRI correctly diagnosed 3 out of 4 cases (sensitivity of 75%, specificity of 100% and accuracy of 75%). Totally, MRI sensitivity in diagnosis impingement was 92.5%, specificity was 100% and accuracy was 92.5%). Table 6

**Table 6: Demographic data, clinical presentation and MRI findings of cases with combined posterior and anterior impingement**

| | Posterior impingement (n=28) | Antero-lateral impingement (n=4) | Anterior impingement (n=4) | Combined impingement (n=4) | Total (n=40) |
|---|---|---|---|---|---|
| True positive cases | 26 | 3 | 4 | 4 | 37 |
| True negative cases | 0 | 0 | 0 | 0 | 0 |
| False positive cases | 0 | 0 | 0 | 0 | 0 |
| False negative cases | 2 | 1 | 0 | 0 | 3 |
| Sensitivity | 92.86% | 100% | 75% | 100% | 92.5% |
| Specificity | 100% | 100% | 100% | 100% | 100% |
| Accuracy | 92.86% | 100% | 75% | 100% | 92.5% |

Data are presented as frequency (%).

Figure 1 shows MRI examination of a male patient, 40 years old, with left ankle pain and clinical diagnosis of posterior ankle impingement.

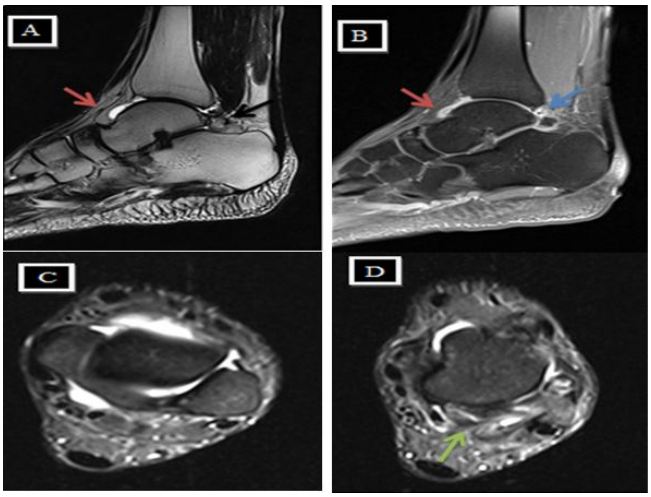


**Figure 1: MRI examination, (A) Sagittal T2 WI showed os trigonum (black arrow). (B) Sagittal T2 WI with fat saturation showed os trigonum with surrounding soft tissue edema (blue arrow). Minimal joint effusion is seen (red arrows in A& B). (C) and (D) Axial T2 WI with fat saturation showed mild joint effusion and soft tissue edema posterior to talus (green arrow). Final diagnosis: Posterior ankle impingement**

Figure 2 shows MRI examination of a male patient, 57 years old, with chronic left ankle pain.

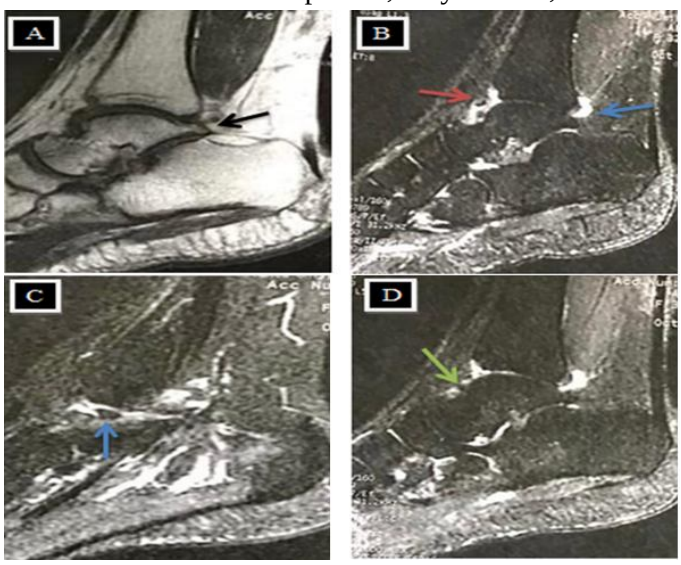


**Figure 2: MRI examination, (A) Sagittal T1 WI showed prominent lateral tubercle of the talus (Stieda process) (black arrow). (B) Sagittal T2 –FS weighted image showed retro-talar fluid (blue arrow), synovial thickening and anterior tibio-talar fluid pocket. (C) Sagittal T2 –FS WI showed inferior tibio-talar loose body (blue arrow). (D) Sagittal T2 –FS WI showed tiny loose body seen anterior to talus (green arrow), denoting anterior and posterior impingement. Final diagnosis: Combined anterior and posterior ankle impingement**

## Discussion

MRI has revolutionised the diagnosis and treatment of the majority of ankle joint disorders. It enabled the detection of a wide variety of bone changes and a variety of disorders in soft tissues such as tendons, ligaments, and synovial membranes [9]. Due to its enhanced soft-

tissue contrast and multiplanar imaging capabilities, MRI is well-suited for examining the complex bone and soft-tissue anatomy of the foot and ankle. In addition, new quick scan methods increase efficiency and enable the performance of dynamic research [10] .

According to clinical presentations in the present study, the most common encountered site of ankle impingement was posterior ankle impingement (28 patients; 70%), followed by anterior ankle impingement (4 patients; 10%), anterolateral ankle impingement (4 patients; 10%) and combined anterior with posterior ankle impingement (4 patients; 10%). Our findings agreed with El-Zawawi et al. [7] and Zeitoun et al. [11], who reported that posterior ankle impingement was the predominant type in their study cases.

Berman et al. [12], described typical presentation of the ankle impingement syndrome to be considered as a limited range of motion and discomfort while executing certain joint motions. Pain and limitation of ankle joint movement were found in all patients in the current research.

In the current study, MRI was done for all cases, the osseous abnormalities were Stieda process, os trigonum, os fibulare, anterior tibio-talar spur, bone cystic changes, and bone marrow edema. While the soft tissue abnormalities were FHL tenosynovitis, thickened PTFL, thickened intermalleolar ligament, thickened anterior tibio-fibular ligament, synovial thickening, soft tissue edema, and joint effusion.

Donovan and Rosenberg [13], reported that MRI is particularly useful for detecting reasons of chronic ankle discomfort that coexist with ankle impingement, such as concealed fractures, cartilage degradation, tendon abnormalities, osteochondral talar lesions, ankle instability and intraarticular bodies.

Imaging is useful for verifying the diagnosis of posterior ankle impingement and ruling out other potential causes of posterior ankle discomfort, such as flexor hallucis longus tendon injuries or tenosynovitis [14].

MRI findings in posterior ankle impingement cases in the present study were Stieda process either intact (42.9%), or fractured (25%), os trigonum (25%), FHL tenosynovitis (60.7%), thickened PTFL (10.7%), thickened intermalleolar ligament (7.1 %), synovial thickening (10.7%), soft tissue edema (35.7%), bone cystic changes (35.7%), bone marrow edema (75%) and joint effusion (78.6%).

In agreement with our findings, Berman et al. (2017) [12] , reported that most posterior impingement syndromes are associated with the posterior talus. Rarely, the secondary ossification centre of the posterolateral talus may stay conspicuous with the so-called "Stieda's process" or demonstrate non-fusion with a consequent os trigonum. The most prevalent cause of posterior impingement is pathology related with the lateral process of the posterior talus.

Also, Sofka [14], stated that besides secondary symptoms that might explicitly imply the existence of posterior ankle impingement, MRI can determine the aetiology of impingement. Increased signal intensity in the soft tissue posterior to the ankle, thickening of the posterior joint capsule, and an oedematous pattern in the bone marrow of the posterior talus are all indicative of posterior ankle impingement.

Donovan and Rosenberg [13], described that conventional MRI can exactly distinguish anomalies at the synchondrosis involving opposing fluid signal or marrow edema at the synchondrosis linked to motion and that soft-tissue anomalies at the posterior ankle such as ligament disruption, FHL tenosynovitis, posterior capsular thickening, and soft-tissue edema and synovitis can also be well described by MRI.

In this study the MRI findings of the clinically diagnosed anterior ankle impingement cases were anterior tibio-talar spur (75%), joint effusion (100%), bone marrow edema (100%), synovial thickening (25%), and soft tissue edema (50%). This is consistent with Al-Riyami et al. [15] who reported that MRI of the ankle joint is helpful in detecting capsular thickness and

synovial inflammation in the anterior tibiotalar joint, and bone marrow edema is often seen in patients with anterior ankle impingement syndrome.

Also, Donovan & Rosenberg [13] reported that the predominant abnormality detected in MRI in cases of anterior ankle impingement was spur formation along the anterior tibial rim, and is often associated with by synovitis and thickening of soft-tissue in the anterior recess. However, in variance with our findings, they reported that marrow edema is uncommonly seen with anterior ankle impingement.

In our study the MRI findings in cases of anterolateral impingement were thickened intact anterior tibiofibular ligament (50%), os fibulare (25%), anterolateral gutter granulation tissue (25%), bone marrow edema (100%), joint effusion (100%), synovial thickening (50%), soft tissue edema (50%), bone cystic changes in (25%). Within the same context, Choo et al. [16] studied 45 patients with arthroscopically confirmed anterolateral impingement. Patients demonstrated soft tissue fullness at the anterolateral gutter of the ankle or fuzzy and noticeable thickening of the anterior talofibular ligament.

Al-Riyami et al. [15] stated that Os fibulare may produce anterior talofibular ligament impingement, resulting in anterolateral ankle impingement.

Anterolateral impingement is believed to originate from an inversion injury that damages the syndesmotic and/or lateral collateral ligaments and capsule. Recurrent microtrauma and subclinical microinstability may proceed to soft-tissue abnormalities in the anterolateral gutter, despite the fact that the initial injury is often minor and does not result in clinical ankle instability. After an ankle sprain, ligamentous and capsular tears, microinstability, and bleeding may cause reactive synovial hyperplasia and scarring in the anterolateral gutter [13].

The current study included four patients with clinically suspected combined posterior and anterior ankle impingement, they presented with pain and limitation of movement during flexion, while 1 (25%) patient had ankle swelling and 2 (50%) patients had clicking. The MRI findings were combination of the findings classical for both types of impingements. The co-existence of more than one type of impingement was previously described by Henderson & Valette (2004) [17], Zeitoun et al. [11] and Qin et al. [18].

In regard to the comparison between clinical and MRI diagnosis in the present work, MRI had sensitivity of 92.86%, specificity of 100% and accuracy of 92.86% in diagnosis of posterior ankle impingement, all cases of anterior and combined ankle impingement were correctly diagnosed by MRI with sensitivity, specificity and accuracy of 100%, while for anterolateral impingement, MRI had sensitivity of 75%, specificity of 100% and accuracy of 75%. Totally, MRI sensitivity in diagnosis impingement was 92.5%, specificity was 100% and accuracy was 92.5%.

El-Zawawi et al. [7] found that on comparing clinical and MRI diagnosis in the 90 scanned ankles, MRI yielded a sensitivity of 89.2%, specificity of 100%, and accuracy of 100% in diagnosis of ankle impingement syndrome.

Also, Duncan et al. [19], declared that concerning the usefulness of MRI in the diagnosis of anterolateral impingement of the ankle, MRI was helpful in making the diagnosis, with sensitivities varied from 0.75 to 0.83, whereas specificities varied from 0.75 to 1.00. Also Ferkel et al. [20],have shown an MRI sensitivity of 83%, specificity of 78.6% and accuracy of 78.9% for the diagnosis of anterolateral impingement. However, it was reported by Donovan & Rosenberg, (2010) [13] that the effectiveness of standard nonorthographic MRI to identify anterolateral gutter soft-tissue anomalies stays debatable, with a broad range of sensitivities (39–100%) and specificities (50–100%).

## Conclusions:

The current research emphasized the significance of MRI in the assessment of ankle impingement cases. MRI exhibits excellent overall sensitivity, specificity, and accuracy in the diagnosis of ankle impingement. MRI displays rather definite anatomic and pathologic

details, with outstanding outlining of both bony and soft tissue structures. Moreover, it assists in the exclusion of other mimic similar conditions.

**Ethical Approval**

This study was conducted after the approval of the Tanta university research ethical committee.

**Consent**

As per international standard or university standard, patients' written consent has been collected and preserved by the author(s).

## References:


1. Sanders TG, Rathur SK. Impingement syndromes of the ankle. Magn Reson Imaging Clin N Am. 2008;16:29-38.
2. Donovan A, Rosenberg ZS. MRI of ankle and lateral hindfoot impingement syndromes. AJR. 2010;195:595-604.
3. Russo A, Zappia M, Reginelli A, Carfora M, D'Agosto G, La Porta M, et al. Ankle impingement: a review of multimodality imaging approach. Musculoskelet Surg. 2013;97:161-8.
4. Lima CMAdO, Ribeiro EB, Coutinho EPD, Vianna EM, Domingues RC, Coutinho Júnior AC. Magnetic resonance imaging of ankle impingement syndrome: iconographic essay. Radiol Bras 2010;43:53-7.
5. Dimmick S, Linklater J. Ankle impingement syndromes. Radiol Clin North Am. 2013;51:479-510.
6. Lavery KP, McHale KJ, Rossy WH, Theodore G. Ankle impingement. J Orthop Surg Res. 2016;11:97.
7. El-Zawawi MS, Ebied OM, Sileema ERA. Role of magnetic resonance imaging in the diagnosis of ankle impingement. Menoufia Med J. 2017;30:99.
8. Dunfee WR, Dalinka MK, Kneeland JB. Imaging of athletic injuries to the ankle and foot. Radiol Clin North Am. 2002;40:289-312.
9. Brockett CL, Chapman GJ. Biomechanics of the ankle. J Orthop Trauma. 2016;30:232-8.
10. Warner SJ, Garner MR, Fabricant PD, Schottel PC, Loftus ML, Hentel KD, et al. The Diagnostic Accuracy of Radiographs and Magnetic Resonance Imaging in Predicting Deltoid Ligament Ruptures in Ankle Fractures. HSS J. 2019;15:115-21.
11. Zeitoun R, Lamiaa IA, Metwally MD, M E-A. The Role of Ultrasound Imaging in Ankle Impingement. Med J Cairo Univ. 2019;87:3283-8.
12. Berman Z, Tafur M, Ahmed SS, Huang BK, Chang EY. Ankle impingement syndromes: an imaging review. Br J Radiol. 2017;90:20-35.
13. Donovan A, Rosenberg ZS. MRI of ankle and lateral hindfoot impingement syndromes. AJR Am J Roentgenol. 2010;195:595-604.
14. Sofka CM. Posterior ankle impingement: clarification and confirmation of the pathoanatomy. HSS J. 2010;6:99-101.
15. Al-Riyami AM, Tan HK, Peh WCG. Imaging of Ankle Impingement Syndromes. Can Assoc Radiol J. 2017;68:431-7.
16. Choo HJ, Suh J-S, Kim S-J, Huh Y-M, Kim MI, Lee J-W. Ankle MRI for anterolateral soft tissue impingement: increased accuracy with the use of contrast-enhanced fat-suppressed 3D-FSPGR MRI. KJR. 2008;9:409-15.

17. Henderson I, La Valette D. Ankle impingement: combined anterior and posterior impingement syndrome of the ankle. Foot Ankle Int. 2004;25:632-8.
18. Qin D-a, Jin Z-z, Song J-f. Combined anterior and posterior ankle impingement syndrome with nonunion of Cedell fracture in a 58-year-old female: a case report. BMC Musculoskelet Disord. 2020;21:1-6.
19. Duncan D, Mologne T, Hildebrand H, Stanley M, Schreckengaust R, Sitler D. The usefulness of magnetic resonance imaging in the diagnosis of anterolateral impingement of the ankle. J Foot Ankle Surg. 2006;45:304-7.
20. Ferkel RD, Tyorkin M, Applegate GR, Heinen GT. MRI evaluation of anterolateral soft tissue impingement of the ankle. Foot Ankle Int. 2010;31:655-61.