

Original Research Article

Evaluating the Prophylactic Anti-Inflammatory Anti-Apoptotic and Antioxidant Effects of Galantamine Hydrobromide through α -7 Nicotinic Receptor on Lithium Carbonate Induced Thyroid Dysfunction in Rats.

Abstract

Galantamine hydrobromide, an FDA-approved drug for Alzheimer's, has recently revealed anti-inflammatory, antioxidant and antiapoptotic effects that can be subjected for further indications other than neurodegenerative diseases. Despite of lithium carbonate's effectiveness in psychiatry, it has multiple organ toxic effects and thyroid dysfunction is one of the most prevalent adverse effects of lithium therapy, however, the precise etiology is still ambiguous. The aim of this experiment was to evaluate the possible prophylactic antioxidant, anti-inflammatory and antiapoptotic effects of galantamine hydrobromide, alone or in combination with vitamin E against lithium induced thyroid dysfunction in rats. This experiment was performed on 40 male Wistar albino rats divided randomly into 5 groups. Group 1 was control group. Group 2 received lithium alone. Group 3 received lithium and galantamine hydrobromide. Group 4 received lithium and vitamin E. Group 5 received lithium, galantamine hydrobromide and vitamin E. Blood was collected to evaluate thyroid function (triiodothyronine T₃, thyroxin T₄, thyroid stimulating hormones (TSH levels), and assess levels of total antioxidant capacity (TAC), Malondialdehyde (MDA), and tumor necrosis factor alpha (TNF α). Then, both lobes of thyroid glands were dissected and processed for histopathological changes

and immunohistochemical expression of (Caspase-3). The results of the study showed that combined treatment of galantamine hydrobromide and vitamin E provide marked anti-inflammatory, antioxidant and anti-apoptotic effects represented by significant changes in all parameters included in this study. However, galantamine alone was more effective than vitamin E to decrease the incidence of lithium induced thyroid toxicity.

Keywords: lithium carbonate; galantamine hydrobromide; vitamin E; thyroid dysfunction; α -7 nicotinic receptor.

1. Introduction

Galantamine hydrobromide (GB) ,a tertiary alkaloid, is a selective, reversible, competitive inhibitor of Acetyl choline esterase enzyme (AChE) that is a drug of choice in USA for treatment of Alzheimer's disease ^(1,2). Many studies have been conducted on GB showing significant anti-inflammatory, anti-apoptotic and antioxidant effects ^(2,3). The anti-inflammatory effect of GB is due to inhibition of ACh degradation and the agonist effect of cholinergic nicotinic receptor alpha7 subunit (α 7nAChRs) that has crucial anti-inflammatory pathway ⁽⁴⁾. The antiapoptotic mechanism of galantamine seems to be related as well to α 7nAChRs which in turn could activate the synthesis of anti-apoptotic proteins such as Bcl-2 and Bcl-XL⁽⁵⁾. While, GB radical scavenging effect is related to its enol group⁽⁶⁾.

Lithium (Li) is one of the most effective medication in psychiatry, as it is not only for symptomatic treatment, but also for a disease-modifying effect ^(7,8). One of the main causes of low adherence to Li therapy is its major side effect and organ toxicity since it has a low therapeutic index ⁽⁹⁾. Thyroid gland is one of the main organ that is seriously affected by Li therapy ⁽¹⁰⁾. Nearly up to 52% of patients on long-term Li treatment develop thyroid dysfunction either hypo or rarely hyperthyroidism ⁽¹¹⁾. Notably, Li-associated hypothyroidism seems

reversible in most patients once Li has been discontinued, however, some cases have reported irreversible damage⁽¹²⁾. The most important clinical rule to bear in mind is that hypothyroidism never justifies Li discontinuation⁽¹³⁾. L-thyroxine is one of the main options for hormone replacement therapy for Li-induced hypothyroidism.

The exact mechanism of Li induced thyroid dysfunction induced is still unclear, however many theories were suggested to clarify the exact etiology and they agreed that it is mainly dose dependent⁽¹⁴⁾, yet, it is still controversial if the risk of this dysfunction is time-dependent or not^(7,15). Li concentrates in thyroid against a concentration gradient,⁽¹⁶⁾ altering iodine uptake, iodine organification, thyroid hormone release and metabolism resulting in disruption of thyroid function^(17,18). Other researchers^(23,34,35) suggested that Li effect on thyroid is provoked through multiple pathological factors such as releasing of inflammatory mediators and free radicals⁽³¹⁾, increasing of lipid peroxidation, DNA damage and mutation, and inducing apoptosis⁽³⁴⁾.

Vitamin E (α -tocopherol), a fat-soluble vitamin, is advocated to be the first line of defense for cell membrane against oxidative stress⁽¹⁹⁾. Vitamin E has different potent antioxidants forms, they donate hydrogen from their phenolic group to scavenge lipid peroxy radicals⁽²⁰⁾. α -tocopherol strength point as a highly efficient antioxidant is that it executes its action extremely fast, before the peroxy radicals can do any harm or other reactions^(21,22).

In this study, we established lithium induced thyroid dysfunction rat model to investigate the protective effect of galantamine hydrobromide through its anti-inflammatory, antioxidant and anti-apoptotic effects and vitamin E as adjuvant.

2. Materials and Methods:

2.1 Ethical Considerations:

The handling of animals and all experimental procedures were adopted by the institutional “Research Ethics Committee, REC”, Faculty of Medicine, Tanta University, Egypt (Approval no. #33996/8/20).

2.2 Drugs and Chemicals:

Lithium carbonate (Prianil CR) 400 mg/tablet a product from the Nile Company for Pharmaceuticals and Chemical Industries, Cairo, Egypt. Galantamine hydrobromide (Famalzyl) 8mg/tablet a product from October Pharma Company for Pharmaceuticals and Chemical Industries, Giza, Egypt. Vitamin E 50gm water soluble powder was purchased from Nutrics[®] Superfood LTD, United Kingdom.

2.3 Experimental Design:

The experiment was performed on 40 male Wister albino rats weighing 120-200 g. in animal laboratory room rats were in wire mesh cages under restrict hygienic measures and had access to standard animal diet and water *ad libitum*. All rats were housed under SPF conditions at 24°C–26°C with 55%–75% humidity and a 12-h light/dark cycle The animals were allowed for acclimatization for 2 weeks and divided randomly into 5 equal groups:

- **Group 1 (control group n=8):** rats received distilled water daily by oral gavage for 4 weeks.
- **Group 2 (Li treated group n=8):** rats received Li in a dose of 30mg/kg/day by oral gavage for 4 weeks ⁽²³⁾.
- **Group 3 (GB treated group n=8):** rats received Li as mentioned in group 2 and received GB in a dose of 5 mg/kg/day by oral gavage two hours before lithium for 4 weeks ⁽²⁴⁾.

- **Group 4 (Vit E treated group n=8):** rats received Li as described in group 2 and received vitamin E in a dose of 100 mg/kg/day by oral gavage two hours before lithium for 4 weeks ⁽²⁵⁾.
- **Group 5 (combined treated group n=8):** rats treated by Li GB and Vit E in the same dosage regimen mentioned above by oral gavage.

2.4 Biochemical Assays:

All biochemical assays were performed in Medical Pharmacology Department Laboratory, Faculty of Medicine, Tanta University.

2.4.1 Assay of serum hormonal levels Serum:

Hormonal assay was to determine serum thyroid stimulating hormone (TSH), serum triiodothyronine (T3), and tetra-iodothyronin (T4) using rat ELISA kits provided MyBioSource, Inc San Diego, USA (Cat No. MBS261285) (Cat No. MBS261867) (Cat No. MBS701641) respectively following the manufacturer's protocol.

2.4.2 Assay of serum Tumor Necrosis Factor α (TNF α):

TNF- α was measured in serum by rat ELISA kit obtained from SunRed Biotechnology (Cat. No DZE201110765) following the manufacture's protocol.

2.4.3 Assay of oxidative stress and antioxidant defense system:

Lipid peroxidation content was assayed serum by measurement of malondialdehyde (MDA) using rat kit from Biodiagnostic Company Tahreer St., Dokki, Giza, Egypt; (Cat. No MD 2529) according to the method described by ohkawa et al ⁽²⁶⁾. While total antioxidant capacity was detected in serum using rat kit from Biodiagnostic Company; Tahreer St., Dokki, Giza, Egypt (Cat. No TA 25 13) according to the method described by koracevic et al ⁽²⁷⁾.

2.5 histopathological evaluation:

Both thyroid lobes were separated and fixed in 10% formal saline solution for 24 hours, then samples were dried and later the specimens were cleared twice in xylol for 30 minutes each time⁽²⁸⁾. The tissue was soaked for 2 hours in soft paraffin for at 60°C then fixed in hard paraffin. Finally, specimens were sectioned at 4–5 micron thickness with a microtome then stained with hematoxylin and eosin (H&E) and examined by light microscope for histopathological changes⁽²⁹⁾.

2.6 Immunohistochemical study:

Other thyroid gland sections were fixed for immunohistochemical study on positively charged slides to assess the reactivity of the thyroid tissue to the antibody of caspase-3. Caspase-3 immunoreactivity appears as brownish cytoplasmic discoloration using the avidin biotin-peroxidase complex technique described by⁽³⁰⁾ and the anti-rat caspase-3 antibody kit was purchased from MASTER DIAGNOSTICA, Granada, Spain.

2.7 Statistical analysis:

All obtained data from biochemical assays and morphometrics of this study were tabulated and statistically analyzed using Graph Pad Prism software 8.0.1 (GraphPad Software, San Diego, CA 92108). Shapiro-Wilk test for normality was performed. Data were analyzed for normality of distributions and subjected to One-Way ANOVA followed by Post-hoc Tukey" multiple comparison test. Data were represented as mean \pm standard error of mean (SEM). The significance was considered at values of $P < 0.05$.

3. Results:

3.1 Biochemical results

Galantamine hydrobromide alone and when combined with Vit E improve serum hormonal levels of lithium-treated rats:

The different effects on hormonal assay are represented in (Fig.1 a,b,c). Li treated group has demonstrated a significant decrease in serum T3 and T4 ($P < 0.05$ for each) as compared to control group. On the other hand, serum TSH exhibited a different pattern where its level was significantly increased in Li treated group as compared to control group ($P < 0.05$). While concurrent administration of GB alone and combined with Vit E along with lithium significantly ($P < 0.01$, $P < 0.001$ respectively) increased T3 and T4 levels and significant decrease in TSH serum levels as compared to Li treated group ($P < 0.01$, $P < 0.001$ respectively) which was more significant in combined treated group. While Vit E treated group has presented a non-significant change in all hormonal levels when compared to Li treated group ($P > 0.05$).

Galantamine hydrobromide reduces inflammation in lithium-administered rats

Considering the mean serum level of TNF- α , Li treated group exhibited a significant elevation when compared to those of control rats ($P < 0.05$). While there was significant decrease in TNF- α serum levels in both GB and combined treated group when compared to the Li treated group ($P < 0.05$) with no significant difference between those two groups when compared to each other. However, Vit E treated rats showed no significant difference in TNF- α level when compared to Li treated rats ($P > 0.05$) (Fig.2).

Galantamine Hydrobromide and Vit E attenuates oxidative stress in lithium treated rats

Li-treated group revealed significant increase in lipid peroxidation marker MDA as compared to control group ($P < 0.05$). While concomitant treatment of GB and Vit E each alone and in

combination exhibited significant decrease in MDA serum levels ($P < 0.01$, $P < 0.001$, $P < 0.001$ respectively) (Fig.3).

Conversely, total antioxidant capacity (TAC) serum level has shown significant decrease in Li treated group as compared to control group ($P < 0.05$). While all treated groups (3,4,5) have indicated significant increase in TAC serum level as compared to Li treated group ($P < 0.01$, $P < 0.001$, $P < 0.001$ respectively) (Fig.4).

Contemplating that Vit E treated group showed more significant decrease in MDA and increase in TAC than Galantamine treated group, while combined treated group showed more significance than each group alone.

3.2 Morphometrical results

Hematoxylin and eosin-stained thyroid sections (Fig.5)

Group 1 (control group): H&E-stained sections of the thyroid gland showed that it consisted of variable- sized follicles with simple cuboidal epithelial cells lining and central lumen, which were filled with homogeneous acidophilic colloid (Fig.5a).

Group 2 (Li treated group): H&E-stained sections revealed distortion of the normal architecture of the thyroid follicles. Most follicles were lined with follicular cells with vacuolated cytoplasm and desquamated epithelial cells in their lumen. Some follicles were empty (with no colloid), while others had partially shrunken colloid. Congested blood vessels and interstitial bleeding in between the follicles were observed (Fig.5b).

Group 3 (GB treated group): sections showed some normal follicles, but some follicles were disrupted with vacuolated colloid. Marked thinning of the follicular basement membrane of some follicles and disruption of the basement membrane of another follicle were observed (Fig.5c).

Group 4 (Vit E treated group): sections showed few apparent normal follicles. Some follicles had vacuolated cytoplasm while others had vacuolated colloid. Interstitial bleeding in between thyroid follicles was also observed (Fig.5d).

Group 5 (combined treated group): sections revealed a marked improvement in the histological structure of the thyroid gland as most of the follicles appeared normal as the control group. Few follicles were observed with irregularity in the follicular basement membrane (Fig.5e).

Immunohistochemical results of Caspase-3 protein (fig

Group 1 (Fig.6a) showed weak positive brown nuclear and cytoplasmic immunoreactivity for caspase-3 in few follicular cells (Fig.6a), while **group 2** indicated strong immunohistochemical expression in nuclei and cytoplasm of most follicular cells (Fig.6b). Interestingly, **group 3** exhibited moderate immunohistochemical expression of in nuclei and cytoplasm of few follicular cells (Fig.6c), where **group 4** showed moderate immunohistochemical expression of the caspase-3 protein in nuclei and cytoplasm of few follicular cells (Fig.6d). Finally, **group 5** revealed weak immunohistochemical expression of the caspase-3 protein in nuclei and cytoplasm of few follicular cells (Fig.6e).

4.Discussion

Lithium, a psychotropic agent widely used in treatment of bipolar disorder⁽³¹⁾, is a unique drug with an impressive psychoactive potential on one hand and a drug with multisystem toxicity effect on the other hand⁽³²⁾. Thyroid gland, one of the essential glands in human body, is highly affected by Li therapy which concentrates 3-4 times greater in thyroid than plasma against a concentration gradient⁽³³⁾⁽¹⁶⁾. The gland's main function is to synthesize and release thyroid hormones T3 and T4, which are crucial for maintaining normal development⁽³⁶⁾ and have proven their effective protective role in oxidative stress, as they regulate levels of antioxidants in the body.

In this study, Li-treated group experienced hypothyroidism which was evidenced biochemically by low hormonal levels and by histopathological examination. The Li treated group has showed a significant increase in serum TNF- α level. While for the oxidative stress profile, this group showed a significant increase in serum MDA level and a significant decrease in TAC level as compared to the control group.

These results agree with the fact that Li therapy alters thyroid status by blocking iodothyronine formation and inhibition of T3 and T4 release, with a compensatory increase of the TSH levels⁽³¹⁾. Li stimulates the inflammatory cells to release proinflammatory cytokines (TNF- α and IL-6)^(14,34).

Toplan's study on 24 male rats found that high doses of lithium result in increased lipid peroxidation and damage to the erythrocyte membrane and subsequent increase in MDA level while low Li doses had non-significant difference on MDA level⁽³¹⁾.

In 2007, another study found that therapeutic doses of lithium increased total antioxidant status in patients with BD⁽³⁷⁾, yet, Li treatment was not able to prevent an oxidative stress-induced damage to macromolecules⁽³⁸⁾. Since total antioxidant status level is a measure of capacity to

scavenge free radicals, the decreased TAC in plasma may lead to an increase free radical mediated cellular insult such as lipid peroxidation⁽³⁷⁾.

These results suggests that the decrease in total antioxidant capacity serum level in Li treated group is due to different causes other than lithium therapy itself. However, the oxidative stress is a sequelae of thyroid dysfunction as mentioned in Toplan's study in 2013, who stated that, thyroid hormones have role in maintaining the oxidant/antioxidant equilibrium and modulates the free radical-induced oxidative damage of lipids, and any damage of thyroid gland or disturbance of its hormonal levels may lead to oxidative stress⁽³¹⁾. This oxidative stress may backfire on thyroid gland itself.

The light microscope examination of thyroid sections of Li treated revealed various pathological alterations in the form of distorted thyroid follicles of variable sizes, congested blood vessels and interstitial bleeding in between the follicles. Congestion in the vasculature of thyroid gland might be due to increased demand for blood to nourish the follicular cells or increase in size of the thyroid gland⁽³⁹⁾. Furthermore, there was a strong immunohistochemical expression of the pro-apoptotic caspase-3 protein in nuclei and cytoplasm of most follicular cells which indicate increase incidence of cell death in Li treated group.

In 2020, Stampone suggested that Li therapy can induce DNA damage, as Li reduces cell cycle progression to allow DNA damage repair. This effect can be explained by the ability of Li to inhibit glycogen synthase kinase-3 beta (GSK3 β) and subsequently activated β -catenin, a function protein, involved in regulation gene transcription, which in turn decrease p57 which is a multifunctional protein involved in the control of growth, differentiation, gene expression, and apoptosis⁽⁴⁰⁾.

The results in the present study showed that treatment with GB provided anti-inflammatory, anti-apoptotic and antioxidant effect. Hence, they were evidenced biochemically by significant decrease in TNF alpha and MDA serum level and increase in TAC serum level while microscopically there was moderate immunohistochemical expression of the proapoptotic protein caspase-3 in nuclei and cytoplasm of few follicular cells. Interestingly, sections of the thyroid gland of the GB treated group showed some normal follicles. These effects were reflected on thyroid profile as they were interestingly significant regarding T3, T4 and TSH levels. Thus, these findings highly support a potential protective effect of GB against lithium thyrotoxicity

The anti-inflammatory effect of GB is due to subsequent accumulation of Ach in the synapses and the agonist effect of $\alpha 7$ nAChRs⁽⁴⁾, that serves as a natural anti-inflammatory defense system to counteract the excessive cytokines release in infective diseases , or autoimmune diseases such as rheumatoid arthritis⁽⁴¹⁾.

GB is interestingly able to upregulate the expression of $\alpha 7$ nAChRs⁽⁴²⁾. Therefore, the antiapoptotic mechanism of GB seems to be related to $\alpha 7$ nAChRs and the PI3K/Akt pathway which in turn could activate the synthesis of anti-apoptotic proteins including Bcl-2 and Bcl-XL, a mechanism already described for nicotine 's neuroprotective effect against β -amyloid-induced toxicity⁽⁵⁾. Additionally, the enol group of GB molecule provides the drug with antioxidant capability as it is a scavenger of reactive oxygen radicals. In rat's brain, the drug was able to decrease lipid peroxidation products significantly⁽⁶⁾.

Vit E, is the first line of defense for cell membrane against oxidative stress⁽¹⁹⁾. That effect strongly suggested vitamin E trial in our present study for protection against Li-induced thyroid dysfunction. In this study, Vit E treated group has revealed a significant decrease in MDA serum

level, while TAC level had a significant increase when compared to the diseased group. These results agree with the previously studied antioxidant effect of vitamin E which protects biological cells from oxidative free radical stress via producing antioxidant enzymes, and consequently increasing the TAC activity, and reducing oxidative free radical stress parameters such as MDA⁽⁴³⁾.

The results of anti-inflammatory and antiapoptotic effects of vitamin E were not promising which, in turn, explains its failure in prophylaxis against the Li induced thyroid dysfunction. These results disagree with the finding of vitamin E decreasing effect on TNF α in type 2 diabetes in Jamalan study in 2015⁽⁴⁴⁾. This can be clarified as the anti-inflammatory effect of vitamin E is more potent for the subtypes γ T and δ T tocotrienols⁽⁴⁵⁾, while the form used in this study is α -tocopherol.

This explains that vitamin E, in this experiment, did not provide a significant prophylactic effect on thyroid gland as reflected on hormonal level. To conclude, vitamin E alone may not provide preventive measures against lithium thyrotoxicity, however, it can help stopping further damage of the gland resulted from the oxidative stress induced by hormonal disturbance.

In the present study, the combined treated group showed a significant anti-inflammatory, antioxidant and anti-apoptotic effects represented biochemically and microscopically, and significant improvement of thyroid hormone profile close to the control group hormone levels.

When the combined treated group is compared to GB treated group it showed superiority as regard antioxidant effect and in thyroid hormone levels. While when compared to Vit E treated group showed superiority as regard all parameters analyzed in this experiment.

5. Conclusion

Finally, there might be a possibility of an additional effect between galantamine hydrobromide and vitamin E that lead to a promising protective outcome against lithium induced thyroid dysfunction, however, the main role of protection here is apparently due to galantamine hydrobromide, and vit E can be an add on therapy. It is highly recommended to evaluate galantamine effect against other lithium side effects in other different clinical studies.

8. References

1. Villarroya M, García AG, Marco-Contelles J, López MG. An update on the pharmacology of galantamine. *Expert Opin Investig Drugs*. 2007;16(12):1987–98.
2. Halpin CM, Reilly C, Walsh JJ. Nature's anti-alzheimer's drug: Isolation and structure elucidation of galantamine from *Leucojum aestivum*. *J Chem Educ*. 2010;87(11):1242–3.
3. Inden M, Takata K, Yanagisawa D, Ashihara E, Tooyama I, Shimohama S, et al. $\alpha 4$ nicotinic acetylcholine receptor modulated by galantamine on nigrostriatal terminals regulates dopamine receptor-mediated rotational behavior. *Neurochem Int*. 2016;94:74–81.
4. Gowayed MA, Rothe K, Rossol M, Attia AS, Wagner U, Baerwald C, et al. The role of $\alpha 7$ nAChR in controlling the anti-inflammatory/anti-arthritic action of galantamine. *Biochem Pharmacol* [Internet]. 2019;170(August):113665.
5. Villarroya M, García AG, Marco-Contelles J, López MG. An update on the pharmacology of galantamine. *Expert Opin Investig Drugs*. 2007;16(12):1987–98.
6. Traykova M, Traykov T, Hadjimitova V, Bojadgieva N. Antioxidant properties of galantamine hydrobromide. *Zeitschrift für Naturforsch C*. 2003;58(5–6):361–5.

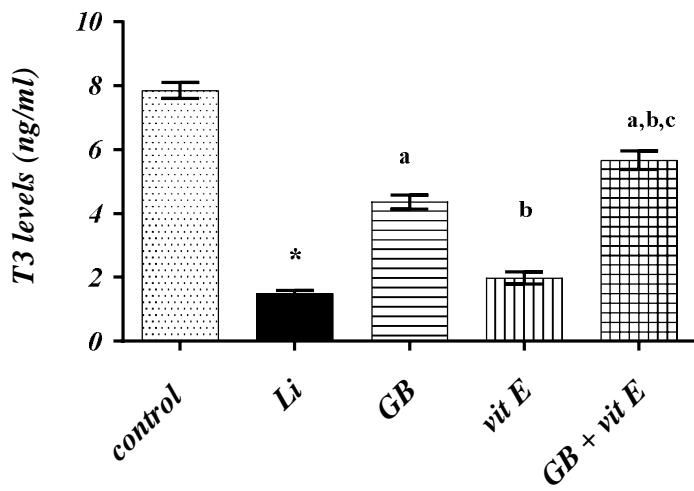
7. Transbøl I, Christiansen C, Baastrup PC. Endocrine effects of lithium. *Eur J Endocrinol.* 1978;87(4):759–67.
8. Barroilhet SA, Ghaemi SN. When and how to use lithium. *Acta Psychiatr Scand.* 2020;142(3):161–72.
9. Gitlin M. Lithium side effects and toxicity: prevalence and management strategies. *Int J Bipolar Disord.* 2016;4(1).
10. Mondal S, Raja K, Schweizer U, Muges G. Chemistry and Biology in the Biosynthesis and Action of Thyroid Hormones. *Angew Chemie - Int Ed.* 2016;55(27):7606–30.
11. Mir SA, Wani AI, Masoodi SR, Bashir MI, Ahmad N. Lithium toxicity and myxedema crisis in an elderly patient. *Indian J Endocrinol Metab.* 2013;17(Suppl 3):S654.
12. Lieber I, Ott M, Öhlund L, Lundqvist R, Eliasson M, Sandlund M, et al. Lithium-associated hypothyroidism and potential for reversibility after lithium discontinuation: Findings from the LiSIE retrospective cohort study. *J Psychopharmacol.* 2020;34(3):293–303.
13. Lazarus JH, Kirov G, Harris BB. Effect of lithium on the thyroid and endocrine glands. In: *Lithium in Neuropsychiatry.* CRC Press; 2013. p. 279–90.
14. Shah N, Bhat G, Shadad S, Itoo M, Shah B, Khan J. Effects of lithium carbonate on the microanatomy of thyroid gland of albino rats. *Int J Res Med Sci.* 2014;2(1):279.
15. Henry C. Lithium side-effects and predictors of hypothyroidism in patients with bipolar disorder: sex differences. *J Psychiatry Neurosci.* 2002;27(2):104.
16. Czarnywojtek A, Zgorzalewicz-Stachowiak M, Czarnocka B, Sawicka-Gutaj N, Gut P,

- Krela-Kazmierczak I, et al. Effect of lithium carbonate on the function of the thyroid gland: Mechanism of action and clinical implications. *J Physiol Pharmacol*. 2020;71(2):1–9.
17. Pathak R, Pathak A. Effectiveness of Zinc Supplementation on Lithium-Induced Alterations in Thyroid Functions. *Biol Trace Elem Res*. 2021;199(6):2266–71.
 18. Lazarus JH. Lithium and thyroid. *Best Pract Res Clin Endocrinol Metab* [Internet]. 2009;23(6):723–33.
 19. Niki E. Evidence for beneficial effects of vitamin E. *Korean J Intern Med*. 2015;30(5):571–9.
 20. Wong RS, Radhakrishnan AK. Tocotrienol research: past into present. *Nutr Rev* [Internet]. 2012 Sep 1;70(9):483–90.
 21. Schneider C. Chemistry and biology of vitamin E. *Mol Nutr Food Res*. 2005;49(1):7–30.
 22. Wijtmans M, Pratt DA, Valgimigli L, DiLabio GA, Pedulli GF, Porter NA. 6-Amino-3-Pyridinols: Towards Diffusion-Controlled Chain-Breaking Antioxidants. *Angew Chemie Int Ed*. 2003;42(36):4370–3.
 23. El-Mahalaway AM, El-Azab NEE. Impacts of resveratrol versus platelet-rich plasma for treatment of experimentally lithium-induced thyroid follicular cell toxicity in rats. A histological and immunohistochemical study. *Ultrastruct Pathol* [Internet]. 2019;43(1):80–93.
 24. Gowayed MA, Refaat R, Ahmed WM, El-Abhar HS. Effect of galantamine on adjuvant-induced arthritis in rats. *Eur J Pharmacol*. 2015;764:547–53.

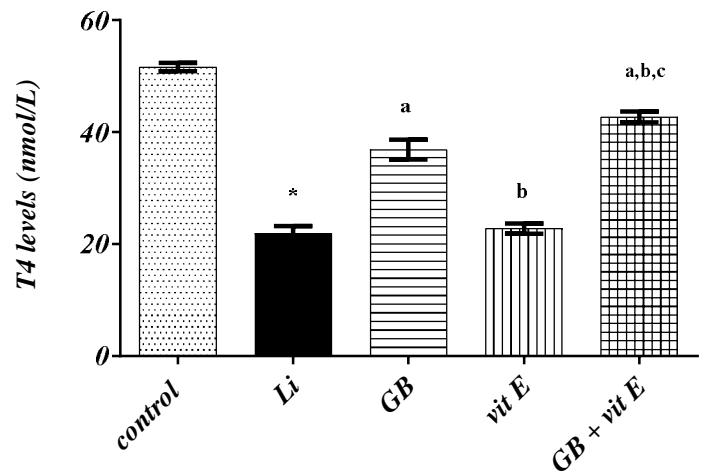
25. Rasheed R, Arsanyos S. Vitamin E Ameliorates the Toxic Effect of Amiodarone on Thyroid Gland in Rats: a Histological and Ultrastructural Study. *J Med Histol.* 2018;2(1):57–68.
26. Ohkawa H, Ohishi N, Yagi K. Assay for lipid peroxides in animal tissues by thiobarbituric acid reaction. *Anal Biochem.* 1979;95(2):351–8.
27. Koracevic D, Koracevic G, Djordjevic V, Andrejevic S, Cosic V. Method for the measurement of antioxidant activity in human fluids. *J Clin Pathol.* 2001;54(5):356–61.
28. Chandler DE, Roberson RW. Bioimaging : current concepts in light and electron microscopy. 2009;440.
29. Layton C, Bancroft JD, Suvana SK, Wolfe D. Fixation of tissues. *Bancroft's Theory Pract Histol Tech (Eighth Ed Content Repos Only.* 2019;40–63.
30. Buchwalow IB, Böcker W. Immunohistochemistry. Basics and Methods. 2010;1:1–149.
31. Toplan S, Dariyerli N, Ozdemir S, Ozcelik D, Zengin EU, Akyolcu MC. Lithium-induced hypothyroidism: Oxidative stress and osmotic fragility status in rats. *Biol Trace Elem Res.* 2013;152(3):373–8.
32. Kumarguru BN, Natarajan M, Nagarajappa AH. The pathology of lithium induced nephropathy: A case report and review, with emphasis on the demonstration of mast cells. *J Clin Diagnostic Res.* 2013;7(2):374–7.
33. Koibuchi N. [Molecular mechanisms of thyroid hormone synthesis and secretion]. *Nihon Rinsho.* 2012;70(11):1844–8.
34. Abd El-Twab SM, Abdul-Hamid M. Curcumin mitigates lithium-induced thyroid

- dysfunction by modulating antioxidant status, apoptosis and inflammatory cytokines. *J Basic Appl Zool* [Internet]. 2016;76:7–19.
35. Shah N, Bhat G, Shadad S, Itoo M, Shah B, Khan J. Lithium carbonate induced histopathological changes in the heart of albino rats. *World J Pharm Pharm Sci* [Internet]. 2015;4(8):1684–92.
 36. Shin NR, Bose S, Wang JH, Nam Y Do, Song EJ, Lim DW, et al. Chemically or surgically induced thyroid dysfunction altered gut microbiota in rat models. *FASEB J*. 2020;34(6):8686–701.
 37. Aliyazicioglu R, Kural B, Çolak M, Karahan SC, Ayvaz S, Deger O. Treatment with lithium, alone or in combination with olanzapine, relieves oxidative stress but increases atherogenic lipids in bipolar disorder. *Tohoku J Exp Med*. 2007;213(1):79–87.
 38. de Vasconcellos APS, Nieto FB, Crema LM, Diehl LA, de Almeida LM, Prediger ME, et al. Chronic Lithium Treatment has Antioxidant Properties but does not Prevent Oxidative Damage Induced by Chronic Variate Stress. *Neurochem Res* [Internet]. 2006;31(9):1141–51.
 39. Mohamed DA, Elnegriss HM. Histological study of thyroid gland after experimental exposure to low frequency electromagnetic fields in adult male Albino rat and possible protective role of Vitamin E. *J Cytol Histol*. 2015;6(6):1.
 40. Stampone E, Bencivenga D, Barone C, Aulitto A, Verace F, Della Ragione F, et al. High dosage lithium treatment induces DNA damage and p57Kip2 decrease. *Int J Mol Sci*. 2020;21(3):1169.

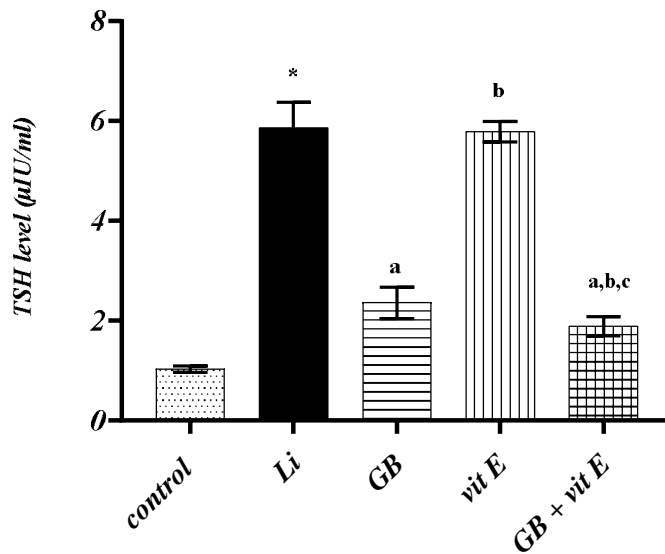
41. Li G, Zhou CL, Zhou QS, Zou HD. Galantamine protects against lipopolysaccharide-induced acute lung injury in rats. *Brazilian J Med Biol Res.* 2015;49.
42. Arias E, Alés E, Gabilan NH, Cano-Abad MF, Villarroya M, García AG, et al. Galantamine prevents apoptosis induced by β -amyloid and thapsigargin: involvement of nicotinic acetylcholine receptors. *Neuropharmacology.* 2004;46(1):103–14.
43. Alghadir AH, Gabr SA, Iqbal ZA, Al-Eisa E. Association of physical activity, vitamin E levels, and total antioxidant capacity with academic performance and executive functions of adolescents. *BMC Pediatr.* 2019;19(1):1–8.
44. Jamalan M, Rezazadeh M, Zeinali M, Ghaffari MA. Effect of ascorbic acid and alpha-tocopherol supplementations on serum leptin, tumor necrosis factor alpha, and serum amyloid A levels in individuals with type 2 diabetes mellitus. *Avicenna J phytomedicine [Internet].* 2015;5(6):531–9.
45. Jiang Q. Natural forms of vitamin E: Metabolism, antioxidant, and anti-inflammatory activities and their role in disease prevention and therapy. *Free Radic Biol Med [Internet].* 2014;72:76–90.



a



b



c

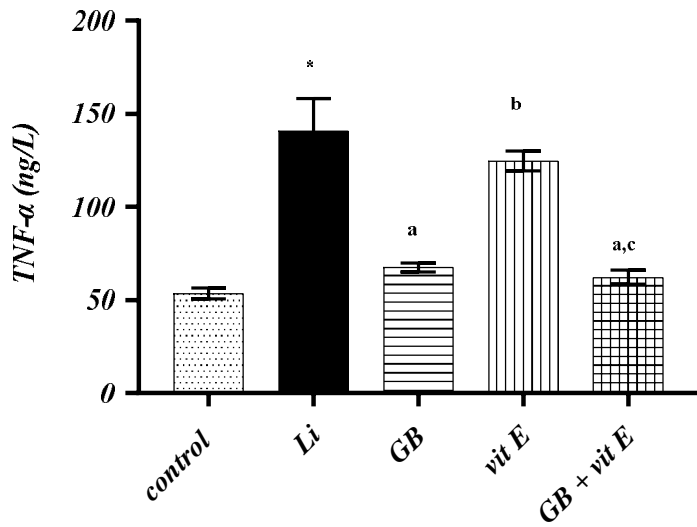
Fig (1.a): T3 serum levels (ng/ml). **Fig (1.b):** T4 serum levels (nmol/L). **Fig (1.c):** TSH serum levels (µIU/ml).

*: Significant difference from group 1 (Normal control) at p value <0.05.

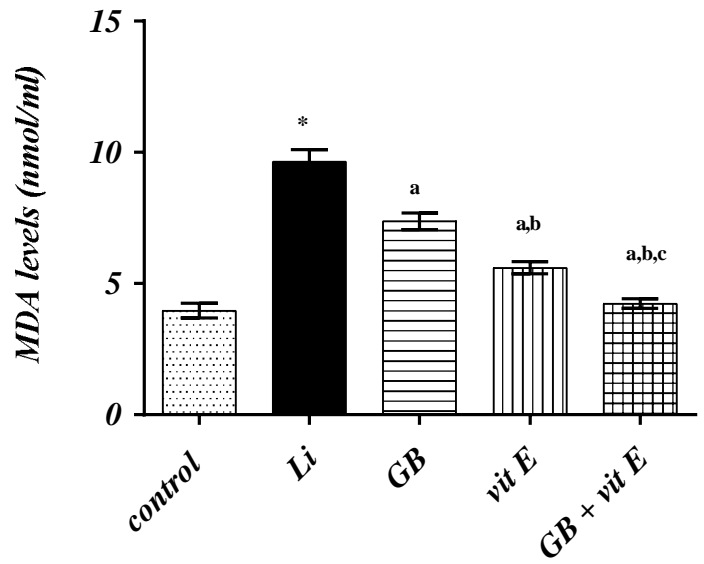
a: Significant difference from group 2 (Li) at p value <0.05.

b: Significant difference from Group 3 (GB) at p value <0.05.

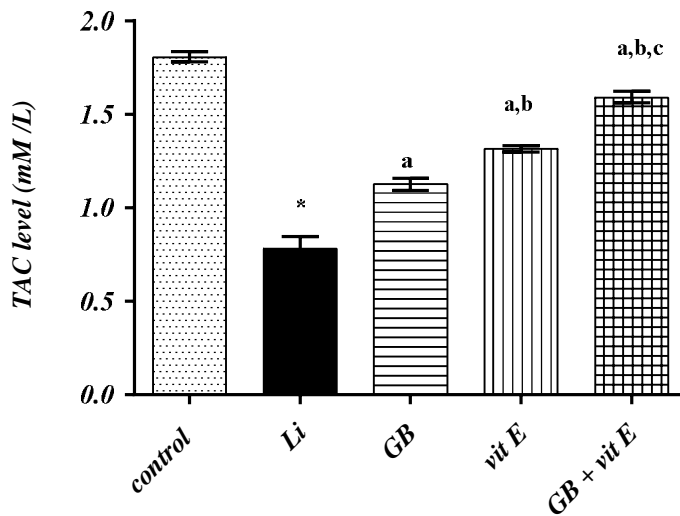
c: Significant difference from group 4 (Vit E) at p value <0.05.



2



3



4

(Fig 2): TNF α serum levels (ng/L). (Fig 3): MDA serum levels (nmol/ml). (Fig 4): TAC serum levels (mM/L).

*: Significant difference from group 1 (Normal control) at p value <0.05.

a: Significant difference from group 2 (Li) at p value <0.05.

b: Significant difference from Group 3 (GB) at p value <0.05.

c: Significant difference from group 4 (Vit E) at p value <0.05.

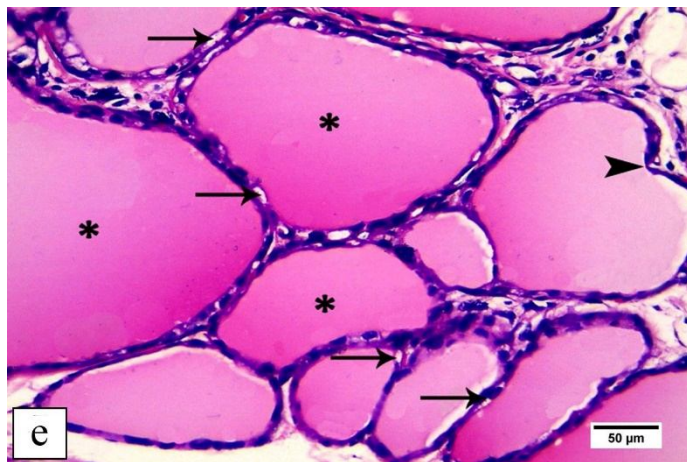
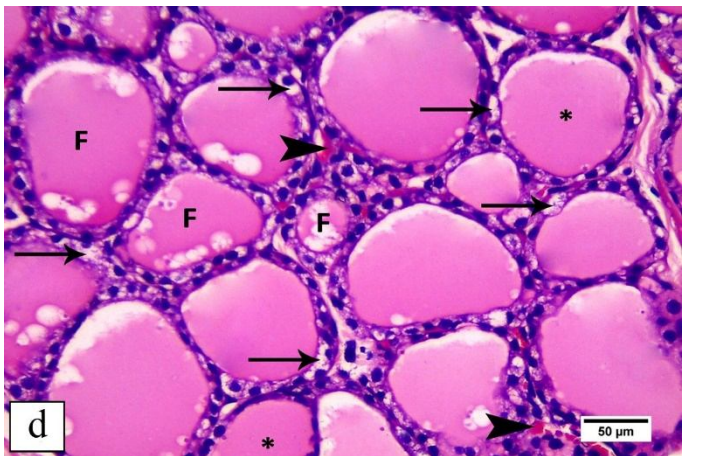
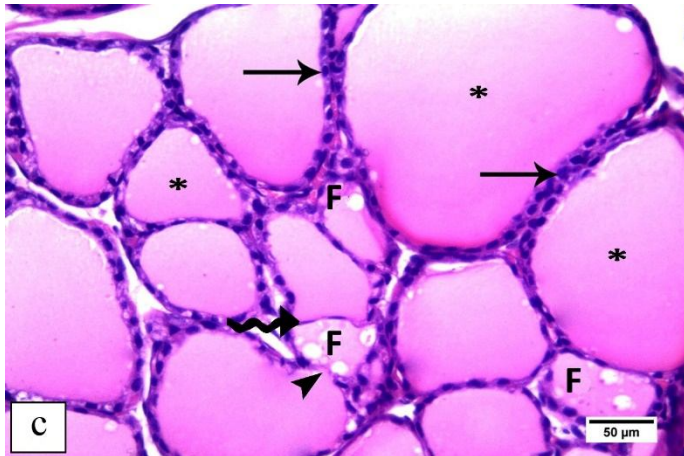
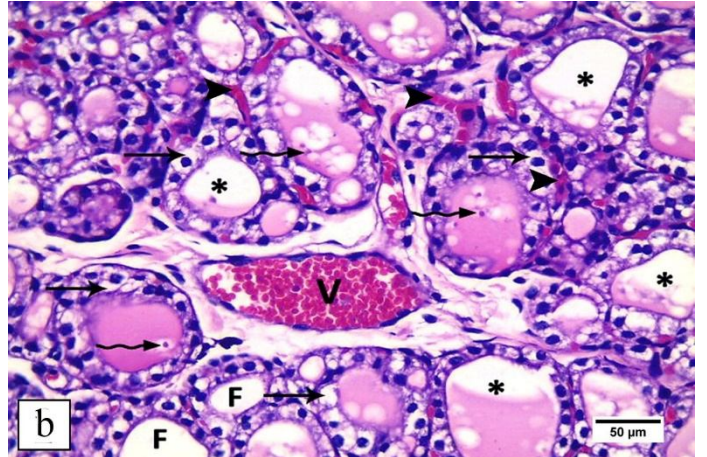
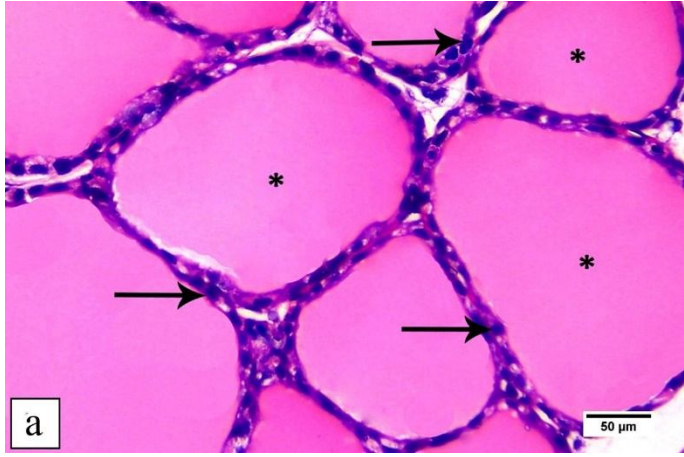
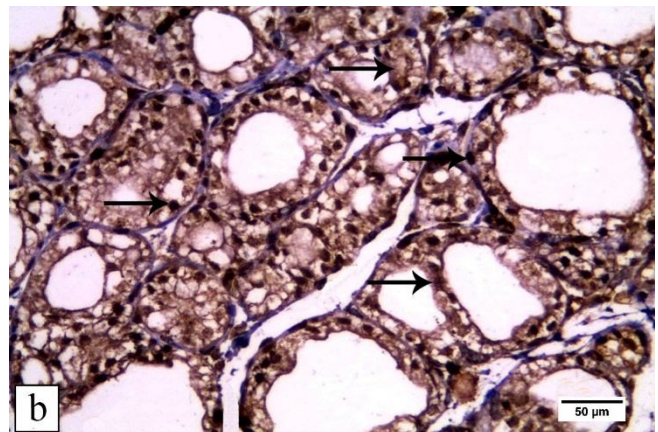
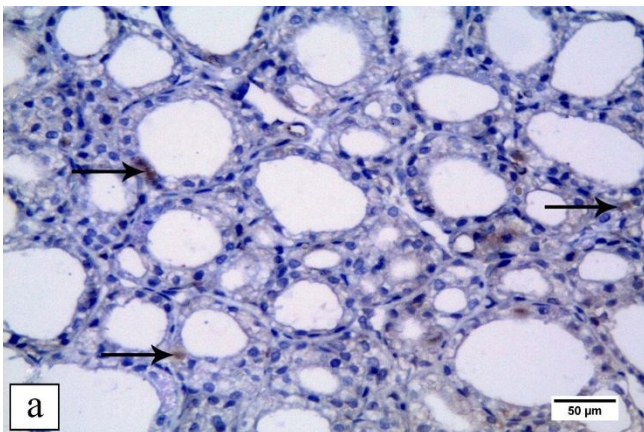


Fig (5.a): Thyroid gland section of the control group showing normal thyroid follicles lined with follicular cuboidal epithelial cells with rounded nuclei (**arrows**) and filled with homogenous acidophilic colloid (**asterisks**). **Fig (5.b):** thyroid gland section of the Li treated group showing disorganized thyroid follicles. Most follicles are lined with follicular cells with vacuolated cytoplasm (**thin arrows**) and desquamated epithelial cells (**wavy arrows**) in their lumen. Some follicles are empty (**F**), while others have partially shrunken colloid (**asterisks**). Congested blood vessels (**V**) and interstitial bleeding (**arrowheads**) in between the follicles are also seen. **Fig (5.c):** thyroid gland section of GB treated group showing some apparent normal follicles that are lined with follicular cuboidal epithelial cells with rounded nuclei (**arrows**) and filled with homogenous acidophilic colloid (**asterisks**). Some follicles are disrupted with vacuolated colloid (**F**). Notice marked thinning of the follicular basement membrane of a single follicle (**wavy arrow**) and disruption of the basement membrane of another one is seen (**arrowheads**). **Fig (5.d):** section of the thyroid gland of Vit E treated group showing few apparent normal follicles with homogenous acidophilic colloid (**asterisks**). Some follicles have vacuolated cytoplasm (**arrows**) while others have vacuolated colloid (**F**). Notice, interstitial bleeding in between thyroid follicles (**arrowheads**) is also seen. **Fig (5.e):** thyroid gland section from the combined treatment group showing most of the follicles are normal with follicular cuboidal epithelial cells (**arrows**) and filled with homogenous acidophilic colloid (**asterisks**). Notice, irregularity in follicular basement membrane is seen in a single follicle (**arrowhead**) (H&E. X400; Scale bar = 50µm).



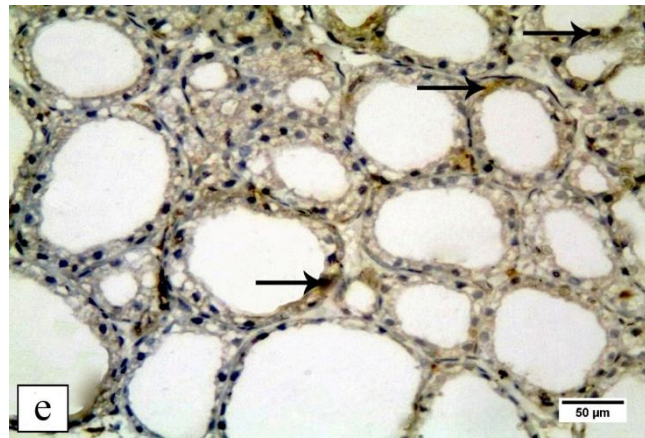
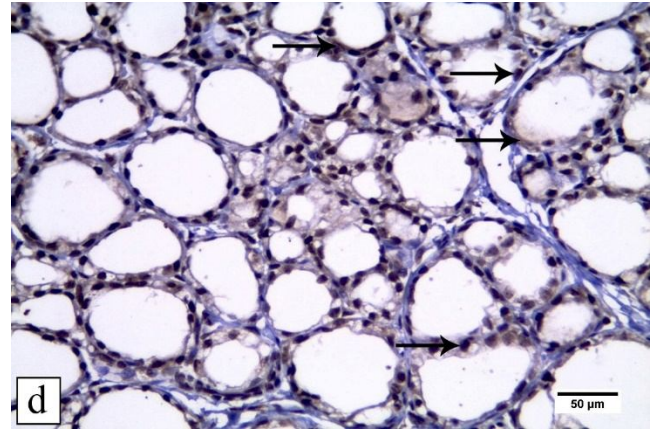
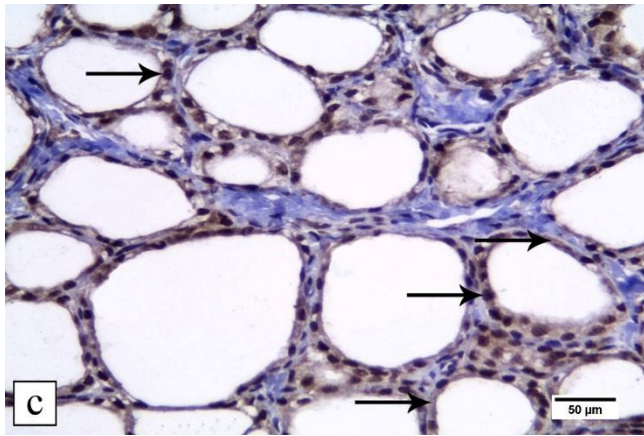


Fig (6.a): thyroid gland section of the control group showing weak positive nuclear and/or cytoplasmic immunoreactivity (**arrows**) for caspase-3 in few follicular cells. **Fig (6.b):** thyroid gland section from the lithium group showing strong immunohistochemical expression of the caspase-3 protein in nuclei and cytoplasm of most follicular cells (**arrows**). **Fig (6.c):** thyroid gland section of the galantamine hydrobromide treated group showing moderate immunohistochemical expression of the caspase-3 protein in nuclei and cytoplasm of few follicular cells (**arrows**). **Fig (6.d):** thyroid gland section of the vitamin E treated group showing moderate immunohistochemical expression of the caspase-3 protein in nuclei and cytoplasm of few follicular cells (**arrows**). **Fig (6.e):** thyroid gland section of the combined treatment treated group showing weak immunohistochemical expression of the caspase-3 protein in nuclei and cytoplasm of few follicular cells (**arrows**). (Caspase-3 immunostaining, X400; Scale bar = 50μm).

