

Original Research Article

Sodium Butyrate as Adjuvant Therapy with Mycophenolate Mofetil for Amelioration of Skin fibrosis in Bleomycin-induced Scleroderma in Mice via Immunomodulatory, Antioxidant, Antiapoptotic and Antifibrotic Mechanisms

Abstract

Background: Scleroderma is an autoimmune, multi-organ ~~disease,disease~~; its clinical hallmark is cutaneous and systemic fibrosis. Up to date, there is no definite cure.

The aim of this study was to investigate the potential effects of sodium butyrate (NaB), and mycophenolate mofetil (MMF) each alone or both in a mice model of scleroderma induced by bleomycin (BLM), and to clarify some of their possible mechanisms on oxidative stress, immunological pattern, apoptosis, inflammation and fibrosis.

Methods: This study was carried out on 50 Balb/C mice, divided into 5 equal groups. Serum levels of anticentromere antibody (ACA), and skin tissue levels of the following parameters were assayed: transforming growth factor- β 1 (TGF- β 1), interleukin-4 (IL-4), malondialdehyde (MDA), and superoxide dismutase (SOD). Tissue sections were examined for histopathological changes, dermal thickness, and immunohistochemical expression of caspase- 3, and α -smooth muscle actin (α -SMA).

Results &Conclusion: The combined group showed a significant decline in TGF- β 1, IL-4, MDA levels, caspase-3, and α -SMA, as well as a significant increase in SOD. Moreover, marked reduction in dermal fibrosis and dermal thickness compared to monotherapy by either NaB or MMF. The combination of NaB and MMF is a promising candidate for the treatment of scleroderma.

Keywords: scleroderma, Bleomycin, Sodium butyrate, Mycophenolate mofetil, oxidative stress, immunological pattern, apoptosis, fibrosis.

1.Introduction

Scleroderma is an autoimmune, heterogeneous, multi-organ disease, its clinical hallmark is cutaneous and systemic fibrosis (1). It is classified into two major separate but related entities types: localized scleroderma (LSc), and systemic sclerosis (SSc), where both types have further subtypes (2). The limited cutaneous (LcSSc) and diffuse cutaneous (DcSSc) represent the two main subtypes of SSc (3). The pathogenesis is still mysterious. Immunological imbalance, genetic, environmental factors play a major role in the pathogenesis. All those initiate collagen synthesis, fibrosis, and progression of scleroderma (4).

Whatever the type of scleroderma, skin involvement with dermal fibrosis is a hallmark of systemic sclerosis (SSc) and the main target by different pathogenic pathways. This could be explained by presence of keratinocytes which may be critical regulators of fibroblast function through secretion of chemo-attracting agents, as well as growth factors and cytokines influencing the phenotype and proliferation rate of fibroblasts (5).

In some animal models, BLM is administrated to induce cutaneous fibrosis (6). BLM-induced model of limited cutaneous scleroderma was developed in mice to reproduce dermal fibrosis with pro-fibrotic inflammation, vascular wall thickness, and production of autoantibodies that mimics its characteristics in human (7,8). BLM is a glycopeptide antibiotic that is widely used as an antitumor for various kinds of cancers (9), but unfortunately, it causes various cutaneous adverse effects including scleroderma in addition to its major dose-limiting toxicity of pulmonary fibrosis (10).

Up to date, there is no definite cure for scleroderma. Treatment is adapted for each patient, targeting the symptoms or the involved organ with a range of drugs including immunomodulatory drugs (11), so many researches are carried out in an attempt to introduce new agents effective for scleroderma. NaB is one of the histone deacetylase inhibitors (HDAC) having potent antioxidant, immunomodulatory and anti-inflammatory properties

through inhibition of the production of pro-inflammatory enzymes and cytokines (12). Butyrate can influence the immune response by affecting immune cell migration, adhesion, and cellular functions such as proliferation and apoptosis (13). So, there is a growing interest in butyrate because of its effect on the epigenetic mechanisms will lead to more specific therapeutic strategies for the prevention and treatment of different diseases (14).

Among the current immunomodulatory drugs is Mycophenolate mofetil (MMF), a prodrug of mycophenolic acid, that suppresses the proliferation of both B and T lymphocytes as well as inhibition of their recruitment and monocytes to inflammation sites. It also inhibits the glycosylation and expression of adhesion molecules. Although it is approved clinically for the treatment of chronic inflammatory and autoimmune diseases (15).

2. Material and Methods:

2.1 Ethical Considerations:

The handling of animals and all experimental procedures were approved by the institutional "Research Ethics Committee, REC", Faculty of Medicine, Tanta University, Egypt (Approval no. #34007/08/20).

2.2. Drugs:

BLM Lyophilized powder (15 U/vial), a product of CELON LABS, Egypt; was dissolved in phosphate buffer saline (PBS) to a final concentration of 0.5 mg/ml. NaB and MMF were purchased from Acros Organics Company. NaB was dissolved in PBS to a final concentration of 20 mg/ml. MMF was dissolved in Dimethyl sulfoxide/phosphate buffer saline mixture (DMSO/PBS 1/10) to a final concentration of 4 mg/ml.

2.3. Animals and groups:

This study was conducted on 50 adult male Balb/c ~~mice~~mice; aging about 6 weeks and weighing 20-25 g. Mice were housed under constrict hygienic measures and had access to a standard animal diet and water *ad libitum*. They were allowed for acclimatization for 2

weeks and divided randomly into 5 equal groups (10 mice for each) as follows:

- **Group 1 (control group):** mice have received vehicles PBS (100µl) by subcutaneous injection (s.c.) every other day and 0.5 ml DMSO/PBS (1/10) by intraperitoneal (i.p.) injection once daily for 21 days.
- **Group 2 (BLM-untreated scleroderma):** mice have received BLM to induce scleroderma in a dose of 100 µl /mouse by s.c. injection every other day for 21 days (16) and received a vehicle 0.5 ml DMSO/PBS (1/10) by i.p injection once daily for 21 days.
- **Group 3 (NaB-treated scleroderma):** mice with induced-scleroderma were treated concomitantly with Na butyrate at a dose of 500 mg/kg by i.p. injection once daily for 21 days (17), and have received a vehicle 0.5 ml DMSO/PBS (1/10) by i.p. injection once daily for 21 days.
- **Group 4 (MMF-treated scleroderma):** mice with induced-scleroderma were treated concomitantly with MMF at a dose of 100 mg/kg by i.p. injection once daily for 21 days (18).
- **Group 5 (NaB+MMF treated scleroderma):** mice with induced-scleroderma were treated concomitantly with both Na butyrate in a dose of 500 mg/kg and MMF in a dose of 100 mg/kg by i.p. injection once daily for 21 days.

2.4 . Induction of scleroderma:

The skin on the dorsum of the back was shaved using shaving cream, and using a marker we draw one square measuring 1 cm² and the injection sites were rotated, starting with the four different corners of the square in an anticlockwise direction followed by the center of the square in a consecutive manner (16).

2.5. Blood and tissue sampling and processing:

Blood was collected from each animal by intracardiac puncture using a vacuum tube to obtain serum for detecting anti-centromere antibody (ACA). The 1 cm² skin area previously injected was shaved using shaving cream and excised from subcutaneous fat. The skin was rinsed 3 times with PBS solution (pH 7.4) to remove any red blood cells and clots, then divided into 4 parts, one part was fixed in formalin 10% to be processed for examination of histopathological changes by light microscope and immunohistochemical expression of caspase-3 and alpha-smooth muscle actin (α -SMA). The other 3 parts of the skin were stored at -80°C for assay of the skin tissue levels of TGF- β ₁, IL-4, MDA, as well as SOD activity.

2.6. Detection of serum Anti-Centromere Antibody:

Serum Anti-Centromere Antibody (ACA/CENP) was detected by ELISA kits of Sun Red Biotechnology Company, Shanghai, (Catalogue No. 201-02-2095), following the manufacturer`s protocol.

2.7. Determination of skin tissue levels of TGF- β ₁, IL-4:

TGF- β ₁ and IL-4 were measured using ELISA kits for mice of Sun Red Biotechnology Company, Shanghai, (Catalogue No. 201-11-0779 and Catalogue No.201-02-0052; respectively) according to the instructions of the manufacturer and expressed as pg/ml tissue supernatant.

2.8. Biochemical assay for oxidative stress parameters in skin tissue:

MDA levels and SOD activity were measured spectrophotometrically by kits of Bio diagnostic Company, Egypt according to the methods described by Ohkawa et al. (19) and Masayasu et al. (20); respectively.

2.9. Histopathological examination:

Part of the skin was immediately fixed in 10% formaldehyde. Paraffin sections (5 μ m) were stained with hematoxylin and eosin (H&E) and Masson Trichrome for detection of

collagen fibers, which were examined under the light microscope for histopathological changes. The dermal thickness (μm) was measured using Image J software (1.49v), national institute of health, Bethesda, Maryland, USA using the set scale method.

2.9. Immunohistochemistry (IHC) detection of caspase-3:

Immunohistochemical expression of caspase-3 in the skin tissue was done using Recombinant Anti-caspase-3 antibody for mouse purchased from Abcam Company, United Kingdom. According to the percentage of caspase-positive cells, immunostaining results were semi-quantitatively scored as follows: 0, when absent; mild, 1+, when <10% of cells in the field were positive; moderate, 2+, when 10% to 50% of cells in the field were positive; strong, 3+, when >50% of cells in the field were stained (21).

2.10. Immunohistochemistry (IHC) detection of α -SMA:

Immunohistochemical expression of α -SMA in the skin tissue was done using Mouse Anti Human α -SMA monoclonal Antibody purchased from CELL SIGNALING TECHNOLOGY, Beverly, Massachusetts. Immunohistochemical staining for all α -SMA was scored by semiquantitative assessment of ten $\times 40$ fields as follows: mild (+) 0–30% of myofibroblasts immunopositive, moderate (++) 31–70% of myofibroblasts immunopositive and strong (+++) >71% of myofibroblasts immunopositive (22).

2.11. Statistical Analysis:

The statistical analysis of the results was performed using Graph Pad Prism version 5 for windows, 2007; Graph Pad Software, Inc. Shapiro-Wilk test for normality was performed. The parametric values were expressed as mean \pm SEM (standard error of the mean), while the non-parametric values were expressed as median (minimum-maximum). Multiple comparisons for parametric values were performed using one-way ANOVA followed by Tukey's as a post hoc test. A non-parametric test for statistical analysis of the

score followed by Mann-Whitney U test. Chi-square test for the nominal results of ACA. The significance was considered at values of $P < 0.05$.

3. Results & Discussion:

3.1. Effect of different treatments on detection of serum ACA:

Group 2 of BLM-untreated scleroderma exhibited a significant increase in ACA detection compared to the normal control group. MMF treatment resulted in a significant decrease in ACA detection compared to the BLM-untreated scleroderma group. NaB/MMF combination treatment provides a significant decrease in ACA detection compared to treatment by each of these drugs alone.

Formatted: Indent: First line: 0.5"

3.2. Effect of different treatments on skin tissue levels of TGF- β 1 and IL-4:

There was a significant increase in TGF- β 1 and IL-4 levels in the BLM-untreated scleroderma group compared to the normal control group. This increase was significantly ameliorated by treatment with NaB and/or MMF. The reduction in TGF- β 1 and IL-4 levels were significant in NaB/MMF combination treatment compared to treatment by each of these drugs alone.

3.3. Effect of different treatments on skin tissue levels of MDA and SOD:

Group 2 of BLM-untreated scleroderma exhibited a significant increase in MDA and a significant reduction in SOD compared to the normal control group. This result was significantly ameliorated by treatment with NaB and/or MMF. NaB/MMF combination treatment provides a significant decrease in MDA and a significant increase in SOD compared to treatment by each of these drugs alone.

Formatted: Indent: First line: 0.5"

3.4. Histopathological results of light microscopic examination of H&E and Masson trichrome of skin sections:

Group 2 of BLM-untreated scleroderma exhibited significant marked dermal fibrosis with surface ulceration and an increase in the dermal thickness. This result was ameliorated by treatment with NaB and/or MMF. NaB/MMF combination treatment provides a significant decrease in dermal fibrosis and dermal thickness compared to treatment by each of these drugs alone. (Fig.1, Fig.2).

Formatted: Indent: First line: 0.5"

3.5. Effect of different treatments on IHC expression of caspase-3:

Group 2 of BLM-untreated scleroderma resulted in a significant increase in caspase-3 immuno-histochemical expression in skin tissue sections compared to the normal control group. This increase was ameliorated by the administration of NaB and/or MMF. These

Formatted: Indent: First line: 0.5"

results were significant in NaB/MMF combination group compared to the use of each of these drugs alone. (Fig.3).

3.6. Effect of different treatments on IHC expression of α -SMA:

Group 2 of BLM-induced scleroderma showed a significant increase in α -smooth muscle actin (α -SMA), a marker of the myofibroblast in skin tissue sections. This increase was ameliorated by the administration of NaB and/or MMF. These results were significant in NaB/MMF combination group compared to the use of each of these drugs alone. (Fig.4).

Current treatment is adapted for each patient, targeting the symptoms or the involved organ with a range of drugs that provide symptomatic relief for patients (2). BLM-induced scleroderma is the most applied experimental animal model that represents the clinical and pathogenic features of LcSSc in humans: immunomodulating, oxidative stress, and vascular injury (23). Also, it has the advantage of being easily performable and applicable to different mouse strains, and evaluation of novel anti-inflammatory and anti-fibrotic therapies for scleroderma in preclinical studies (24).

In the current work, BLM caused a significant increase in the detection of ACA which is associated mostly with the limited (LcSSc) subtype that is in line with the previous study (25). ACA was assayed in this work because of its specificity to the LcSSc subtype. Patients with diffuse scleroderma (DcSSc) are more likely to have anti-topoisomerase I or anti-RNA polymerase III antibodies, whereas patients with LcSSc are more likely to have ACA (26).

Activation of the immune system is an important point in the pathogenesis of scleroderma. The CD4⁺ T lymphocytes take the upper hand in mononuclear cell skin infiltrates causing the release of interleukins (IL-13, profibrotic IL-4, and IL-6) and TGF- β 1 that initiate fibrosis and vascular injury (27). TGF- β 1 and other cytokines trigger fibroblast activation which is a key event in the pathogenesis of scleroderma in addition to differentiation of α -SMA-expressing myofibroblasts. Activated fibroblast triggers chronic extracellular matrix (ECM) secretion in a copious amount and subsequently fibrosis (28). This was demonstrated in the present study by the significant increase in TGF- β 1 and IL-4 in scleroderma induced by BLM.

BLM showed a significant increase in oxidative stress biomarkers such as MDA and a decrease in SOD. It was reported that the production of reactive oxygen species (ROS) by the skin and visceral fibroblasts as well as endothelial cells leads to stimulation of inflammatory reaction, activation of fibroblasts differentiation into myofibroblasts, stimulation of the growth of dermal and visceral fibroblasts, moreover it can induce cell apoptosis (29). This

Formatted: Indent: First line: 0.5"

situation also leads to the suppression of the expression of antioxidant enzymes such as SOD (30).

Apoptosis is a matter of conflict in scleroderma, meanwhile, endothelial cell apoptosis which results from an endothelial injury, it was reported that apoptosis of endothelial cells induces resistance of fibroblast to apoptosis (31). Caspases play an important role in apoptosis which is critical for the pathogenesis of various diseases, where caspase-3 is a key executor of apoptosis (32). BLM showed a significant increase in caspase-3 immunohistochemical expression in the skin. This could be depending on the theory that supposed apoptosis itself acts as a selection factor in scleroderma development so during the initial stages of SSc, apoptosis-susceptible subpopulations of fibroblasts are cleared and the resistant fibroblasts remain (33).

Dermal thickness increased with BLM indicating cutaneous fibrosis. This is due to severe dermal deposition of dense collagen with mononuclear cell infiltrates, resembling the cutaneous changes of human scleroderma (34). Myofibroblasts are contractile cells that are interpreted in morphogenesis, inflammation, wound healing, fibrosis, and oncogenesis in various tissues. In fibrotic disorders, the sustained presence of myofibroblasts causes excess ECM secretion, and fibrosis (35), so BLM showed a significant increase in α -SMA, a marker of the myofibroblast in skin tissue sections. This is in concordance with that described by Manetti et al.(34), who reported that BLM showed marked dermal fibrosis with surface ulceration.

The present study is the first that assessed the effect of NaB on ACA detection in BLM-induced scleroderma. However, there was a non-significant difference in ACA detection compared to the BLM group. This result could be attributed to the limitation of its incidence. ACA antibody has been detected in the serum of 46.6% of LcSSc patients, while, it is detected in 23.4% of patients with DcSSc (11).

There is a lack of reports studying the effect of NaB against dermal fibroblasts, a recent study conducted by Park et al. (36) reported that suppressed TGF- β 1 with their associated profibrotic and proinflammatory mediators against dermal fibroblasts during fibrosis and consequently can exhibit antifibrotic effects by inhibiting gene transcription involved in fibrogenesis. That effect on TGF- β 1 is reflected consequently on dermal fibrosis and myofibroblast which is expressed by α -SMA which is in line with our results that reported that NaB leads to reduction of TGF- β 1, α -SMA, and dermal thickness.

Genetics and environmental factors cause endothelial cell injury, leading to up-regulation of cellular adhesion molecules (vascular cell adhesion molecule (VCAM),

intracellular cell adhesion molecule (ICAM) which in turn recruit inflammatory mononuclear cells of which most are T-helper (Th) cells. The Th cells (Th1, Th2, and Th17) produce IL-1, IL-2, IL-4, IL-6, IL-8, IL-12, IL-13, IL-17, tumor necrosis factor (TNF)- α , interferon (IFN)- α and IFN- γ . Production of these cytokines consequently leads to inflammation and activation of fibroblasts and myofibroblasts, resulting in fibrosis (37). Zapolska-Downar et al. (38) reported that NaB causes a decrease in VCAM-1 and ICAM-1 expression, this could explain the decrease of IL-4 with NaB. Furthermore, it decreased MDA and increased SOD, as butyrate is one of the HDAC inhibitors having potent antioxidant and anti-inflammatory properties through reduction of ROS mediated by NF- κ B activation (39).

Even though NaB modulates apoptosis via alteration of the balance between pro- and anti-apoptotic proteins and thus interferes with the maintenance of a good balance between DNA damage and apoptosis, caspase-3 expression increased in our work, for further investigation (40). These findings were reflected histopathologically as a mild reduction of dermal fibrosis and dermal thickness when compared to the untreated scleroderma group which agrees with the recent study by Park et al. (36).

MMF induces programmed cell death of activated human T lymphocytes and human T-lymphocyte cell lines, and inhibit of antibody production by activated B cells, maturation, and cytokine expression. Finally, it is effective in suppressing oxidative stress accompanied by immunologically driven inflammatory reactions (41). MMF revealed a significant decrease in ACA detection in the serum, a result that may be explained by its effect on inhibition of antibody production by activated B cells, inhibition of maturation, and cytokine expression (41).

Most inflammatory cells infiltrating the skin in scleroderma are T lymphocytes. Activated T lymphocytes stimulate fibroblasts and the expression of adhesion molecules. T lymphocytes, through profibrotic cytokines production as TGF- β 1, IL-6, IL-4, IL-2, and via cell-cell contact, induce the transformation of fibroblasts into myofibroblasts. The cytostatic effect of MMF is significantly more prominent on activated T- lymphocytes than other cell types. It also inhibits the expression of adhesion molecules, and the recruitment of lymphocytes and monocytes to inflammatory sites (18).

The results of our study are in line with Ozgen et al. (18), who proved that MMF decreases levels of TGF- β 1, IL-4, and α -SMA expression in mice with experimental BLM-induced scleroderma. Activated macrophages in turn produce copious amounts of TGF, platelet-derived growth factor (PDGF), thus stimulating collagen production by fibroblasts

(3). MMF decreases oxidative stress severity by reducing oxygen-free radical production. Moreover, it may decrease the production of ROS and H₂O₂ production (42), which explain the effect of MMF in our study on decreasing MDA and increasing SOD activity.

Regarding apoptosis, MMF caused a significant decrease in caspase-3 IHC expression. The effect of MMF on the prevention of apoptosis in scleroderma is poorly studied and requires further investigations in parallel with other sets of apoptotic and anti-apoptotic markers. moreover, histopathological examination revealed a moderate reduction in dermal fibrosis with a significant decrease in dermal thickness as compared to the BLM group which is in line with the previous study by Ozgen et al. (18).

When NaB and MMF were compared to each other, they showed a non-significant difference in ACA, IL-4, and α -SMA. However, MMF showed superiority in the reduction of TGF- β 1 levels and in its antioxidant, anti-apoptotic effects, histopathological findings, and dermal thickness. as compared to NaB. The superiority of MMF over NaB may be attributed to the kinetic fact that NaB is rapidly metabolized and eliminated within 5-13 minutes after IV administration, therefore there is a limitation in its clinical use (43). When NaB/MMF combination treatment is compared to monotherapy by either NaB or MMF, it provides an augmented amelioration of the disease activity and revealed superiority.

In conclusion, NaB and MMF are promising candidates for the treatment of scleroderma by immunomodulatory, antioxidant, anti-apoptotic, and antifibrotic mediated mechanisms. Their combination is superior to monotherapy by each drug alone. Further research is recommended to compose and investigate new formulas of NaB with enhanced kinetic properties. Moreover, these results should be verified in humans in further clinical studies.

6. Abbreviations

ACA: anticentromere antibody; α -SMA: alpha-smooth muscle actin; BLM: bleomycin;

ELISA: enzyme-linked immunosorbent assay; H&E: hematoxylin & eosin; i.p:

intraperitoneal; IL-4: interleukin-4; ICAM: intracellular cell adhesion molecule; LSC:

localized scleroderma; MDA: malondialdehyde; MMF: mycophenolate mofetil; NaB: sodium

butyrate; PBS: phosphate buffer saline; ROS: reactive oxygen species; SEM: standard error

of mean; SOD: superoxide dismutase; SSc: systemic sclerosis; TGF- β 1 : transforming growth factor- β 1; VCAM: vascular cell adhesion molecule;

10. References

1. Johnson ME, Pioli PA, Whitfield ML. Gene expression profiling offers insights into the role of innate immune signaling in SSc. In: *Seminars in immunopathology*. Springer; 2015. p. 501–9.
2. Ferrelli C, Gasparini G, Parodi A, Cozzani E, Rongioletti F, Atzori L. Cutaneous manifestations of scleroderma and scleroderma-like disorders: a comprehensive review. *Clin Rev Allergy Immunol*. 2017;53(3):306–36.
3. Singh D, Parihar AKS, Patel S, Srivastava S, Diwan P, Singh MR. Scleroderma: an insight into causes, pathogenesis and treatment strategies. *Pathophysiology*. 2019;26(2):103–14.
4. Fett N, Werth VP. Update on morphea: part I. Epidemiology, clinical presentation, and pathogenesis. *J Am Acad Dermatol*. 2011;64(2):217–28.
5. Nikitorowicz-Buniak J, Shiwen X, Denton CP, Abraham D, Stratton R. Abnormally differentiating keratinocytes in the epidermis of systemic sclerosis patients show enhanced secretion of CCN2 and S100A9. *J Invest Dermatol*. 2014;134(11):2693–702.
6. Marangoni RG, Varga J, Tourtellotte WG. Animal models of scleroderma: recent progress. *Curr Opin Rheumatol*. 2016;28(6):561–70.
7. Yamamoto T, Takagawa S, Katayama I, Yamazaki K, Hamazaki Y, Shinkai H, et al. Animal model of sclerotic skin. I: Local injections of bleomycin induce sclerotic skin mimicking scleroderma. *J Invest Dermatol*. 1999;112(4):456–62.
8. Yamamoto T, Nishioka K. Animal model of sclerotic skin. V: increased expression of α -smooth muscle actin in fibroblastic cells in bleomycin-induced scleroderma. *Clin Immunol*. 2002;102(1):77–83.
9. Raman V, Quillen K, Sloan M. Acquired Glanzmann thrombasthenia associated with Hodgkin lymphoma: rapid reversal of functional platelet defect with ABVD (adriamycin/bleomycin/vinblastine/dacarbazine) chemotherapy. *Clin Lymphoma Myeloma Leuk*. 2014;14(2).

10. Yamamoto T. Bleomycin and the skin. *Br J Dermatol*. 2006;155(5):869–75.
11. Balbir-Gurman A, Braun-Moscovici Y. Scleroderma–New aspects in pathogenesis and treatment. *Best Pract Res Clin Rheumatol*. 2012;26(1):13–24.
12. Zhou B, Te Ba, Wang L, Gao Y, He Q, Yan Z, et al. Combination of sodium butyrate and probiotics ameliorates severe burn-induced intestinal injury by inhibiting oxidative stress and inflammatory response. *Burns* [Internet]. 2021; Available from: <https://www.sciencedirect.com/science/article/pii/S0305417921003144>
13. Liu H, Wang J, He T, Becker S, Zhang G, Li D, et al. Butyrate: a double-edged sword for health? *Adv Nutr*. 2018;9(1):21–9.
14. Pacheco RG, Esposito CC, Müller LCM, Castelo-Branco MTL, Quintella LP, Chagas VLA, et al. Use of butyrate or glutamine in enema solution reduces inflammation and fibrosis in experimental diversion colitis. *World J Gastroenterol WJG*. 2012;18(32):4278.
15. Bandelier C, Guerne P-A, Genevay S, Finckh A, Gabay C. Clinical experience with mycophenolate mofetil in systemic autoimmune conditions refractory to common immunosuppressive therapies. *Swiss Med Wkly*. 2009;139(3–4):41–6.
16. Ruzehaji N, Avouac J, Elhai M, Frechet M, Frantz C, Ruiz B, et al. Combined effect of genetic background and gender in a mouse model of bleomycin-induced skin fibrosis. *Arthritis Res Ther*. 2015;17(1):1–12.
17. Shakoori TA, Zulfiqar S, Khawaja KI, Masud F. Effect of Butyrate on Genetic Expression of Sirt1/AMPK and Akt/mTOR Axes in Murine Adipose Tissue. *Pak J Zool*. 2018;50(2).
18. Ozgen M, Koca SS, Dagli AF, Gundogdu B, Ustundag B, Isik A. Mycophenolate mofetil and daclizumab targeting T lymphocytes in bleomycin-induced experimental scleroderma. *Clin Exp Dermatology Exp dermatology*. 2012;37(1):48–54.
19. Ohkawa H, Ohishi N, Yagi K. Assay for lipid peroxides in animal tissues by thiobarbituric acid reaction. *Anal Biochem*. 1979;95(2):351–8.
20. Masayasu M, Hiroshi Y. A simplified assay method of superoxide dismutase activity for clinical use. *Clin Chim acta*. 1979;92(3):337–42.
21. Akasaka Y, Ishikawa Y, Ono I, Fujita K, Masuda T, Asuwa N, et al. Enhanced

- expression of caspase-3 in hypertrophic scars and keloid: induction of caspase-3 and apoptosis in keloid fibroblasts in vitro. *Lab Investig.* 2000;80(3):345–57.
22. Błyszczuk P, Kozlova A, Guo Z, Kania G, Distler O. Experimental Mouse Model of Bleomycin-Induced Skin Fibrosis. *Curr Protoc Immunol.* 2019;126(1):e88.
 23. Yamamoto T, Katayama I. Vascular changes in bleomycin-induced scleroderma. *Int J Rheumatol.* 2011;2011.
 24. Avouac J. Mouse model of experimental dermal fibrosis: the bleomycin-induced dermal fibrosis. In: *Arthritis Research.* Springer; 2014. p. 91–8.
 25. Ceribelli A, Cavazzana I, Franceschini F, Airò P, Tincani A, Cattaneo R, et al. Anti-Th/To are common antinucleolar autoantibodies in Italian patients with scleroderma. *J Rheumatol.* 2010;37(10):2071–5.
 26. Worrell JC, O'Reilly S. Bi-directional communication: Conversations between fibroblasts and immune cells in systemic sclerosis. *J Autoimmun.* 2020;102526.
 27. Kraaij MD, van Laar JM. The role of B cells in systemic sclerosis. *Biol targets Ther.* 2008;2(3):389.
 28. Henderson J, Distler J, O'Reilly S. The role of epigenetic modifications in systemic sclerosis: a druggable target. *Trends Mol Med.* 2019;25(5):395–411.
 29. Grygiel-Górniak B, Puszczewicz M. Oxidative damage and antioxidative therapy in systemic sclerosis. *Mediators Inflamm.* 2014;2014.
 30. Gabrielli A, Svegliati S, Moroncini G, Amico D. Suppl 1: New Insights into the Role of Oxidative Stress in Scleroderma Fibrosis. *Open Rheumatol J.* 2012;6:87.
 31. Yamamoto T. The bleomycin-induced scleroderma model: what have we learned for scleroderma pathogenesis? *Arch Dermatol Res.* 2006;297(8):333–44.
 32. Yamamoto T, Nishioka K. Possible role of apoptosis in the pathogenesis of bleomycin-induced scleroderma. *J Invest Dermatol.* 2004;122(1):44–50.
 33. Jelaska A, Korn JH. Role of apoptosis and transforming growth factor β 1 in fibroblast selection and activation in systemic sclerosis. *Arthritis Rheum Off J Am Coll Rheumatol.* 2000;43(10):2230–9.
 34. Manetti M, Neumann E, Distler O, Müller-Ladner U. Animal models of scleroderma: from cellular and molecular mechanisms to novel antifibrotic strategies. *Adv Vasc*

Med. 2009;57–75.

35. Angadi P V, Kale AD, Hallikerimath S. Evaluation of myofibroblasts in oral submucous fibrosis: correlation with disease severity. *J oral Pathol Med*. 2011;40(3):208–13.
36. Park HJ, Jeong O-Y, Chun SH, Cheon YH, Kim M, Kim S, et al. Butyrate Improves Skin/Lung Fibrosis and Intestinal Dysbiosis in Bleomycin-Induced Mouse Models. *Int J Mol Sci*. 2021;22(5):2765.
37. Fett N. Scleroderma: nomenclature, etiology, pathogenesis, prognosis, and treatments: facts and controversies. *Clin Dermatol*. 2013;31(4):432–7.
38. Zapolska-Downar D, Siennicka A, Kaczmarczyk M, Kołodziej B, Naruszewicz M. Butyrate inhibits cytokine-induced VCAM-1 and ICAM-1 expression in cultured endothelial cells: the role of NF- κ B and PPAR α . *J Nutr Biochem*. 2004;15(4):220–8.
39. Russo I, Luciani A, De Cicco P, Troncone E, Ciacci C. Butyrate attenuates lipopolysaccharide-induced inflammation in intestinal cells and Crohn's mucosa through modulation of antioxidant defense machinery. *PLoS One*. 2012;7(3):e32841.
40. Khan S, Jena G. Sodium butyrate, a HDAC inhibitor ameliorates eNOS, iNOS and TGF- β 1-induced fibrogenesis, apoptosis and DNA damage in the kidney of juvenile diabetic rats. *Food Chem Toxicol*. 2014;73:127–39.
41. Zwerner J, Fiorentino D. Mycophenolate mofetil. *Dermatol Ther*. 2007;20(4):229–38.
42. Kędzierska K, Domański M, Sporniak-Tutak K, Dołęgowska B, Ciechanowski K. Oxidative Stress and Renal Interstitial Fibrosis in Patients After Renal Transplantation: Current State of Knowledge. *Transplant Proc [Internet]*. 2011;43(10):3577–83. Available from: <https://www.sciencedirect.com/science/article/pii/S0041134511012735>
43. Daniel P, Brazier M, Cerutti I, Pieri F, Tardivel I, Desmet G, et al. Pharmacokinetic study of butyric acid administered in vivo as sodium and arginine butyrate salts. *Clin Chim acta*. 1989;181(3):255–63.

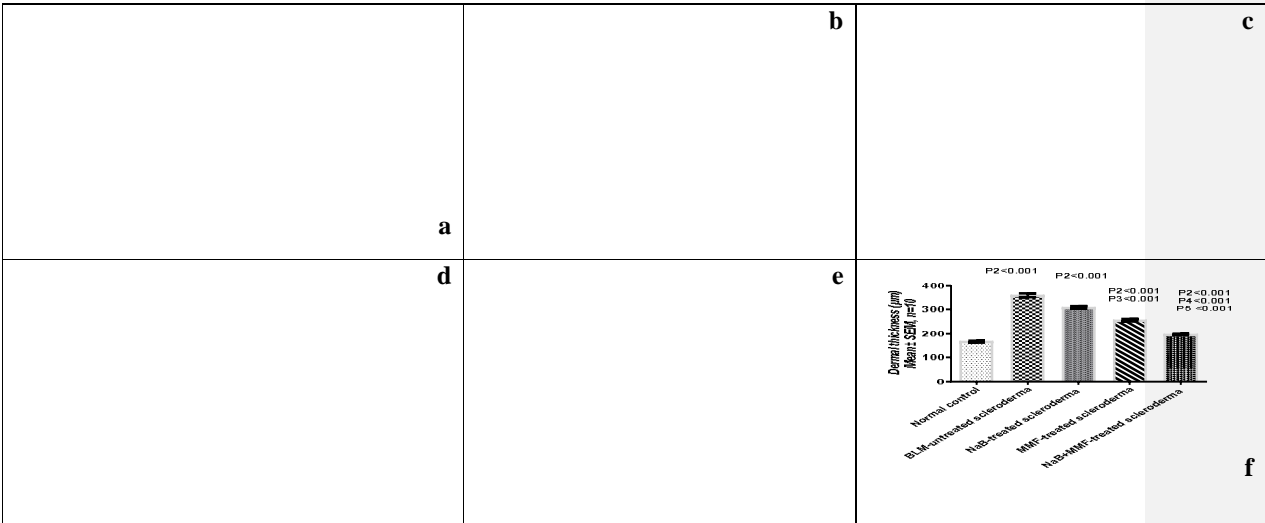


Fig. 1: Light microscope histopathological examination of H&E stained skin sections of different studied groups: (a): normal control (group 1) showing normal skin consisting of epidermis with underlying normal thickness of dermis (red arrow). [200], (b): BLM-untreated scleroderma (group 2) showing marked dermal fibrosis (red arrow) with surface ulceration (green arrow). [200], (c): NaB-treated scleroderma (group 3) showing mild reduction of dermal fibrosis (red arrow). [200], (d): MMF-treated scleroderma (group 4) showing moderate reduction of dermal fibrosis (red arrow). [x200], (e): NaB+MMF-treated scleroderma (group 5) showing marked reduction of dermal fibrosis (red arrow). [x200], (f): Imaging measurement of dermal thickness (µm) of skin sections.






Fig. 2: Light microscope histopathological examination of Masson trichrome stained skin sections of different studied groups: (a): normal control (group 1) showing blue staining of dermal fibroblasts showing normal thickness of dermis (red arrow). [X100], (b): BLM-untreated scleroderma (group 2) showing marked blue staining of dermal fibrosis (red arrow) with surface ulceration (green arrow). [x200], (c): NaB-treated scleroderma (group 3) showing mild reduction of dermal fibrosis with blue staining (red arrow). [x100], (d): MMF-treated scleroderma (group 4) showing moderate reduction of dermal fibrosis with blue staining (red arrow). [x100], (e): NaB+MMF-treated scleroderma (group 5) showing marked reduction of dermal fibrosis with blue staining (red arrow). [x200]





F

Fig.3: Immunohistochemical (IHC) expression of caspase-3 in skin sections of different studied groups:
 (a): Showing negative Caspase-3 staining of dermal myofibroblasts in normal control (group 1). [X200], (b): Showing apparent strong Caspase-3 staining of dermal myofibroblasts in BLM-untreated scleroderma (group 2). [x200], (c): Showing strong Caspase-3 staining of dermal myofibroblasts in NaB-treated scleroderma (group 3). [x200], (d): Showing apparent moderate Caspase-3 staining of dermal myofibroblasts in MMF-treated scleroderma (group 4). [x200], (e): Showing mild Caspase-3 staining of dermal myofibroblasts in NaB+MMF-treated scleroderma (group 5). [x200], (f): Scores of immunohistochemical (IHC) expression of caspase-3 in different studied groups



f

Fig.4: Immunohistochemical (IHC) expression of α -SMA in skin sections of different studied groups:
 (a); Showing apparent mild α -SMA staining of dermal myofibroblasts in normal control (group 1). [X200], (b): Showing strong α -SMA staining of dermal myofibroblasts in BLM-untreated scleroderma (group2). [x200], (c): Showing moderate α -SMA staining of dermal myofibroblasts in NaB-treated scleroderma (group 3). [x200], (d): Showing moderate α -SMA staining of dermal myofibroblasts in MMF-treated scleroderma (group 4). [x200], (e): Showing mild α -SMA staining of dermal myofibroblasts in NaB+MMF-treated scleroderma (group 5). [x200], (f): Scores of immunohistochemical (IHC) expression of α -SMA in different studied groups.