

Review Article

Psammomatoid and Trabecular Juvenile Ossifying Fibromas: Two Aggressive Tumors

Abstract: Juvenile ossifying fibromas (JOFs) of the jaws are uncommon benign fibro-osseous tumors affecting children under 15 years of age. Based on histological criteria, JOFs have been classified into psammomatoid and trabecular. Their aggressiveness, added to their high tendency to recur, provokes real diagnostic and therapeutic challenges for the dental practitioner and makes postoperative follow-up over the years indispensable. The aim of this article was to review the clinical, histological, and radiological features of these lesions as well as their treatment modalities.

Keywords: Juvenile, ossifying fibroma, trabecular, psammomatoid.

1. Introduction

Juvenile ossifying fibromas (JOFs), also known as juvenile active ossifying fibromas and juvenile aggressive ossifying fibromas, are uncommon benign fibro-osseous tumors (1,2). They present as osteolytic lesions affecting the facial bones with possible intracranial and orbital extensions (3-5). Typically, JOFs occur under the age of 15 with no gender predilection (3,4).

Histologically, and like in all the ossifying fibromas, the normal bone is replaced by a fibrous cellular stroma including mineralized bone trabeculae and cementum-like material (6,7).

Due to their high recurrence rate, early diagnosis, appropriate treatment, and long-term follow-up are indispensable (3).

The main objective of this article was to review the clinical, histological, and radiological features of JOFs as well as their treatment modalities.

Comment [DC1]: I would like to congratulate the author for proposing the description of a lesion so rare and great interest to the field of Dentistry. However, I suggest below some modifications so that the manuscript can better suit the publication.

- 1- The manuscript is a literature review, but some points about the lesion are little explored. Although it is a rare lesion, there are data available in the world literature that could be added to this review and were not detailed in demographic, clinical, radiographic, and mainly histological aspects (i.e. ethnicity, other histopathological findings, etc.)
- 2- The author adds some figures throughout the text, however, it is not clear if they are his own. In the case of figures whose owner is the author, I advise that the case of this patient be reported, changing the type of manuscript to "case report and literature review". In this situation, there would be a need to add the "discussion" section. The description of your case will be of paramount importance so that the scientific community can appreciate the findings of this rare lesion.
- 3- Another suggestion would be to adopt the style of a letter to the editor or short communication instead of a literature review. The way it was written is not appropriate for a literature review, although it is a coherent text.
- 4- I also suggest that the figure legends provide more detail about the aspects presented.

2. Clinical, radiological, and histological features of JOFs

JOFs are variants of ossifying fibroma affecting young patients. According to a study conducted by Sloomweg et al.(8) the average age at the time of the lesion diagnosis was 11.8 years. The majority of the cases occur in the sinonasal area and the jaws more frequently in the maxilla than in the mandible(9,10).

Due to their aggressive nature, JOFs grow asymptotically to reach very large sizes, leading to severe facial asymmetry and giving suspicion of malignancy (10) (Figure 1).

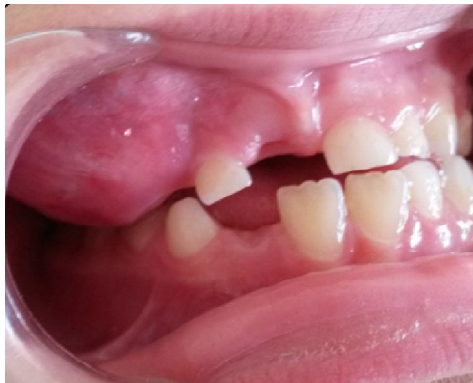

Figure 1: A well-defined, large swelling obliterating the vestibule

In many cases, JOFs reach the maxillary sinus, the nasal cavity, and push the globe superiorly. Extension to the cranial base is also reported (10,11). JOFs can provoke cortical thinning and perforation as well as tooth displacement and root resorption (3,6). Paresthesia is not commonly seen (3).

Radiologically, JOFs can be seen as well demarcated uni- or multilocular lesions; the amount of calcified tissue produced leads to a variable degree of radiolucency and radiopacity (6,12). Cone-beam computed tomography (3D radiography) assessment may show well-defined sclerotic borders with an inconsistent number of calcifications (13) (Figure 2).

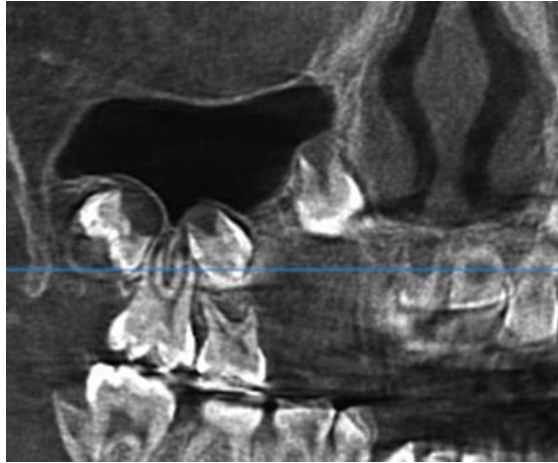


Figure 2: A CBCT image showing a large, well-defined mixed lesion

Histologically, JOFs show heterogeneous morphology. Cell-rich fibrous tissue with giant cells and bands of cellular osteoid trabeculae are often present (10,14) (Figure 3).

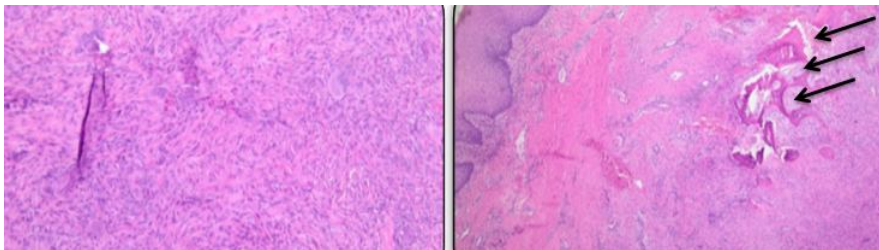


Figure 3: Histological cuts showing mixed spindle and giant cells and trabeculae of immature bone

Based on histological criteria, JOFs have been classified into two types: the psammomatoid, characterized by small uniform spherical ossicles resembling psammoma bodies commonly involving the orbit and paranasal sinuses, and the trabecular, distinguished by trabecular osteoid and woven bone mainly affecting the jaws (6).

3. Differential diagnosis

Many bone lesions, usually found in facial bones and jaws, may constitute a differential diagnosis challenge for JOFs. Fibrous dysplasia remains the most important one (1,2,15); it can be ruled out

as it typically shows normal marginal bone with less cellular stroma and an important amount of lamellar bone instead of woven one (16).

Cemento-ossifying fibroma, a histological variant of JOF, can as well be considered; nevertheless, giant cells, which are obviously found in JOFs, are not present in cement-ossifying fibromas (17).

Cementoblastoma, osteoblastoma, osteosarcoma, and other lesions must also be ruled out when diagnosing JOFs (1,15); this can be done through careful clinical, radiological and histological assessments.

4. Treatment of JOFs

The treatment modalities of JOFs remain controversial. Aggressive surgical resection and conservative surgery are among the suggested treatment techniques (18-20).

According to Abuzinad and Alyamani (2), the less aggressive approach should be considered first for JOF treatment in children. Likewise, Slootweg and Müller(21) recommended conservative surgery since they found no differences in the results between the limited surgical excision and the major approach.

On the other hand, many authors reported a high recurrence rate after conservative or mini-invasive treatment (in 30-56% of cases) (18,22,23), and therefore, a complete surgical resection remains the favorite choice of treatment (1,3,15,24).

It is to be noted that whatever the surgical technique was, a long-term postoperative follow-up is mandatory (1,2,4,15,25).

5. Conclusion

JOFs of the jaws are uncommon tumors with high risk of recurrence. Thorough evaluations of the clinical, radiological, and histological features of these lesions are needed to surmount the diagnostic and therapeutic challenges. Furthermore, long-term follow-up of the patient after complete surgical excision is indispensable.

References

1. Osunde O, Iyogun C, Adebola R. Juvenile aggressive ossifying fibroma of the maxilla: a case report and review of the literature. *Ann Med Health Sci Res.* 2013;3(2):288-290.
2. Abuzinada S, Alyamani A. Management of juvenile ossifying fibroma in the maxilla and mandible. *J Maxillofac Oral Surg.* 2010;9(1):91-95.
3. Sun G, Chen X, Tang E, Li Z, Li J. Juvenile ossifying fibroma of the maxilla. *Int J Oral Maxillofac Surg.* 2007;36(1):82-85.
4. Keles B, Duran M, Uyar Y, Azimov A, Demirkan A, Esen HH. Juvenile ossifying fibroma of the mandible: a case report. *J Oral Maxillofac Res.* 2010;1(2):e5.
5. Khademi B, Niknejad N, Mahmoudi J. An aggressive psammomatoid ossifying fibroma of the sinonasal tract: report of a case. *Ear Nose Throat J.* 2007;86(7):400-401.
6. El-Mofty S. Psammomatoid and trabecular juvenile ossifying fibroma of the craniofacial skeleton: two distinct clinicopathologic entities. *Oral Surg Oral Med Oral Pathol Oral Radiol Endod.* 2002;93(3):296-304.
7. Brannon RB, Fowler CB. Benign fibro-osseous lesions: a review of current concepts. *Adv Anat Pathol.* 2001;8(3):126-143.
8. Slootweg PJ, Panders AK, Koopmans R, Nikkels PG. Juvenile ossifying fibroma. An analysis of 33 cases with emphasis on histopathological aspects. *J Oral Pathol Med.* 1994;23(9):385-388.
9. Noffke CE. Juvenile ossifying fibroma of the mandible. An 8 year radiological follow-up. *Dentomaxillofac Radiol.* 1998;27(6):363-366.
10. Khanna J, Ramaswami R. Juvenile ossifying fibroma in the mandible. *Ann Maxillofac Surg.* 2018;8(1):147-150.
11. Barrena López C, Bollar Zabala A, Úrculo Bareño E. Cranial juvenile psammomatoid ossifying fibroma: case report. *J Neurosurg Pediatr.* 2016;17(3):318-323.
12. Papadaki ME, Troulis MJ, Kaban LB. Advances in diagnosis and management of fibro-osseous lesions. *Oral Maxillofac Surg Clin North Am.* 2005;17(4):415-434.

13. Brügger OE, Reichart PA, Werder P, Altermatt HJ, Bornstein MM. Asymptomatic ossifying fibroma of the mandible: a case presentation. *Quintessence Int.* 2012;43(5):381-385.
14. Kramer IR, Pindborg JJ. *Histological classification of odontogenic tumours histologic typing of odontogenic tumours.* 2nd edition. Berlin: Springer-verlog: 28. 1992
15. Rai S, Kaur M, Goel S, Prabhat M. Trabeculae type of juvenile aggressive ossifying fibroma of the maxilla: Report of two cases. *Contemp Clin Dent.* 2012;3(Suppl 1):S45-50.
16. Khoury NJ, Naffaa LN, Shabb NS, Haddad MC. Juvenile ossifying fibroma: CT and MR findings. *Eur Radiol.* 2002;12 Suppl 3:S109-113.
17. Williams HK, Mangham C, Speight PM. Juvenile ossifying fibroma. An analysis of eight cases and a comparison with other fibro-osseous lesions. *J Oral Pathol Med.* 2000;29(1):13-18.
18. Espinosa SA, Villanueva J, Hampel H, Reyes D. Spontaneous regeneration after juvenile ossifying fibroma resection: a case report. *Oral Surg Oral Med Oral Pathol Oral Radiol Endod.* 2006;102(5):e32-35.
19. Dominguet PR, Meyer TN, Alves FA, Bittencourt WS. Juvenile ossifying fibroma of the jaw. *Br J Oral Maxillofac Surg.* 2008;46(6):480-481.
20. Saiz-Pardo-Pinos AJ, Olmedo-Gaya MV, Prados-Sánchez E, Vallecillo-Capilla M. Juvenile ossifying fibroma: a case study. *Med Oral Patol Oral Cir Bucal.* 2004; 9(5):456-458
21. Sloopweg PJ, Müller H. Juvenile ossifying fibroma. Report of four cases. *J Craniomaxillofac Surg.* 1990;18(3):125-129.
22. Shekhar MG, Bokhari K. Juvenile aggressive ossifying fibroma of the maxilla. *J Indian Soc Pedod Prev Dent.* 2009;27(3):170-174.
23. MacDonald-Jankowski DS. Fibro-osseous lesions of the face and jaws. *Clin Radiol.* 2004;59(1): 11-25. Erratum in: *Clin Radiol.* 2009;64(1):107.

24. Thankappan S, Nair S, Thomas V, Sharafudeen KP. Psammomatoid and trabecular variants of juvenile ossifying fibroma-two case reports. *Indian J Radiol Imaging.* 2009;19(2):116-119.
25. Breheret R, Jеufroy C, Cassagnau E, Malard O. Juvenile ossifying fibroma of the maxilla. *Eur Ann Otorhinolaryngol Head Neck Dis.* 2011;128(6):317-320.