

Original Research Article

Endoscopically Assisted Repair of Nasal Septal Perforation Using Platelet Rich Plasma

Abstract

Background: Nasal septal perforations (NSPs) are nasal septum defects as a result of necrosis to the cartilage or bony tissues in addition to their mucous membrane on both surfaces. The current work aimed to estimate endoscopically assisted repair of medium-sized nasal septal perforation using inferiorly based rotational flap together with Platelet rich plasma (PRP).

Methods: It was a randomized controlled double-blind study recruited on 40 cases with anterior septal perforation for endoscopic repair. Patients randomly were allocated into two equal groups: group A were cases with anterior septal perforation for endoscopic repair using inferior based mucosal rotational and septal flaps only and group B were patients subjected to inferior based mucosal rotational and septal flaps together with PRP. All participants were exposed to thorough history taking, laboratory, clinical examination, and radiological investigation.

Results: Number of patients who had complete or partial closure of septal perforation, was insignificantly different between both groups. Number of patients who had decrease in size of perforation, same size perforation, residual symptoms, and who were asymptomatic was insignificant difference between both groups. Times to disappearance of residual epistaxis and residual crusting were significantly earlier in group B in comparison with group A ($P = 0.001$ and 0.011 respectively).

Conclusions: Overall, PRP is a promising material for nasal septal perforation. Times to disappearance of residual epistaxis and residual crusting were remarkably earlier in group B in comparison with group A.

Keywords: Endoscopically, Assisted Repair, Nasal Septal Perforation, Platelet Rich Plasma

Introduction:

Nasal septal perforations (NSPs) are complications in the nasal septum due to necrosis of the cartilage or bony tissues as well as their mucous membrane on both surfaces. The most frequent signs of septal perforations implicate crustation, epistaxis, nasal whistling, rhinorrhoea, and nasal obstruction with severe symptoms prevailing in cases with greater and more anterior perforations^[1-4].

There are several factors affecting perforations, however the most of them arises in response to iatrogenic injury after submucosal resection surgery. Other regular causes comprise trauma, neoplasm, infection and inhalation of irritants chemical such as cocaine^[2, 3]. 0.9% of adult population have perforations^[5], Roughly 85% of them are asymptomatic.

In spite of its incidence, relatively few cases requested for surgery, since symptoms are often managed with conservative approaches, such as topical gel, saline spray and nasal emollients. Additionally, the nasal buttons placement is considered effective. There are several surgical procedures to close a nasal septal perforation if conservative approaches are ineffective^[6].

Surgical techniques most commonly depend on size, perforation site and the surgeon experience^[7, 8]. Typically, smaller perforations may be repaired endoscopically, while greater perforations might necessitate an open septorhinoplasty. External procedures provide binocular vision and a larger operating field, particularly along the posterior and superior margins of the perforation^[4]. Most techniques are based on the pedicled endonasal flaps, which can be used to repair small-medium septal perforations. Endonasal flaps include the bridge-flap^[9], inferior turbinate flap^[10], inferior meatal flap^[7, 8], anterior ethmoidal artery flap^[11], lateral nasal wall flap^[12], and middle turbinate flap^[13]. Nevertheless, in large perforations, a flap such as the pericranial flap for complete closure may be necessary^[14].

Corret spelling :[1APE|FW]Comment

Platelets are cytoplasmic parts of megakaryocytes, developed in bone marrow with diameter approximately 2 μ m. They hold greater than 30 bioactive proteins, the majority of which play a crucial role in tissue healing and hemostasis. All wound healing is initiated by seven essential protein growth factors secreted actively by platelets^[15]. PRP also contains three blood proteins considered as cell adhesion molecules: Fibrin, vitronectin and fibronectin.

Therefore, our study aimed to estimate endoscopically assisted management of medium-sized nasal septal perforation via inferiorly based rotational flap together with PRP.

Patients and Methods:

This randomized controlled double-blind study recruited 40 cases with anterior septal perforation for endoscopic repair starting from 1st of April 2019 till the end of November 2020 and the follow up for at least 6 months after the operation at the department of Otorhinolaryngology, at Otorhinolaryngology department, Tanta University Hospitals after being approved by the institutional ethical committee, Tanta University. All participants wrote an informed consent.

Patient aged from 18 to 60 years, size of perforations: less than 1.5 cm, site of perforation (anterior), post-traumatic perforation were included.

Patients with one or more of the following criteria had been excluded from the study: Cases don't follow up after surgery, Site of perforation (posterior), Size of perforation (very small, large), Nasal tumors or chronic granuloma of the nose. Diabetic patients, drug abusers, heavy smokers. Patients with contraindications for general surgery were excluded.

Randomization and blindness:

Randomization was performed by computer-generated random numbers and closed opaque envelopes that opened later after enrolment by a nurse who did not participate in any part of the study. Both of the physician and the patient were blinded to PRP application.

How sample size : [2APE | FW] Comment ? was calculated

Better mention no : [3APE | FW] Comment of ethica commity orderr

Patients randomly were allocated into two equal groups: group A were cases with anterior septal perforation for endoscopic repair using inferior based mucosal rotational and septal flaps only and group B were patients subjected to inferior based mucosal rotational and septal flaps together with PRP.

All patients included in the present study had been subjected to:

Detailed history taking including: Personal data (Name, age, sex, occupation, address), Complaint (pain-Numbness and tinglingweakness — autonomic symptoms), Present history (duration, progress and mode of onset,), Previous medical history, risk factors including (drug intake, obesity, diabetes mellitus, hypertension, smoking, , and collagen disorders comorbid diseases such as renal and hepatic diseases or), Previous surgical and medical problems and family history of similar conditions..

Careful clinical examination: General examination (Blood pressure, Pulse, Cardiovascular, Neurological and Respiration assessment). Local examination: Preoperative examination of the nose using A 0-degree nasal endoscope and metal roller to detect the size of perforation. assessment of nasal and sinus passages using direct vision and a magnified, high-quality image was carried out during nasal endoscopy. It is a common procedure performed in the office of an otolaryngologist and considered as an effective diagnostic tool for estimation of sinonasal anatomy, nasal mucosa and nasal pathology.

Technique:

The endoscope was delivered after a nasal decongestant and a local anesthetic were applied to the nasal cavities. A 3 mm or 4 mm 0° scope is often utilized, and an antifog solution is used prior to its use in nasal cavity. Next, three independent passes were made with the scope through each nasal cavity. The apparition of the mucosa and the nasal cavity architecture are inspected with each pass. The mucosa color (pale versus hyperemic), the existence of inflammatory or hypertrophic mucosa, the presence of nasal polyps or secretions

(purulent, thick, or thin), and any obvious anatomic anomalies are all noted by the examiner (e.g., an accessory ostia, concha bullosa, septal deviation or spur).

Laboratory investigations: Liver function tests (AST, ALT, serum albumin, serum bilirubin, ALP), Renal functions tests (serum creatinine and serum urea), Complete blood count (CBC), INR, PT, PTT, Bleeding time, Clotting time and ESR

Radiological investigations: CT nose and Paranasal sinuses coronal & axial view.

CT scans can supply detailed information about the anatomy and abnormalities of the paranasal sinuses^[16]. CT scan has a vital role in diagnosis and decision making of repair of septal perforation by detection the condition of inferior turbinate if there is hypertrophy, we can take mucosal flap from it for repair the perforated septum. CT scan show the condition of middle turbinate if there is concha bullosa or hypertrophy in middle turbinate we can take mucosal flap for repair the perforated septum

Surgical technique:

A closed, endoscopic, endonasal technique is used to accomplish the surgery. Here, the nasal fossa on either side should be examined to assess patency. For ease of access, we elevate the rotational flap on the more patent side and the muco-perichondrial flap on the contralateral side. Next, the septum was injected with 1% lidocaine with 1:100,000 epinephrine, followed by intranasal placement of oxymetazoline soaked Cottonoid R pledgets. The posterior portion of the perforation was aggressively incised, resulting in 2 leaflets that were carried superiorly and inferiorly across the perforation, spanning about 180 degrees via transfixion incision, a unilateral mucoperichondrial flap circumferentially around the perforation beyond the posterior limit to the bony septum.

An empty foil suture pack was inserted into the mucoperichondrial pocket as an apposition barrier prior to raising the rotating flap to reduce harm to the mucoperichondrial flap. The rotating flap was then created by incising the contralateral mucosa with a 3-mm

angled ophthalmologic keratotomy or slit knife. The rotational flap appears posteriorly and inferiorly then, incision extend anteriorly and superiorly just inferior to the olfactory region, traverses below the internal nasal valve connecting to the anterior part of the septal perforation. The flap was designed to follow the path of the posterior nasal artery, a branch of the SPA. The mucosa was raised from the perichondrium and the defect is spanned with the rotating flap before suturing. A relaxing incision along the posterior portion of the pedicle may be required in some circumstances for greater rotation. Secondary aim is used to repair exposed cartilage superiorly and posteriorly to the flap pedicle. **In group B only: then the preparation of PRP:**

Collection of around 34ml of venous blood in 4 tubes (8.5ml each one) with 100 µl 8% EDTA-K2 anticoagulants. We used automatic blood cell analyzer to count the platelets in 2 ml of the blood and another 2 ml was stored at -80°C in a refrigerator for growth factor measurements. The remaining blood sample was shaken then placed in a centrifuge tube. PRP was prepared using the modified Curasan procedure, which involved centrifuging it twice. The centrifuge tube was first spun for 10 minutes at 1200 rpm at 24°C before transferring the upper layer with buffy coat to empty sterile tubes. Platelets pellets with few RBCs are collected at the bottom of the tube after the second spun at 2400 rpm at 24°C. The PRP Gel (5ml) is placed between the cartilage and mucoperichondrial flap on the side opposite the rotating flap. The rotating flap is secured meticulously into position along its anterior and inferior edges using chromic sutures on a small Keith needle. Finally, the anterior septal incision will be sewn together to complete the healing process. Lastly, non-absorbable sutures are used to fix antibacterial ointment-coated silica splints intra-nasally.

Post-operative care

The majority of cases have splints kept in place for 14 days, while cases are still taking oral antibiotic. rarely, the splints were prematurely removed due to acute sinusitis or apparent sensitivity. currently, splints have been maintained for 3 weeks with administration of low-dose aspirin as an anticoagulant and to potentially increase rotational flap survival.

Correct :[4APE|FW]Comment

Statistical analysis

SPSS v26 was used to perform statistical analysis (IBM Inc., Chicago, IL, USA). Comparing the two groups using an unpaired Student's t- test, quantitative data were provided as mean and standard deviation (SD). When applicable, qualitative variables were given as frequency and percentage (percent) and analyzed using the Chi-square test or Fisher's exact test. P value ≤ 0.05 was considered statistically significant.

Results:

In this study, eligibility of 47 cases were assessed, 4 patients did not match the inclusion requirements and 3 patients rejected the participation. The other 40 cases randomly were allocated into two groups (20 each). All of them were followed up and statistically analyzed. **Figure 1**

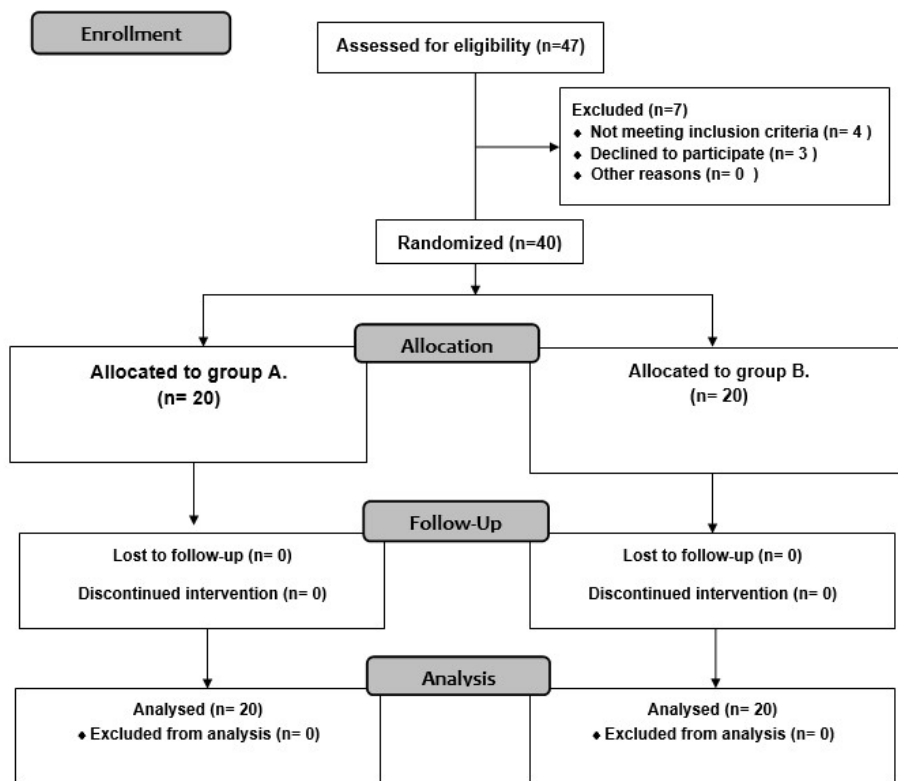


Figure 1: Diagram of the randomized trial enrolment, allocation of interventions, and analysis.

All patients' characteristics were insignificantly different between both groups. Size of perforation was insignificantly different between both groups. **Table 1**

Table 1: participants' characteristics and perforation size(cm) between both groups

| | | Group A (n=20) | Group B (n=20) | P value |
|--------------------------|-----------|-------------------|-------------------|---------|
| Age (years) | Mean ± SD | 34.65 ± 10.54 | 36.85 ± 10.60 | 0.514 |
| | Range | 21 – 59 | 23 – 56 | |
| Gender | Male | 13 (65.0%) | 12 (60.0%) | 0.744 |
| | Female | 7 (35.0%) | 8 (40.0%) | |
| Size of perforation (cm) | Mean ± SD | 0.95 ± 0.41 | 0.89 ± 0.34 | 0.616 |
| | Range | 0.3 – 1.5 | 0.3 – 1.5 | |

Number of patients who had complete or partial closure of septal perforation, was insignificantly different between both groups. **Table 2**

Table 2: Healing of septal perforation in both groups

| Healing of septal perforation | Group A (n = 20) | Group B (n = 20) | P value |
|-------------------------------|---------------------|---------------------|---------|
| Complete closure | 12 (60%) | 14 (70%) | 0.507 |
| Incomplete closure | 8 (40%) | 6 (30%) | |

Number of patients who had decrease in size of perforation, same size perforation, residual symptoms, and who were asymptomatic was insignificant difference between both groups. **Table 3**

Table 3: Residual size and symptoms of patients who had incomplete closure of septal perforation.

| | | Group A (n =8) | Group B (n =6) | P value |
|--------------------|---------------------------------|-------------------|-------------------|---------|
| Incomplete closure | Decrease in size of perforation | 5 (62.5%) | 5 (83.3%) | 1 |
| | Same size of perforation | 3 (37.5%) | 1 (16.7%) | 0.605 |
| | Residual symptoms | 3(37.5%) | 1(16.7%) | 0.605 |
| | • Whistling | 1 | 1 | |
| • Crustation | 1 | 0 | | |
| • Epistaxis | 1 | 0 | | |
| | Asymptomatic | 5 (62.5%) | 5 (83.3%) | 1 |

Times to disappearance of residual epistaxis and residual crustation were significantly earlier in group B compared to group A (P = 0.001 and 0.011 respectively). **Table 4**

Table 4: Postoperative duration for disappearance of manifestations between both groups

| | Group A (n = 20) | Group B (n = 20) | P value |
|--|---------------------|---------------------|---------------|
| Duration for disappearance of residual epistaxis (days) | 32 ± 2.12 | 17.5 ± .54 | 0.001* |
| Duration for disappearance of residual crustation (days) | 42.33 ± 2.52 | 27.5 ± 3.54 | 0.011* |

*: significant as P<0.05.

Discussion:

Nasal septal perforation of the cartilaginous and/or bony nasal septum is an anatomical defect. In the majority of cases, there is asymptomatic perforation; nonetheless, symptomatic cases have recurrent nasal crusting, epistaxis, whistling, dryness, headache, and nasal obstruction. Anterior perforations are typically symptomatic, but posterior perforations are asymptomatic due to the quick humidification by the nasal mucosa, preventing dryness^[17].

Platelet-rich plasma is a novel substance utilized frequently in several surgical specialties. Since PRP is autologous, it is safe, and it increases the platelets count and growth factors that are deposited in the healing region, as well as being simple to prepare.^[18]

The present study showed that size of perforation was 0.95 ± 0.41 with a range from 0.3 to 1.5 in group A and 0.89 ± 0.34 with range from 0.3 to 1.5 in group B. Size of perforation was insignificantly different between both groups.

In the study of Atallah et al.^[19], 14 cases with anterior septal perforation were included in the case series study, all of them underwent to superiorly based septal mucosal flap. They found out that the vertical diameter of the perforations ranged from 0.5 to 2 cm (mean \pm SD 1.38 ± 0.47 cm). The anteroposterior diameter of the perforation ranged from 1 to 2.5 cm (mean \pm SD 1.63 ± 0.51 cm). This technique revealed 71.4% success rate.

According to Lee et al.^[20], the perforation was in the cartilaginous area with 15 mm size (ranging from 7 to 20 mm)

In unilateral flap repair cases, the endoscopic approach has resulted in great success rates. In fact, Kridel^[21] highlighted that "a septal perforation is a hole in 3 distinct contiguous layers composed of both right and left septal mucoperichondrial flaps and the intervening cartilage, all 3 of which must be separated from each other and repaired individually". Nevertheless, Castelnovo et al.^[11] showed 100% success rate with simply an anterior ethmoidal artery unilateral septal flap without any interposition graft. There are several

advantages to use the unilateral nasal flap, including avoiding the perforation enlargement or development of other perforations and reducing the surgical time in such one step process. Moreover, some authors concluded that the bilateral flaps repair is the most important aspect for successful closure. Despite this, these authors were unable to achieve the success rate of endoscopic procedures utilizing only one flap and a graft.^[17]

The current study showed that there was 12 (60%) succeeded and 8 (40%) failed in group A, and 14 (70.0%) succeeded 6 (30%) failed in group B. Success was insignificantly different between both groups. Healing was insignificantly different between both groups. Times to disappearance of residual epistaxis and residual crusting were insignificantly different between both groups.

Lee et al.^[20], reported an endoscopic technique in 2008 that used a temporalis fascia on one side and unilateral advancement of mucosal flaps. Hemitransfixion flaps were created by making a lateral incision under the inferior turbinate and a horizontal incision on the septal dorsum. The mucoperiosteum and mucoperichondrium were then raised to generate two flaps that progress (one upward and the other downward) to cover the perforation before suturing with 5.0 vicryl. while performing a one stage procedure.

Mansour, 2011^[22], enrolled 6 cases with harvested free graft from the inferior turbinate and positioned between the mucoperichondrium of both septum sides. after following up for 2 years, 5 patients had a full repair (83%) and one partial repair, with a resolution of symptoms in all cases. This approach has the benefit of not requiring the development of flaps, but it can only repair the septal perforation on a single layer.

In contrast, Giacomini et al.^[23], suggested a three-layer repair of the septum using endoscopy. They conducted a hemitransfix incision and raised the mucoperichondrial and mucoperiosteal layers on both sides from the anterior septum to the choana and until the nasal

floor. After the perforation margins were sacrificed, the raised flaps were advanced bilaterally (mainly in a horizontal plane) using an inverted sliding flap technique.

Vertical or horizontal relaxation incisions are inserted for better mobilisation and facilitate vertical progress. Between the two flaps, an interpositional graft of autologous auricular conchal cartilage was placed. With this technique, the authors reported successful repair in 10 large (2-4 cm) perforations with a success rate of 71.4% and relief of symptoms in 12 patients (85.7%).

In addition, Castellnuovo et al.^[11], reported optimal outcomes with 100% repair in 11 perforations with diameter ranged from 10 to 25 mm using the AEA-supplied unilateral superiorly based rotational-advancement flap method.

In order to access the lateral wall of the posterior section of the inferior meatus, the researchers made an incision vertically along the septum. To reach the inferior border of the perforation, an incision is made perpendicular to the septum and runs horizontally along the inferior meatus till its anterior part. Before suturing around the perimeter of the perforation, the upper portion of the flap is crated so that it may be easily advanced. As a result of the one-layer method, all of the damaged areas could be repaired during the first experiment.

Another study of RPR-assisted tympanoplasty was carried out by Gopalakrishnan et al.^[24], 25 cases who underwent tympanoplasty using PRP and 25 control subjects who underwent tympanoplasty without PRP were compared. At the end of the first month, the closure rate was 72% in the PRP group and 40% in the control group. Additionally, the closure rate was 92% in the PRP group and 72% in the control group at the end of the second month; and 96% in the PRP group and 80% in the control group at the end of the third month. The authors concluded that applying RPR during tympanoplasty inhibits graft displacement.

In the study of Friji et al.^[25], described a technique for the autologous transplantation of fat and PRP to manage the atrophic rhinitis.

how can be used :[5APE|FW]Comment
tympanoplasty result fir sepyal perforation
term of PRP in

For the five cases, the, middle turbinate, inferior turbinate, floor and septum of both nasal cavities were treated with autologous lipoaspirate. The same sites were treated with PRP. The cases reported an amelioration in their symptoms, including loss of nasal crusting. The thorough clinical examination revealed no signs of atrophy and existence of glistening nasal mucosa

. Six months following the intervention, the average score on the SinoNasal outcome test 20 decreased from 36 to 8. In addition, nasal mucociliary clearance time was dramatically reduced after surgery (960 seconds) compared to before surgery (1995 seconds). The authors found that this technique yielded positive subjective and objective results. SinoNasal Outcome Test 20 scores had improved from 36 to 8. In addition, the nasal mucociliary clearance time was significantly shorter after (960 seconds) than before (1995 seconds) surgery. The authors concluded that this method achieved encouraging subjective and objective outcomes.

Following submucosal diathermy, Salaheldin and Hussein ^[26], injected PRP into inferior turbinates of 30 patients. Patients treated with PRP demonstrated remarkable improvements in mucociliary, bleeding, crusting, and clearance compared with a control saline group (n = 30).

According to Rice ^[27], published the initial findings of this prospective study on PRP as packing material after endoscopic sinus surgery. Some of the first 13 patients who received platelet-rich plasma suffered a worsening of their postoperative condition. As a result of these negative findings, the project was abandoned. Some limitations of the present study were the relatively sample size, single centric study and the exclusion of cases with posterior perforation site, the very small and large perforation size, nasal tumors or chronic granuloma of the nose, diabetic patients, drug abusers and heavy smokers.

Conclusions:

Overall, PRP is a promising material for nasal septal perforation. Times to disappearance of residual epistaxis and residual crusting were significantly earlier in group B compared to group A.

References:

1. Virkkula P, Mäkitie AA, Vento SI. Surgical outcome and complications of nasal septal perforation repair with temporal fascia and periosteal grafts. *Clinical Medicine Insights: Ear, Nose and Throat*. 2015;8: CMENT. S23230.
2. Kaya E, Cingi C, Olgun Y, Soken H, Pinarbasli Ö. Three-layer interlocking: a novel technique for repairing a nasal septum perforation. *Annals of Otolaryngology, Rhinology & Laryngology*. 2015; 124:212-5.
3. Chhabra N, Houser SM, editors. Endonasal repair of septal perforations using a rotational mucosal flap and acellular dermal interposition graft. *International forum of allergy & rhinology*; 2012: Wiley Online Library.
4. Re M, Paolucci L, Romeo R, Mallardi V. Surgical treatment of nasal septal perforations. Our experience. *Acta otorhinolaryngologica italica*. 2006; 26:102.
5. Oberg D, Akerlund A, Johansson L, Bende M. Prevalence of nasal septal perforation: the Skovde population-based study. *Rhinology*. 2003; 41:72-5.
6. Watson D, Barkdull G. Surgical management of the septal perforation. *Otolaryngologic Clinics of North America*. 2009; 42:483-93.
7. Goh A, Hussain S. Different surgical treatments for nasal septal perforation and their outcomes. *The Journal of Laryngology & Otology*. 2007;121:419-26.
8. Teymoortash A, Werner J. Repair of nasal septal perforation using a simple unilateral inferior meatal mucosal flap. *Journal of plastic, reconstructive & aesthetic surgery*. 2009; 62:1261-4.

Better provide :[6APE|FW]Comment
years old 5reference not more than

9. Schultz-Coulon H. Experiences with the bridge-flap technique for the repair of large nasal septal perforations. *Rhinology*. 1994; 32:25-33.
10. Friedman M, Ibrahim H, Ramakrishnan V. Inferior turbinate flap for repair of nasal septal perforation. *The Laryngoscope*. 2003; 113:1425-8.
11. Castelnuovo P, Ferrel F, Khodaei I, Palma P. Anterior ethmoidal artery septal flap for the management of septal perforation. *Archives of Facial Plastic Surgery*. 2011; 13:411-4.
12. Alobid I, Mason E, Solares CA, Prevedello D, Enseñat J, De Notaris M, et al. Pedicled lateral nasal wall flap for the reconstruction of the nasal septum perforation. A radio-anatomical study. *Rhinology*. 2015; 53:235-41.
13. Hanci D, Altun H. Repair of nasal septal perforation using middle turbinate flap (monopedicled superiory based bone included conchal flap): a new unilateral middle turbinate mucosal flap technique. *European Archives of Oto-Rhino-Laryngology*. 2015; 272:1707-12.
14. Alobid I, Langdon C, López-Chacon M, Enseñat J, Carrau R, Bernal-Sprekelsen M, et al. Total septal perforation repair with a pericranial flap: radio-anatomical and clinical findings. *The Laryngoscope*. 2018; 128:1320-7.
15. Schliephake H. Bone growth factors in maxillofacial skeletal reconstruction. *International journal of oral and maxillofacial surgery*. 2002; 31:469-84.
16. Dammann F, Bootz F, Cohnen M, Haßfeld S, Tatagiba M, Kösling S. Diagnostic imaging modalities in head and neck disease. *Deutsches Ärzteblatt International*. 2014; 111:417.
17. Park YS, Choi JY. Repair of Nasal Septal Perforation Using Polycaprolactone Plate and Temporalis Fascia Graft. *Journal of Rhinology*. 2019; 26:127-31.
18. Sclafani AP, Azzi J. Platelet preparations for use in facial rejuvenation and wound healing: a critical review of current literature. *Aesthetic plastic surgery*. 2015; 39:495-505.

19. Atallah AT, Khalil YA, Abdelshafi IA, El-Demerdash AA, Hamdan AM. Superiorly based septal mucosal flap for endoscopic repair of nasal septal perforation. *Menoufia Medical Journal*. 2019; 32:380.
20. Lee H-R, Ahn D-B, Park J-H, Kim Y-H, Sin C-M, Youn S-J, et al. Endoscopic repairment of septal perforation with using a unilateral nasal mucosal flap. *Clinical and Experimental Otorhinolaryngology*. 2008; 1:154.
21. Kridel RW. Considerations in the etiology, treatment, and repair of septal perforations. *Facial Plastic Surgery Clinics*. 2004; 12:435-50.
22. Mansour HA. Repair of nasal septal perforation using inferior turbinate graft. *The Journal of Laryngology & Otology*. 2011; 125:474-8.
23. Giacomini PG, Ferraro S, Di Girolamo S, Ottaviani F. Large nasal septal perforation repair by closed endoscopically assisted approach. *Annals of plastic surgery*. 2011; 66:633-6.
24. Sankaranarayanan G, Prithviraj V, Kumar R. A STUDY ON EFFICACY OF AUTOLOGOUS PLATELET RICH PLASMA IN MYRINGOPLASTY. *Online Journal of Otolaryngology*. 2013;3.
25. Friji M, Gopalakrishnan S, Verma S, Parida P, Mohapatra D. New regenerative approach to atrophic rhinitis using autologous lipoaspirate transfer and platelet-rich plasma in five patients: Our Experience. *Clinical Otolaryngology*. 2014; 39:289-92.
26. Salaheldin AH, Hussein A. Effect of platelet-rich plasma on nasal mucociliary clearance after submucous diathermy of inferior turbinate. *Egyptian Journal of Ear, Nose, Throat and Allied Sciences*. 2012; 13:71-5.
27. Rice DH. Platelet-rich plasma in endoscopic sinus surgery. *Ear, nose & throat journal*. 2006; 85:516-8.