

Nutcracker syndrome: an exceptional etiology of acute abdominal pain in young subjects : a case report

ABSTRACT

Nutcracker syndrome, a rare condition that causes abdominal pain as a result of the left renal vein being compressed as it passes between the aorta and the superior mesenteric artery, is most common in individuals between the ages of 20 and 30. Its diagnosis is based essentially on modern imaging methods (CT scan, Doppler ultrasound, phlebography) and its treatment is controversial, Doppler ultrasound has a sensitivity of 78% and a specificity of 100%. Both CT and MRI can show compression of the left renal vein between the aorta and superior mesenteric artery.

keywords: Nutcracker syndrome, Left renal vein, Aorto-mesenteric region, Surgery

Introduction

“Nutcracker syndrome is a rare etiology that corresponds to mild abdominal pain following benign acute abdominal pain due to compression of the left renal vein during its passage between the aorta and the superior mesenteric artery (SMA)” [2], leading to stenosis of the aorto-mesenteric part of the left renal vein and dilation of its hilar part [13]. “The symptomatology remains dominated by back pain, abdominal pain and hematuria. The diagnosis is confirmed by a CT scan of vascular reconstruction of the hilar region of the kidney and the study of the pressure gradient between the left renal vein and the inferior vena cava” [1].

Patient and observation

This is a young 21 year old male, chronic smoker 7 years old and cannabis user for 4 years, admitted to the emergency department for the assessment of acute epigastric abdominal pain not improved by usual analgesics, associated with pelvic heaviness, evolving for 20 days. The clinical examination showed a generalized abdominal defense. The standard radiological (abdomino-pelvic ultrasound) and biological (blood count, lipasemia) work-up was normal, hb 13 g/dL ; GB normal at 7500 elements/mm³ ,CRP was normal and lipasemia was normal at 45 . An abdomino-pelvic CT scan was performed before and after injection of contrast products and did not show any sign of peritonitis by ulcer perforation. However, it showed a dilatation of the left renal vein (LRV) upstream of a reduction in its caliber opposite the aorto-mesenteric region with a compression ratio (>2.25) (Figure 2) with narrowing of the aorto-mesenteric angle to 30° (Figure 4)

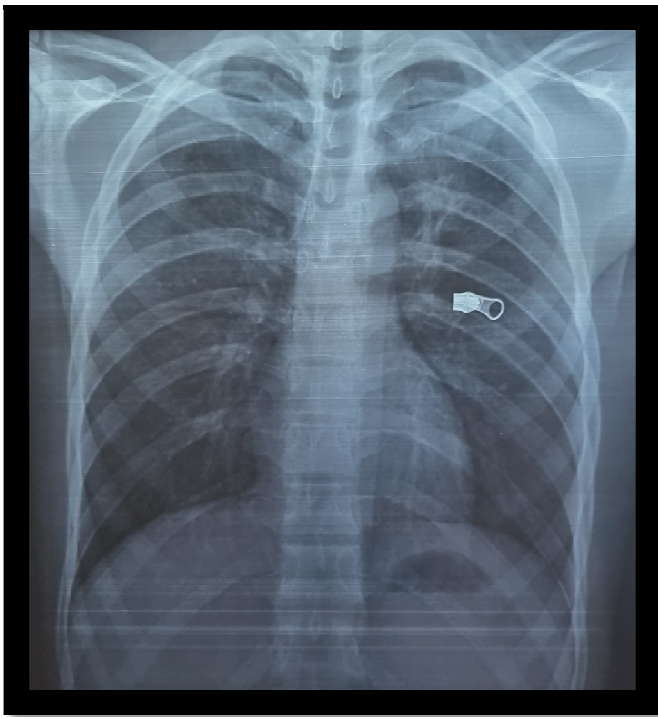


Figure 1: Chest X-ray centered on the domes

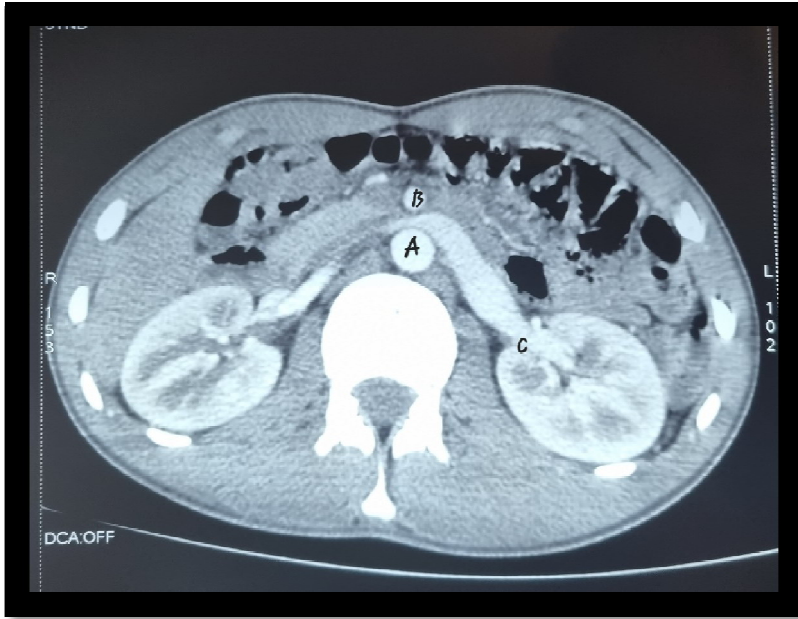

Figure 2: Axial section abdomino-pelvic CT scan before and after contrast material injection, beak sign (arrow) designating at the level of the aorto-mesenteric fork; A) abdominal aorta; B) superior mesenteric artery; C) compression of the left renal vein; ratio of hilar and aorto-mesenteric portion of the left renal vein diameter (>2.25), fulfilling the diagnostic criteria of **Nutcracker syndrome (NCA)**

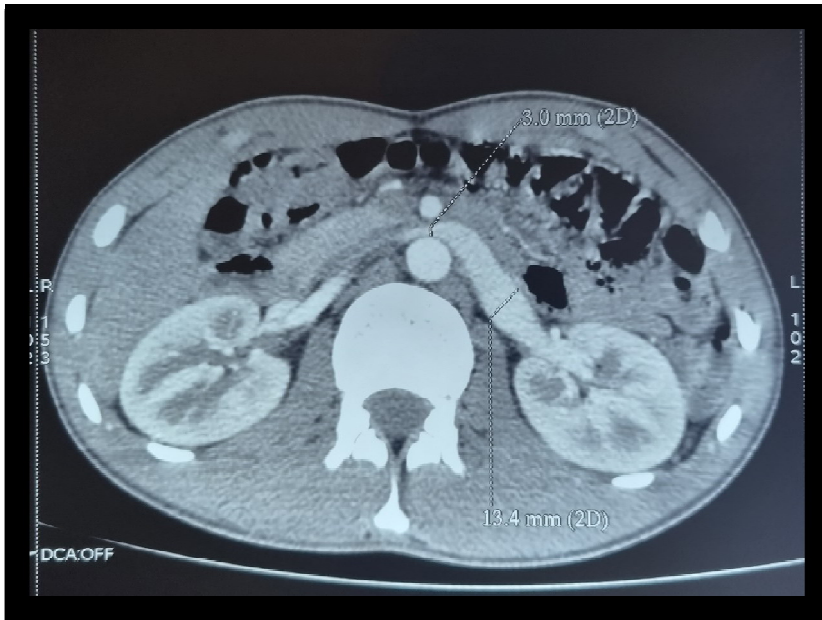

Figure 3: Axial section abdomino-pelvic CT scan before and after contrast material injection, beak sign (arrow) designating at the level of the aorto-mesenteric fork

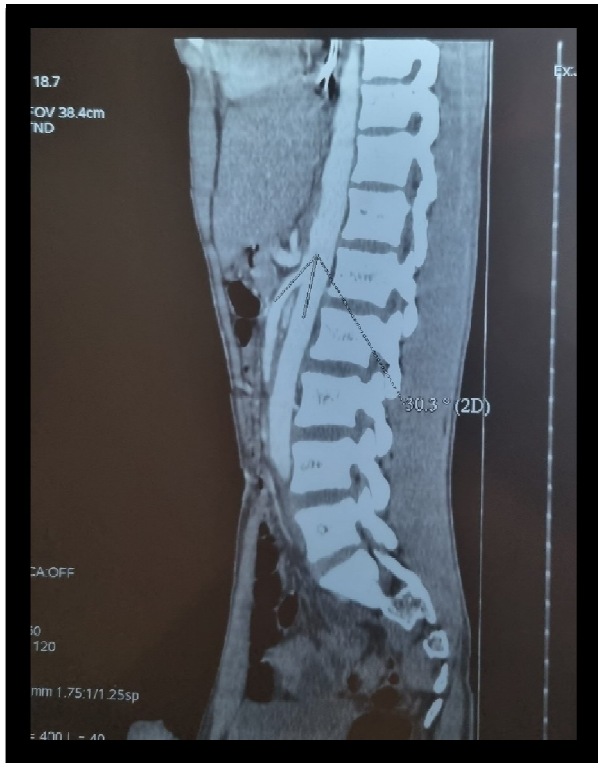

Figure 4: Sagittal section abdomino-pelvic CT scan before and after contrast material injection; A) angulation between abdominal aorta and superior mesenteric artery; B) measured at 30°, fulfilling the diagnostic criteria for NCA.

In front of this very evocative CT picture, the CT scan was sufficient to make the diagnosis of Nutcracker syndrome. After multidisciplinary discussion, therapeutic abstention was indicated given the intermittent nature of the clinical symptomatology and its moderate intensity

Discussion

"Nutcracker syndrome (NCA) refers to compression of the Left Renal Vein as it passes through the aorto-mesenteric clamp, resulting in obstruction of **blood flow from the left renal vein** to the inferior vena cava due to extrinsic compression" [4]. It is a rare entity, but probably underestimated with unknown prevalence [3] is higher in young subjects between 30 and 40 years of age, with a more frequent involvement in women [13,14], "more frequent in women in the third or fourth decade, although a later study showed an equal prevalence between men and women" [6], "probably related to the rapid development of the vertebral bodies during puberty, causing a narrowing of the angle between the abdominal aorta and the superior mesenteric artery" [5].

The syndrome can be divided into 3 types: anterior, posterior and mixed [15]. Anterior : found in the majority of cases, it corresponds to a compression of the Left Renal Vein, normally located, by the aorta and the Superior Mesenteric Artery; while the posterior variant, designates the participation of a retro-aortic Left Renal Vein, in a small space between the abdominal aorta and the vertebral column [8,16], "other etiologies: pancreatic tumors, para-aortic adenopathies, retroperitoneal tumors, abdominal aortic aneurysm, duplication of the left renal vein, left renal ptosis, lordosis, and decreased retroperitoneal and mesenteric adipose tissue" [7]

Its pathophysiology remains unknown but several hypotheses have been put forward: anatomical variants [17,18]; duplicity of the left renal vein, in which case patients may suffer from both anterior and posterior components; ectopic or horseshoe kidneys; abnormal congenital birth of the spermatic and ovarian arteries may also constrict the renal vein; with cofactors: hypertension of the venous network (vena cava more than portal) may contribute to the increase or appearance of signs [19] the female predominance of the syndrome in adults could be explained by valvular alteration of the gonadal veins following venous hypertensions during pregnancy [19]; only one case of aortic aneurysm below the SMA (superior mesenteric artery) has been revealed because it induced a nutcracker syndrome. In contrast, all causes of extrinsic renal vein compression can induce secondary nutcracker syndromes, including pancreatic cancers, retroperitoneal tumors, and para-aortic adenopathies [18].

"Nutcracker syndrome can be clinically differentiated into 2 subtypes as follows: typical presentation (or renal presentation) and atypical presentation (or urologic presentation). The typical clinical presentation includes hematuria, orthostatic proteinuria with or without flank pain. Atypical presentation includes abdominal pain, varicocele, dyspareunia, dysmenorrhea, fatigue and orthostatic intolerance" [4], Some subjects with marked compression of the RVG are completely asymptomatic [20].

"Positive diagnosis is based on imaging showing a renal cell recoil gradient ≥ 3 mmHg, an angle of less than 45° between the aorta and superior mesenteric artery, left renal vein narrowing, venous collateral circulation, gonadal vein distension, or pelvic congestion" [5]. The multi-bar CT scan, with its multiplanar acquisitions, offers a definite advantage for the establishment of the diagnosis by objectifying different criteria in particular: compression of the left renal artery in the space formed by the superior mesenteric artery and the aorta, distension of the gonadal veins and pelvic congestion. Some authors have therefore attempted to validate these criteria, including Kim et al. who [21] pointed to Bec's sign, which is very evocative on axial sections (compression of the RVG in the aorto-mesenteric fork) with a specificity of 88.9%, angulation between the aorta and the MSA ($<41^\circ$) with a specificity of 55.6%, RVG diameter ratio (hilar-to-aorto-mesenteric ratio) >4.9 with a specificity of 100%, distension of the gonadal veins and pelvic congestion , Despite the great contribution of CT in the diagnosis by its high accuracy of anatomical parameters and its non-invasive character, it presents non-negligible constraints nowadays such as exposure to radiation and risks of allergy [18], "Doppler ultrasonography had a sensitivity of 78% and a specificity of 100%,The most specific finding of nutcracker syndrome was the ratio of hilar

and aorto-mesenteric left renal vein diameter ≥ 4.9 (specificity 100%) and an axial CT image with **the beak sign** [4]. "Phlebography is the gold standard examination to confirm the diagnosis, which shows a pressure gradient in the trapped area". [10,22,25]

According to literature reviews, 1 mmHg corresponds to the normal pressure gradient, Beinart et al. designated that a pressure gradient of 1 mmHg or more indicates RV hypertension [23,24].

"Management of nutcracker syndrome depends on the clinical presentation and severity of hypertension in the left renal vein, ranging from simple monitoring to nephrectomy. Mild and tolerable symptoms can be followed conservatively. However, recurrent gross hematuria with anemia, severe flank pain, impaired renal function and ineffective or worsening conservative treatment, persistent orthostatic proteinuria after 24 months of follow-up may require surgical treatment" [9,10].

"Conservative treatment with observation for at least 2 years without medication is the best option for young patients, 75% of patients with hematuria have complete resolution during this period" [12]. "Surgical techniques used for patients with severe symptoms are nephropexy, intravascular and extravascular stenting, left renal vein or superior mesenteric artery transposition, gonadal bypass, renal autotransplantation and nephrectomy" [4,26].

Conclusion

The nutcracker syndrome is defined as the compression of the left renal vein between the aorta and the angle of the superior mesenteric artery responsible for several clinical manifestations, often unrecognized and which must be evoked in front of acute abdominal pains associated with a micro or macroscopic hematuria, the conduct to hold depends on the severity of the clinical signs going from the simple monitoring to the nephrectomy

Ethical Approval:

As per international standard or university standard written ethical approval has been collected and preserved by the author(s).

Consent

As per international standard or university standard, patients' written consent has been collected and preserved by the author(s).

REFERENCES

- [1] Robert Andrianne, Raymond Limet, David Waltregny, et al., Hematuria caused by nutcracker syndrome: peroperative confirmation of its reality, *Prog. Urol.* 12 (6) (2002) 1323–1326.
- [2] Z. Teyeb, S. Hamzaoui, T. Larbi, M. Abdallah, K. Bouslema, S. M'rad, A rare etiology of chronic abdominal pain: nutcracker syndrome, *Rev. Intern. Med.* 35 (December) (2014) A162–A163.
- [3] Dana Penfold, Saran et Lotfollahzadeh, Nutcracker Syndrome. *StatPearls*, 2020 [Internet].
- [4] K. Gulleroglu, B. Gulleroglu, E. Baskin, Nutcracker syndrome, *World J. Nephrol.* 3 (November (4)) (2014) 277–281.
- [5] K. Ananthan, S. Onida, A.H. Davies, Nutcracker syndrome: an update on current diagnostic criteria and management guidelines, *Eur. J. Vasc. Endovasc. Surg.* 53 (6) (2017) 886–894.
- [6] L. Dunphy, M. Penna, E. Tam, E.-K. Jihene, Left renal vein entrapment syndrome: nutcracker syndrome!, *BMJ Case Rep. CP* 12 (9) (2019), e230877.
- [7] A. Basile, D. Tsetis, G. Calcara, M. Figuera, F. Coppolino, M.T. Patti, et al., Nutcracker syndrome due to left renal vein compression by an aberrant right renal artery, *Am. J. Kidney Dis.* 50 (2) (2007) 326–329.
- [8] Y. He, Z. Wu, S. Chen, L. Tian, D. Li, M. Li, et al., Nutcracker syndrome-how well do we know it? *Urology* 83 (1) (2014) 12–17.
- [9] Long Wang, Lu Yi, Luoyan Yang, et al., Diagnosis and surgical treatment of nutcracker syndrome: a single-center experience, *Urology* 73 (4) (2009) 871–876.
- [10] A. Noorani, S.R. Walsh, D.G. Cooper, et al., Entrapment syndromes, *Eur. J. Vasc. Endovasc. Surg.* 37 (2) (2009) 213–220.
- [11] R.A. Agha, M.R. Borrelli, R. Farwana, K. Koshy, A. Fowler, D.P. Orgill, For the SCARE Group, The SCARE 2018 statement: updating consensus Surgical CASe REport (SCARE) guidelines, *Int. J. Surg.* 60 (2018) 132–136.
- [12] Andrew K. Kurklinsky, Thom W. et rooke, Nutcracker phenomenon and nutcracker syndrome, in: *Mayo Clinic Proceedings*, Elsevier, 2010, pp. 552–559.
- [13] Takezawa K, Nakazawa S, Yoneda S, Tanigawa G, Fujita K, Okumi M et al. Renal autotransplantation for the treatment of nutcracker phenomenon which caused varicocele rupture: a case report. *Hinyokika Kyo*. 2011;57(4): 213-6. PubMed | Google Scholar
- [14] Andrianne R, Limet R, Waltregny D, de Leval J. Hematuria caused by nutcracker syndrome: peroperative confirmation of its presence. *Progres En Urol J Assoc Francaise Urol Soc Francaise Urol*. 2002;12(6): 1323-6. PubMed | Google Scholar

- [15] Orczyk K, Wysiadecki G, Majos A, Stefańczyk L, Topol M, Polgaj M. What each clinical anatomist has to know about left renal vein entrapment syndrome (nutcracker syndrome): a review of the most important findings. *BioMed Res Int.* 2017;2017: 1746570. PubMed| Google Scholar
- [16] Menard MT. Nutcracker syndrome: when should it be treated and how. *Perspect Vasc Surg Endovasc Ther.* 2009;21(2): 117-24. PubMed| Google Scholar
- [17] Panagar AD, Subhash RLP, Suresh BS, Nagaraj DN. Circumaortic left renal vein-a rare case report. *J Clin Diagn Res JCDR.* 2014 Mar;8(3): 111-2. PubMed| Google Scholar
- [18] Kurklinsky AK, Rooke TW. Nutcracker phenomenon and nutcracker syndrome. *Mayo Clin Proc.* 2010 Jun;85(6): 552-9. PubMed| Google Scholar
- [19] Yih NDC, Chyen LH, Cunli Y, Jaywantraj PS, Isip ABC, Anil SA. Renosplenic shunting in the nutcracker phenomenon: a discussion and paradigm shift in options? A novel approach to treating nutcracker syndrome. *Int J Angiol Off Publ Int Coll Angiol Inc.* 2014 Mar;23(1): 71-6. PubMed| Google Scholar
- [20] Berthelot J-M, Douane F, Maugars Y, Frampas E. Le syndrome nutcracker: une cause rare de douleurs lombaires gauches mais aussi de souffrances pelviennes inexpliquées. *Rev Rhum.* 2017;84(2): 111-6. Google Scholar
- [21] Kim KW, Cho JY, Kim SH, Yoon JH, Kim DS, Chung JW et al. Diagnostic value of computed tomographic findings of nutcracker syndrome: correlation with renal venography and renocaval pressure gradients. *Eur J Radiol.* 2011;80(3): 648-54. PubMed| Google Scholar
- [22] Ahmed K, Sampath R, Khan MS. Current trends in the diagnosis and management of renal nutcracker syndrome: a review. *Eur J Vasc Endovasc Surg.* 2006 Apr;31(4): 410-6. PubMed| Google Scholar
- [23] Wei SM, Chen ZD, Zhou M. Intravenous stent placement for treatment of the nutcracker syndrome. *J Urol.* 2003;170(5): 1934-5. PubMed| Google Scholar
- [24] Beinart C, Sniderman KW, Saddekni S, Weiner M, Vaughan Jr ED, Sos TA. Left renal vein hypertension: a cause of occult hematuria. *Radiology.* 1982;145(3): 647-50. PubMed| Google Scholar
- [25] Shin JI, Park JM, Lee JS, Kim MJ. Effect of renal doppler ultrasound on the detection of nutcracker syndrome in children with hematuria. *Eur J Pediatr.* 2007;166(5): 399-404. PubMed| Google Scholar
- [26] Kim JY, Joh JH, Choi HY, Do YS, Shin SW, Kim DI. Transposition of the left renal vein in nutcracker syndrome. *Eur J Vasc Endovasc Surg.* 2006;31(1): 80-2. PubMed| Google Scholar