

Case study

Lupus-like syndrome and cardiac tamponade as initial presentation of a primary cardiac malignant tumor: Report of a case

ABSTRACT

This is the case of a 38-year-old man with a history of two female relatives with Systemic Lupus Erythematosus and personal factors of high cardiovascular risk (gender, stress, smoking, chronic consumption of electronic cigarette). The patient presented tamponade due to pericardial effusion secondary to Lupus-like syndrome that preceded and accompanied at all times an angiosarcoma of the roof and anterior wall of the right atrium. His clinical evolution is described, as well as the surgical and pharmacological treatment in the Cardiovascular Care Unit of a third-level hospital and the possible causes of the poor response to management that led to his death.

Keywords: Cardiac angiosarcoma; Primary cardiac malignant tumor; Lupus-like syndrome; Systemic Lupus Erythematosus; Cardiac tamponade.

1. INTRODUCTION

Primary cardiac tumors are extremely rare, their frequency is reported to be less than 0.1% of all body tumors. Angiosarcomas are the most representative and the characteristic is their aggressive behavior. The paraneoplastic syndrome may be the prelude to the development of a malignant neoplasm, its disappearance may be related to tumor control, and reappearance is generally associated with

recurrence of the neoplasm [1]. The manifestations of the paraneoplastic syndrome develop at a distance from the primary tumor and are mediated by hormones, peptides, compounds with autocrine or paracrine effect, immunoglobulins, and cytotoxic lymphocytes [2]. Lupus-like syndrome has been described in association with different types of neoplasms, including lung, breast and ovarian carcinoma, Hodgkin's disease and hairy cell leukemia. It is characterized by the presence of polyserositis, Raynaud's phenomenon, non-deforming inflammatory arthritis, leukopenia, and positive antinuclear antibodies [3]. In the literature, the association of Lupus-like syndrome with a primary cardiac malignant tumor has not been reported. We present the clinical case of a patient who was complicated by cardiac tamponade, compromised cardiac function, serous effusion and positive diagnostic tests for lupus accompanying a primary cardiac angiosarcoma.

2. CASE REPORT

A 38-year-old man with a family history of systemic lupus erythematosus (SLE) in two members of his family (aunt and maternal cousin) and personal factors of high cardiovascular risk (gender, stress, smoking, and chronic use of electronic cigarettes). His condition began four weeks prior with dyspnea on great exertion that progressed to dyspnea on minimal exertion, orthopnea, and cough with mucus production. A private physician diagnosed her with an upper respiratory tract infection and prescribed a third-generation cephalosporin and nonsteroidal anti-inflammatory agents.

The patient went to the emergency department because his symptoms deteriorated, he showed clinical data compatible with congestive heart failure and

cardiogenic shock. The chest X-ray showed global cardiomegaly with the double cardiac silhouette sign and thickening of the median fissure. **Figure 1**

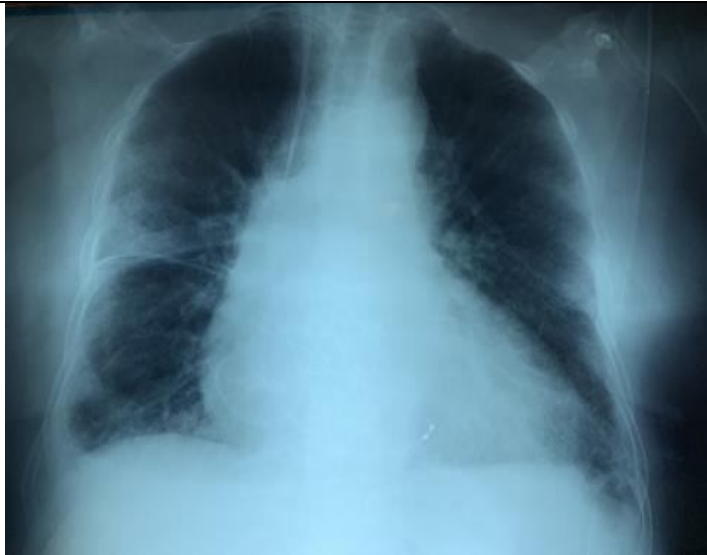

Figure 1. Chest X-ray on admission to the Emergency Department. Global cardiomegaly is evident. The arrow shows thickening of the median fissure.

He was admitted to the Cardiovascular Intensive Care Unit. A structural transthoracic echocardiogram showed pericardial effusion with hemodynamic repercussion. **Figure 2**

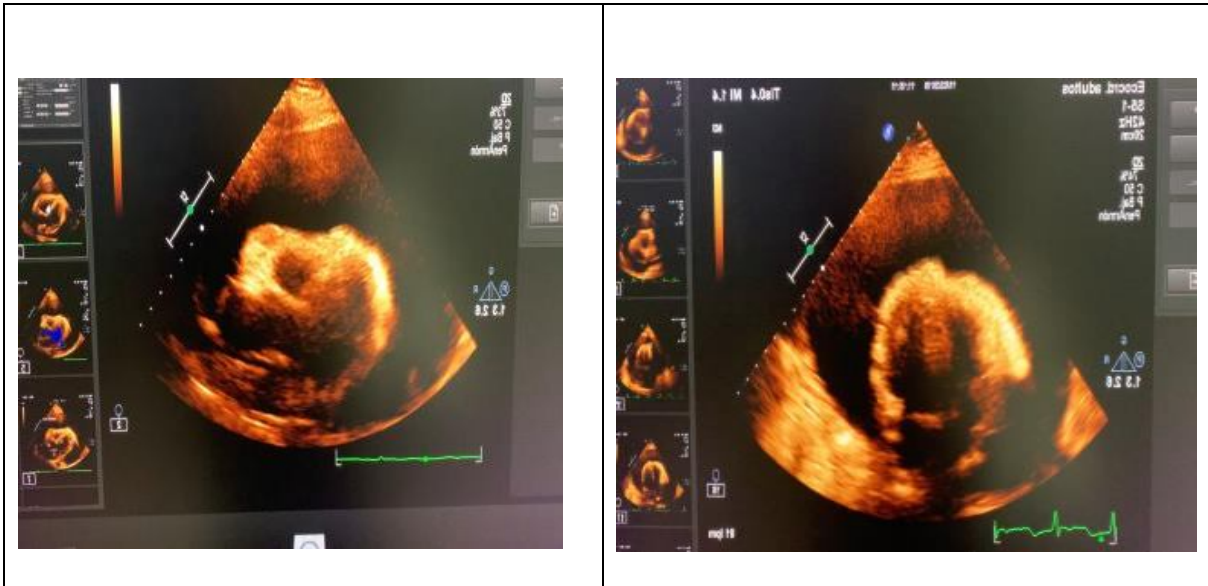


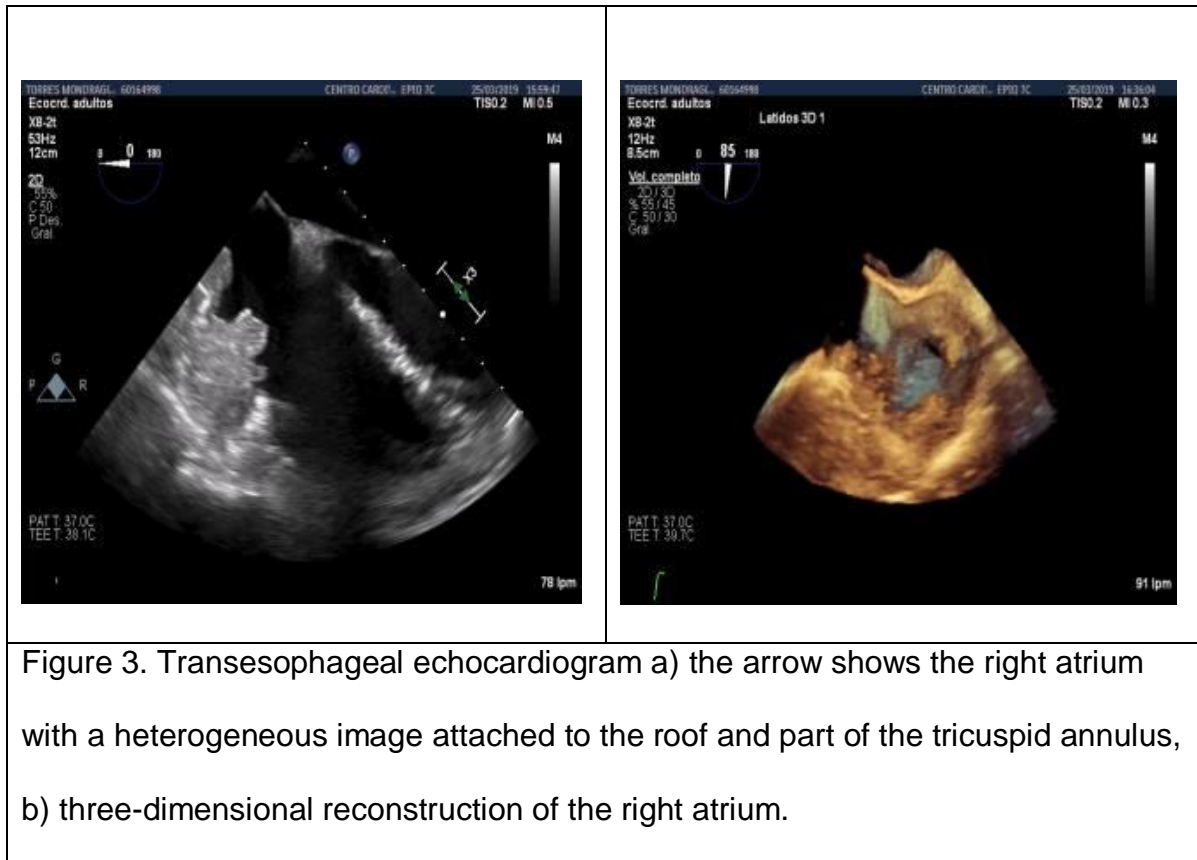
Figure 2. Structural transthoracic echocardiogram a) long axis, the arrows show pericardial effusion and collapse of the right cavities, b) four-chamber window, the arrows show collapse of the atria and right ventricle.

Urgent surgery was performed that consisted of creating a pericardial window and placing a mediastinal and intrapleural tube. 2,600 ml of hematic pericardial fluid reported by the laboratory as lymphocytic exudate were drained. 48 hours after surgery, he presented data of low cardiac output, requiring vasoactive amines (norepinephrine) and an inotropic agent (dobutamine). A new transthoracic echocardiogram showed left and right ventricular systolic dysfunction, left ventricular ejection fraction $<35\%$, and persistent pericardial effusion. 72 hours after surgery, the patient presented coughing fits with hemoptysis, so a bronchoscopy was performed that showed old bleeding with atelectasis of the main bronchus of the right lower lobe and tracheobronchial dyskinesia.

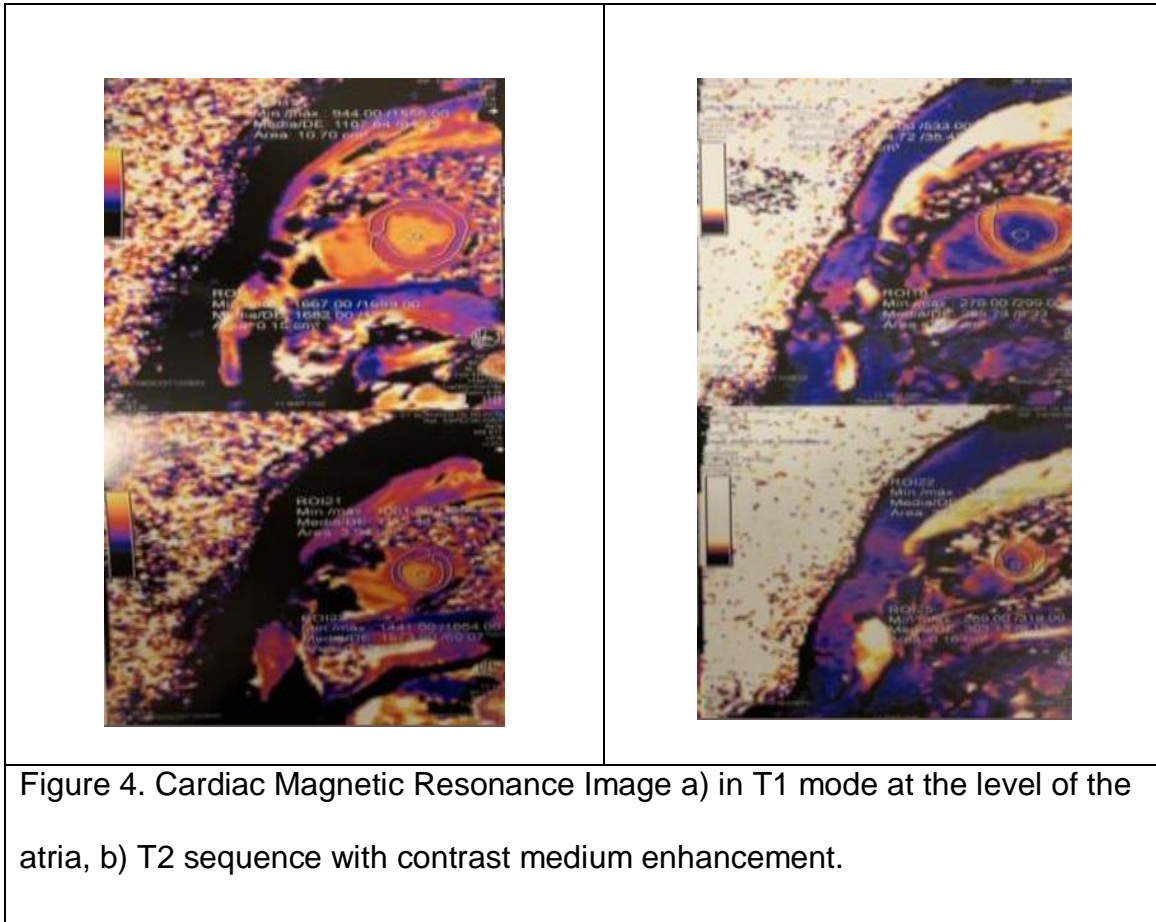
Due to the persistence of the pericardial effusion, several immunological tests were performed with the following results: positive antinuclear antibodies 1:40 with a thick speckled pattern, anti-double-stranded DNA antibodies 33.84 IU/ml, C-reactive protein 7.5 mg/dL, sedimentation rate globular 15 mm/hour and D-dimer 3787.15 ng/ml. The following laboratory parameters were normal: rheumatoid factor 12.5 IU/ml, pANCA antibodies 0.16 IU/ml, cANCA antibodies 0.33 IU/ml, anti-SSA (Ro) antibodies 0.25 IU/ml, anti-La antibodies 0.26 IU/ml, anti-Smith antibodies (Smith) 0.15 IU/ml, brain natriuretic peptide 92.2 pg/ml and troponin I 4.3 pg/ml. Pericardial fluid cultures, respiratory viral panel, and serological viral panel were reported as negative.

Considering the patient's history and age, the onset of his condition with pericardial effusion, and the positive immunological findings, he was classified as a carrier of an autoimmune disease of the Lupus-like syndrome type. Methylprednisolone pulses were prescribed with significant clinical improvement.

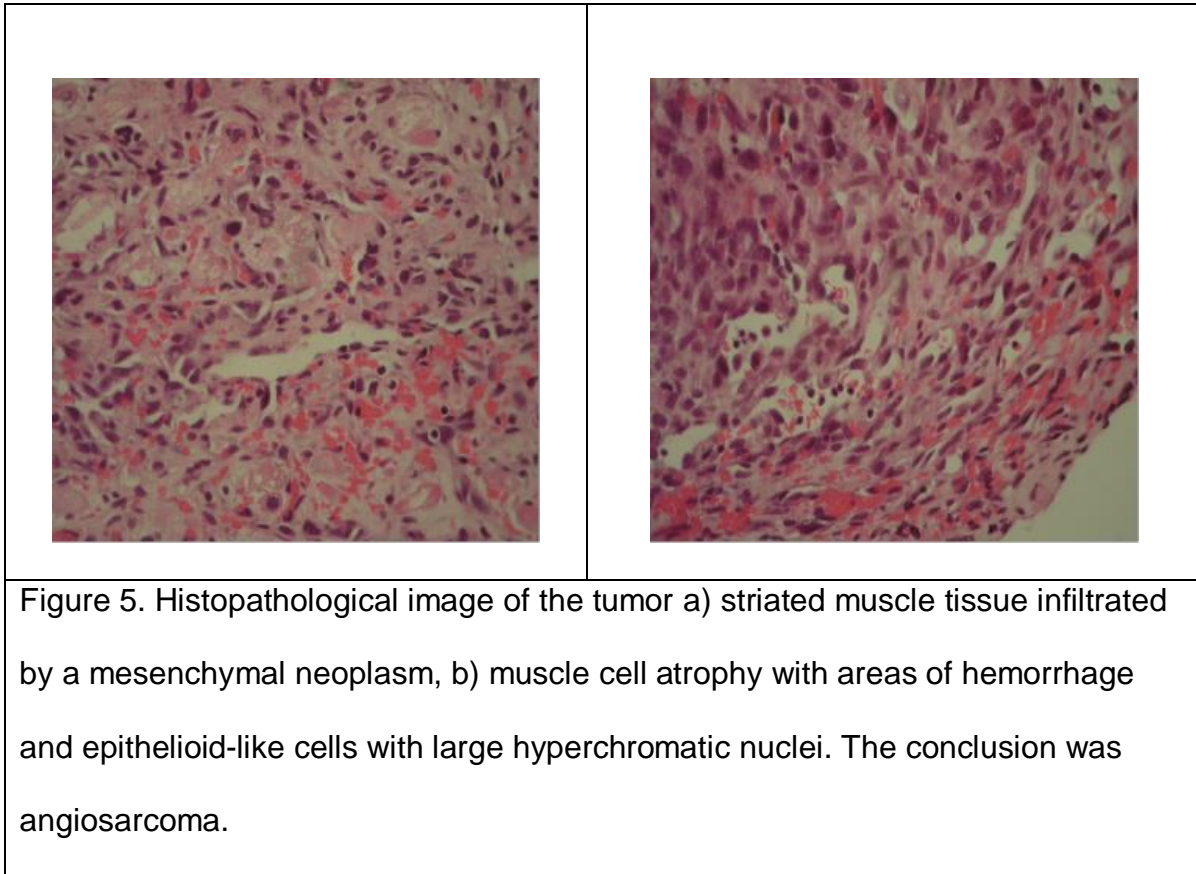
A transesophageal echocardiogram was performed and a fixed mass was observed in the lateral wall and roof of the right atrium with diameters of 50 mm x 20 mm and heterogeneous echogenicity. Left ventricular ejection fraction was calculated to be 50%. **Figure 3**



A cardiac Magnetic Resonance Imaging study confirmed that the right atrium was dilated by a lobulated mass adhered to the roof and the anterior wall, the dimensions of the inferior vena cava were 51 x 22 mm and the pericardium was thickened with fluid from leak. The tumor image showed enhancement to the contrast medium. **Figure 4**



Because it was considered technically accessible, a cardiac catheterization was performed with a biopsy of the tumor, finding the epicardial arteries without significant lesions. The biopsy was reported as striated muscle tissue infiltrated by a malignant neoplasm with a mesenchymal appearance with solid growth and cleft formation, spindle cells with ovoid nuclei, atypical figures with large, round and hyperchromatic nuclei. The immunohistochemical technique reported deposits of CD 34 positive, focal positive CD 31, positive Fli-1, negative Myogenin and negative Desmin. The conclusion was angiosarcoma. **Figure 5**



Positron Emission Tomography (PET) reported a cardiac mass with increased radiotracer uptake and focal metabolic activity in hepatic segment III, but hepatic magnetic resonance imaging ruled out the possibility of metastasis. The case underwent a medical-surgical session, concluding that the patient was a candidate for tumor resection with reconstruction of the right atrium. However, the patient did not accept surgical treatment and was therefore sent home for outpatient follow-up. He was admitted on three subsequent occasions due to the persistence of pericardial effusion and structural compromise of the heart with hemodynamic repercussions. The last hospitalization occurred 12 months after diagnosis, the

patient died due to tumor growth, systemic metastases and multiorgan failure irreversible to all types of treatment.

3. DISCUSSION

This is the case of a man in his fourth decade of life with a primary malignant cardiac tumor, specifically a primary angiosarcoma of the right atrium wall with loco-regional activity due to infiltration of neighboring structures with compatible clinical and serological data. with lupus-like syndrome. The accelerated local growth of the tumor, its presence as an expanding mass, and the effect on the contractile function of the rest of the heart were determining factors in limiting the therapeutic options to just one, tumor resection and right atrial reconstruction. It has been reported that, at the time of diagnosis, primary cardiac sarcomas appear as large and locally invasive tumors, which reduces the survival of most patients to only 6 to 12 months, it can be prolonged if they undergo radical surgery and chemotherapy. Ramlawi et al. [4] studied a series of 95 patients from the Houston Methodist Hospital with primary cardiac malignancies, of which 60% underwent surgical treatment with adjuvant chemotherapy; in the end, only 2 patients lived for 5 years. Oliveira et al. [5] consulted the records of the National Cancer Institute of the United States of America from 1973 to 2011 and identified 551 patients with primary cardiac malignancies, which represented 0.008%. The authors reported survival at one year of 47%, at three years 16%, and at five years 11%. Sarcomas and mesotheliomas turned out to be the most lethal. Simpson et al. [6] studied a series of 34 patients with a malignant primary cardiac tumor treated at the Mayo Clinic over a period of 32 years and found that survival was

significantly higher when complete surgical resection was possible (17 months), but not when surgery was not possible could be done (6 months). In their study, the longest mean survival corresponded to patients without metastases at the time of presentation, but not when metastases were already present (15 vs 5 months). Heart transplantation has had unclear and contradictory results. Its success is limited by several factors intrinsic to neoplasia, such as local and distant tumor recurrence and uncertain response to chemotherapy [7].

In the reported case, the pericardial effusion with tamponade was the announcement of the Lupus-like syndrome that accompanied the angiosarcoma. The collection of fluid in large quantities was a manifestation that was difficult to associate with any specific cause at first. The history of two female relatives with SLE and the negative cultures, but rather the positive immunological tests in the patient's serum were the clues compatible with the rheumatological diagnosis. Although it is true that SLE can be the frequent origin in women, it is not in the case of men. The possibility of a double pathology should be mentioned: the patient has a family history of SLE, so he could have SLE and cardiac angiosarcoma at the same time. The angiosarcoma may not necessarily be producing the Lupus-like syndrome.

Angiosarcomas express endothelial markers including coagulation system factor VIII (von Willebrand factor), CD34, CD31 reticulin, thrombomodulin, and vascular endothelial growth factor (VEGF). The most specific marker for primary cardiac angiosarcoma is CD31 [8]. In patients with these tumors, upregulation of vascular receptor tyrosine kinases such as TIE1, KDR, TEK and FLT has also been documented, and overexpression of HIF 1 alpha and HIF 2 beta also promote

VEGF synthesis. Immunohistochemical studies are important to confirm the diagnosis, Von Willebrand factor, Agglutinin 1 and CD31 are the markers that characterize a poorly differentiated tumor [9,10]. However, progressive dedifferentiation of the tumor can lead to a loss of these markers. Some epithelioid angiosarcomas may express cytokeratins, leading to confusion with differentiated carcinomas. VEGF-A is the best studied cytokine, it is known that it is expressed more in angiosarcomas than in other tumors. VEGFR-2 expression correlates with worse prognosis [11,12].

The association of SLE and the origin of a neoplasm has been reported relatively frequently in the literature [13,14], but not the development of Lupus-like syndrome and a primary malignant cardiac tumor, as occurred in the case at hand.

Angiosarcomas are malignant vascular tumors of the endothelium, cardiac involvement is extremely rare, and antibody formation can mimic SLE.

The patient presented pericardial involvement from beginning to end, manifested as tamponade and persistent effusion despite undergoing surgery and having received high-dose immunosuppressive therapy as if it were a case with SLE activity. The poor response to treatment could have been conditioned by the growing tumor that was not resected because the patient did not authorize it and by the persistent immunological activity, a condition already identified in men with SLE. Despite the loco-regional aggressiveness of the angiosarcoma, the negative for its surgical resection, the adverse effect of the Lupus-like syndrome and the acute chronic deterioration evident with each hospitalization, the patient's survival lasted 12 months. The comprehensive study of the patient to establish the diagnosis and management, as well as the preparation of the manuscript with

complementary studies, are the main strengths of the case report. The main limitation is that it is an individual case.

4. CONCLUSIONS

The aggressiveness of the primary cardiac angiosarcoma and the Lupus-like syndrome as its herald and companion made the possibility of success in the medical and surgical management of the patient doubly difficult.

CONSENT AND ETHICAL CONSIDERATIONS

The authors declare that 'written informed consent was obtained from the patient (or other approved parties) for publication of this case report and accompanying images. A copy of the written consent is available for review by the Editorial office/Chief Editor/Editorial Board members of this journal. Approval was obtained from the Ethics Committee of the host hospital.

COMPETING INTERESTS

None.

ACKNOWLEDGEMENTS

The authors thank Isabel Alvarado-Cabrero MD Pathologist Oncologist of the Department of Pathology Hospital Star Médica Centro for their collaboration in this clinical case.

REFERENCES

1. Racanelli V, Prete M, Minoia C, Favoino E, Perosa F. Rheumatic disorders as paraneoplastic syndromes. *Autoimmun Rev.* 2008;7:352-58.
https://www.ufrgs.br/ligadeoncologia/index_arquivos/review_paraneoplastic_syndromes.pdf
2. Minna JD, Bunn PA Jr. Paraneoplastic syndromes. In: DeVita VT Jr, Lawrence TS, Rosenberg SA, editors. *Cancer: principles and practice of Oncology.* 11th edition. Philadelphia: Lippincott Williams & Wilkins; 2011.
3. Freundlich B, Makover D, Maul GG. A novel antinuclear antibody associated with a lupus-like paraneoplastic syndrome. *Ann Intern Med.* 1988;109(4):295-97.
<https://www.acpjournals.org/doi/pdf/10.7326/0003-4819-109-4-295>
4. Ramlawi B, Leja MJ, Abu Saleh WK, Al Jabbari O, Benjamin R, Ravi V, et al. Surgical treatment of primary cardiac sarcomas: review of a single-institution experience. *Ann Thorac Surg.* 2016;101(2):698-702.
<https://www.annalsthoracicsurgery.org/action/showPdf?pii=S0003-4975%2815%2901347-8>
5. Oliveira GH, Al-Kindi SG, Hoimes C, Park SJ. Characteristics and survival of malignant cardiac tumors: a 40-year analysis of >500 patients. *Circulation.* 2015;132(25):2395-2402.
<https://www.ahajournals.org/doi/epub/10.1161/CIRCULATIONAHA.115.016418>
6. Simpson L, Kumar SK, Okuno SH, Schaff HV, Porrata LF, Buckner JC, et al. Malignant primary cardiac tumors: review of a single institution experience. *Cancer.* 2008;112:2440-46.
<https://acsjournals.onlinelibrary.wiley.com/doi/epdf/10.1002/cncr.23459>

7. Grandmougin D, Fayad G, Decoene C, Pol A, Warembourg H. Total orthotopic heart transplantation for primary cardiac rhabdomyosarcoma: factors influencing long-term survival. *Ann Thorac Surg.* 2001;71:1438-41.

[https://www.annalsthoracicsurgery.org/article/S0003-4975\(01\)02480-8/pdf](https://www.annalsthoracicsurgery.org/article/S0003-4975(01)02480-8/pdf)

8. Pernick N. Angiosarcoma. *PathologyOutlines.com*

Website <https://www.pathologyoutlines.com/topic/hearttumorangiosarcoma.html>

9. Omiyale AO, Carton J. Clinical and pathologic features of primary angiosarcoma of the kidney. *Curr Urol Rep.* 2018 2018 Jan 31;19(2):4.

<https://pubmed.ncbi.nlm.nih.gov/29383452/>

10. Ohsawa M, Naka N , Tomita Y, Kawamori D, Kanno H , Oazasa K. Use of immunohistochemical procedures in diagnosing angiosarcoma. Evaluation of 98 cases. *Cancer.* 1995;75(12):2867-74

[https://acsjournals.onlinelibrary.wiley.com/doi/epdf/10.1002/1097-](https://acsjournals.onlinelibrary.wiley.com/doi/epdf/10.1002/1097-0142%2819950615%2975%3A12%3C2867%3A%3AAID-CNCR2820751212%3E3.0.CO%3B2-8)

[0142%2819950615%2975%3A12%3C2867%3A%3AAID-](https://acsjournals.onlinelibrary.wiley.com/doi/epdf/10.1002/1097-0142%2819950615%2975%3A12%3C2867%3A%3AAID-CNCR2820751212%3E3.0.CO%3B2-8)

[CNCR2820751212%3E3.0.CO%3B2-8](https://acsjournals.onlinelibrary.wiley.com/doi/epdf/10.1002/1097-0142%2819950615%2975%3A12%3C2867%3A%3AAID-CNCR2820751212%3E3.0.CO%3B2-8)

11. Young RJ, Brown NJ, Reed MW, Hughes D, Woll PJ. Angiosarcoma. *Lancet Oncol.* 2010;11(10):983-91.

<https://pubmed.ncbi.nlm.nih.gov/20537949/>

12. Dim D, Ravi V, Tan J, Hicks D, Wong M. The actin-bundling motility protein fascin and vascular endothelial growth factor (VEGF) are universally over-expressed in human angiosarcoma. *J Clin Oncol.* 2007;25(18):suppl. 10068

https://ascopubs.org/doi/abs/10.1200/jco.2007.25.18_suppl.10068

13. Song L, Wang Y, Zhang J, Song N, Xu X, Lu Y. The risk of cancer development in systemic lupus erythematosus (SLE) patients: a systematic review and meta-analysis. *Arthritis Res Ther.* 2018;20:270.

<https://arthritis-research.biomedcentral.com/track/pdf/10.1186/s13075-018-1760-3.pdf>

14. Jan JY, Kim H, Jung SY, Jan EJ, Cho SK, Sung YK. Increased risk of malignancy in patients with systemic lupus erythematosus: population based cohort study in Korea. *Arthritis Res Ther.* 2021;23:270.

<https://arthritis-research.biomedcentral.com/track/pdf/10.1186/s13075-021-02648-y.pdf>