

Case study

PENILE FRACTURE WITH BILATERAL CORPORA CAVERNOSA TEAR AND NEAR-COMplete URETHRAL INJURY FOLLOWING A MOTORBIKE ACCIDENT: A CASE REPORT.

Abstract

Penile fracture is a blunt injury to an erected penis with a resultant rupture of the tunica albuginea of the corpus cavernosum. It is an uncommon injury most commonly sustained during sexual intercourse. Concomitant urethral injury is rare in penile fracture. Reported herein is the case of a 31-year-old man who was referred from a peripheral hospital with penile swelling, bleeding per urethra, and a urethra catheter in situ following a motorbike accident in which he was a passenger sliding his erect penis against the back of the rider. Surgical exploration was performed and a bilateral rupture of the corpora cavernosa with a near-complete urethral tear was seen. The injuries were repaired primarily. In follow-up, the patient reported satisfactory erectile function. This case highlights a new mechanism of penile fracture injury and the importance of surgical repair irrespective of the timing or severity of the penile fracture.

Keywords: penile fracture, corpora cavernosa tear, urethral injury, motorbike accident.

Introduction

“Penile fracture is caused by blunt injury to the erected penis leading to rupture of the tunica albuginea of the corpus cavernosum. Penile fracture results from the rupture of the corporal cavernosal, due to abrupt bending or pressure on the penis during an erection”.^{1,2} “This is

uncommon, but emergent urological condition. The most frequent aetiology of penile fracture is hitting the erected penis against the symphysis pubis or the perineum during vigorous sexual intercourse”.^{1,2} “Penile fracture can be associated with urethral injury in 6-9%”^{1,3} “In patients with bilateral cavernosal rupture, urethral injuries should be suspected”.^{4,5}

Reported herein is a rare case of near-complete urethral rupture with a tear of both corpora cavernosa following a motor-bike accident in which the passenger hit his erect penis against the back of the rider when the rider suddenly applied the brake in an attempt to avoid a pothole.

Case presentation

A 31-year-old unmarried male patient presented to our urology unit with a history of penile pain, swelling, and bleeding per urethral of 14 days duration. The incident happened when he slid his erect penis against the back of the bike rider who suddenly applied the brake in an attempt to avoid a pothole. He suddenly developed severe pain in the penis followed by swelling of the penis, sudden detumescence, and bleeding from the urethra associated. The patient was unable to void following the injury. On account of the above, he presented to a peripheral hospital where a diagnosis of urethral injury was made. He was subsequently catheterized and given antibiotics and analgesics. He was referred after fourteen days following the persistence of symptoms. Physical examination showed a markedly swollen, deformed penis with a deviation of the distal shaft of the penis toward the dorsal surface with a size 16 Foley catheter in situ. Palpable hematoma with tenderness was noted over the ventral aspect of the distal shaft of the penis. “Rolling sign” was noted bilaterally, palpated at the sites of tunica albuginea tear about 5 cm from the base of the penis, and was moderately tender on examination. The scrotum and the testes were essentially normal. The abdominal examination was not remarkable.

Surgical exploration was done through a subcoronal circumferential incision after administration of general anaesthesia and application of a tourniquet at the base of the penis. The penis was degloved, and evacuation of hematoma was carried out. There were two large defects on the ventral aspect of both corpora cavernosa (Figure 1) with a near-complete rupture of the urethra around the mid-penile shaft (Figure 2).

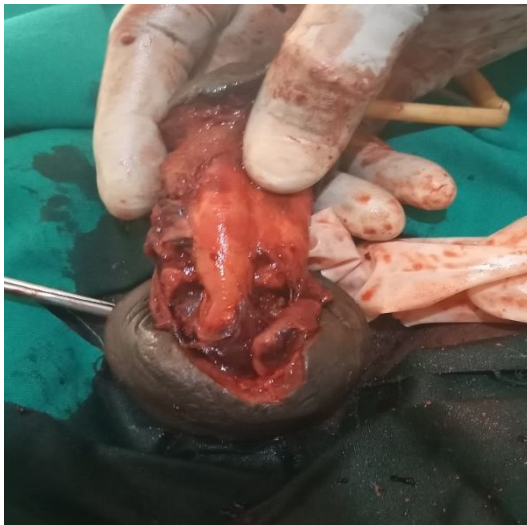

Figure 1: Penile fracture with bilateral rupture of the corpora cavernosa.

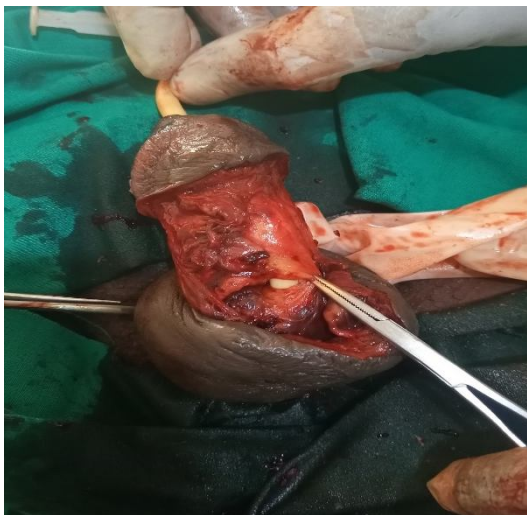


Figure 2: Rupture of both corpora cavernosa with urethral injury in the patient.

Closure of the corpora cavernosa on both sides was done by use of a 3/0 vicryl suture.

Subsequently, end to end, mucosa to mucosa, and tension-free urethral anastomosis over the 16 F urethral catheter were done using a 4/0 vicryl suture. Some reinforcement suture in the corpus spongiosum was done. The wound was subsequently closed in layers and tourniquet removed (Figure 3).

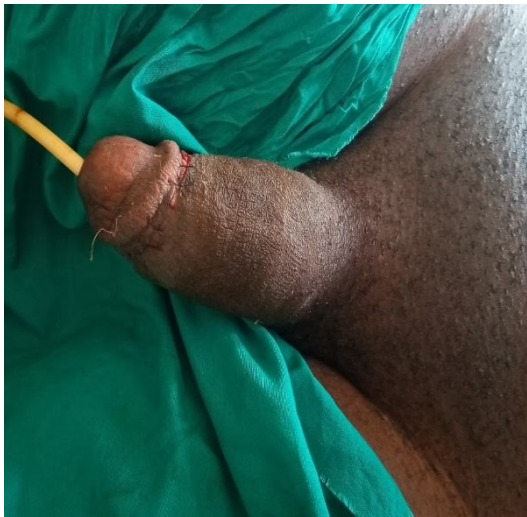

Figure 3: Immediate post operative image.

Discussion

“The increased risk of penile rupture during erection is partly due to the stretching and thinning of the tunica albuginea when the penis is erect. Studies have shown that the tunica albuginea, when the penis is in a flaccid state, is about 2.5 mm thick and as thin as 0.25 mm when the penis is erect state”.⁶ This tunica albuginea thinning makes the penis more prone to traumatic injury when erect.

The leading cause of penile fracture in the West African sub-region is sexual intercourse followed by forceful manipulation of the erect penis.^{2,4} During sexual intercourse, the erect penis slips out of the vagina, forcefully hits the pubic symphysis or perineum, buckles, and the already stretched-out tunica albuginea ruptures.⁶ The patient in this case report had a rare atypical aetiology as the fracture was sustained from hitting his erect penis against the back of the motorbike rider when the rider suddenly applied the brake in an attempt to avoid a pothole.

“The corpora cavernosa laceration is often unilateral, though bilateral rupture accounts for 1-10% of cases”.^{3,4,7} In a series of 251 patients with penile fractures reported by Zargooshi, 64.9% had right-sided tears while 34.3% had left corporal tears with bilateral tunica albuginea reported only in only two (0.8%) patients.⁷ This index patient had bilateral tunica albuginea rupture.

“Concomitant urethral injuries in patients with penile fracture is rare, with reported frequencies in the 6% to 9% range”.^{1,3} “Bleeding per urethra, inability to micturate, or hematuria are reported clinical features of associated urethral injury”.^{4,7} However, “urethral bleeding without urethral injury has been noted after a penile fracture”.⁴ “Patients with bilateral corporeal rupture should compulsorily be assessed for urethral injury”.⁸

The diagnosis of penile fracture is often clinical. However, imaging investigations such as cavernosography, penile Doppler scan, and retrograde urethrography should be done for patients with indeterminate clinical features or for those with complications such as urethral injuries.^{4,8}

“Some surgeons prefer early surgery and direct inspection of the urethra due to the false negative results that may be associated with retrograde urethrography”.⁹ “This is the practice in our urology unit. The fracture site is close to the urethral rupture and both can be diagnosed and repaired easily intraoperatively”.⁴

“Regarding the corporal injury, studies have shown that immediate surgical repair is vital and leads to better outcomes and fewer complications when compared to non-operative management”.¹ In our case, the patient had surgery immediately after his arrival at our clinic but about 14 days after the penile fracture. Kozacioglu¹⁰ and colleagues published a series of 43 patients divided into 3 groups according to the time interval before penile exploration. As a result, there were no significant differences between these groups. No complication of penile deformity or erectile dysfunction was noted in the long term due to a delay in surgical intervention. In this case study, a delay in presentation of 14 days did not cause any curvature or erectile dysfunction despite the severity of the penile fracture and urethral involvement.

Conclusion

Penile fracture is an uncommon urological emergency, particularly those with urethral involvement. Atypical mechanisms of injury often result in delayed diagnosis. Concomitant urethral injury should be suspected in the presence of suggestive clinical features like urethral bleeding, hematuria or urinary retention, and in penile fractures with bilateral cavernosal rupture. Surgical repair is the gold standard irrespective of the duration and severity of injury.

Ethical Approval:

As per international standard or university standard written ethical approval has been collected and preserved by the author(s).

Consent

As per international standard or university standard, patients’ written consent has been collected and preserved by the author(s).

References

- ¹ Bennani S, El-Mrini M, Meziane F, Benjelloun S. Traumatic rupture of the corpus cavernosum: 25 case reports and literature review [in French] *Ann Urol (Paris)* 1992;26:355-9.
- ² Ogbetere FE, Ootobo OF. Penile fracture in Southern Nigeria: A 10-year review in two tertiary referral centers. *Niger J Med* 2021;30:134-8
- ³ Amer T, Wilson R, Chlosta P, AlBuheissi S, Qazi H, Fraser M, Aboumarzouk OM. Penile Fracture: A Meta-Analysis. *Urol Int* 2016;96(3):315-29.
- ⁴ Eke N. Fracture of the penis. *Br J Surg* 2002;89(5):555-65.
- ⁵ Fergany AF, Angermeier KW, Montague DK. Review of Cleveland clinic experience with penile fracture. *Urology* 1999;54:352-5.
- ⁶ Bitsch M, Kromann-Andersen B, Schou J, et al. The elasticity and the tensile strength of tunica albuginea of the corpora cavernosa. *J Urol* 1990;143:642-5.
- ⁷ Zargooshi J. Sexual function and tunica albuginea wound healing following penile fracture: An 18-year follow-up study of 352 patients from Kermanshah. *Iran J Sex Med* 2009;6:1141-50.
- ⁸ Tsang T, Demby AM. Penile fracture with urethral injury. *J Urol* 1992;147:466.
- ⁹ Mydlo JH, Hayyeri M, Macchia RJ. Urethrography and cavernosography imaging in a small series of penile fractures: A comparison with surgical findings. *Urology* 1998;51:616-9.
- ¹⁰ Kozacioglu Z, Degirmenci T, Arslan M, et al. Long-term significance of the number of hours until surgical repair of penile fractures. *Urol Int* 2011;87:75-9,