

Corneal Endothelial Changes in Patients with Diabetes Mellitus: A Specular Microscopy Study

ABSTRACT

Purpose: to evaluate the changes in corneal endothelium in patients with diabetes mellitus using specular microscopy.

Setting: The study was performed in the outpatient clinic of Tanta ophthalmology Hospital.

Design: Cross-sectional study.

Patients and methods: Corneal endothelium (CE) examination using noncontact specular microscopy that includes the following parameters: Coefficient of variation (CV), Endothelial cell density (ECD), Central corneal thickness (CCT), Hexagonality (HEX) and Cell size (Minimum, Maximum and Average).

Results: The study comprised 40 eyes of healthy individuals without diabetes, 40 eyes of patients with type II diabetes for less than 10 years, and 40 eyes of patients with type 2 diabetes for more than 10 years. This study showed no statistically significant differences in endothelial cell density (ECD) between diabetic patients and non-diabetics. In this study, we found a statistically significant increase in the mean Coefficient of variation (CV) from 34.73% in group A (non-diabetics) to 37.80% in group B (diabetics for less than 10 years) and increased to 40.63% in group C (diabetics for more than 10 years). According to the hexagonality (HEX%), our study showed a statistically significant decrease of mean HEX% from 54.70% in group A(non-diabetics) to 44.35% in group B (diabetics for less than 10 years) and decreased to 42.0% in group C (diabetics for more than 10 years). In our study, there was a statistically significant reduction in the mean central corneal thickness (CCT) from 518.18 μm in group A to 500.70 μm in group B and decreased to 491.93 μm in group C. The differences between groups A and B, and A and C were statistically significant. However, statistically non significant difference was noticed between groups B and C. Regarding the correlation between HBA1C and the specular microscopy parameters, our study showed that there was a significant negative correlation between HBA1C and HEX%, And between HBA1C and CCT. However, there was a positive relation between HBA1C and CV. **Conclusion:** Diabetes mellitus (DM) has significant impacts on the CE. Compared to non-diabetic individuals, diabetic patients' CE had a higher CV% and a lower HEX% and central corneal thickness. A strong negative correlation was found between HBA1C and HEX%, with a substantial positive correlation between HBA1C and CV%.

Keywords: Diabetes mellitus, Corneal Endothelium, Specular microscope.

1. INTRODUCTION:

“Diabetes mellitus (DM) is a class of metabolic disorders defined by hyperglycemia caused by abnormalities in insulin production and/or higher insulin cellular resistance” [1]. It is considered a chronic condition with long term macro- and microvascular complications, such as diabetic neuropathy, nephropathy and retinopathy [2]. DM damages all corneal layers. Patients with DM are susceptible to punctate epithelial keratopathy, corneal endothelium (CE) damage, persistent epithelial defects, recurrent corneal erosions, superficial keratitis, ulcers and reduced corneal sensitivity [3].

The endothelium of the cornea maintains the delicate equilibrium of stromal hydration to guarantee appropriate nourishment without compromising clarity of the cornea [4]. The endothelium may be viewed via specular reflection at the slit lamp. Although this approach is necessary for evaluating the cornea, the slit lamp's restricted magnification typically makes it difficult to detect small endothelial alterations [5].

Specular microscopy is a non-invasive imaging procedure that creates high magnification pictures of the endothelium of the cornea. Using automated software, these pictures may be evaluated quantitatively and qualitatively to aid in the diagnosis of pathology, the proper monitoring of endothelial disease, and surgical management [6]. The specular microscope provides several indicators that help in the diagnosis and treatment of corneal disorders such as cell density (CD; The number of endothelial cells per mm^2), coefficient of variation (CV; the standard deviation in cell area/average cell area), Hexagonality (HEX%; the percent of hexagonal cells), central corneal thickness (CCT), and average cell size in μm^2 .

This study was carried out to evaluate the corneal endothelial cell changes in patients with diabetes mellitus of different durations.

2. SUBJECTS AND METHODS:

This cross-sectional and observational study was carried out on 60 patients attending the Ophthalmology outpatient clinic at Tanta Ophthalmology Hospital. The duration of the study extended for 12 months (from December 2020 to November 2021). The study adhered to the tenets of the Declaration of Helsinki and all patients signed a written informed consent to participate in the study and for publication of data before enrollment in the study after approval from the ethical committee, Faculty of Medicine, Tanta University, and its later amendments or comparable ethical standards (34242/11/20). No is 34242 / Date is November 2020.

2.1. Participants in this study were equally divided into three groups:

Group A: - Normal individuals with no DM.

Group B: - Patients with DM of less than 10 years duration.

Group C: - Patients with DM of more than 10 years duration.

2.2. Patient's inclusion in the study was accomplished according to the following criteria:

1. Patients with type II DM.
2. Patients above 40 years of age.

Patients with corneal scarring, corneal pathologies such as keratoconus and corneal endothelial dystrophies, glaucoma patients, history of contact lens wear, previous eye surgeries, previous ocular trauma, and patients with chronic intraocular inflammations were excluded from the study.

All participants were subjected to full history taking including the duration of diabetes mellitus and the medication used for glycemic control. Full ophthalmic evaluation including corrected distance visual acuity (CDVA), uncorrected distance visual acuity (UDVA), slitlamp biomicroscopy, manifest and cycloplegic refraction, fundus examination, and iOP measurement with applanation tonometry.

Specular microscopy was performed using TOPCON SP-1P specular microscope (Topcon Cooperation, Japan).

The parameters included in the study were coefficient of variation (CV), endothelial cell density (ECD), central corneal thickness (CCT), hexagonality (HEX), and average cell size.

2.1. Statistical analysis:

With the help of the IBM SPSS software programme, version 20.0, statistical analysis was carried out (Armonk, NY: IBM Corp). Qualitative data were described using number and percent. The normality of the distribution was examined using the Shapiro-Wilk test. The range (minimum and maximum), mean, standard deviation, median, and interquartile range were used to characterise quantitative data (IQR). The significance of the results was assessed at the 5% level.

The used tests were **chi square**: when dealing with categorical variables, it is necessary to compare groups. **Correction of the Monte Carlo simulation**: when more than 20% of cells have an anticipated count of less than 5, chi-square corrections are applied. **F-test : (ANOVA)**: Post Hoc test (Tukey) for pairwise comparisons of normally distributed quantitative variables for comparisons between more than two groups. **Mann Whitney's**: compare two groups of people with improperly distributed quantitative variables. **Kruskal Wallis test**: post Hoc (Dunn's multiple comparisons test) can be used for pairwise comparisons of quantitative variables with abnormally distributed distribution and to compare data from more than two study groups. **Pearson coefficient**: to establish a statistical relationship between two normally distributed quantitative variables

3. RESULTS

In group A, included 10 females and 10 males. While group B included 8 males and 12 females, and group C included 10 males and 10 females. The mean age was 57.0 ± 10.99 years (ranging from 42 to 71 years), 57.10 ± 7.16 years (ranging from 41 to 68 years), and 56.90 ± 8.28 years (ranging from 42 to 72 years) in groups A, B, and C, respectively.

The mean duration of DM was 5.30 ± 2.05 years (1 to 8 years range), and 15.20 ± 4.10 years ranging from (10 to 25 years) in groups B and C respectively. A statistically significant distinction existed between the two research groups ($P < 0.001$).

The mean HbA1c level was $5.0 \pm 0.38\%$ (ranging from 4.20 to 5.60%), $6.69 \pm 1.0\%$ (ranging from 5.50 to 8.50%), $8.04 \pm 1.63\%$ (ranging from 5.40 to 11.40%) in groups A, B, and C respectively. There was statistically significant difference between groups A and B ($p < 0.001$), groups A and C ($p < 0.001$) and between groups B and C ($p < 0.001$).

3.1. Specular microscopy results: (Table 1)

The mean ECD was 2713.15 ± 374.50 cells/mm² (ranging from 2009 to 328 cells/mm²), 2752.53 ± 374.0 cells/mm² (ranging from 2014 to 3996 cells/mm²), and 2811.35 ± 250.61 cells/mm² (ranging from 2179 to 3306 cells/mm²) in groups A, B, and C respectively. No statistically significant difference were found among the three groups ($p = 0.428$).

The mean CV was $34.73 \pm 2.67\%$ (ranging from 30 to 41%), $37.80 \pm 4.29\%$ (ranging from 30 to 45%), and $40.63 \pm 2.71\%$ (ranging from 36 to 46%) in groups A, B, and C respectively. There were statistically significant differences between groups A and B ($p < 0.001$), between groups A and C ($p < 0.001$), and between groups B and C ($p = 0.001$).

The mean HEX was $54.70 \pm 4.95\%$ (ranging from 46 to 62%), $44.35 \pm 3.74\%$ (ranging from 38 to 51%), and $42.0 \pm 3.84\%$ (ranging from 36 to 51%) in groups A, B, and C respectively. There were statistically significant differences between groups A and B ($p < 0.001$), between groups A and C ($p < 0.001$), and between groups B and C ($p = 0.037$).

The mean CCT was 518.18 ± 23.58 μm (ranging from 454 to 551 μm), 500.70 ± 21.82 μm (ranging from 464 to 534 μm), and 491.93 ± 27.52 μm (ranging from 427 to 533 μm) in groups A, B, and C respectively. The differences between groups A and B was statistically significant ($p = 0.005$), as well as between groups A and C ($p < 0.001$). There was no statistically significant difference between groups B and group C ($p = 0.247$).

The mean average cell size was 317.82 ± 28.37 μm^2 (ranging from 274 to 390 μm^2), 343.18 ± 38.35 (ranging from 276 to 413 μm^2), and 345.05 ± 37.48 μm^2 (ranging from 278 to 420 μm^2) in groups A, B,

and C respectively. The differences between groups A and B were statistically significant ($p=0.004$), and between groups A and C ($p=0.002$). No statistically significant differences found between groups B and group C ($p=0.969$).

3.2. Correlations between HbA1c and Specular microscopy results: (Table 2)

There was a significant negative correlation between HbA1c and CCT ($p<0.001$).

There was no significant correlation between HbA1c and ECD ($p: 0.073$).

There was a significant negative correlation between HbA1c and HEX ($p: <0.001$).

There was a significant positive correlation between HbA1c and CV ($p<0.001$).

Table (1): Comparison between the three studied groups according to different parameters

	Group A (n = 20)	Group B (n = 20)	Group C (n = 20)	Test of sig.	p
Duration					
Mean \pm SD.	–	5.30 \pm 2.05	15.20 \pm 4.10	U=0.0*	<0.001*
Median (Min. – Max.)	–	6(1 – 8)	14.5(10 – 25)		
HbA1c					
Mean \pm SD.	5.0 \pm 0.38	6.69 \pm 1.0	8.04 \pm 1.63	F=36.751*	<0.001*
Median (Min. – Max.)	5(4.2 – 5.6)	6.3(5.5 – 8.5)	7.9(5.4 – 11.4)		
Sig.bet.Grps	p1<0.001*,p2<0.001*p3=0.001*				
ECD					
Mean \pm SD.	2713.15 \pm 374.50	2752.53 \pm 374.0	2811.35 \pm 250.61	F=0.855	0.428
Median (Min. – Max.)	2738(2426 – 3007)	2731(2014 – 3996)	2821.5(2179 – 3306)		
CV					
Mean \pm SD.	34.73 \pm 2.67	37.80 \pm 4.29	40.63 \pm 2.71	F=31.794*	<0.001*
Median (Min. – Max.)	34(30 – 41)	38(30 – 45)	40(36 – 46)		
Sig.bet.Grps	p1<0.001*,p2<0.001*,p3=0.001*				
HEX					
Mean \pm SD.	54.70 \pm 4.95	44.35 \pm 3.74	42.0 \pm 3.84	F=102.849*	<0.001*
Median (Min. – Max.)	53.5(46 – 62)	44(38 – 51)	43(36 – 51)		
Sig.bet.Grps	p1<0.001*,p2<0.001*,p3=0.037*				
CCT					
Mean \pm SD.	518.18 \pm 23.58	500.70 \pm 21.82	491.93 \pm 27.52	F=11.974*	<0.001*
Median (Min. – Max.)	516.5(454 – 551)	500(464 – 534)	493.5(427 – 27.5)		
Sig.bet.Grps	p1=0.005*,p2<0.001*,p3=0.247				
Average cell size					
Mean \pm SD.	317.82 \pm 28.37	343.18 \pm 38.35	345.05 \pm 37.48	F=7.539*	0.001*
Median (Min. – Max.)	316(274 – 390)	340(276 – 413)	339(278 – 420)		
Sig.bet.Grps	p1=0.004*,p2=0.002*,p3=0.969				

SD: Standard deviation|QR: Inter quartile range

F: F for ANOVA test, Pairwise comparison bet. each 2 groups was done using Post Hoc Test (Tukey)

p: p value for comparing between the studied groups

p1: p value for comparing between group A and B

p2: p value for comparing between group A and C

p3: p value for comparing between group B and C

*: Statistically significant at $p \leq 0.05$

Table (2): Correlation between HbA1c and Specular microscopy results in total sample (n= 120)

	HbA1c	
	r	P
ECD	-0.073	0.427
CV	0.359	<0.001*
HEX	-0.682	<0.001*
CCT	-0.401	<0.001*

r: Pearson coefficient

*: Statistically significant at $p \leq 0.05$

4.CASE PRESENTATION:

Case1:

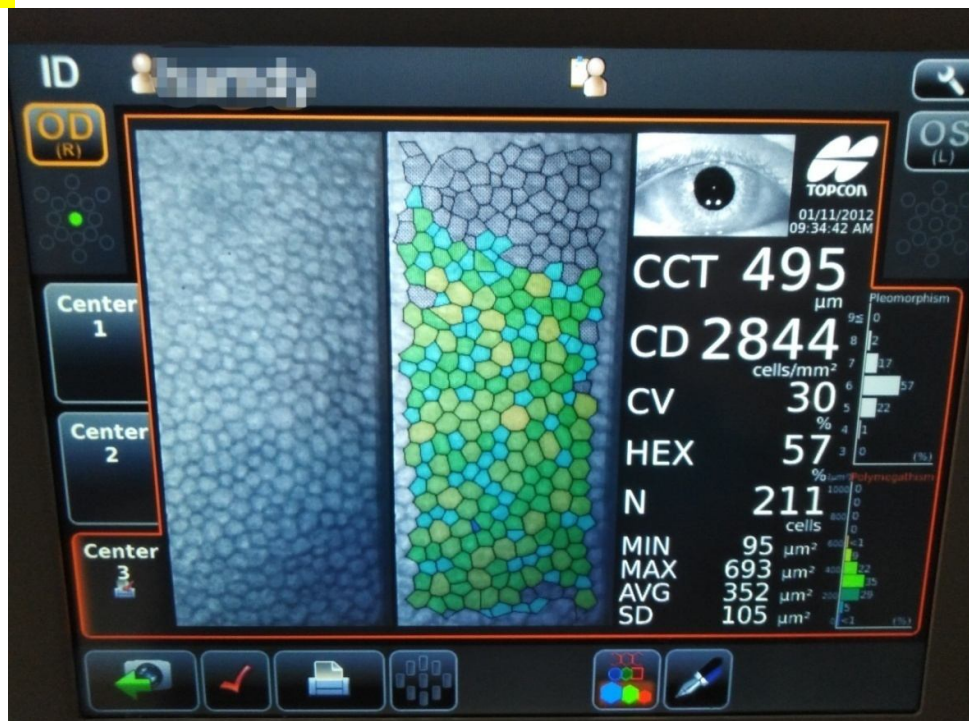

Figure (1): Specular microscopy image of the right eye of male aged 56 years from group A (non diabetics). It shows CCT= 495 μm , ECD=2844 cells/ mm^2 , CV=30%, HEX=57%, and Average cell size= 352 μm^2 .

Case 2:

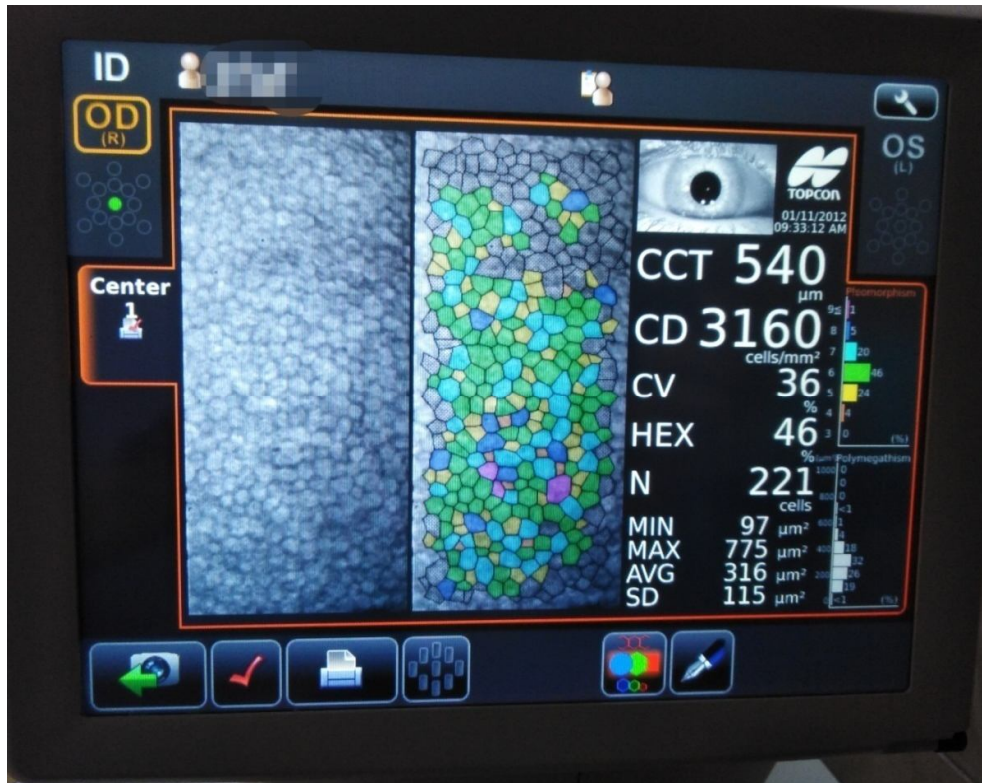

Figure (2): Specular microscopy image of the right eye of male aged 59 years from group B (diabetics of less than 10 years). It shows CCT= 540 μm, ECD=3160 cells/mm², CV=36%, HEX=46%, and Average cell size= 316 μm².

Case 3:

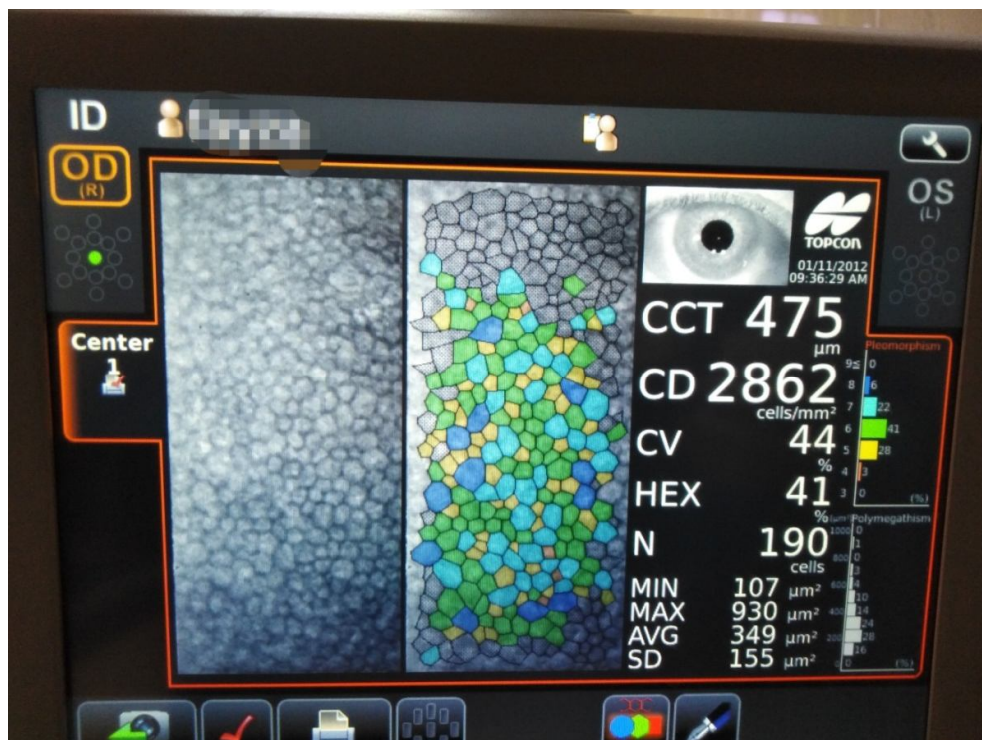


Figure (3): Specular microscopy image of the right eye of female aged 58 years from group C (diabetics of more than 10 years). It shows CCT= 475 μm, ECD=2862 cells/mm², CV=44%, HEX=41%, and Average cell size= 349 μm².

5. DISCUSSION:

This study used specular microscopy to analyze alterations in the CE in patients with diabetes.

The CE is a single layer of cells whose Na/K-ATPase pump activity is essential for preserving the cornea's optical clarity [7]. The density of corneal endothelial cells falls by roughly 0.5% every year. In addition to aging, the loss of corneal endothelial cells is affected by race, heredity, intraocular surgery, trauma and infection [8].

“DM is a metabolic disorder characterized by persistent hyperglycemia arising from defective insulin production or insulin action. Chronic hyperglycemia may result in micro- and macrovascular diseases and alters nearly all eye tissues” [9]. It is crucial to evaluate the corneal endothelial cell state in diabetic individuals. Surgical stress, like as cataract surgery, can reduce the number of corneal endothelial cells. In diabetic individuals, preoperative corneal endothelial cell dysfunction may exacerbate postoperative corneal endothelial cell damage.

Our study revealed no statistically significant difference in endothelial cell density (ECD) between diabetic and non-diabetic individuals. This was similar to the results of Storr-Paulsen et al., [5] and Siribunkum et al., [10] “studies of CE morphology in type II DM where they did not find any statistically significant difference in endothelial cell density”. However, studies by Sumit et al.,[11] involving more sample size (540 eyes or less) Rizvi and Zafar,[12] (130 eyes) and Kim & Kim et al.,[13] included 511 (1022 eyes) type II DM patients and 900 (1799 eyes) non-diabetic patients, showed that the mean endothelial cell density of type II DM patients was significantly lower than that of controls. Also, El-Agamy and Alsubaie, [14] Sudhir et al.,[15] Choo et al.,[4] and Inoue et al.,[16] studies revealed a significant reduction in ECD of diabetic corneas relative to controls.

Regarding the Coefficient of variation (CV), our study demonstrated significant increase in the mean CV from $34.73 \pm 2.67\%$ in group A (non-diabetics) to $37.80 \pm 4.29\%$ in group B (diabetics of less than 10 years) and increased to $40.63 \pm 2.71\%$ in group C (diabetics of more than 10 years). There were statistically significant differences between the three studied groups ($p < 0.001$). This is similar to studies by El-Agamy and Alsubaie, [14] Shenoy et al.,[17] and Lee et al.,[18] The rise in CV suggested that the endothelial cells expanded to cover the spaces between adjacent cells. In opposition, Sumit et al.,[11] Inoue et al.,[16] Chen et al.,[6] and Sudhir et al.,[15] found that there was no significant difference in CV between diabetic and non-diabetic corneas.

In the comparison of the mean CV value between patients with diabetes of less than ten years and those with diabetes of more than ten years, there was a statistically significant increase in group C (diabetics of more than 10 years) ($p = 0.001$).

According to the percentage of hexagonality (HEX%), our study found significant decrease of mean HEX% from $54.70 \pm 4.95\%$ in group A to $44.35 \pm 3.74\%$ in group B and decreased to $42.0 \pm 3.84\%$ in group C. There was a statistically significant differences between the three studied groups ($p < 0.001$). This is similar to studies by Sudhir et al.,[15] Storr-Paulsen et al.,[5] and Inoue et al [16]. In opposition, El-Agamy and Alsubaie, [14] Choo et al.,[4] and Lee et al.,[18] reported that they did not detect any statistically significant change in HEX% in diabetic compared to non-diabetic corneas.

Concerning the average cell size results, our study showed significant increase of the mean average cell size from $317.82 \pm 28.37\mu\text{m}^2$ of group A (non-diabetics), to $343.18 \pm 38.35\mu\text{m}^2$ of group B (diabetics of less than 10 years). There were statistically significant difference between group A and B ($p = 0.004$). Also, the mean average cell size of group C increased to $345.05 \pm 37.48\mu\text{m}^2$. There was a statistically significant difference between group A and C ($p = 0.002$), But we found no statistically significant difference between group B and C ($p = 0.969$).

Numerous research [6, 18, 19] has shed “light on the morphological characteristics of diabetic cornea. Assessing the polyol (sorbitol–aldose reductase) pathway in diabetic cornea established this. These investigations demonstrated that high glucose levels stimulate aldose reductase activity, leading sorbitol accumulation in corneal epithelial and endothelial cells. This sorbitol works as an osmotic agent and causes endothelial cells to enlarge. Moreover, DM reduces the Na⁺–K⁺ ATPase activity of the corneal epithelium, resulting in morphological and permeability abnormalities and ultimately corneal destruction. In addition, the function of the endothelial pump was shown to be influenced by

the lower ATP generation caused by the slowed Krebs cycle in diabetic cornea”.

As regards to the central corneal thickness (CCT), our study found a significant decrease of mean CCT from $518.18 \pm 23.58 \mu\text{m}$ of group A to $500.70 \pm 21.82 \mu\text{m}$ of group B. The difference between groups A and B was statistically significant ($p=0.005$). Also, the mean CCT of group C decreased to $491.93 \pm 27.52 \mu\text{m}$. There was statistically significant difference between groups A and C ($p<0.001$), But we found no statistically significant difference between groups B and C ($p=0.247$).

These results regarding the CCT differ from the majority of previous results which found increasing in the CCT in diabetics compared to nondiabetics as the study of Storr-Paulsen et al.,[5] and Lee et al., [18] that showed a statistically significant difference in CCT between diabetes and control participants.

Our results may be due to the smaller sample size, the large variation in normal central corneal thickness which range from $500 \mu\text{m}$ to $550 \mu\text{m}$ and also may be due to the dryness associated with DM, which was demonstrated by a prior study by Oriowo,[20] on the effect of diabetes on central corneal thickness (CCT) measures in individuals with and without dry eyes. Their study found that the mean CCT was $610 \mu\text{m}$ (599 to 620), $601 \mu\text{m}$ (582 to 618), and $583 \mu\text{m}$ (576 to 589) μm , respectively, in diabetics without dry eye, with dry eye, and the control groups. Also, this decrease in the central corneal thickness may be due to the natural crosslinking effect that occurs in the cornea of diabetic patients which was proven by Naderan et al.,[21] about the association between DM and keratoconus, This study discovered that DM has a statistically significant preventive impact against the formation of Keratoconus. The cross-linking biomechanical effects were represented in epidemiological findings as well.

Also, a study by Choo et al.,[4] Sudhir et al.,[15] El-Agamy and Alsubaie,[14] and Inoue et al.,[16] found that “the CCT in diabetic patients was not significantly different from that in nondiabetic patients”.

Regarding the correlation between HbA1c and the specular microscopy parameters, a significant negative correlation between HbA1c and HEX% ($p: <0.001$) was found in our study, and between HbA1c and CCT ($p<0.001$). But there was significant positive correlation between HbA1c and CV ($p<0.001$). However, Storr-Paulsen et al.,[5] showed significantly reduced ECD in individuals with increased HbA1c, but no effect on CCT. However, Altay et al.,[22] reported “significantly thicker CCT in hyperglycemic than in euglycemic conditions in the same patient before and during effective HbA1c management”.

In summary, type II diabetes was associated with a substantial decrease in the proportion of hexagonal cells and central corneal thickness compared to healthy controls. In addition, there was a very significant rise in the coefficient of variation between diabetics and controls, although there was no statistically significant difference in endothelial cell density between diabetics and controls.

6. CONCLUSION

Our study has demonstrated considerable effects of diabetes mellitus (DM) on the corneal endothelium.

Our study showed that the corneal endothelium of diabetic patients had decreased HEX%, decreased central corneal thickness, and increased CV% compared to non- diabetics.

There was significant negative correlation between HBA1C and HEX%, And between HBA1C and CCT. But there was significant positive correlation between HBA1C and CV.

These consequences have ramifications for both corneal surgeons who use diabetic donor tissue and treat diabetic patients as well as diabetic patients undergoing anterior segment surgery. **CONSENT AND ETHICAL APPROVAL**

The study adhered to the tenets of the Declaration of Helsinki and all patients signed a written informed consent to participate in the study and for publication of data before enrollment in the study

after approval from the ethical committee, Faculty of Medicine, Tanta University, and its later amendments or comparable ethical standards (34242/11/20).

REFERENCES:

1. van Crevel R, van de Vijver S, Moore DAJ. The global diabetes epidemic: what does it mean for infectious diseases in tropical countries? *Lancet Diabetes Endocrinol.* 2017;5(6):457-68.
2. Gella L, Raman R, Kulothungan V, Saumya Pal S, Ganesan S, Sharma T. Retinal sensitivity in subjects with type 2 diabetes mellitus: Sankara Nethralaya Diabetic Retinopathy Epidemiology and Molecular Genetics Study (SN-DREAMS II, Report No. 4). *Br J Ophthalmol.* 2016; 100(6): 808-13.
3. Ljubimov AV. Diabetic complications in the cornea. *Vision Res.* 2017;139:138-52.
4. Choo M, Prakash K, Samsudin A, Soong T, Ramli N, Kadir A. Corneal changes in type II diabetes mellitus in Malaysia. *Int J Ophthalmol.* 2010;3(3):234-6.
5. Storr-Paulsen A, Singh A, Jeppesen H, Norregaard JC, Thulesen J. Corneal endothelial morphology and central thickness in patients with type II diabetes mellitus. *Acta Ophthalmol.* 2014;92(2):158-60.
6. Chen Y, Huang S, Jonna G, Channa P. Corneal endothelial cell changes in diabetes mellitus. *Invest Ophthalmol Vis Sci.* 2014;55(13):2054.
7. Tuft SJ, Coster DJ. The corneal endothelium. *Eye (Lond).* 1990;4 (Pt 3):389-424.
8. Mäkitie J, Vannas A, Koskenvuo M. Corneal endothelial cells in mono- and di-zygotic twins. *Invest Ophthalmol Vis Sci.* 1983;24(8):1029-32.
9. Vieira-Potter VJ, Karamichos D, Lee DJ. Ocular Complications of Diabetes and Therapeutic Approaches. *Biomed Res Int.* 2016;2016:3801570.
10. Siribunkum J, Kosrirukvongs P, Singalavanija A. Corneal abnormalities in diabetes. *J Med Assoc Thai.* 2001;84(8):1075-83.
11. Sumit SA, Bammigatti C, Kumar P. Corneal endothelial changes in patients of type 2 diabetes mellitus using specular microscopy. *EC Ophthalmology.* 2017;6:100-7.
12. Rizvi B, Zafar O. Corneal Endothelial Cell Count in Type II Diabetic Patients. *Pak Armed Forces Med J.* 2016;66(4):494-97.
13. Kim YJ, Kim TG. The effects of type 2 diabetes mellitus on the corneal endothelium and central corneal thickness. *Sci Rep.* 2021;11(1):8324.
14. El-Agamy A, Alsubaie S. Corneal endothelium and central corneal thickness changes in type 2 diabetes mellitus. *Clin Ophthalmol.* 2017;11:481-6.
15. Sudhir RR, Raman R, Sharma T. Changes in the corneal endothelial cell density and morphology in patients with type 2 diabetes mellitus: a population-based study, Sankara Nethralaya Diabetic Retinopathy and Molecular Genetics Study (SN-DREAMS, Report 23). *Cornea.* 2012;31(10):1119-22.
16. Inoue K, Kato S, Inoue Y, Amano S, Oshika T. The corneal endothelium and thickness in type II diabetes mellitus. *Jpn J Ophthalmol.* 2002;46(1):65-9.
17. Shenoy R, Khandekar R, Bialasiewicz A, Al Muniri A. Corneal endothelium in patients with diabetes mellitus: a historical cohort study. *Eur J Ophthalmol.* 2009;19(3):369-75.
18. Lee JS, Oum BS, Choi HY, Lee JE, Cho BM. Differences in corneal thickness and corneal endothelium related to duration in diabetes. *Eye (Lond).* 2006;20(3):315-8.
19. Briggs S, Osuagwu UL, AlHarthi EM. Manifestations of type 2 diabetes in corneal endothelial cell density, corneal thickness and intraocular pressure. *J Biomed Res.* 2016;30(1):46-51.
20. Oriowo OM. Profile of central corneal thickness in diabetics with and without dry eye in a Saudi

population. *Optometry*. 2009;80(8):442-6.

21. Naderan M, Naderan M, Rezagholizadeh F, Zolfaghari M, Pahlevani R, Rajabi MT. Association between diabetes and keratoconus: a case-control study. *Cornea*. 2014;33(12):1271-3.
22. Altay Y, Burcu A, Ornek F. The change in central corneal thickness after successful control of hyperglycemia in diabetic patients. *Int Eye Sci*. 2014;14(4):575-8.