

## Original Research Article

# Alleviation of Acetic Acid-Induced Ulcerative Colitis in Rat Model by *Vernonia Amygdalina* (Asteraceae) Leaf Extract

### ABSTRACT

**Background:** Ulcerative colitis (UC) is a category of chronic inflammatory intestinal disease of unknown origin. Some medicinal plants have been used as therapeutic targets for UC, however, there is a paucity of information on the use of *Vernonia amygdalina* leaves.

**Aim:** The present study aimed to investigate the protective effects of aqueous extract of *V. amygdalina* leaves (AEVA) on experimental rat models of ulcerative colitis.

**Place and Duration of Study:** Department of Medical Laboratory Sciences and Animal House, College of Medicine, University of Nigeria, Enugu Campus, between September 2016 and November 2018.

**Methodology:** Twenty-four rats equally divided into six groups were used for the study. A control group received only drinking water while UC was induced by transrectal infusion of 1 ml of 4% acetic acid into rats in 5 groups. UC-model rats were given no further treatment whereas the other four treatment groups received a single oral daily dose of sulfasalazine (SSZ, 225mg/kg), 50, 100, and 200mg/kg body weight (b.wt.) of AEVA for seven days. The rats were, thereafter, weighed and sacrificed under chloroform anaesthesia. The distal colon of each rat was excised, weighed, and examined both macroscopically and microscopically. Histopathological grading was conducted to determine the extent of the injury.

**Results:** Results revealed severe inflammatory cellular infiltration, mucosal erosion, and ulceration in the UC-model rats. However, a dose-dependent reduction in the colonic lesions was observed following treatment with AEVA and the most potent dose was 200mg/kg b.wt.

**Conclusion:** The present study has indicated that the aqueous extract of *Vernonia amygdalina* leaves mitigates AA-induced ulcerative colitis and hence may be offered as a potential therapeutic agent.

**Keywords:** Histopathology; *Vernonia amygdalina*; Aqueous extract; Ulcerative colitis; Rats.

## 1. INTRODUCTION

Inflammatory bowel disease (IBD), which comprises ulcerative colitis (UC) and Crohn's disease (CD), is a group of chronic idiopathic inflammatory intestinal diseases (UC) [1]. The incidence rate is increasing and thus has become a global healthcare burden [2]. The clinical manifestations associated with inflammatory bowel disease (IBD) included diarrhoea, diarrhoea, blood in stool, abdominal pain, and weight loss [3]. Ulcerative colitis (UC) is of unknown aetiology but it may be dependent on some factors being of environmental, immunological, or genetic origin (Button *et al*, 2010) [4]. The main characteristic feature differentiating UC from CD is that UC affects chiefly the rectum and descending colon with the lesions being homogenous and continuous without skip areas [5,6].

Across geographical zones and from one country to another, the prevalence of ulcerative colitis UC varies. Previously, the incidence was thought to be rare in the sub-Saharan region of Africa[7], but evidence suggesting an increase is currently available and may likely pose a public health challenge in the near future soon[8]. In Nigeria, however, the disease has been reported in adults[9,10], though among physicians, it is commonly perceived as being very rare, but this has been attributed to diagnostic delay[11].

Conventional treatment of UC has employed different drugs including aminosalicyclic acid, immunosuppressants, biological therapies, and corticosteroids[12], however, none is effective to cure the disease. The treatment of UC patients is usually based on the disease severity, and as such is adjusted for each patient mainly to reduce the symptoms[13,14]. However, rare and common adverse side effects have been associated with the use of these conventional therapies[15]. More so, in Nigeria, the difficulty in sourcing the basic drug (sulfasalazine) for treatment has posed a major challenge to patients, thus making it cost-prohibitive[11]. Due to these challenges, previous researchers have reported on the common use of alternative remedies for the treatment of IBD[16,17]. Therefore, the need for the development of cheaper and readily available new therapies with ascertained safety and efficacy is pertinent.

Several plants have been discovered to possess anti-inflammatory action and one of such plants is *Vernonia amygdalina*. The plant is commonly known as bitter leaf and it occurs as a shrub or herb of about 1 – 3 m in height throughout tropical Africa [18]. In Nigeria, it is a common plant to the South-Easterners (Igbos) as it is popularly used as a staple vegetable in soups. Traditional healers use the plant as a remedy for many diseases. A wide array of phytochemicals has been shown to be present in *V. amygdalina* and these are believed to be responsible for the various biological activities of the plant. *V. amygdalina* have been known to possess anti-inflammatory, anti-nociceptive, antipyretic, antidiabetic, anti-cancer anticancer, antibacterial, and antifungal, antimalarial, antileishmanial, amoebicidal, antioxidant, hepatoprotective, and nephroprotective activities[19-27].

The use of herbal remedies or their active principles have has become an increasingly appealing approach in experimental studies. Since, there is a dearth of scientific literature on the effect of *Vernonia amygdalina* in IBD, the present study was therefore undertaken to evaluate the effects of the *Vernonia amygdalina* aqueous leaf extract on acetic acid-induced ulcerative colitis UC in albino Wistar rats.

## 2. MATERIAL AND METHODS

### 2.1 Study area

The study was carried out at the Department of Medical Laboratory Sciences, Faculty of Health Sciences and Technology, College of Medicine, University of Nigeria, Enugu Campus, Nigeria. The animal studies were carried out at the College of Medicine Research Animal Facility. The entire research work was conducted from September 2016 – November 2018.

### 2.2 Chemicals

All the chemicals used were of analytical grade.

### 2.3 Procurement and Identification of Plant Material

Fresh leaves of *Vernonia amygdalina* used for this work were purchased from New Market in Enugu Metropolis, Enugu State, Nigeria during the rainy season. The plant taxonomy was identified and authenticated by a specialized Botanist by comparing it with voucher specimens specimens available at the herbarium section of the Department of Plant Science

and Biotechnology, University of Nigeria, Nsukka. The plant material was allowed to air-dry in shade for two weeks, reduced into a homogenous fine powder using a gasoline grinding machine, and stored in tightly closed containers at room temperature for further pharmacological studies.

#### 2.4 Plant Extraction

One hundred grams of the air-dried powder of *V. amygdalina* leaves was placed in a flask containing 750ml of distilled water for extraction. The mixture was homogenised using a wooden stirrer with occasional shaking for 12h. The homogenate was sieved using a clean muslin cloth and the filtrate obtained was stored in the refrigerator (2-8°C) until required for use. The extractive value was determined and the yield was found to be 120mg/ml.

#### 2.5 Animal Housing

Twenty-four (24) albino rats of weight (110g-155g) were obtained from the animal house at the Department of Physiology, University of Nigeria, Enugu Campus. They were housed in the animal house of the Department of Anatomy, University of Nigeria, Enugu Campus, and grouped into six (6) of four (4) rats per group. They were housed under ambient conditions of temperature and 12 hours of light:12 hours of dark cycle. Clean water and standard commercial rat feed (Guinea feed®) were provided for the animals, *ad libitum*. The animals were left for two weeks to acclimatize to the laboratory environment before the commencement of the studies. The study protocol employed in accordance with International guidelines and principles for the care and handling of laboratory animals. The Institutional Animal Welfare and Ethics Committee approved all the experimental procedures carried out.

#### 2.6 Induction of the Experimental Ulcerative Colitis in Rats

After a 36-hour fast, procedures for the induction of colitis were carried out. A soft paediatric polyurethane cannula (diameter of 2mm) was used for the rectal entrance of the acetic acid (AA). Under mild chloroform anaesthesia, the tip of the cannula was inserted up to 8 cm proximal to the anus. In order to induce ulcerative colitis, one millilitre (1ml) of 4% acetic acid was slowly delivered transrectally into the colon using the cannula for 30 s. To avoid leakage of the acetic acid, each animal was maintained in a head-down position for another 30 s.

**2.6.1 Experimental Protocol:** Treatments commenced 24 hours after colitis induction and continued for seven days. The treatments given to the six experimental groups were as follows:

- **Group A:** Normal control receiving only drinking water only
- **Group B:** Negative control (ulcerative colitis control) and received 1ml/kg of normal saline orally.
- **Group C:** Positive control and were treated with oral SSZ (225mg/kg body weight),
- **Group D:** Low dose (50mg/kg body weight) of AEVA
- **Group E:** Medium dose (100mg/kg body weight) of AEVA and,
- **Group F:** High dose (200mg/kg body weight) of AEVA.

All drug treatments [aqueous extract of *Vernonia amygdalina* leaves (AEVA) and Sulfasalazine (SSZ)] were administered as a single dose, daily, by oral gavage.

**2.6.2 Monitoring of Animal Body Weight:** The animals were monitored for changes in body weight by obtaining the daily body weights of each rat in all the groups with the aid of a digital weighing balance. Body weights at 24, 48, 72, 96, 120, 144, and 168 hrs post-UC induction were recorded, and the total body weight change was determined.

**2.6.3 Macroscopic Assessment of Colonic Damage:** On the eighth day, the rats were sacrificed under chloroform ~~anaesthesia~~ **anesthesia**. Their distal colonic segments (10 cm in length and 3 cm proximal to the anus) were excised, cut open longitudinally to expose the inner mucosa, and gently washed using normal saline to free the tissue from ~~faecal~~ **fecal** content. The wet colon tissues were weighed and the weight-to-length ratio ~~were was~~ obtained for the determination of the disease index caused by wall thickening and ~~oedema~~ **edema** as previously described [28].

The severity of colonic damage was assessed macroscopically with the aid of a magnifying lens (x10) for grading ~~of~~ lesions quantified by a scoring system (0 - 4) as previously described [29].

**2.6.4 Histological Processing:** The tissues were fixed in freshly prepared 10% formalin ~~prior to~~ **before** processing. They were further processed using an Automatic tissue processor to dehydrate, clear, and infiltrate the tissue with molten paraffin wax. The tissues were later embedded in tissue cassettes with paraffin wax and cut into thin sections (3 – 5µm) using a rotary microtome. The tissue sections obtained were stained with ~~haematoxylin~~ **hematoxylin** and eosin routine staining procedure.

**2.6.5 Histopathological assessment:** The stained colon sections of control and test groups were examined for histomorphological alterations using an Olympus® binocular microscope with an inbuilt lighting system. The sections were photomicrographed using AmScope® digital camera (MU300) and inserted into one of the eyepiece tubes of the Olympus binocular microscope. Histopathological analyses of the tissue sections were conducted as previously described [12]. ~~Extent~~ **The extent** of injury, inflammatory cellular infiltration, and crypt damage were scored on a 0-3 scale in at least 3 sections from each tissue sample. For injury (0: none; 1: mucosal; 2: mucosal and submucosal; 3: transmural); crypt damage (0: none; 1: basal third damaged; 2: basal two-thirds damaged; 3: loss of entire crypt and epithelium); and severity of inflammation (0: none; 1: slight; 2: moderate; 3: severe). The minimum and maximum total scores of 0 and 9 respectively, are obtainable by this scoring system.

## 2.7 Statistical Analysis

Data obtained in the present study were expressed as mean ± SEM. Group ~~mean~~ **means** comparisons were carried out using a one-way ANOVA test followed by Tukey's post hoc test. The statistical package for social sciences (SPSS, Chicago, IL) software, version 23 was used for the analysis.  $p < 0.05$  was considered statistically significant.

## 3. RESULTS

### 3.1 Effect of AA and various treatments on Animal body weights

The data presented in Table 1 illustrates the effect of AA-induced UC in control and treatment groups. Twenty-four (24) hours (Day 1) after the induction of ~~ulcerative colitis~~ **UC**, there was a significant decrease ( $p < 0.05$ ) in the mean body weight gain of animals in all treatment groups (B – F) when compared to the normal control (Group A). A similar effect was also noted after 48hrs in groups D and E only ( $p < 0.05$ ). However, a progressive increase in body weight gain was observed in all groups from 72 – 120 hrs of study and on the last day of the experiment. By the end of the study, body weight gain was observed in all the groups with the highest in group F treated with 200mg/kg AEVA. However, a significant decrease in weight gain was noted only in group E treated with 100mg/kg AEVA when compared to the normal control ( $p < 0.05$ ).

**Table 1:** Effect of Acetic acid (AA)-induced ulcerative colitis (UC) of body weights and total body weight change of rats and its modulation by treatments with Sulfasalazine (SSZ) and *V. amygdalina* extract

TREATMENT GROUPS	BODY WEIGHT CHANGES							TOTAL BODY WEIGHT CHANGE
	24 Hrs	48 Hrs	72 Hrs	96 Hrs	120 Hrs	144 Hrs	168 Hrs	
A (normal control)	10.50±1.44 <sup>b</sup>	4.50±0.87	1.75±0.48	1.50±0.29	1.25±0.48	0.50±0.50	4.00±0.71	24.00±2.45
B (AA only)	-3.25±0.85 <sup>a</sup>	0.25±0.85	4.50±0.65	4.00±0.82	3.25±0.63	3.50±0.29	6.50±3.52	18.75±2.10
C (SSZ + AA)	-2.75±0.25 <sup>a</sup>	2.75±1.11	6.00±0.71	5.00±0.00	4.50±0.87	-3.25±0.25 <sup>b</sup>	12.50±0.50 <sup>ab</sup>	24.75±1.55
D (50 mg/kg AEVA + AA)	-2.25±0.63 <sup>a</sup>	-2.50±1.26 <sup>a</sup>	4.50±1.32	5.50±1.55	3.50±1.19	0.75±0.75	4.75±1.03	14.25±3.77
E (100 mg/kg AEVA + AA)	0.00±0.00 <sup>a</sup>	-6.00±2.16 <sup>a</sup>	4.75±1.80	4.25±0.63	3.50±0.96	-0.50±2.06	1.50±0.87	7.50±0.65 <sup>a</sup>
F (200 mg/kg AEVA + AA)	-2.00±0.41 <sup>a</sup>	2.50±1.89	10.00±2.61 <sup>a</sup>	8.75±1.65 <sup>ab</sup>	6.00±0.82 <sup>a</sup>	1.00±1.35	6.50±1.50	31.25±4.50
F-Ratio	47.975	7.272	3.403	5.332	3.349	4.125	4.775	8.961
Sig.	0.000	0.001	0.024	0.004	0.026	0.011	0.006	0.000

Data (Mean±SEM) obtained from all treatment groups and controls were statistically analyzed using ANOVA followed by Tukey's multiple comparison test. A: p<0.05 when compared to normal control; b: p<0.05 when compared to AA control. SSZ: Sulfasalazine; AA: Acetic acid; AEVA: Aqueous extract of *Vernonia amygdalina* leaves

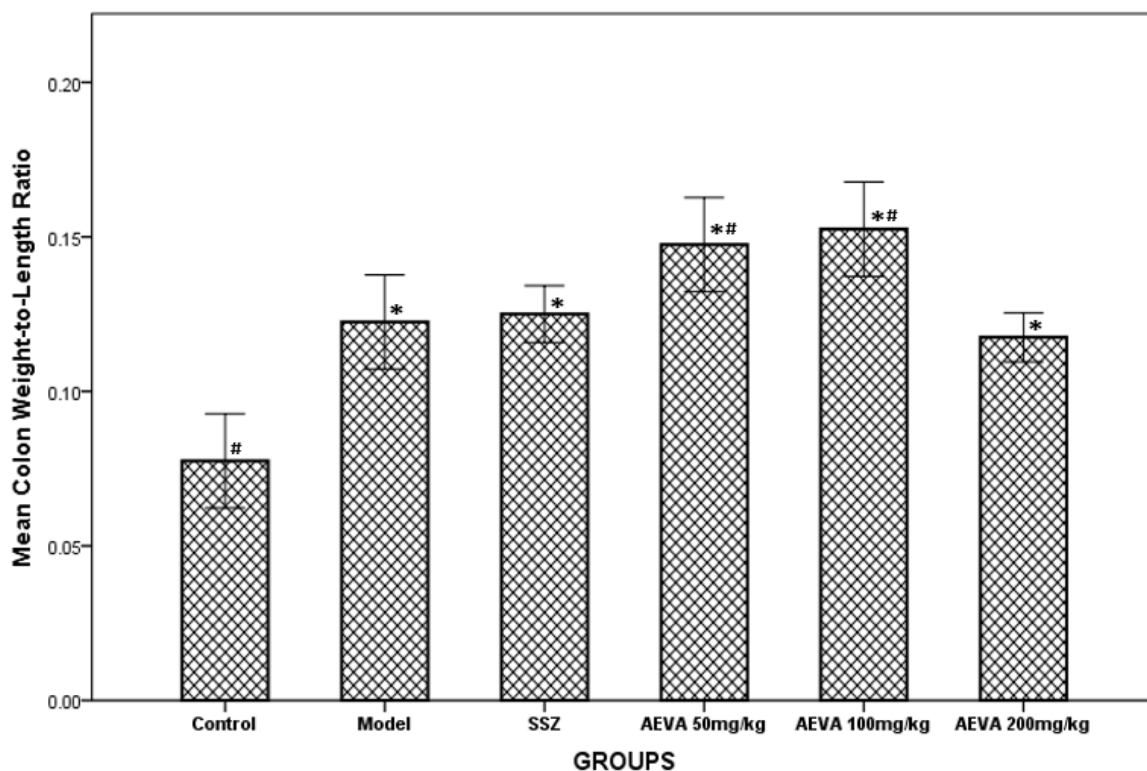
### 3.2 Effect of AEVA treatments on colon weight-to-length ratio

Differences in colon weight-to-length ratio are presented in Figure 1. Significantly increased values (p<0.05) were observed in all UC-induced rats (Groups B to F) when compared to normal control (0.08±0.00). Higher colon weight-to-length ratios were produced by treatments with 50 and 100mg/kg body weight AEVA treatment groups (0.15±0.01 and 0.15±0.01 respectively) when compared to the UC-model (0.12±0.01) (p<0.05); whereas, no significant change was observed with the values obtained for SSZ and 200mg/kg b.wt. AEVA treatment groups (0.13±0.01 and 0.12±0.01 respectively).

### 3.3 Macroscopical Assessment of Colon damage

The effect of AEVA treatments on the macroscopical features of the colon is represented in Figure 2. Upon macroscopical examination of the colonic tissues of rats in all treatment groups, intact tissue morphology with no sign of damage was observed in the normal control (group A) (Plate A1) with a score of 0.00±0.00. However, in the UC-model (group B), the highest score of 3.75±0.25 was recorded (p<0.05) when compared to the normal control. There was evidence of hyperaemia, hyperemia, extensive mucosal erosion, and ulceration (Plate A2). Sulfasalazine moderately preserved the tissue against damage caused by AA, decreasing the macroscopic score to 1.75±0.485 (p<0.05) when compared to the UC model. Macroscopical features revealed minimal evidence of haemorrhage, hemorrhage and erosions (Plate A3).

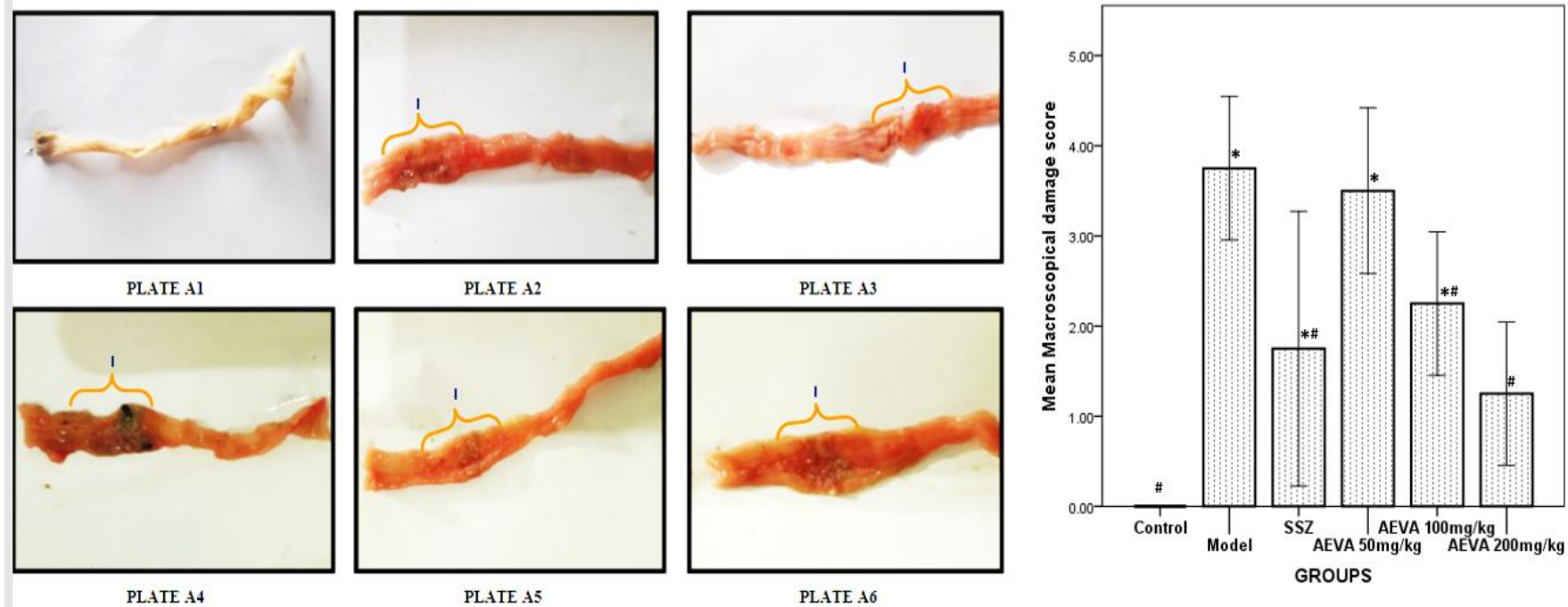
In the *AEVA*-treated groups, tissue preservation was best offered by the dose of 200mg/kg (Plate A6), followed by 100mg/kg (Plate A5) with reduced macroscopic scores of  $1.25 \pm 0.25$  and  $2.25 \pm 0.25$  respectively ( $p < 0.05$ ) when compared to UC model. However, treatment with 50 mg/kg *AEVA* (Plate A4) produced high scores of  $3.50 \pm 0.48$ , with the macroscopic features similar to those observed in UC-model rats.



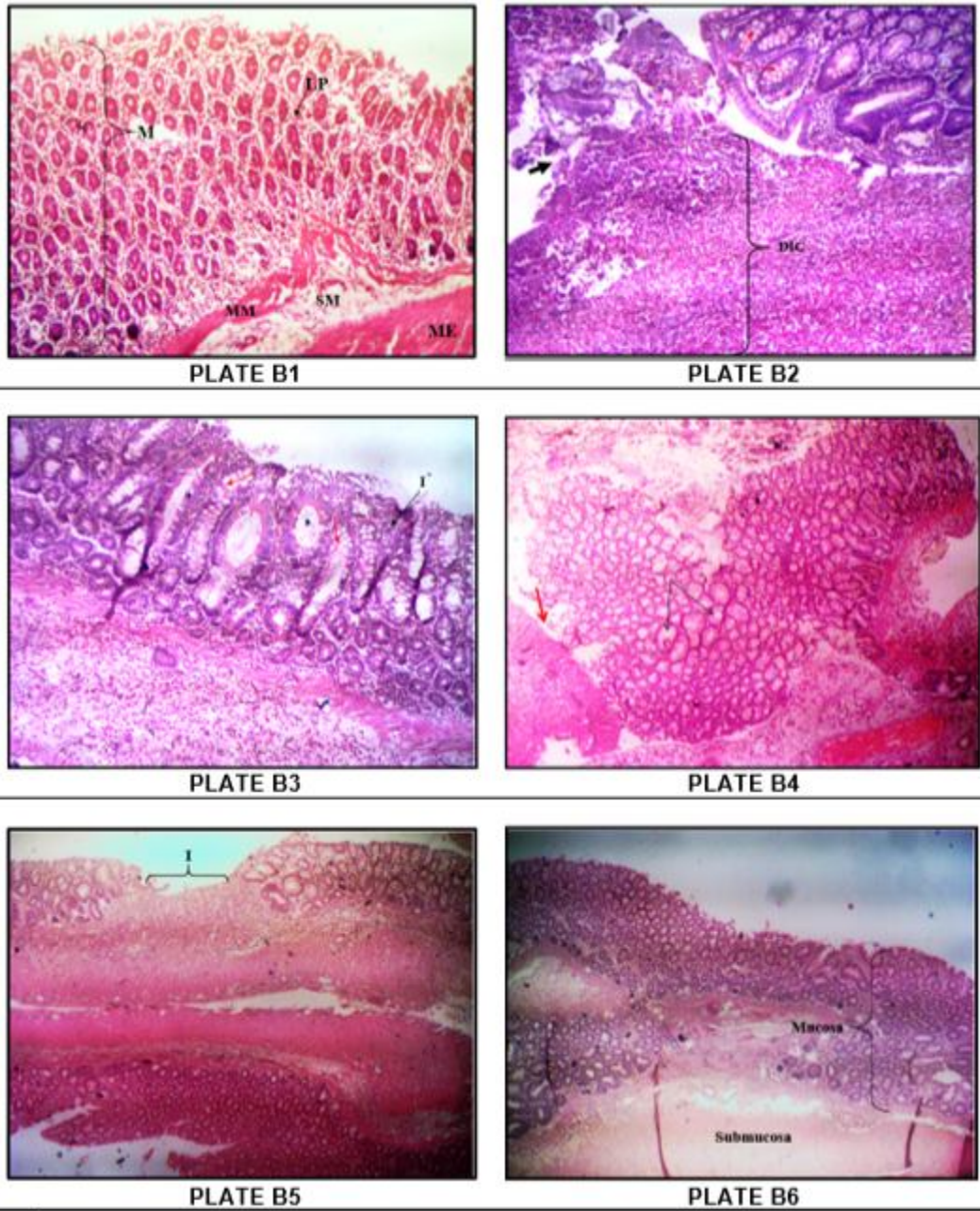
**Fig. 1:** Effect of *AEVA* treatment on rat mean Colon weight-to-length ratio in Acetic acid-induced ulcerative colitis. Data are expressed as Mean ± SEM (n=4), where \* and #  $p < 0.05$  compared to normal control and UC-model respectively. [*AEVA* – Aqueous extract of *V. amygdalina* leaves; **ucUC** – Ulcerative colitis]

### 3.4 Histopathological Findings

Figure 3 represents the findings from the microscopical examination of the colonic tissues. The normal control rats showed normal histoarchitecture of the intestinal tissue. Normal mucosa (M), lamina propria (LP), muscularis mucosa (MM), submucosa (SM) and muscularis externa (ME) are shown (Plate B1). Contrarily, the colon of UC-model rats showed ulcerated and desquamated epithelial mucosa (thick arrows), crypt disarray, massive diffuse inflammatory cellular infiltration extending to the submucosal region (DIC), necrosis associated with edema and goblet cell hyperplasia in few crypts seen (red arrows) (Plate B2). However, treatment with the standard drug, Sulfasalazine, produced a relative improvement in the mucosal layer as it was fairly eroded with mild inflammatory cellular infiltration (I) and showing evidence of goblet cell hyperplasia (red arrows) and submucosal edema (Plate B3).



**Fig. 2.:** Effect of **AEVA** treatment on AA-induced macroscopic damage on colon tissues of rats. Photomicrographs of the colon tissues reveal **portion portions** on the segment bearing the lesions [I]. (A1) Normal control; (A2) UC-model; (A3) SSZ; (A4, A5 and A6) **AEVA** 50, 100 and 200mg/kg respectively. The quantified macroscopical damage scores are represented in bar charts. Data are presented as Mean±SEM (n=4), where \* and # p<0.05 compared to normal control and UC-model respectively



**Fig. 3.:** Effect of **AEVA** treatment on AA-induced histopathological damage on colon tissues of rats. Light photomicrographs of the colon tissues reveal a portion on the segment bearing the lesions [I]. (B1) Normal control; (B2) UC-model; (B3) SSZ; (B4, B5 and B6) **AEVA** 50, 100 and 200mg/kg respectively. [Stain: H&E: Mag.:x100]

**Table 2:** Histopathological evaluation of colonic tissues of rats after oral treatment with Sulfasalazine and Aqueous extract of *Vernonia amygdalina* leaves post-induction of Ulcerative colitis using Acetic acid

GROUPS	HISTOLOGICAL GRADING CRITERIA			TOTAL SCORES
	Extent of Injury	Inflammatory Cellular Infiltration	Crypt Damage	
Group A (normal control)	0.00±0.00 <sup>#</sup>	0.00±0.00 <sup>#</sup>	0.00±0.00 <sup>#</sup>	0.00±0.00 <sup>#</sup>
Group B (UC-model)	2.75±0.25*	3.00±0.00*	2.75±0.25*	8.50±0.29*
Group C (AA + 100mg/kg SSZ)	1.00±0.00 <sup>#</sup>	1.00±0.00 <sup>#</sup>	0.75±0.25 <sup>#</sup>	2.75±0.25 <sup>#</sup>
Group D (AA + 50mg/kg AEVA)	2.25±0.25*	2.75±0.25*	2.75±0.25*	7.75±0.63*
Group E (AA + 100mg/kg AEVA)	0.75±0.25 <sup>#</sup>	0.75±0.25 <sup>#</sup>	0.75±0.25 <sup>#</sup>	2.25±0.48 <sup>#</sup>
Group F (AA + 200mg/kg AEVA)	0.50±0.25 <sup>#</sup>	0.25±0.25 <sup>#</sup>	0.25±0.25 <sup>#</sup>	1.00±0.71 <sup>#</sup>
F-ratio	25.154	52.333	29.000	59.892
Sig.	0.000	0.000	0.000	0.000

Data expressed in mean ± SEM; \*p<0.05 when compared to the normal control (Group A) and <sup>#</sup>p<0.05 in comparison to the UC-model (Group B). SSZ – Sulfasalazine; AEVA – Aqueous extract of *Vernonia amygdalina* leaves; AA – Acetic acid; UC- Ulcerative colitis

#### 4. DISCUSSION

The present study evaluated the protective effects of *Vernonia amygdalina* leaves extract (AEVA) against experimentally induced ulcerative colitis (UC) in rats as a model for inflammatory bowel disease (IBD). Three dose levels of the extract were evaluated in Acetic acid (AA)-induced colitis albino rats, in comparison with Sulfasalazine (SSZ), a standard drug which that is usually prescribed to UC patients [30]. The preventive effect of AEVA was confirmed by the use of SSZ and also histological evaluation. Post-treatment of the animal models with AEVA for seven days significantly reduced Acetic acid (AA)-induced lesions in a dose-dependent manner.

The induction of UC with acetic acid is a widely accepted and well-established model of UC which produces the morphological features that mimics the pathogenesis of human IBD[31,32]. Experimentally, prominent tissue injury on the colon are produced following administration of AA and the causative factor for the associated alterations is oxidative stress[33]. This has been demonstrated in previous studies which documented increased malondialdehyde (MDA) levels (pro-oxidant) and decreased antioxidant systems (SOD, CAT, and GPX levels) in tissues[34]. The imbalance which exists between the pro-oxidant and anti-oxidant systems is well-known to play an important role in the pathogenesis of various diseases. The results obtained in the present study confirmed the suitability of the use of AA to induce UC having produced acute lesions characteristically associated with the disease.

The gold standards for evaluating inflammatory injury in tissues remain macroscopic and microscopical examination. Macroscopically, no change was observed in the colon of normal control rats suggesting that animal handling did not interfere with the empirical outputs. However, AA treatment on the colon produced hyperaemia, mucosal erosion, and ulceration on the treated region of the colon. Profound microscopical changes found in the current study were consistent with the necropsy revealing damaged crypts, mucosal ulceration, marked transmural infiltration of inflammatory aggregates, and necrosis, thus indicating the extent and severity of the disease. These macroscopical and histopathological findings correlate with previous reports[35,36].

A significant body weight loss was observed in all the treated rats twenty-four (24) hours after the induction of ulcerative colitis, a similar trend seen both in previous studies[37,38]. The weight loss could be attributed to the diarrheal effect established by the induced colitis.

In colitis, loss of weight is usually attributed to rapid loss of body fluid due to diarrhoea/diarrhea and rectal bleeding, malabsorption, nutrient deficiency due to reduced appetite, and food aversion[39]. In the current study, the weight loss observed could be attributed to fluid loss through diarrhoea/diarrhea, and rectal bleeding. The increase in the water content of stool can be due to the impaired water absorption caused by the ulceration of the mucosa of the colon. Similar impairments were reported in earlier studies using the same 4% acetic acid to induce ulcerative colitis model[33, 39].

This present research was conducted based on the possibility that the AEVA could be used for the treatment of ulcerative colitis. Upon treatment with AEVA, it was observed that treatment with the highest dose of the extract showed an accelerated weight gain in a manner better than that offered by the standard drug, SSZ. However, lower doses of the extract did not produce better effects than the UC-model group on body weight. Thus, it can be inferred that extract of *V. amygdalina* alleviated the effect of diarrhoea/diarrhea on the treated rats which was induced after intrarectal administration of acetic acid. Previous studies have also shown anti-diarrhoea/diarrheal properties of *V. amygdalina* following experimentally-induced experimentally induced diarrhoea [40,41].

In the current study, the results of the macroscopic examination of the colon of AEVA-treated rats are indicative of the therapeutic potential of the extract against lesions impacted by acetic acid. This necropsy observation was further supported by the histopathological findings which showed dose-dependent cytoarchitectural preservation of the colon mucosa by the extract treatment. As noted from the histopathological scores, the highest dose of the extract administered (200mg/kg) markedly inhibited the lesions exerted by acetic acid including erosions, ulceration, necrosis, inflammatory cellular infiltration, and hyperplasia. This ameliorative effect suggests that *V. amygdalina* leaves protected the rats from further disease progression by either an enhanced healing, anti-oxidant, and/or anti-inflammatory mechanism on the tissue, correlating with previous reports on the pharmacological effects of the extract[42,43]. The tissue restorative process offered by the extract in the present study was better than that offered with the standard drug, Sulfasalazine.

These/This finding justifies the wide traditional use of *V. amygdalina* extract in the treatment and/or management of various ailments and diseases in humans and animals. The effects observed in this study may be attributable to the single or synergistic action of the phytochemical principles present in the extract which include flavonoids, saponins, sesquiterpene lactones, lignans, phenolic acids, coumarins, xanthenes and anthraquinones[44].

## 5. CONCLUSION

The findings obtained from the present study suggest that oral administration of aqueous extract of *Vernonia amygdalina* possesses a substantial protective effect against the deleterious effect of acetic acid-induced ulcerative colitis in rats. Further investigations to identify the bioactive constituent(s) responsible for the observed effects are required in order to identify a natural and safe agent for effective treatment of individuals with ulcerative colitis.

## ETHICAL APPROVAL

All authors hereby declare that "Principles of laboratory animal care" (NIH publication No. 85-23, revised 1985) were followed, as well as specific national laws where applicable. All experiments have been examined and approved by the appropriate Institutional ethics committee. Animal housing and handling protocols were performed in strict accordance to guidelines describing the use of rats for research.

## REFERENCES

1. Finlay, D. G., Basu, D., & Sellin, J. H. Effect of race and ethnicity on perceptions of inflammatory bowel disease. *Inflammatory bowel diseases* 2006;12(6), 503-507.
2. M'koma, A. E. Inflammatory bowel disease: an expanding global health problem. *Clinical Medicine Insights: Gastroenterology* 2013; 6, CGast-S12731.
3. Safarpour, A. R., Hosseini, S. V., & Mehrabani, D. Epidemiology of inflammatory bowel diseases in Iran and Asia; a mini review. *Iranian Journal of Medical Sciences* 2013;38(2 Suppl), 140.
4. Button, L. A., Roberts, S. E., Goldacre, M. J., Akbari, A., Rodgers, S. E., & Williams, J. G. (2010). Hospitalized prevalence and 5-year mortality for IBD: record linkage study. *World Journal of Gastroenterology: WJG*, 16(4), 431.
5. Loddo, I., & Romano, C. Inflammatory bowel disease: genetics, epigenetics, and pathogenesis. *Frontiers in immunology* 2015;6, 551.
6. Liu, T. C., & Stappenbeck, T. S. Genetics and pathogenesis of inflammatory bowel disease. *Annual Review of Pathology: Mechanisms of Disease* 2016;11, 127-148.
7. Cosnes, J., Gower-Rousseau, C., Seksik, P. and Cortot, A. (2011). Epidemiology and Natural History of Inflammatory Bowel Diseases. *Gastroenterology*. 140: 1785-1794.
8. Hodges, P., & Kelly, P. Inflammatory bowel disease in Africa: what is the current state of knowledge?. *International health* 2020; 12(3), 222-230.
9. Hodges, P., & Kelly, P. Inflammatory bowel disease in Africa: what is the current state of knowledge?. *International health* 2020; 12(3), 222-230.
10. Ukwanya-Ukwanya, A.Y., Ahmed, A., Odigie, V.I. and Mohammed, A. Inflammatory bowel disease in Nigerians: Still a rare diagnosis? *Annals of African Medicine* 2011; 10(2):175-179.
11. Alatishe, O.I., Otegbayo, J.A., Nwosu, M.N., Lawal, O.O., Ola, S.O. and Anyanwu, N.C. Characteristics of inflammatory bowel disease in three tertiary health centres in southern Nigeria. *West African Journal Medicine* 2012; 31(1):28-31.
12. Ekwunife, C. N., Nweke, I. G., Achusi, I. B., & Ekwunife, C. U. Ulcerative colitis prone to delayed diagnosis in a Nigerian population: case series. *Annals of medical and health sciences research* 2015; 5(4), 311-313.
13. Rodriguez-Canales, M., Jimenez-Rivas, R., Canales-Martinez, M. M., Garcia-Lopez, A. J., Rivera-Yañez, N., Nieto-Yañez, O., ... & Rodriguez-Monroy, M. A. Protective effect of *Amphipterygium adstringens* extract on dextran sulphate sodium-induced ulcerative colitis in mice. *Mediators of inflammation*, 2016.
14. El-Meligy, R. M., Awaad, A. S., Soliman, G. A., Bacha, A. B., Alafeefy, A. M., & Kenawy, S. A. Prophylactic and curative anti-ulcerative colitis activity and the possible mechanisms of action of some desert plants. *Journal of enzyme inhibition and medicinal chemistry* 2015;30(2), 250-258.

14. Awaad, A. A., Alkanhal, H. F., El-Meligy, R. M., Zain, G. M., Adri, V. D. S., Hassan, D. A., & Alqasoumi, S. I. Anti-ulcerative colitis activity of *Calotropis procera* Linn. *Saudi Pharmaceutical Journal* 2018; 26(1), 75-78.
15. Siegel, C. A. Explaining risks of inflammatory bowel disease therapy to patients. *Alimentary pharmacology & therapeutics* 2011; 33(1), 23-32.
16. Ke, F., Yadav, P. K., & Ju, L. Z. Herbal medicine in the treatment of ulcerative colitis. *Saudi journal of gastroenterology: official journal of the Saudi Gastroenterology Association* 2012; 18(1), 3.
17. Opheim, R., Bernklev, T., Fagermoen, M. S., Cvancarova, M., & Moum, B. Use of complementary and alternative medicine in patients with inflammatory bowel disease: results of a cross-sectional study in Norway. *Scandinavian journal of gastroenterology* 2012; 47(12), 1436-1447.
18. Ojiako, O.A. and Nwanjo, H.U. Is *Vernonia amygdalina* hepatotoxic or hepatoprotective? Response from biochemical and toxicity studies on rats. *African Journal of Biotechnology*. 2006; 5(18):1648-1651.
19. Asante, D. B., Henneh, I. T., Acheampong, D. O., Kyei, F., Adokoh, C. K., Ofori, E. G., ... & Ameyaw, E. O. Anti-inflammatory, anti-nociceptive and antipyretic activity of young and old leaves of *Vernonia amygdalina*. *Biomedicine & pharmacotherapy* 2019; 111, 1187-1203.
20. Uhuegbu, F.O. and Ogbuehi, K.J. Effect of aqueous extract (crude) of leaves of *Vernonia amygdalina* (Del.) on blood glucose, serum albumin and cholesterol levels in diabetic albino rats. *Global Journal of Pure Applied Sciences* 2004; 10: 189-194.
21. Joseph, J., Khor, K. Z., Moses, E. J., Lim, V., Aziz, M. Y., & Samad, N. A. In vitro Anticancer Effects of *Vernonia amygdalina* Leaf Extract and Green-Synthesised Silver Nanoparticles. *International journal of nanomedicine* 2021; 16, 3599.
22. Agbankpe, A. J., Dougnon, T. V., Bankole, S. H., Houngbegnon, O., & Dah-Nouvlessounon, D. In vitro antibacterial effects of *Crateva adansonii*, *Vernonia amygdalina* and *Sesamum radiatum* used for the treatment of infectious diarrhoeas in Benin. *Journal of Infectious Diseases & Therapy*, 2016.
23. Habtom, S., & Gebrehiwot, S. In vitro antimicrobial activities of crude extracts of *Vernonia amygdalina* and *Croton macrostachyus* against some bacterial and fungal test pathogens. *J Phytopharmacol* 2019; 8(2), 57-62.
24. Abosi, A. O., & Raseroka, B. H. In vivo antimalarial activity of *Vernonia amygdalina*. *British Journal of Biomedical Science* 2003; 60(2), 89-91.
25. Moundipa, P. F., Flore, K. G. M., Bilong, C. F., & Bruchhaus, I. In vitro amoebicidal activity of some medicinal plants of the Bamun region (Cameroon). *African Journal of Traditional, Complementary and Alternative Medicines* 2005; 2(2), 113-121.
26. Iwalokun, B. A., Efedede, B. U., Alabi-Sofunde, J. A., Oduala, T., Magbagbeola, O. A., & Akinwande, A. I. Hepatoprotective and antioxidant activities of *Vernonia amygdalina* on acetaminophen-induced hepatic damage in mice. *Journal of Medicinal Food* 2006; 9(4), 524-530.
27. Akpanyung, E. O., Noah, U. T., Bassey, U. E., & Udotong, J. R. I. Protective potential of ethanol leaf extract of *Vernonia amygdalina* against aluminium chloride induced renal toxicity in male Wistar rats. *Journal of Medicinal Plants Studies* 2020; 8(3), 39-43.
28. Duijvestein, M., Wildenberg, M. E., Welling, M. M., Hennink, S., Molendijk, I., van Zuylen, V. L., ... & Hommes, D. W. Pretreatment with interferon- $\gamma$  enhances the therapeutic activity of mesenchymal stromal cells in animal models of colitis. *Stem cells* 2011; 29(10), 1549-1558.
29. Adakudugu, E. A., Ameyaw, E. O., Obese, E., Biney, R. P., Henneh, I. T., Aidoo, D. B., ... & Obiri, D. D. Protective effect of bergapten in acetic acid-induced colitis in rats. *Heliyon*, 2020; 6(8), e04710.

30. Nikfar, S., Rahimi, R., Rezaie, A., & Abdollahi, M. A meta-analysis of the efficacy of sulfasalazine in comparison with 5-aminosalicylates in the induction of improvement and maintenance of remission in patients with ulcerative colitis. *Digestive diseases and sciences*, 2009; 54(6), 1157-1170.
31. Fabia, R., Willen, R., Ar'Rajab, A., Andersson, R., Ahren, B., & Bengmark, S. Acetic acid-induced colitis in the rat: a reproducible experimental model for acute ulcerative colitis. *European surgical research* 1992; 24(4), 211-225.
32. Awaad, A. A., Alkanhal, H. F., El-Meligy, R. M., Zain, G. M., Adri, V. D. S., Hassan, D. A., & Alqasoumi, S. I. Anti-ulcerative colitis activity of *Calotropis procera* Linn. *Saudi Pharmaceutical Journal* 2018; 26(1), 75-78.
33. Harisa, G. E. I., Abo-Salem, O. M., El-Sayed, E. S. M., Taha, E. I., & El-Halawany, N. L-arginine augments the antioxidant effect of garlic against acetic acid-induced ulcerative colitis in rats. *Pakistan Journal of Pharmaceutical Sciences* 2009; 22(4).
34. Cetinkaya, A., Bulbuloglu, E., Kantarceken, B., Ciralik, H., Kurutas, E. B., Buyukbese, M. A., & Gumusalan, Y. Effects of L-carnitine on oxidant/antioxidant status in acetic acid-induced colitis. *Digestive diseases and sciences* 2006; 51(3), 488-494.
35. Adegoke, G. A., Onasanwo, S. A., Eyarefe, O. D., & Olaleye, S. B. Ameliorative effects of *Musa sapientum* peel extract on acetic acid-induced colitis in rats. *The Journal of Basic & Applied Zoology* 2016; 77, 49-55.
36. Rafeeq, M., Murad, H. A. S., Abdallah, H. M., & El-Halawany, A. M. Protective effect of 6-paradol in acetic acid-induced ulcerative colitis in rats. *BMC complementary medicine and therapies* 2021; 21(1), 1-10.
37. Bastaki, S. M., Adeghate, E., Amir, N., Ojha, S., & Oz, M. Menthol inhibits oxidative stress and inflammation in acetic acid-induced colitis in rat colonic mucosa. *American journal of translational research* 2018; 10(12), 4210.
38. Okayasu, I., Hatakeyama, S., Yamada, M., Ohkusa, T., Inagaki, Y., & Nakaya, R. A novel method in the induction of reliable experimental acute and chronic ulcerative colitis in mice. *Gastroenterology* 1990; 98(3), 694-702.
39. Owusu, G., Obiri, D. D., Ainooson, G. K., Osafo, N., Antwi, A. O., Duduyemi, B. M., & Ansah, C. Acetic acid-induced ulcerative colitis in sprague-dawley rats is suppressed by hydroethanolic extract of *Cordia vignei* leaves through reduced serum levels of TNF- $\alpha$  and IL-6. *International journal of chronic diseases*, 2020.
40. Okere, O. S., Sangodele, J. O., Tade, O. G., Obafemi, O. T., & Falode, J. A. Anti-diarrhea potential and acute toxicity studies of methanolic extract of *Vernonia amygdalina* and *Cymbopogon citratus* against castor oil induced diarrhea model in rats. *International Journal of Biochemistry Research & Review* 2015; 6(2), 46.
41. Gudeta, B. M., Taye, G. M., Abula, T., & Gadisa, D. A. Evaluation of Anti-Diarrheal Activity of 80% Methanol Extracts of *Vernonia amygdalina* Delile (Asteraceae) Leaves in Mice. *Journal of Experimental Pharmacology* 2020; 12, 455.
42. Nafiu, A. B., Akinwale, O. C., Akinfe, O. A., Owoyele, B. V., Abioye, A. I. R., Abdulazeez, F. I., & Rahman, M. T. Histomorphological Evaluation of Wound Healing-Comparison between Use of Honey and *Vernonia Amygdalina* Leaf Juice. *Nigeria. Trop. J. Health Sci* 2016; 23(3), 10-11.
43. Wang, W. T., Liao, S. F., Wu, Z. L., Chang, C. W., & Wu, J. Y. Simultaneous study of antioxidant activity, DNA protection and anti-inflammatory effect of *Vernonia amygdalina* leaves extracts. *Plos one* 2020; 15(7), e0235717.
44. Ijeh, I. I., & Ejike, C. E. Current perspectives on the medicinal potentials of *Vernonia amygdalina* Del. *Journal of Medicinal Plants Research* 2011; 5(7), 1051-1061.