

Case study

Macrophagic activation syndrome revealing Hodgkin lymphoma: Case report

ABSTRACT

Macrophage Activation Syndrome (MAS), or Haemophagocytosis Syndrome, is a clinical-biological entity characterized by the proliferation and non-specific activation of macrophages of the reticulo-histiocytic system, with phagocytosis of the blood elements formed. This syndrome can be primary in children or secondary to various conditions at any age. Its association with Hodgkin's lymphoma is exceptional. We report here a case of MAS that revealed Hodgkin's lymphoma in a 5-year-old child. And we underline the interest of an urgent diagnosis and a fast care because risk of evolution towards a fatal multivisceral failure.

Keywords: Macrophage Activation Syndrome; MAS; Hemophagocytosis Syndrome; Hodgkin's Lymphoma

INTRODUCTION

Macrophage activation syndrome (MAS) is a rare disease [1], characterized by proliferation and non-specific activation of macrophages of the reticulo-histiocytic system, with phagocytosis of the blood elements formed. It is potentially fatal if not treated quickly [2]. It is a pathology that associates clinical signs (fever, hepato-splenomegaly, lymphadenopathy) and biological abnormalities (bi- or tricytopenia, hepatic cytolysis, elevation of lactate dehydrogenase, coagulopathy) with an image of hemophagocytosis on a cytological or histological sample. None of these signs is specific. However, the association with hypertriglyceridemia and hyperferritinemia is very strongly suggestive of MAS. This syndrome can be primary in children or secondary to various conditions at any age. Viral

infections by herpes viruses (especially Epstein-Barr and cytomegalovirus), by intracellular germs (tuberculosis), but also by pyogenic bacteria are, with neoplasms (mainly lymphomas) and certain autoimmune diseases (e.g., lupus), which are the main causes of MAS to look for. If T or NK lymphomas are the classic causes of reactive MAS, its association with Hodgkin's lymphoma (HL) is exceptional [3] and has a poor prognosis, hence the interest of thinking about it in order to make the diagnosis as quickly as possible and to start a specific treatment because of the risk of multi-visceral failures. We report here a case of MAS that revealed Hodgkin's lymphoma in a 5-year-old child.

CASE REPORT

The patient is a boy aged 5 and a half, who presented 36 days before admission with a prolonged fever. On clinical examination, the child was febrile at 39.5°C, has a splenomegaly and cervical lymphadenopathy. The biological assessment showed hypochromic microcytic anemia with hemoglobin level at 7.6 g/l. Mean corpuscular volume is 70 Fomtolitre, and mean corpuscular hemoglobin content is 23 picogramme, hyperferritinemia 1366 ng/ml, thrombocytopenia 98 g/l, hypertriglyceridemia 3.16 g/l, an inflammatory syndrome with sedimentation rate 100mm in the first hour, fibrinogen :7.5 g/l, c-reactive protein; 328 mg/l. Hepatic cytolysis (Aspartate aminotransferase : 251 ui/l, alanine aminotransferase: 182 ui/l, lactate dehydrogenase :1054 ui/l), and hemophagocytosis in the bone marrow. Thus, in the presence of Henter et al's five criteria, the diagnosis of macrophage activation syndrome was made. The etiological assessment revealed a reactivation of the Epstein-Barr virus (EBV), raising the suspicion of lymphoma. On the cervico-thoraco-abdominal CT scan: appearance in favor of homogeneous hepatosplenomegaly (Figure 1) with above and below diaphragmatic lymphadenopathy (Figure 2). Cervical lymph node biopsy confirmed the diagnosis of

scleronodular-type hodgkin lymphoma of scleronodular type Hodgkin's lymphoma. The patient was transferred to the pediatric oncology department.

DISCUSSION

The standard definition of MAS is based on the criteria of Henter et al, 2004 [3]. Diagnosis is possible when at least five of the following signs are present: fever, splenomegaly, cytopenia (at least two of: hemoglobin less than 9 g/dl, platelets less than 100 G/l, neutrophils less than 1 G/l), hypertriglyceridemia (greater than 3 g/L) or hypofibrinogenemia (lower than 1.5 g/l), hyperferritinemia (greater than 500 µg/l), increase in CD25 (greater than 2400 IU/ml), decrease in Natural killer cells activity and the presence of hemophagocytosis in the bone marrow, spleen or lymph nodes. Hypertriglyceridemia and hyperferritinemia are the most suggestive abnormalities of MAS when associated with cytopenias [4] as is the case of our patient. The liver balance sheet is always disturbed during MAS. Usually the LDH level is high. When the diagnosis of MAS is made, the search for the triggering element is imperative for the prognosis. In the case of our patient, infection with the Epstein-Barr virus (EBV) was the triggering factor.

The study by Takahashi et al. had clearly demonstrated the difference in prognosis between lymphoma-related MAS versus other MAS etiologies. In these MASs, the median survival was short (83 days), like overall survival (8%), which differed from other MASs linked for two thirds to viral infections and associated with 83% overall survival [5]. Among MAS secondary to lymphomas, the discovery of Hodgkin's lymphoma is an exceptional situation, the most common being T or NK lymphomas [6]. The Hodgkin's lymphoma associated with a MAS seems a particular entity. In all cases, it precedes or is contemporary with the discovery of MAS. Another particularity is the very strong association with EBV, which again contrasts

with the classic forms of Hodgkin's lymphoma (20–40%) [7]. The presence of EBV raises the hypothesis of an immune deficiency with respect to Epstein-Barr virus, thus patients with a history of infectious mononucleosis presenting a high risk of developing Hodgkin's lymphoma [8]. Finally, the evolution is rarely favorable.

CONCLUSION

The diagnosis of MAS should be considered in the presence of persistent fever associated with characteristic biological signs. When the diagnosis of MAS is retained, all means must be implemented to identify the triggering cause. the possibility of an exceptional Hodgkin's lymphoma should not be ruled out.

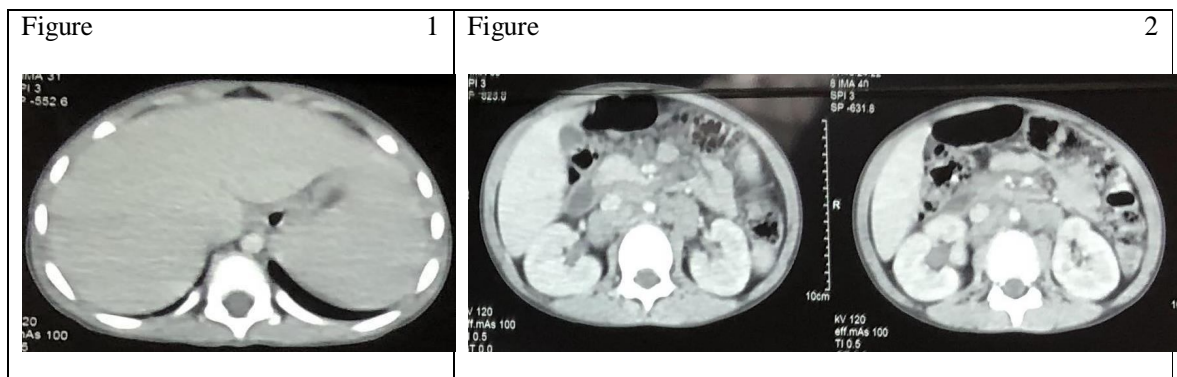


Fig 1 and 2: The cervico-thoraco-abdominal CT scan; homogeneous hepatosplenomegaly and lymphadenopathy.

Ethical Approval:

As per international standard or university standard written ethical approval has been collected and preserved by the author(s).

Consent

As per international standard or university standard, Parental's written consent has been collected and preserved by the author(s).

DATA AVAILABILITY

Not applicable

CONFLICTS OF INTEREST

The authors declare that there is no conflict of interest regarding the publication of this paper.

FUNDING STATEMENT

No funding was received to assist with the preparation of this manuscript.

AUTHORS'S CONTRIBUTIONS

This work was carried out in collaboration among all authors. NM and AAM designed the study, performed the statistical analysis, wrote the protocol, wrote the first draft of the manuscript, and managed the analyses of the study. NM and AAM managed the literature searches. All authors read and approved the final manuscript.

ACKNOWLEDGMENTS

We are grateful to the patient and her family for their collaboration.

REFERENCES

- 1 Chargui, Soumaya, et al. "Syndrome d'activation macrophagique d'origine infectieuse." *Ann. Afr. Med* 15.1 (2021): e4470.

- 2 Gonzalez F, Vincent F, Cohen Y. Syndrome d'activation macrophagique d'origine infectieuse/ étiologies et prise en charge. Réanimation 2009 ;18(4) : 284-290.
- 3 Martinaud C., et al. "Syndrome d'activation macrophagique révélant une maladie de Hodgkin chez un sujet âgé." La Revue de médecine interne 32.2 (2011): e15-e17.
- 4 Demirkol D, Yildizdas D, Bayrakci B, Karapinar B, Kendirli T, Koroglu TF, et al. Hyerferritinemia in the critically ill child with secondary hemophagocytic lymphohistiocytosis/sepsis/multiple dysfunction syndrome /macrophage syndrome what is the treatment? Crit Care 2012;16(2):R52.
- 5 Takahashi N, Chubachi A, Kume M, Hatano Y, Komatsuda A, Kawabata Y, et al. A clinical analysis of 52 adult patients with hemophagocytic syndrome: the prognostic significance of the underlying diseases. Int J Hematol 2001;74: 209-13
- 6 Takeshita M, Kikuchi M, Ohshima K, Nibu K, Suzumiya J, Hisano S, et al. Bone marrow findings in malignant histiocytosis and/or malignant lymphoma with concurrent hemophagocytic syndrome. Leuk Lymphoma 1993;12:79-89
- 7 Henter Ji, Horne A, Arico M, Egeler RM, Filipovich AH, Imashuku S, et al. HLH-2004: diagnostic and therapeutic guidelines for hemophagocytic lymphohistiocytosis. Pediatr Blood Cancer 2007;48:124-31
- 8 Rigaud S, Fondaneche MC, Lambert N, Pasquier B, Mateo V, Soulas P, et al. XIAP deficiency in humans cause an X-linked Lymphoproliferative syndrome. Nature 2006;444: 110-4