

DELAYED AND NON-HEALING WOUNDS IN ORAL & MAXILLOFACIAL SURGERY PRACTICE- A CASE SERIES

ABSTRACT

Wound healing is a physiological response to an injury. It is a very complex biological process. The oral cavity is a remarkable environment where healing often occurs without scar formation, even though oral cavity harbors millions of microbes. But instances of delayed or non-healing of wounds are common in the practice of oral and maxillofacial surgery. A plethora of causes have been suggested by various authors to account for these phenomena. Some of the common ones reported in the literature are the following¹: old age, obesity, chronic diseases, vascular insufficiency, malnutrition, protein and vitamin deficiency, malignancy, anemia, stress, immune-deficiency, infection and deficient oxygen delivery to tissues. Underlying systemic conditions are often ignored or undetected by general practitioners and this influence wound healing significantly. This article presents a series of unusual cases of delayed/non healing wounds, which warrant the need of proper referral of such cases by general practitioners to tertiary care centres.

Key words: delayed, wound, non-healing

Case no.1 -Non healing extraction wound

Introduction

Usually healing of extraction wounds is an uneventful process. Both local and systemic factors may lead to delayed healing¹. Usually, local factors predominate in such situations. Decreased immune response is the most common systemic condition that is usually seen as the general cause. Systemic malignancies are often ignored as a contributing factor of delayed healing since the chances are often rare².

The following is a case report of a non-healing extraction socket, with an uncommon etiologic factor.

Patient information

58-year-old lady with a complaint of non-healing extraction wound of two weeks duration with sprouting soft growth from the extraction socket reported to our out-patient department of Oral and maxillofacial surgery. She gave history of no other systemic disease other than that of hyper-lipidemia for which she was receiving treatment.

History of Presenting illness and clinical examination

She had a history of decayed lower right first molar (46), for which she had undergone extraction two weeks back (Fig 1a). The extraction procedure was normal with minor bleeding, which was arrested after suturing and pressure pack. On the 7th day, sutures were removed and she was entirely asymptomatic until that date. 3 days later, a soft tissue growth had developed over the extraction socket with occasional bleeding. Initially, it was suspected to be a granulation tissue by her dentist and she was advised to continue antibiotics and anti-inflammatory drugs. Subsequently, during the next 4 days, the growth rapidly enlarged in to a massive sprouting one (Fig. 1b) to the extent that the patient-experienced difficulty in closing the mouth, with bleeding and mild paraesthesia

Fig: 1(a, b, c)

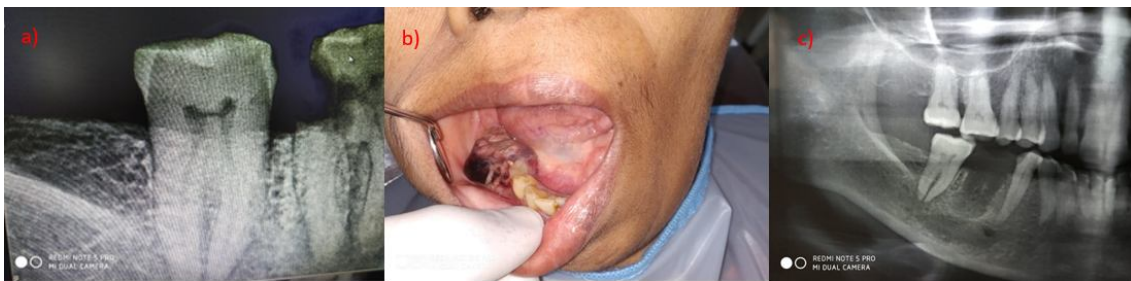

Fig 1a: Pre-extraction IOPAR, 1b: Sprouting growth, 1c: Post extraction OPG after 2 weeks

Diagnostic Assessment

An OPG was taken (Fig.1c) which was apparently normal.

To rule out the possibility of a systemic cause, random and fasting blood sugar as well as HbA1c estimation was done; which were normal. Haematology tests were also performed. The report showed that most of the parameters were within normal limits except for the following abnormal values (Table 1)

PARAMETER	PATIENT VALUE	NORMAL RANGE
WBC	37,100 cells/cumm	4,500-11,000 cells/cumm
Lymphocytes	53%	20-40%
ESR	110mm/hr	Male <10 Female<20
Platelets	50,000cells/cumm	1.5-4.5 lakh cells/cumm
PCV	29%	36- 48% in females

Table 1- Showing abnormal haematological parameters

Therapeutic Intervention

A possibility of a hematological malignancy was suspected and the patient was referred to the Regional cancer centre. Following bone marrow biopsy and blood smear report, the diagnosis of B lymphoblastic leukaemia was made. This was later confirmed with other tests.

Follow up and outcomes

The patient was treated with chemotherapy, but unfortunately succumbed to the death after one month of diagnosis.

Case report: 2- Non healing extraction socket

Introduction

If the symptoms for which the extraction is performed do not resolve completely or if the extraction socket fails to heal, there is an obvious chance for underlying pathology. This is yet another case, which shows the failure of an extraction socket to show adequate signs of healing timely.

Patient information

A 59-year-old gentleman with complaints of pain in the lower right back tooth region for two months with occasional pus discharge from the area reported to our outpatient department. The patient was not having any known systemic comorbidities.

History of Presenting illness and clinical examination

He gave a history of extraction of 48 in the same area two months back. The extraction procedure was normal (Fig 2a and 2b). The healing was uneventful. Two weeks later occasional pus discharge was noted from the adjacent tooth with pain. The patient consulted a local dental clinic from where antibiotics and analgesics were prescribed. The symptoms declined initially but later on the symptom aggravated and hence the patient reported our outpatient department.

On examination, there was a sinus opening in relation to 47 with pus discharge. 47 was having grade one mobility and was tender on percussion. It was diagnosed to be a periodontal abscess in relation to 47. The extraction of 47 was done uneventfully, and the post-operative bleeding was within normal limit. But the post extraction healing was not satisfactory. There was purulent discharge from the extraction site with an outgrowth of proliferative soft tissue mass from the extraction socket.

Diagnostic Assessment

All the routine blood examinations were performed. All the blood parameters were within normal limits. Pus was sent for culture and sensitivity. A biopsy was performed which showed dysplastic stratified squamous epithelium invading in to underlying connective tissue in the form of sheets and cords which was compatible with squamous cell carcinoma (Fig 2c).

Management

Patient was referred to our oncosurgery unit, where further test were done and was diagnosed with T2N0M0 squamous cell carcinoma. He had undergone segmental resection with prophylactic neck dissection, followed by secondary reconstruction.

Fig: 2(a, b, c)

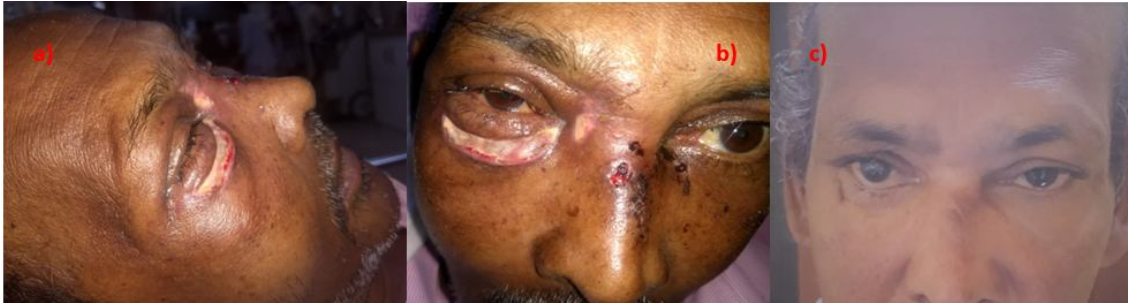

Fig 2a and 2b: Wound breakdown after 2 weeks, 2c: Surgical site after therapeutic management

Follow up and outcomes

Periodic follow up is being done for every 6 months since then with USG head and neck

Case Report: 3 -Post-operative surgical site infection after open reduction and internal fixation of fracture (ORIF)

Introduction

Open reduction and internal fixation of maxillofacial fractures utilizing mini plates have shown the highest success rate. However, failures are not rare. Main reasons for soft tissue infection are improper techniques and underlying medical conditions of the patient which are sometimes overlooked. The following case report highlights the importance of adequate haemoglobin level and appropriate antimicrobial coverage required for uneventful healing after open reduction and internal fixation (ORIF) of facial bone fractures.

Patient information

A 57-year-old male patient with previous history of **open reduction and internal fixation** (ORIF) in maxilla, right zygoma and right orbital floor reconstruction performed in our unit reported to our outpatient with surgical site infection, 14 days after surgery. The patient was having type ii diabetic mellitus, but was not under regular medications.

History of Presenting illness and clinical examination

A patient with a history of fracture maxilla and right ZMC and floor of right orbit reported back with surgical site infection, 14 days after surgery. The patient was having type ii diabetic mellitus, but was not under regular medications. There was wound dehiscence in the right infra orbital region (Fig. 3a and 3b) with active pus discharge extra orally and from the right upper buccal vestibule. The wound dehiscence was confined to the skin and sub cutaneous tissue.

Diagnostic Assessment

Routine blood examination and culture sensitivity tests were carried out. Since the patient was diabetic, it was assumed that inadequate glycemic control after discharge from hospital caused post-operative infection and wound dehiscence. But surprisingly the patient's glycemic control was adequate. The mean corpuscular volume (MCV), mean corpuscular hemoglobin (MCH) and Hb levels were considerably low. The culture and sensitivity report was also interesting. The microbial flora was resistant to most routinely used antibiotics, except imipenem, ertapenem and tigecycline.

Therapeutic Intervention

Since the wound dehiscence was confined to the skin and connective tissue, the plates implanted were not exposed and the plate removal was not considered in the immediate management. The priority was to raise the hemoglobin to a physiological level. 3 pints of Packed Red Blood Corpuscles transfusion was done after cross-matching. After the third transfusion hemoglobin level was raised to 11.6gm%. Also, Tab Orofer XT was administered once daily to control iron deficiency anemia. The antibiotic was then changed to imipenem. Along with this, dietary alternations were also done to control the nutritional deficiency. The surgical wound exploration, drainage of the pus and debridement were performed under local anesthesia. No foreign body like gauze piece could be located inside the wound as the cause for wound infection.

Within one week pus discharge subsided and healthy granulation tissue had developed at the surgical site. His culture report was also negative by this period.

Follow up and outcomes

Patient was in a regular follow up for the six months and the wound was perfectly healed in the last visit (Fig 3c).

Fig: 3 (a, b, c)

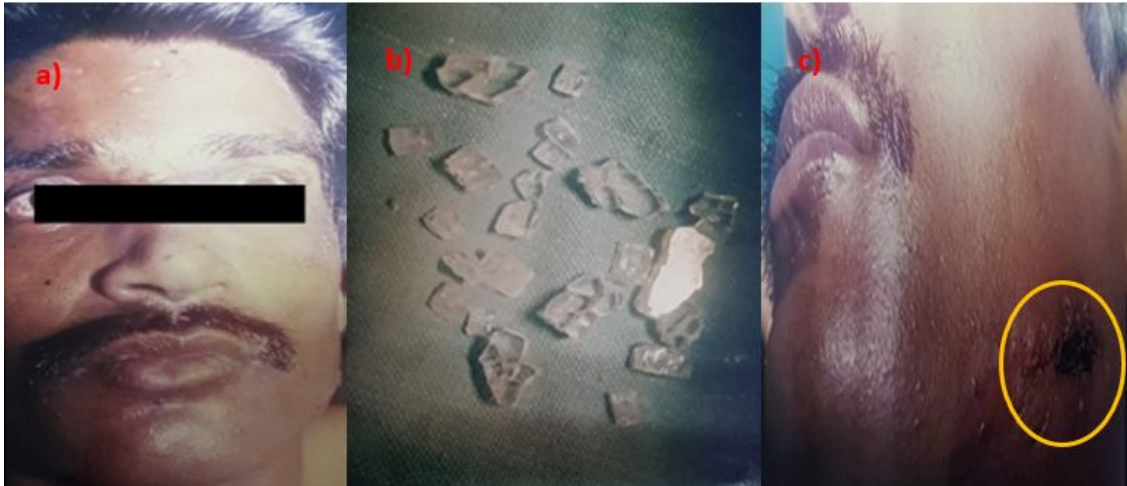

Fig 3a: Patient at the time of presentation, 3b: Glass particles retrieved, 3c: healed surgical site

Case Report: 4-Foreign Bodies in soft Tissue

Introduction

A reason for morbidity in soft tissue injuries is concealed foreign body entrapment. When delayed, the localization and removal of foreign bodies in soft tissue is challenging due to the associated inflammation/infection, granulated tissue, and fibrosis¹⁶. The following case report reveals the importance of thorough examination of facial wounds in the emergency department for foreign bodies such as glass particles.

Patient information

A 32-year-old male patient (4a) reported to our department complaining of pain and swelling in the left lower border of the mandible. The patient did not have any underlying comorbidities.

History of Presenting illness and clinical examination

The patient provided a history of a road traffic accident (RTA) two weeks back. The primary care and suturing of lacerated wound in the left lower border of the mandible was performed at a local hospital. On clinical examination, there was no evidence of fracture mandible or dental focus of infection to account for the swelling and pain.

Diagnostic Assessment

Routine blood and urine examinations were done and all the values were within the normal range. OPG was also found to be normal. Hence, an USG of the area was performed. USG detected foreign body with a hypoechoic ring and demonstrated a reverberation artefact that was suggestive of glass particles in the sutured wound.

Therapeutic Intervention

With help of USG, it was easy to localize the foreign body and to define the relationship with soft tissues. The wound was re-explored and glass particles along with necrotic tissue were removed (Fig 4b). Wound healed uneventfully, except for the presentation of slight scarring over the area (Fig 4c).

Follow up and outcomes

Patient was in a regular follow up for the past six months and the wound was perfectly healed in the last visit.

Fig: 4(a, b, c, d)

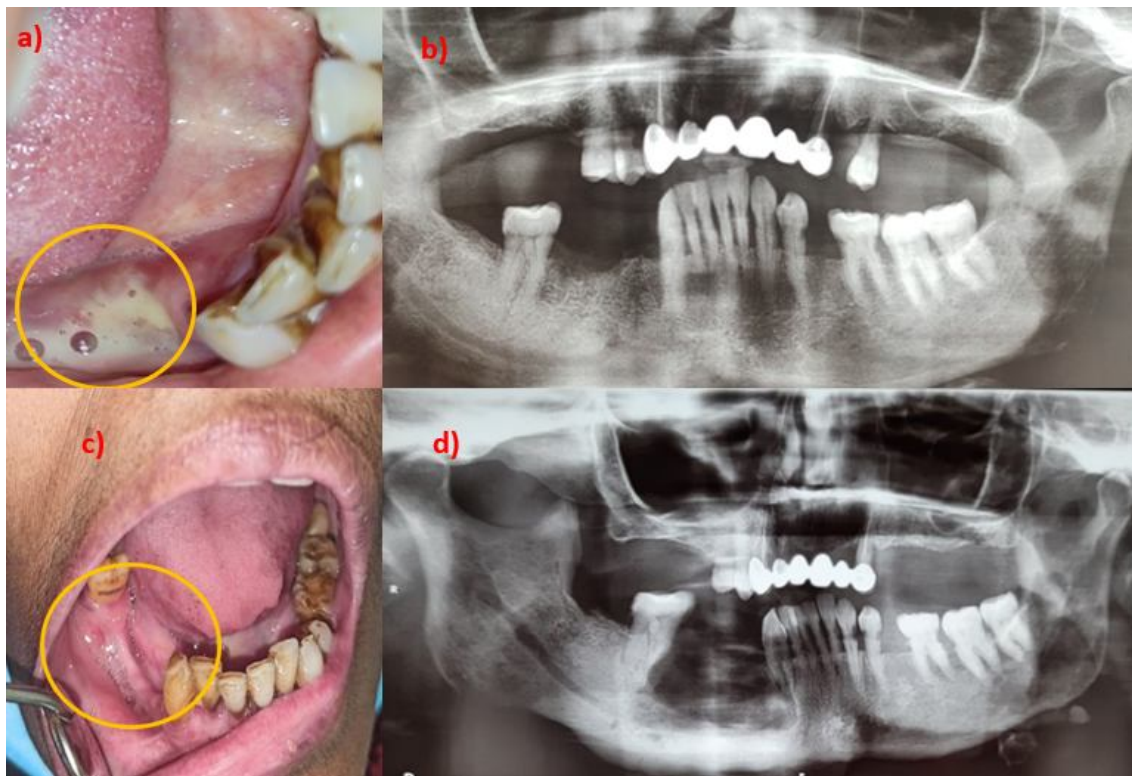


Fig 4a: Pus from the extraction site, 4b: OPG one month after extraction, 4c: healed surgical site after sequestrectomy, 4d: Post Op OPG

Case Report: 5-Osteoradionecrosis following extraction

Introduction

Osteoradionecrosis (ORN) is one of the most serious oral complications occurring for treating head and neck cancer treatment. ORN is an exposure of non-viable, non-healing,

non-septic lesion in the irradiated bone, which fails to heal without intervention. Although ORN lesions may be infected, this is usually a secondary event to the true pathophysiologic process of radiation necrosis⁹. Osteoradionecrosis is one of the common consequences of irradiation-induced tissue injury. Pain, drainage and the fistulous tract in the mucosa or skin that has been irradiated are the common clinical manifestations of ORN²⁰. This case report highlights the need of proper post-radiation treatment protocol needed for extraction and other surgical procedures in the maxillofacial area.

Patient information

A 77-year-old female patient reported to our department with complaints of pus discharge in the lower right back tooth region since three and a half years. The patient was diabetic, dyslipidemic and was also under psychiatric medication.

History of Presenting illness and clinical examination

The patient had a history of breast cancer four years earlier (T2N2M1), for which she had undergone radiation and chemotherapy. Dental extraction of 47 was done 3 months after the radiation therapy. Since then she gives a history of continuous pus discharge from the extraction socket (Fig 5a). On examination, non-healing extraction site was seen in relation to 47 with pus extruding from the extraction socket with obliteration of buccal vestibule and erythematous swollen area from 45 to 48. Paraesthesia in relation to the lateral one-third of right lower lip was reported. The site was non-tender on palpation.

Diagnostic Assessment

The pus was sent for culture and sensitivity, which revealed aerobic streptococcus viridians species (alpha haemolytic). A routine blood examination revealed a slight elevation in creatinine level. CRP was elevated slightly. An OPG (Fig 5b) was also taken which showed moderate bone loss in relation to the extraction site. CT mandible revealed ill-defined oblong area of mixed sclerosis and intramedullary lucency involving the body of the mandible on the right side with cortical defects and sequestrum.

Therapeutic Intervention

The patient was given ampicillin 500mg, 6 hourly for 7 days, pentoxifyllin 400mg three times daily, and tocopherol 1000 IU daily therapy on a long-term basis. But even after long-term medical management, symptoms didn't subside, hence sequestrectomy was done under GA. Before surgery, saline plus betadine irrigation 1:1 ratio and Inj Accuzone plus 1.5-g IV BD + Tab Pentoxifylline 400mg TID + Cap Evion 600mg BD for one week. Daily irrigation reduced the pus discharge. Periodic follow-up has been performed since then and the surgical site is in the healing stage (Fig 5c and 5d).

Follow up and outcomes

Fig: 5 (a, b, c,)

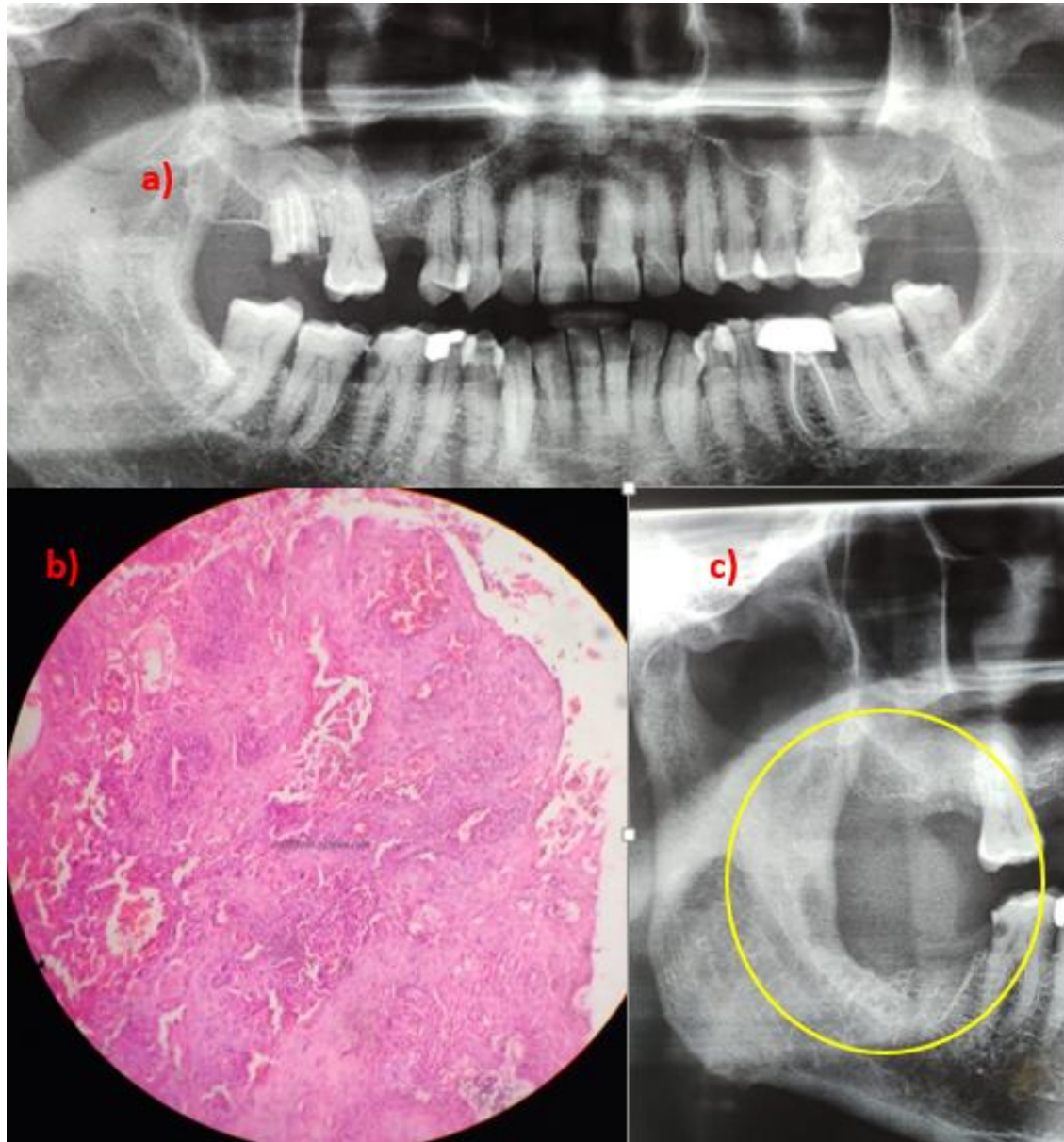


Fig 5a: OPG before extraction of 47, 48; 5b: Histopathological section of biopsy material; 5c: OPG after extraction of 47, 48

DISCUSSION AND CONCLUSION

Five cases of delayed and non-healing wounds were presented. The first case report highlights the need of a proper history, clinical examination, and investigation and referral system for wounds which fail to heal by conventional treatment modalities. The B lymphoblastic leukaemia is a type of leukaemia which affects B lymphocytes. It is the most common type of all. It is an aggressive type of leukaemia with very low prognosis. Although in most cases it cannot be cured, early diagnosis and treatment can help the patient live longer and better^{3, 4, 5}. According to Lynch and coworkers⁶ any type of extractions are contraindicated in patients suffering from leukaemia. Thoma and co-workers was of the

view that surgery in leukemic patients may result in the breakdown of wounds, which may result in profuse bleeding. They further stated that extractions should be performed in such patients only if no other alternatives available." Zegarilli and Kutscher were also of the view that oral surgical procedures are usually contraindicated.⁸ Little and Falace stated that those patients in the acute states of leukaemia should not be taken for oral surgical procedures⁹. The second case report highlights the need of adequate oxygen tension, role of Hb and antibiotic sensitivity in healing process. Sandblom,¹⁰ in a study performed on rabbits found that anaemia produced by post-surgery blood loss and if the volume not replaced might lead to a significant reduction in wound healing. According to Sandberg anaemia induces delayed healing probably mediated by a depression in oxygen delivery to the wound area¹¹. Reduced Hb levels tend to decrease the oxygen level in the developing granulation tissue. Collagen accounts for the strength of the wounds and oxygen is one of the major requirements of collagen synthesis. The energy requirement of the cellular events in wound healing requires ATP, which purely depends on oxidation. Thus the rate limiting factor for collagen synthesis is local bioavailability of oxygen^{12, 13}. Ferrous ion which serves as a co-factor in the enzymatic hydroxylation of proline and lysine in procollagen.¹⁴ So iron deficiency significantly limits the production of mature collagen which is essential for healing. The gravity of antibiotic resistance in wound care is well established. Majority of non-healing post-operative wounds show multiple bacterial strains which are resistant to common antibiotics. In such cases, repeated cultures and sensitivity test is a vital tool to monitor the emergence of resistant strains⁷.

Wounds of the face and those caused by RTA are more likely to harbor retained foreign bodies such as earth and glass particles.^{17,18} Hence at the time of primary care of the wound itself due attention should be given for the cleaning and debridement of the wound. In those instances when the patient has a sensation of foreign body retention or when the wound healing is altered or when there are signs of infection / inflammation consideration should be given for radiograph and/or USG. The third case report highlights the need of thorough debridement of wounds prior to closure.

Extractions are contraindicated for at least 6 months after radiation therapy¹⁹. So prior to radiation therapy proper intraoral examination should be done and the teeth with poor prognosis should be extracted before radiation therapy. An incidence of extraction within 6 months after radiation potentiates the risk of ORN. Recent understanding of the pathophysiology of ORN based on the concept of radiation-induced fibrosis has led to the formulation of novel therapeutic regimens composed of pentoxifylline and tocopherol. Pentoxifylline has a significant role in fibroblast proliferation and extracellular matrix (ECM) production. Pentoxifylline and its metabolites remarkably improve blood flow by decreasing its viscosity and enhance microcirculation and tissue oxygenation. Usually 400 mg dosage of pentoxifylline in extended-release tablet form three times a day is recommended. The effect of pentoxifylline is evident within 2 to 4 weeks; it is recommended that treatment must be continued for at least 8 weeks²¹. Since the patient was not responding to drug therapy surgical management was done which resulted in resolution of the condition.

If the symptoms for which extraction is performed do not resolve completely or if the extraction socket fails to heal, there is obvious chance for underlying pathology²². Failure of a lesion to show adequate signs of healing in a timely manner, is very common when risk

underlying oral SCC are present as seen in case report 5. Such cases cannot be diagnosed by a clinical examination. This warrants prompt referral to an oral and maxillofacial surgeon for proper evaluation and biopsy if required²³.

Ethical Approval:

As per international standard or university standard written ethical approval has been collected and preserved by the author(s).

Consent

As per international standard or university standard, patients' written consent has been collected and preserved by the author(s).

REFERENCES:

1. Adeyemo, W.L., Ladeinde, A.L., Ogunlewe, M.O. Clinical evaluation of post extraction Site wound healing. *J Contemp Dent Pract* 2006; 7 (3): 40-49.
2. Obuekwe, O.N., Akpata, O., Ojo, M.A., Madukwe, I.U., Osaguona, A.O. Malignant tumors presenting after dental extraction: a case series. *East Afr Med J* 2005; 82(5): 256-259.
3. Cerhan, J.R., Slager, S.L., Familial predisposition and genetic risk factors for lymphoma. *Blood*. 2015;126: 2265-2273
4. Roman, C., Montserrat, E., Chronic Lymphocytic leukemia. *N Engl J Med*. 1995;333:1052-1057.
5. Cian J Henry., Leo Stassen. The non-healing extraction socket: a diagnosticdilemma – case report and discussion.*Journal of the Irish Dental Association* 2016; 62 (4): 215-220
6. Lynch MA: *Burket's Oral Medicine*, 7th ed. Philadelphia, J. B. Lippincott Company, 1977, p 420.
7. Thoma KH: *Oral Surgery*, 5th ed. Saint Louis, The C. V. Mosby Company, 1999, p 147.
8. Zegarelli EV, Kutscher AH, Hyman GA: *Diagnosis of diseases of the mouth and jaws*, 2nd ed. Philadelphia, Lea & Febiger, 1978, p 543.
9. Little JW, Falace DA: *Dental Management of the Medically Compromised Patient*. St. Louis, The C. V. Mosby Company, 1980, p 193.

10. Sandblom, P.: The Tensile Strength of Healing Wounds, *Acta Chir Scand*, suppl 89, pp 5-108, 1944.
11. Sandberg, N., and Zederfeldt, B.: Influence of Acute Hemorrhage on Wound Healing in the Rabbit, *Acta Chir Scand* 118:367-371 (April) 1960.
12. Arey L B : Wound healing, *Physiolo.Rev*;16:327, 1966.
13. Beutler, E.: "Tissue Effect of Iron Deficiency" in Gross, F (ed.): *Iron Metabolism*, Berlin: Springer-Verlag, 1964.
14. Kivirikko, K.I., and Prockop, D.J.: Enzymatic Hydroxylation of Proline and Lysine in Protocollagen, *Proc Nat Acad Sci* 57:782-789 (March) 1967.
15. P Margreet G Filius, Inge C gyssens : Impact of increasing antimicrobial resistance on wound management, *Am J Clin Dermatol*. 2003;3(1):1-7.
16. Gron P, Anderson K, Vraa A: Detection of glass foreign bodies by radiography. *Injury* 1986; 17:404-406.
17. Montano JB, Steele MT, Watson WA: Foreign body retention in glass-caused wounds. *Ann Emerg Med* 1992; 21:1360-1363.
18. Stein F: Foreign body injuries of the hand. *Emerg Med Clin North Am* 1985;3:383-390.
19. Lyons A., Ghazali N. Osteoradionecrosis of the jaws: current understanding of its pathophysiology and treatment. *Br J Oral Maxillofac Surg*. 2008;46:653–660.
20. Kluth E. V, Jain PR, Stuchell RN, Frich JC., Jr A study of factors contributing to the development of osteoradionecrosis of the jaws. *J Prosthet Dent*. 1988;59:194–201.
21. Delanian S, Lefaix JL: The radiation-induced fibroatrophic process: therapeutic perspective via the antioxidant pathway. *Radiother Oncol* 2004, 73:119–131.
22. Saxby, P.J., and Soutar, D. S : intraoral tumors presenting after dental extraction. *British Dental Journal*, 166(9),337-338.
23. T. Singh and M Schenber: Delayed diagnosis of oral squamous cell carcinoma following dental treatment: *Ann R Coll Surg Engl*. 2013 Jul; 95(5): 369–373