

Case study

Rare Polypoid disease of the gastro intestinal tract – Cronkhite–Canada syndrome.

Abstract –

Cronkhite–Canada syndrome is a rare condition with multiple hamartomatous polyps in the gastrointestinal tract; need to be differentiated, from other conditions with similar symptoms and polypoid lesions. 52 year old male patient presented with anorexia and weight loss, discovered to be having multiple polypoid lesions in the stomach, duodenum, colon and terminal ileum with histological features of Cronkhite–Canada syndrome. He later developed diarrhoea and characteristic ectodermal signs of CCS. He was treated with prednisolone, sulfasalazine. Nevertheless, the disease was steroid resistant and developed recurrent pneumonia and Candidemia and finally succumbed due to the malnutrition and the infections.

Key wards – Gastrointestinal polyps, Cronkite Canada syndrome, skin pigmentation and alopecia, Diarrhoea and weight loss.

Introduction –

Cronkhite–Canada syndrome [CSS] is a condition with multiple gastrointestinal hamartomatous polyps with high morbidity and mortality due to the absence of effective treatment. This 52 year old male patient presented with anorexia and weight loss was diagnosed to have CCS and succumbed to the illness due to steroid resistant disease and immunosuppression related systemic infections.

Case presentation –

52 year old male patient presented with anorexia for 2 months, weight loss, early satiety, epigastric discomfort, change in taste perception, reflux symptoms with occasional vomiting. There was no dysphagia, per rectal bleeding or passage of mucus and bowel habits remain

unchanged. Arthralgia, skin rashes, nail changes or oral ulcers were not seen at the initial presentation. His past medical history was unremarkable with no family history of gastrointestinal polyposis conditions or malignancies. He was a non-smoker and non-alcoholic. On examination the patient was afebrile, pale, anicteric, apart from mild epigastric region tenderness, the abdominal examination and rectal examination was unremarkable.

Blood count showed normochromic anaemia [haemoglobin - 10.3g/dl] with normal white cell and platelet count. Serum electrolytes, serum creatine, transaminases, bilirubin levels and inflammatory markers were normal. Gastroduodenoscopy revealed multiple polypoid lesions of various sizes and morphology, extensively involving from gastric cardia sparing the esophagus up to the 3rd part of the duodenum extending beyond the reach of the scope [Fig 1,2]. In the initial endoscopy, no significant pyloric obstruction was noted. Colonoscopy also revealed similar lesions from rectums up to the terminal ileum; however, these were smaller and less numerous [Fig 3,4].

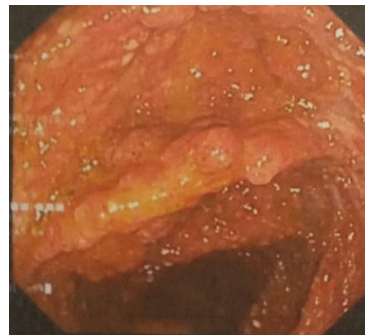
Biopsies from stomach, duodenum and colon showed edematous lamina propria, mix cellular infiltrate with predominant plasma cells, lymphocytes and eosinophil, focal mucosal ulceration. In the stomach and duodenum significant villi atrophy, crypt architectural distortion, fibrosis of the lamina propria with goblet cell metaplasia was noted. There was no granuloma or dysplasia. Base on clinical features and histology findings Cronkhite–Canada syndrome was diagnosed. The MRI enterography showed diffuse inflammatory changes of small and large bowel.

Treatment with Prednisolone 40mg/day and Sulfasalazine 1g/3times a day for 3 months was started with some improvement in appetite and general condition for 2-3 weeks. However, he deteriorated gradually and after 3 months from the presentation he developed diarrhoea, became intolerant to meals and weight loss was dramatic [around 30% loss]. Parenteral nutritional support, regular blood and albumin transfusions were provided. During this time pigmentation of palms and soles, dystrophy of the nails [fig 5] and hair loss was noted. Repeat gastric and duodenal biopsies revealed mild dysplasia in the stomach and immunohistochemistry with pan-cytokeratin was negative for malignancy.

Steroids were withdrawn due to pneumonia and fungemia [candidemia]. He was managed conservatively with parenteral nutrition, jejunostomy feeding, antibiotics and symptomatic treatments for nausea and vomiting. He succumbed due to the illness around 8 months from the initial presentation.

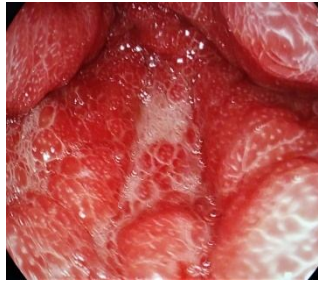
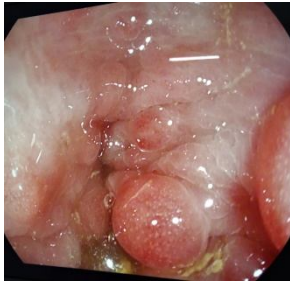
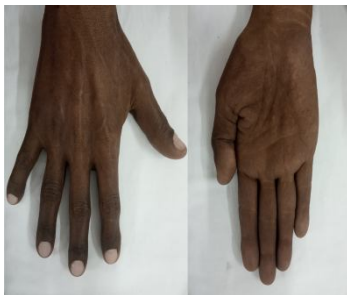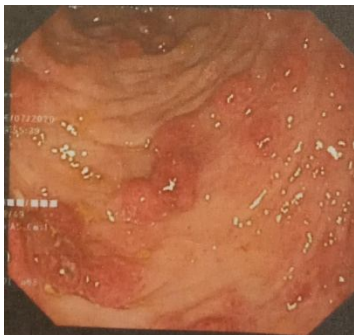Fig 1



Discussion –

Gastrointestinal polyps can be non-neoplastic [hamartomatous, inflammatory and hyperplastic polyps] or neoplastic adenomatous polyps¹. Cronkhite–Canada syndrome is an extremely rare condition of unknown aetiology where numerous non neoplastic, hamartomatous polyps develop in the stomach, duodenum and small bowel and colon with relative sparing of the esophagus^{1,2}.

There is male predominance and condition is common during the 5th and 6th decades². Commonest presentation is diarrhoea and weight loss, seen in 70% of cases resulting from diffuse small bowel mucosal inflammation and atrophy^{3,4}. Changes or reduction of taste [hypogeusia], abdominal discomfort and ectodermal changes [Nail dystrophy, loss of hair and eye brows, skin/ mucosal pigmentation] are other features^{2,3,4,5}. The sequence at which symptoms occur may change².

Hamartomatous polyps are characteristic of CSS where the main features are edema of the lamina propria and mixed cellular infiltration with predominant eosinophils, plasma cells and lymphocytes in contrast to neutrophils in other inflammatory conditions, crypt architectural distortion, loss of duodenal and small bowel villi [linked to protein losing enteropathy] and gastric mucosal atrophy^{2,4}. Hyperplastic and adenomatous polyps may also occur, postulated to be origin of gastric, duodenal and colonic adenocarcinomas; nevertheless, genetic studies and poorly differentiated cancers with no adjacent adenomatous changes suggests cancers in CCS originate in pathways other than adenoma carcinoma sequence⁴. This patient had metaplasia and low grade dysplasia in gastric biopsies and 20% patients showed to develop gastric cancers².

Diagnosis CSS often difficult due to unfamiliarity and nonspecific symptoms and need to be differentiated from other conditions with gastrointestinal polyps [Peutz-Jeghers syndrome (PJS), juvenile polyposis syndrome (JPS), Familial adenomatous polyposis, hyperplastic polyposis, and Cowden disease]^{2,4}. Absence of architectural distortion and cellular infiltrates are important features that differentiate PJS and JPS from CSS². IgG4, CD 138 positivity of plasma cells in the CSS infiltrate can aid in diagnosis^{3,4}. In patients with predominant eosinophilic infiltrate without the typical polyps; eosinophilic gastroenteritis, celiac disease,

parasitic infection, and lymphoma need to be excluded². Diarrhoea and abdominal pain predominant cases, particularly in the early stages can mimic inflammatory bowel disease. Two main MRI features of Crohn's disease, small bowel wall thickening and bowel wall enhancement⁶ was noted in this patient, which indicates MRI enterography is not beneficial in this clinical setting.

Main treatment options are steroids and nutritional optimization including electrolytes, minerals and vitamins^{2,3,4,5}. Hypoalbuminemia is difficult to treat. Evidence suggests high doses of steroid [Prednisolone >30mg/day] for at least 6 months is beneficial; although relapse and steroid resistance is common^{2,3}. Combine use of sulfasalazine have shown added advantage². Azathioprine, cyclosporine and anti-TNF- α drugs are options in resistant cases^{2,4,7}. Further immune suppression was not acceptable in this patient since multiple infections. Resection of localized disease in the colon/ small bowel and repeated endoscopic polypectomy is reported with good success; nevertheless, surgery cannot cure the condition and extensive involvement as seen in this patient makes surgical resection not feasible.

Spontaneous remission with supportive management is reported in some cases, but mortality around 55% observed resulting from immune suppression, malnutrition related problems and gastric and colon malignancies are the main factors contributing to mortality³.

Declarations -

Ethical approval -

Not applicable.

Consent for publication -

Patient consent obtained for publication without personal details.

References –

1. Jerrold R. Turner, Mark W. Lingen (2014), Oral cavity and gastrointestinal tract; in: Vinay Kumar, Abul K. Abbas, Jon C. Aster; Robins basic pathology 9th edition, elsevier saunders, pages 606 to 611.
2. Ze-Yu Wu, Li-Xuan Sang and Bing Chang; Cronkhite–Canada syndrome: from clinical features to treatment; *Gastroenterology Report*, 8(5), 2020, 333–342 doi: 10.1093/gastro/goaa058.
3. Jyong-Hong Lee, Chi-Chieh Yang, Chih-Sheng Wu, Kuo-Hsin Yang; Cronkhite-Canada syndrome: a rare case report and literature review; *Biomedical Research* 2018; 29 (13): 2837-2840.
4. Marcela Kopálová, Ondřej Urban, Jilí Cyrany, Jan Laco, Jan Bureš, Stanislav Rejchrt, Jolana Bártová and Ilja Tachecí; Cronkhite-Canada Syndrome: Review of the Literature; *Gastroenterology Research and Practice* Volume 2013, Article ID 856873, 9 pages <http://dx.doi.org/10.1155/2013/856873>.
5. Sigrid Schulte, Fabian Kütting, Jessica Mertens, Thomas Kaufmann, Uta Drebber, Dirk Nierhoff, Ulrich Töx and Hans-Michael Steffen; Case report of patient with a Cronkhite Canada syndrome: sustained remission after treatment with corticosteroids and mesalazine; *BMC Gastroenterology* (2019) 19:36 <https://doi.org/10.1186/s12876-019-0944-x>.
6. J G Albert, F Martiny, A Krummenerl, K Stock, J Leßke, C M Göbel, E Lotterer, H H Nietsch, C Behrmann, W E Fleig; Diagnosis of small bowel Crohn's disease: a prospective comparison of capsule endoscopy with magnetic resonance imaging and fluoroscopic enteroclysis; *Gut* 2005;54:1721–1727. doi: 10.1136/gut.2005.069427.
7. S. A. Taylor, J. Kelly and D. E. Loomes; Cronkhite-Canada Syndrome: Sustained Clinical Response with Anti-TNF Therapy; *Case Reports in Medicine* Volume 2018, Article ID 9409732, 5 pages <https://doi.org/10.1155/2018/9409732>.