Case study

Mesenteric Adenolymphitis Rare Cause of Abdominal Pain Stimulating Acute Appendicitis

ABSTRACT

Mesenteric adenolymphitis is an inflammation of a part of the abdominal wall. It mainly affects children and can be of viral, bacterial or parasitic origin. Treatment is mainly symptomatic except in the case of bacterial origin where antibiotics must be used.also known as mesenteric adenitis, is an inflammation of the lymph nodes located in the mesentery, a fold of the abdominal peritoneum connecting the small intestine to the posterior wall of the abdomen.is common, typical of young adults and children, in whom it is one of the main reasons for acute abdominal pain in emergency departments and one of the main diagnoses of confusion with appendicitis.she is a clinical entity, the symptoms of which are inflammation of the mesenteric lymph nodes, mainly in the right lower quadrant of the abdomen. Abdominal pain, nausea, diarrhoea and fever are common.

keywords: Mesenteric Adenolymphitis, Abdominal Pain , Acute Appendicitis

INTRODUCTION

Mesenteric adenolymphitis is an inflammation of a part of the abdominal wall. It mainly affects children and can be of viral, bacterial or parasitic origin. Treatment is mainly symptomatic except in the case of bacterial origin where antibiotics must be used.

Mesenteric adenolymphitis, also known as mesenteric adenitis, is an inflammation of the lymph nodes located in the mesentery, a fold of the abdominal peritoneum connecting the small intestine to the posterior wall of the abdomen.

Mesenteric adenolymphitis is common, typical of young adults and children, in whom it is one of the main reasons for acute abdominal pain in emergency departments and one of the main diagnoses of confusion with appendicitis.

Case Presentation

This is a 17 year old patient with no particular pathological history admitted to the emergency department for acute abdominal pain starting in the right iliac fossa with clinical examination: patient conscious, hemodynamically and respiratorily stable with abdominal examination: mac burney positive with the rest of the abdomen soft with the rest of the examination without any particularities, she benefited from a biological check-up which showed HB: 12.9 g/dl hyperleukocytosis at 13000/ul platelet count is 236000/ul abec BHCG count is negative with abdominal CT scan which showed mesenteric adenolymphitis (figure 1) with multiple subcentimetric coelio mesenteric adenopathies the largest is 7mm with

normal appearing appendix in latero-caecal position with ascending course measuring 5mm maximum thickness (figure 2)

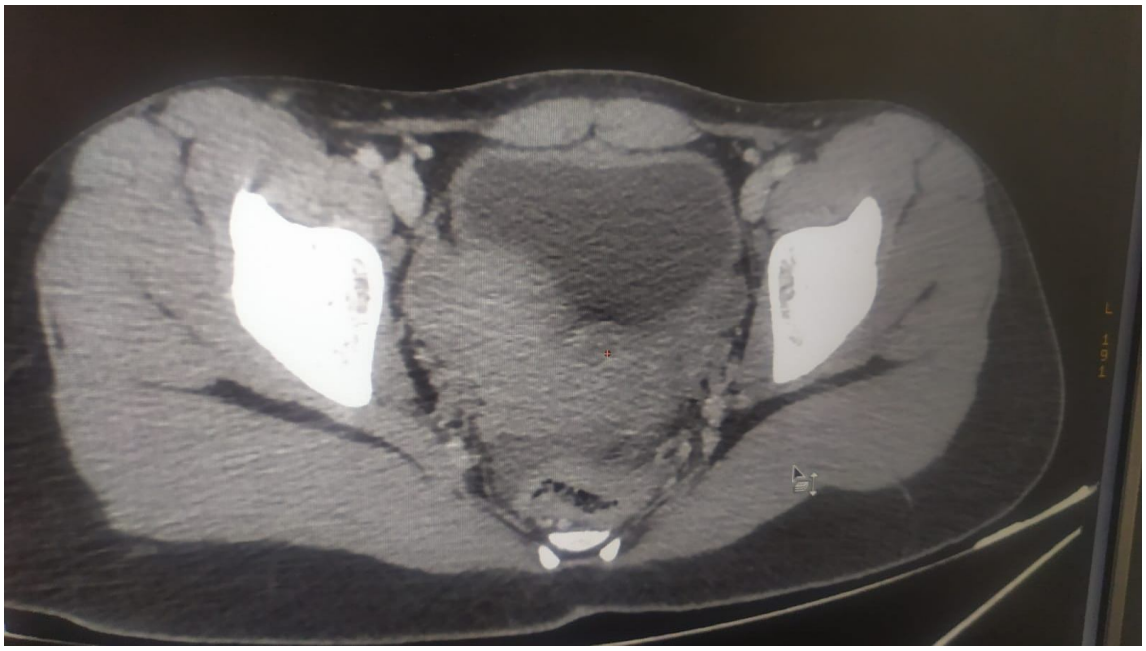

Figure. 1. abdominal CT image showing adenolymphitis

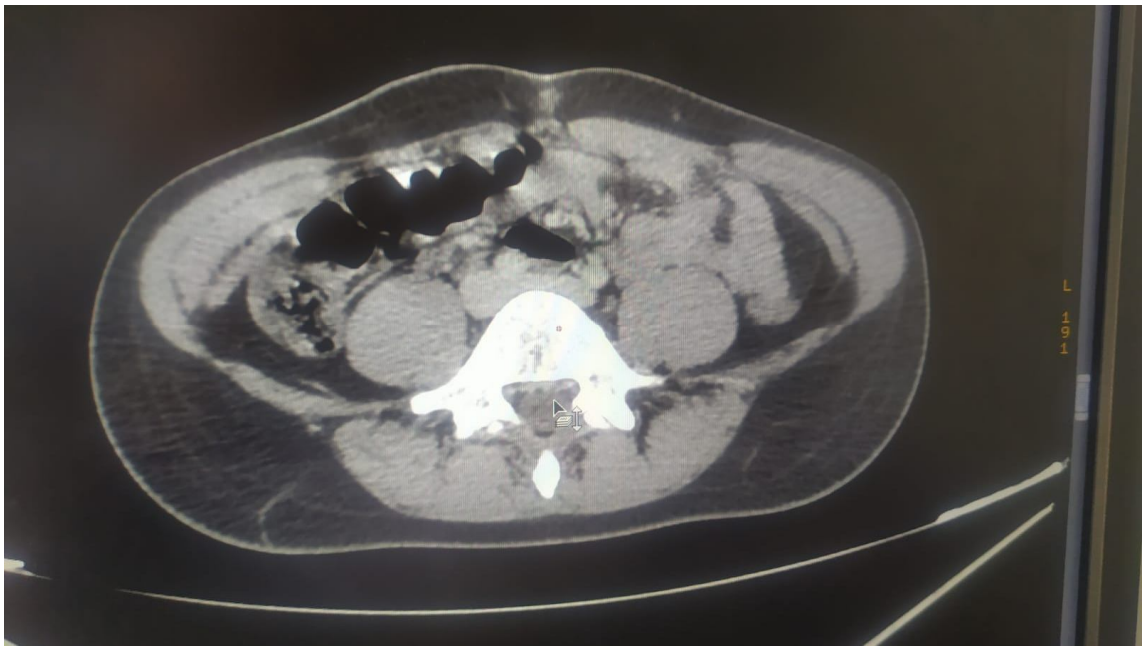

Figure. 2. abdominal CT image showing appendix in latero-caecal position with ascending

The CT scan was sufficient to make the diagnosis of mesenteric adenolymphitis in the face of this very suggestive image. After multidisciplinary discussion, therapeutic abstention was indicated given the intermittent nature of the clinical symptomatology and its moderate intensity with good evolution of the patient under analgesic-based treatment

Discussion

Mesenteric adenolymphitis is viral in 80% of cases (Epstein-Barr Virus), more rarely bacterial (yersinia, mesenteric tuberculosis) or parasitic (toxoplasmosis, lambliasis). Mesenteric adenolymphitis can be caused by an ENT infection, which leads to inflammation of the abdominal lymph nodes.

These nodes are not usually seen in the general adult, asymptomatic, immunocompetent population [1] [20]

The presence of at least 3 nodes with a minor axis greater than 5 mm is necessary for the diagnosis of adenolymphitis. [19]

The presence of these lymph nodes should be a warning sign to look for abdominal pathology [3]. In the absence of any other abnormality, the diagnosis of primary mesenteric adenolymphitis is made. If an intra-abdominal inflammatory process is detectable, it is a secondary mesenteric adenolymphitis [1]: appendicitis or Crohn's disease in flare-up, infectious colitis, ulcerative colitis, acute systemic lupus erythematosus [18]

Infectious aetiologies are related to Yersinia type bacteria, which often reach the terminal ileum, whose wall is thickened. [17] [21]

The median age of primary adenolymphitis is 21 years, and 30 years for secondary adenolymphitis [1]. The distinction between primary and secondary adenolymphitis is important, as it may affect the management of the disease. [23] [24]

To confirm the diagnosis of mesenteric adenolymphitis it is necessary to use blood cultures, urine microscopy or an abdominal scan. [11]

Symptoms of mesenteric adenolymphitis are Hypogastric pain, most often in the right iliac fossa with nausea, vomiting, diarrhoea, loss of appetite, abdominal distension, sometimes in the form of respiratory tract infections, all evolving in a feverish picture. [12] [22]

Because of its similar symptoms, mesenteric adenolymphitis is often confused with appendicitis in young adults and adolescents. 10-20% of patients who undergo exploratory surgery for suspected acute appendicitis have their diagnosis corrected to mesenteric adenolymphitis. However, unlike appendicitis, mesenteric adenitis is often accompanied by inflammation of other lymphoid organs, such as the tonsils. [9] [13]

Mesenteric adenitis generally has a good prognosis. However, it can sometimes lead to complications such as: abscesses, dehydration if the patient has severe diarrhoea or vomiting, arthralgia or even sometimes progressing to peritonitis or sepsis. [3] [10]

The distinction between adenolymphitis and appendicitis is difficult. Seven percent of suspected appendicitis is actually adenolymphitis [2]. Nodes are also present in appendicitis, but the nodes are usually more numerous, larger in adenolymphitis and the appendix is normal in appearance (or there is a history of appendectomy). [2] [7]

In children, the lymphatic system increases rapidly in size, reaching adult size by the age of 6 years. The mesenteric lymph nodes are therefore easily visible on ultrasound or CT scan. The minimum size of the minor lymph node axis can be considered pathological if it is larger than 8mm [4]. The size of the lymphatic system then decreases during puberty. [5] [23]

Treatment of mesenteric adenolymphitis is usually viral in origin, and heals spontaneously. [8]

The management of mesenteric adenolymphitis is therefore mainly symptomatic. The treatments associated with mesenteric adenolymphitis are: analgesics [6]

Treatments identical to those proposed for gastroenteritis. Antidiarrhoeals, hydration, antibiotic therapy is used when the infection is bacterial in nature. [14]

Prevention To avoid a bacterial infection, it is advisable to be vigilant in terms of cleanliness of the home and personal hygiene. It is advisable to avoid being in the company of people who are ill and have a virus. It is also important to wash your hands regularly [15]

CONCLUSION

Mesenteric adenolymphitis is a clinical entity, the symptoms of which are inflammation of the mesenteric lymph nodes, mainly in the right lower quadrant of the abdomen. Abdominal pain, nausea, diarrhoea and fever are common. [16]

REFERENCES

[1] Macari M, Hines J, Balthazar E & Megibow A. Mesenteric adenitis: ct diagnosis of primary versus secondary causes, incidence, and clinical significance in pediatric and adult patients. AJR Am J Roentgenol (2002) 178: pp. 853-858.

[2] Rao PM, Rhea JT & Novelline RA. Ct diagnosis of mesenteric adenitis. Radiology (1997) 202: pp. 145-149.

[3] Lucey BC, Stuhlfaut JW & Soto JA. Mesenteric lymph nodes seen at imaging: causes and significance. Radiographics (2005) 25: pp. 351-365.

[4] Karmazyn B, Werner EA, Rejaie B & Applegate KE. Mesenteric lymph nodes in children: what is normal?. Pediatr Radiol (2005) 35: pp. 774-777.

[5] D. Djeddi * , L. Ribeiro, A.-L. Leke, B. Boudailliez, J.-P. Canarelli Adénolymphite mésentérique à Yersinia pseudotuberculosis simulant une tumeur abdominopelvienne chez l'enfant – 2003

[6] Macari M, Hines J, Balthazar E, Megibow A. Mesenteric adenitis: CT diagnosis of primary versus secondary causes, incidence, and clinical significance in pediatric and adult patients. AJR Am J Roentgenol 2002;178:853—8.

[7] Rao PM, Rhea JT, Novelline RA. CT diagnosis of mesenteric adenitis. Radiology 1997;202:145—9

[8] Horton KM, Corl FM, Fischman EK. CT evaluation of the colon: inflammatory disease. Radiographics 2000;20:399—418.

[9] Puylaert JB, Van Der Zant FM, Mutsaers JA. Infectious ileocecitis caused by Yersinia, Campylobacter, and Salmonella: clinical, radiological and US findings. Eur Radiol 1997;7:3—9.

[10] Merine DS, Fishman EK, Jones B, Nussbaum AR, Simmons T. Right lower quadrant pain in the immunocompromised patient: CT findings in 10 cases. AJR Am J Roentgenol 1987;149:1177—9.

[11] Katz DS, Lane MJ, Ross BA, Gold BM, Jeffrey Jr RB, Mindelzun RE. Diverticulitis of the right colon revisited. AJR Am J Roentgenol 1998;171:151—6.

[12] Coulier B, Maldague P, Bourgeois A, Broze B. Diverticulitis ofthe small bowel: CT diagnosis. Abdom Imaging 2007;32:228—33.

[13] Bennett GL, Birnbaum BA, Balthazar EJ. CT of Meckel's diverticulitis in 11 patients. AJR Am J Roentgenol 2004;182: 625—9.

[14] Taourel P, Aufort S, Merigeaud S, Curros Doyon F, Hocquet MD, Delabrousse E. Imaging of ischaemic colitis. Radiol Clin North Am 2008;46:909—24.

[15] Tsai HL, Hsieh JS, Yu FJ, Wu DC, Chen FM, Huang CJ, et al. Perforated colonic cancer presenting as int

[16] Tsuboi M, Takase K, Kaneda I, Ishibashi T, Yamada T, Kitami M, et al. Perforated and non perforated appendicitis: defect in enhancing appendiceal wall-depiction with multi-detector row CT. Radiology 2008;246:142—7.

[17] Foley TA, Earnest 4th F, Nathan MA, Hough DM, Schiller HJ, Hoskin TL. Differentiation of nonperforated from perforated appendicitis: accuracy of CT diagnosis and relationship of CT findings to length of hospital stay. Radiology 2005;235:89—96.

[18] Ganguli S, Raptopoulos V, Komlos F, Siewert B, Kruskal JB. Right lower quadrant pain: value of the nonvisualized appendix in patients at multidetector CT. Radiology 2006;241:175—80.

[19] Merigeaud S, Millet I, Taourel P. Acute appendicitis in CT of the acute abdomen. Ed. P Taourel. Medical Radiology. Diagnostic Imaging. Springer-Verlag Berlin Heidelberg 2011;143—81.

[20] Nikolaidis P, Hwang CM, Miller FH, Papanicolaou N. The nonvisualized appendix: incidence of acute appendicitis when secondary iniflammatory changes are absent. AJR Am J Roentgenol 2004;183:889—92.

[21] Balthazar EJ, Birnbaum BA, Yee J, Megibow AJ, Roshkow J, Gray C. Acute appendicitis: CT and US correlation in 100 patients. Radiology 1994;190:31—5.

[22] Pickuth D, Heywang-Köbrunner SH, Spielmann RP. Suspected acute appendicitis: is ultrasonography or computed tomography the preferred imaging technique? Eur J Surg 2000;166:315—9.

[23] Gaitini D, Beck-Razi N, Mor-Yosef D, Fischer D, Ben Itzhak O, Krausz MM, et al. Diagnosing acute appendicitis in adults: accuracy of color doppler sonography and MDCT compared with surgery and clinical follow-up. AJR Am J Roentgenol 2008;190:1300—6.

[24] Keyzer C, Zalcman M, De Maertelaer V, et al. Comparison of US and unenhanced multi-detector row CT in patients suspected of having acute appendicitis. Radiology 2005;236:527—34.