

Urinary tract endometriosis: Surgical perspective

Abstract:

Urinary tract endometriosis is debilitating disease affecting young woman of reproductive age. Deterioration or loss of renal function can occur if early diagnosis and treatment is not done. We present a case of endometriosis involving urinary tract in a 36 years old woman. She presented with abdominal pain, dysuria and was found to have urinary bladder mass involving left ureteric orifice on ultrasound and CT scan of abdomen causing obstructive uropathy. Cystoscopy was planned in a view to get intravesical view and tissue diagnosis. Cystoscopy confirmed presence of broad based, exophytic, vascular mass involving left half of the trigone of urinary bladder. Biopsy of the mass was suggestive of endometriosis. Open partial cystectomy, left ureteroneocystostomy with hysterectomy was performed in order to save renal function and prevent further recurrence.

Key words:

Endometriosis, Urinary tract, Obstructive uropathy.

Introduction:

Endometriosis is defined as the presence of endometrial glandular and stromal tissue outside the uterus accompanied by chronic inflammation. Various classifications suggest presence of endometriosis at various places in the female genital tract¹.

Case report:

36 years, para 2 female was investigated for chronic, dull aching lower abdominal pain and dysuria for one year and 3 months duration. History of pain aggravation during menses was present. Her menstrual cycles were regular with moderate flow and used to last for 3 to 4 days. She had caesarean section delivery twice in the past two and three years back respectively. Clinical examination revealed suprapubic tenderness on deep palpation. She had palpable induration at left posterolateral fornix on prevaginal bimanual examination. Laboratory evaluation including a complete blood count, serum biochemical analysis, renal function tests, urine analysis and urine culture were normal (Table no.1). Ultrasonography of abdomen and pelvis was suggestive of exophytic mass at the base of bladder close to left ureteric orifice with moderate left hydronephrosis. CT scan of abdomen and pelvis confirmed the findings of obstruction of left ureter by a mass lesion of 3 x 3.5 cm at the base of urinary bladder (Fig.1).

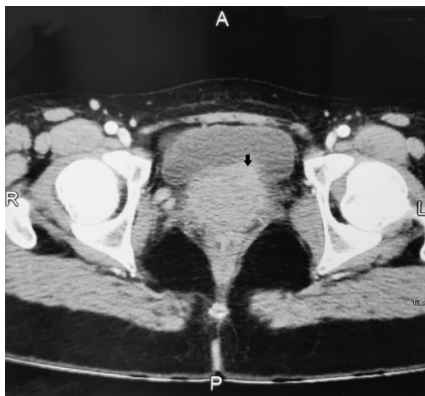


Fig.1 CT scan abdomen and pelvis

(Black arrow denotes deep infiltrating mass at left half of the bladder trigone)

A diagnostic cystoscopy was performed after clinical workup under anaesthesia to get clear intravesical view of the lesion and tissue diagnosis. A papillary, exophytic, vascular mass of 3 x 3.5cm was noted at left half of

trigone involving left ureteric orifice (Fig.2). Right ureteric orifice was normal. Rest of the urinary bladder mucosa was normal. The capacity of the bladder was normal. Deep biopsy of the lesion was taken for confirmation of diagnosis. Histopathological examination suggested the diagnosis of endometriosis.

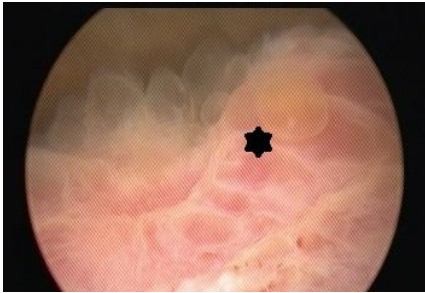


Fig. 2 Cystoscopy findings

(* denotes papillary exophytic mass at bladder trigone)

Based on clinical, endoscopic, radiological and histopathological findings treatment plan was decided. We did not prefer a hormonal therapy in our patient due to evident ureteral obstruction and hydronephrosis. If there had been a delay in the treatment of our patient, kidney function might have been lost.

Partial cystectomy, left neoureterocystostomy with concomitant hysterectomy was planned as patient expressed no desire for future fertility. An open laparotomy approach was planned. Under general anaesthesia cystoscopy with placement of right ureteral catheter was done. Left ureteric orifice was involved in the mass lesion hence couldn't be catheterised. Indwelling Foley catheter was placed in the urinary bladder. Abdomen was opened by midline infraumbilical incision. Dense adhesions were noted at uterovesical fold. Adhesions of left ovary with uterus were present. Left hydronephrosis was noted, right ureter was normal in course and calibre. Standard hysterectomy was performed with bilateral salpingectomy, the adherent ovary was removed along with specimen. The other side ovary was preserved considering young age of the patient to avoid early menopausal effects. Vaginal vault was closed in layers. Urinary bladder was opened in midline and bivalved vertically. Left trigonal mass was excised along with left ureteric orifice in a full thickness manner, keeping 3-4mm lesion free margin (Fig.3). Right ureteric orifice was preserved by using pre placed ureteral catheter as a guide. Left anti refluxing neoureterocystostomy was performed, DJ was placed in the left ureter. Urinary bladder was closed carefully two layers. Greater omental process with pedicle was mobilised and fixed as an interposing flap between urinary bladder and vaginal vault in an attempt to avoid vesicovaginal fistula in future. Histopathology confirmed the presence of benign endometrial glands in muscularis propria of the urinary bladder (Fig.4). Postoperative course was uneventful; Foley catheter was removed on 7th postoperative day and left DJ stent was removed after two weeks.

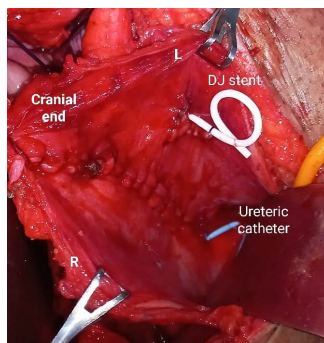


Fig. 3 Operative findings

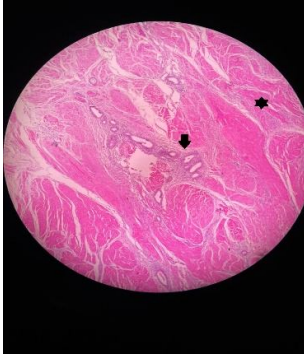


Fig. 4 Histopathology findings (Arrow denotes presence of endometrial glandular tissue while * denotes normal detrusor muscle of the bladder)

Discussion:

Endometriosis is a chronic, estrogen-dependent disease and affects 6 to 10% of reproductive-age women. Urinary tract involvement is observed in approximately 1% females². The term urinary tract endometriosis (UTE) refers to endometriotic tissue implants in the bladder, ureter, kidney, and urethra. Among women with UTE, the prevalence of disease at specific sites is as follows: bladder, 85%; ureter, 10%; kidney, 4%; and urethra, 2%³. In 36% of cases the endometriosis is localized only in the bladder, however, different locations of UTE may coexist.

Three broad types of endometriosis are described according to the disease morphology and localization: ovarian, superficial peritoneal and deep infiltrative endometriosis (DIE). DIE most commonly invades the rectovaginal space, uterosacral ligaments, bowel or urinary tract⁴. Endometriosis involving urinary bladder is a type of DIE diagnosed in 11% of overall patients.

Bladder endometriosis is further classified as 'primary' or 'secondary'⁵⁻⁶ depending on its onset. Primary lesion is a spontaneously occurring disease. Major theories postulate the origin of endometriotic tissue due to retrograde menstruation, coelomic metaplasia, and lympho-vascular metastasis²².

The secondary bladder endometriosis is an iatrogenic lesion, occurring after pelvic surgery, such as caesarean delivery or hysterectomy. Up to 50% of patients with bladder endometriosis have a past history of pelvic surgery^{7,8}. The lesion usually starts from the serosal surface of the bladder and evolve towards mucosa and it is often multifocal. The trigone and dome of the bladder are the most frequently affected sites⁹⁻¹⁰. Involvement of ureteric orifice in the bladder as in our case, can potentially lead to loss of renal function by severe hydronephrosis leading to urinary tract obstruction.

Woman with UTE may present with abdominal or flank pain, renal colic, haematuria, cyclical dysuria, dyspareunia, urgency, frequency and suprapubic pain. About 30% of the patients with bladder endometriosis remain asymptomatic and the diagnosis is incidental. Rest 70% of women present with urinary storage symptoms at the time of first diagnosis. Cyclical gross haematuria is present in only 20% of cases and is pathognomonic for bladder endometriosis¹¹. Symptoms may get aggravated during menses, due to engorgement of the endometrial tissue within the invaded organ which distends and stretches the surrounding tissue. In the present case patient presented with chronic, dull aching lower abdominal pain. However, considering her reproductive age with history of previous pelvic surgery and no documented infection raised a concern about UTE.

The physical examination (bimanual per vaginal examination) may suggest endometriotic infiltration of the pelvis if there is a palpable nodule, or thickened area, or a palpable cystic expansion with anatomical correlation to uterosacral ligaments, vagina, rectovaginal space, pouch of Douglas, the rectosigmoid and the posterior wall of the urinary bladder¹² as in a given case. Apart from routine blood tests all patients should also be assessed for

renal function test as silent loss of renal function is known in DIE. Urine should be evaluated for evidence of microscopic or macroscopic haematuria. Urine cultures are usually negative. Urine cytology is mandatory in order to exclude bladder cancer. Combination of abdominal, transvaginal and if needed transrectal ultrasound examination should be performed. It may reveal heterogeneous, hyperechoic, intraluminal nodules in the bladder. Hydroureter and hydronephrosis will be revealed if the lesion is involving ureteral orifice¹⁹ as in our case.

Pelvic magnetic resonance has high sensitivity and specificity for diagnosis of urinary tract endometriosis. The diagnosis of bladder endometriosis is based upon a hypointense signal of nodules on T2-weighted images with a frequent hyperintense signal on fatty saturation of T1-weighted images¹⁹.

Cystoscopy may demonstrate an intraluminal mass of the posterior bladder wall, trigone or dome. Ureteral orifices should be assessed carefully. If needed retrograde pyelography should be done to rule out ureteral involvement. Morphology of the lesion changes with phases of menstrual cycle. During menstruation the lesions are larger and appear congested. Colour may vary from blue, brown, black to red and purple²⁰. Biopsy of the lesion is critical for histopathological confirmation and to rule out carcinoma.

The differential diagnosis includes bladder carcinoma, angiomas, leiomyoma, amyloidosis, malakoplakia and glandular cystitis.

Treatment depends on multiple factors as age, fertility preferences and extent of the disease. Treatment can be either medical, surgical or combination of both.

Medical treatment includes hormonal therapy. The aim of medical treatment is to induce regression of the endometrial tissue. It includes gonadotrophin-releasing hormone (GnRH) agonists and antagonist, progestins and combined oral contraceptives²¹.

Hormonal therapy causes temporary regression of DIE and is effective modality for those desiring to preserve fertility. Even if all these drugs may alleviate the severity of pelvic pain, dysmenorrhea and dyspareunia, the symptoms may recur when therapy is discontinued¹³. The hormonal therapy does not change obstruction secondary to fibrous tissue and adhesions in DIE¹⁴. Although medical treatment may be effective in selected cases, it is advisable to remove all visible endometriotic lesions, especially deep endometriotic lesions by surgical approach¹⁵.

Main goals of the surgical treatment should be preservation of renal function, relief of obstruction and prevention of recurrence. Precise pre operative workup is needed to plan accurate surgical procedure. Transurethral resection of endometrial lesions in the bladder can be performed. It is indicated in superficial lesions specially in premenopausal females with desire to preserve fertility. Histopathological confirmation is added benefit of TUR. However, in DIE, trans urethral resection should be combined with hormonal therapy in order to reduce risk of recurrence¹⁶. Combined TUR with laparoscopic excision of endometrial implants is preferable in case of concomitant intraperitoneal deposits.

Partial cystectomy is a procedure which involves full thickness surgical excision of the DIE involving the bladder wall with preservation of bladder function. It can safely be performed in cases with monofocal lesions with aim of 1-2cm lesion free margins. Patient should have normal bladder capacity and function pre-operatively. Several reports suggest excellent outcomes in terms of symptom relief and recurrence rate¹⁷. Approach for the procedure can be either open, laparoscopic or robotic. Pre op cystoscopy is advisable to define exact part of the bladder to be removed. If the lesion is in trigonal area around ureteral orifices, as in our case then placement of either ureteric catheters or DJ stents can be done to avoid intra op ureteral injury. If bladder DIE has involved ureteral orifices, full thickness excision with reimplantation of the ureter at a new place in the bladder (neoureterocystostomy) should be done to avoid recurrence of the disease¹⁸. Concomitant hysterectomy can be performed if fertility is not desired and in women approaching menopause. Table 2 denotes available surgical treatments.

Conclusion:

Urinary tract endometriosis is a debilitating disease that impacts quality of life of reproductive age women. Silent loss of renal function due to obstructive uropathy is known, hence early diagnosis and precise treatment is crucial. Considering recurrence rates long term follow up is essential.

Table no.1 Laboratory parameters

Lab parameter	Value
Haemoglobin	12 mg%
Total leucocyte count	6500/mm ³
Blood Urea	32 mg%
Serum creatinine	1.2mg%
Urine culture	No growth

Table no.2

Surgical treatment for endometriosis¹¹

Surgical treatment		Indication
Trans Urethral Resection (TUR) of the lesion		Superficial lesions in premenopausal women desired to preserve fertility usually combined with hormonal therapy.
Partial Cystectomy (With or without concomitant cystoscopy)	Laparotomy	Monofocal deep infiltrating endometriosis lesions
	Laparoscopy	
	Robotic	
Combined Transurethral resection and laparoscopic excision of peritoneal lesions		Concomitant intraperitoneal endometriotic deposits with bladder endometriosis.
Partial cystectomy with unilateral or bilateral ureteral reimplantation		Deep infiltrating endometriosis involving ureteric orifices

References

1. Shook TE, Nyberg LM: Endometriosis of the urinary tract. *Urology* 1988; 31: 1–6.
2. Abeshouse BS, Abeshouse G: Endometriosis of the urinary tract: a review of the literature and a report of four cases of vesical endometriosis. *J Int Coll Surg.* 1960, 34: 43-63.
3. Berlanda, N.; Vercellini, P.; Carmignani, L.; Aimi, G.; Amicarelli, F.; Fedele, L. Ureteral and Vesical Endometriosis. *Obstet. Gynecol. Surv.* 2009, 64, 830–842.
4. Trașca ET, Trașca E, Titu A, Rıza ML, Busuioac I: Ureteral stenosis due to endometriosis. *Rom J Morphol Embryol.* 2012, 53: 433-437.
5. Blumenkrantz MJ, Gallagher N, Bashore RA, Tenckhoff H: Retrograde menstruation in women undergoing chronic peritoneal dialysis. *Obstet Gynecol* 1981; 57: 667–670.
6. Chapron C, Chopin N, Borghese B, Foulot H, Dousset B, Vacher-Lavenu MC, Vieira M, Hasan W, Bricou A: Deeply infiltrating endometriosis: pathogenetic implications of the anatomical distribution. *Hum Reprod* 2006; 21: 1839–1845.
7. Horne A.W., Saunders P.T. SnapShot: Endometriosis. *Cell.* 2019; 179:1677–1677.e1. doi: 10.1016/j.cell.2019.11.033.

8. Batler RA, Kim SC, Nadler RB: Bladder endometriosis: Pertinent clinical images. *Urology*. 2001, 57: 798-799. 10.1016/S0090-4295(00)01114-6.
9. Gehr TW, Sica DA: Case report and review of the literature: ureteral endometriosis. *Am J Med Sci*. 1987, 294: 346-352. 10.1097/00000441-198711000-00009.
10. Yohannes P: Ureteral endometriosis. *J Urol*. 2003, 170: 20-25.
11. Carmen Maccagnano, Federico Pellucchi et al: Diagnosis and Treatment of Bladder Endometriosis: State of the Art. *Urol Int* 2012; 89:249–258.
12. Collinet P, Marcelli F, Villers A, Regis C, Lucot JP, Cosson M, Vinatier D: Management of endometriosis of the urinary tract. *Gynecol Obstet Fertil* 2006; 34: 347–352.
13. Sánchez Merino JM, Guillán Maquieira C, García Alonso J: The treatment of bladder endometriosis. *Arch Esp Urol* 2005; 58: 189–194.
14. Shafirir AL, Farland LV, Shah DK, et al. Risk for and consequences of endometriosis: a critical epidemiologic review. *Best Pract Res Clin Obstet Gynaecol* 2018; 51:1-15.
15. Stepniewska A, Grosso G, Molon A, Caleffi G, Perin E, Sciosca M, Mainardi P, Minelli L: Ureteral endometriosis: clinical and radiological follow-up after laparoscopic ureterocystoneostomy. *Hum Reprod*. 2011, 26: 112-116. 10.1093/humrep/deq293.
16. Dunselman GA, Vermeulen N, Becker C, Calhaz-Jorge C, D’Hooghe T, De Bie B, Heikenneimo O, Horne AW, Kiesel L, Nap A, Prentice A, Saridogan E, Soriano D, Nelen W: ESHRE guideline: management of women with endometriosis. *Hum Reprod*. 2014, 29: 400-412.
17. Garcia-Rojo D, Hannoui N., Vicente E. : Bladder Endometriosis: Clinical, Diagnostic and Therapeutic Aspects, *Urology*, Vol 78, issue 3, supplement, s208-s209, September 01, 2011 <https://doi.org/10.1016/j.urology.2011.07.625>.
18. Somigliana E., Vercellini P., Gattei U., Chopin N., Chiodo I., Chapron C. Bladder endometriosis: Getting closer and closer to the unifying metastatic hypothesis. *Fertil. Steril*. 2007; 87:1287–1290. doi: 10.1016/j.fertnstert.2006.11.090.
19. Mathew Leonardi, Mercedes Espada. Endometriosis and the Urinary Tract: From Diagnosis to Surgical Treatment. *Diagnostics* 2020, 10, 771; doi:10.3390/diagnostics10100771.
20. Geng, J.H.; Lee, Y.C. Bladder Endometriosis. *N. Engl. J. Med*. 2019, 381, e43.
21. Tommaso Capezzuoli, Sara Clemenza. Classification/staging systems for endometriosis: the state of the art. *Gynaecological and Reproductive Endocrinology and Metabolism* 2020; 1(1):14-22.
22. Krina T. Zondervan, Christian M. Becker, Endometriosis. *N Engl J Med* 2020; 382:1244-56. DOI: 10.1056/NEJMra1810764.